

Case Report

The Masquelet technique for septic arthritis of the small joint in the hands: Case reports

Taichi Saito^{a,*}, Tomoyuki Noda^b, Hiroya Kondo^a, Koji Demiya^a, Satoshi Nezu^a, Suguru Yokoo^a, Minami Matsuhashi^a, Takenori Uehara^a, Yasunori Shimamura^c, Masayuki Kodama^d, Toshifumi Ozaki^a

^a Department of Orthopaedic Surgery, Okayama University Graduate School of Medicine, Dentistry and Pharmaceutical Sciences, Okayama, Japan

^b Department of Musculoskeletal Traumatology, Okayama University Graduate School of Medicine, Dentistry and Pharmaceutical Sciences, Okayama, Japan

^c Department of Sports Medicine, Okayama University Graduate School of Medicine, Dentistry and Pharmaceutical Sciences, Okayama, Japan

^d Mizushima Central Hospital, Okayama, Japan

ARTICLE INFO

Keywords:

The small joint
Hand
Septic arthritis
Masquelet technique
Induced membrane

ABSTRACT

Septic arthritis in distal interphalangeal (DIP) joints sometimes occurs in association with mucous cysts or after the surgical treatment of mallet fingers. Recently, several studies have demonstrated the effectiveness of the Masquelet technique in the treatment of bone defects caused by trauma or infection. However, only few studies have reported the use of this technique for septic arthritis in small joints of the hand, and its effectiveness in treating septic arthritis in DIP joints remains unclear.

We report the clinical and radiological outcomes of three patients who were treated with the Masquelet technique for septic arthritis in DIP joints. One patient had uncontrolled diabetes and another had rheumatoid arthritis treated with methotrexate and prednisolone. The first surgical stage involved thorough debridement of the infection site, including the middle and distal phalanx. We placed an external fixator from the middle to the distal phalanx and then packed the cavity of the DIP joint with antibiotic cement bead of polymethylmethacrylate (40 g) including 2 g of vancomycin and 200 mg of minocycline. At 4–6 weeks after the first surgical stage, the infection had cleared, and the second surgical stage was performed. The external fixator and cement bead were carefully removed while carefully preserving the surrounding osteo-induced membrane. The membrane was smooth and nonadherent to the cement block. In the second surgical stage, an autogenous bone graft was harvested from the iliac bone and inserted into the joint space, within the membrane. The bone graft, distal phalanx, and middle phalanx were fixed with Kirschner wires and/or a soft wire. Despite the high risk of infection, bone union was achieved in all patients without recurrence of infection. Although the Masquelet technique requires two surgeries, it can lead to favorable clinical and radiological outcomes for infected small joints of the hand.

* Corresponding author at: Department of Orthopaedic Surgery, Okayama University Graduate School of Medicine, Dentistry and Pharmaceutical Sciences, 2-5-1, Shikata-cho, Kitaku, Okayama City 700-8558, Japan.

E-mail address: umehachi55@gmail.com (T. Saito).

<https://doi.org/10.1016/j.tcr.2019.100268>

Accepted 30 November 2019

2352-6440/© 2019 The Authors. Published by Elsevier Ltd. This is an open access article under the CC BY-NC-ND license (<http://creativecommons.org/licenses/by-nc-nd/4.0/>).

Introduction

Septic arthritis in distal interphalangeal (DIP) joints sometimes occurs in association with mucous cysts or after the surgical treatment of mallet fingers. Some studies have shown that external fixation is an effective method for the treatment of septic arthritis in small joints of the hand [1,2] because wound care can be continued while avoiding fixation at the infection site and enforcing rigid fixation.

Recently, the Masquelet technique has attracted attention for the treatment of bone defects and non-union caused by trauma or infection [3]. This technique comprises a two-stage surgical procedure. In the first surgical stage, radical debridement of necrotic or infected tissue is performed, followed by cement spacer grafting with or without antibiotics. After 4–8 weeks of the first surgery, the cement spacer is removed carefully while leaving the induced membrane intact. In the second surgical stage, a bone graft is implanted inside the membrane.

However, only few studies have reported the appropriate management of septic arthritis in small joints of the hands [4,5]. Additionally, it is unclear whether the Masquelet technique is effective for treating septic arthritis in DIP joints. Here, we report the clinical and radiological outcomes of three patients who were treated with the Masquelet technique for septic arthritis in DIP joints. All the patients provided signed informed consent for the publication of their cases.

Case reports

Case 1

A 50-year-old woman with untreated diabetes presented a painful DIP joint of the index finger related to Heberden's node and mucous cyst since a few years, and now complained of severe pain, redness, and swelling at the DIP joint that had been discharging pus over the past month. She was referred to our hospital with a diagnosis of septic arthritis.

Initial examination revealed that the patient had swelling and erythema of the DIP joint of the index finger. X-ray revealed narrowing of the DIP joint space with lytic bone lesions surrounding the DIP joint. Magnetic resonance imaging (MRI) revealed joint effusion and bone marrow changes, which were suggestive of osteoarthritis and osteomyelitis in the DIP joint (Fig. 1a).

In the first surgical stage, the wound, including the infected parts of the middle and distal phalanx, was thoroughly debrided. An external fixator was placed from the middle to the distal phalanx. An antibiotic cement bead of polymethylmethacrylate (40 g) with 2 g of vancomycin and 200 mg of minocycline was packed in the cavity of the DIP joint (Fig. 1b). Cefazolin was administered intravenously preoperatively and continued for two weeks after the first operation.

Signs of improvement were observed 4 weeks after the first surgery, and swelling and redness of the soft tissues around the DIP joint had reduced. The external fixator and antibiotic spacer were carefully removed without disrupting the surrounding osteo-induced membrane, which was very smooth and nonadherent to the antibiotic cement block (Fig. 1c). In the second surgical stage, an iliac crest bone autograft was harvested and packed inside the membrane. The autograft, distal phalanx, and middle phalanx were fixed with small Kirschner wires (K-wires) and a soft wire (Fig. 1d).

At the 3-month follow-up, X-ray revealed bone union and the wires were removed 6 months after the bone graft. At the 1-year follow-up, the patient had no abnormal sensation and demonstrated good range of finger motion except in the fused joint (Fig. 1e). She was able to return to her original work.

Case 2

A 71-year-old woman underwent K-wire fixation for bony mallet finger in her thumb. She had received methotrexate (8 mg/week) and prednisolone (5 mg/day) for rheumatoid arthritis (RA). Two months after the surgery, she presented redness and swelling at the interphalangeal (IP) joint with draining pus. Therefore, the patient was referred to our hospital. On initial examination, she had swelling and erythema at the IP joint, and X-ray and MRI revealed osteoarthritis and osteomyelitis around the IP joint (Fig. 2a). The patient was administered cefazolin, preoperatively, and underwent the two-stage surgical procedure as described for Case 1 (Fig. 2b and c). Cefazolin (2 g/day) administration was continued for two weeks.

Bone union was achieved at the 4-month follow-up. At the 1-year follow-up the patient had no abnormal sensation or pain and demonstrated full range of motion in the finger except in the fused joint (Fig. 2d).

Case 3

A 67-year-old woman underwent open reduction and internal fixation for chronic bony mallet finger in the middle finger. At her first visit to the hospital after surgery, the wound showed signs of infection and her DIP joint was swollen, red, and tender. X-ray and MRI revealed osteoarthritis and osteomyelitis around the DIP joint (Fig. 3a). We performed the two-stage surgical procedure, similar to that in the previous cases (Fig. 3b and c). Cefazolin was also administered as the same as others. Bone union was achieved at the 3-month follow-up. The patient had a full range of motion in the finger except in the fused joint, with no pain, at the 1-year follow-up (Fig. 3d).

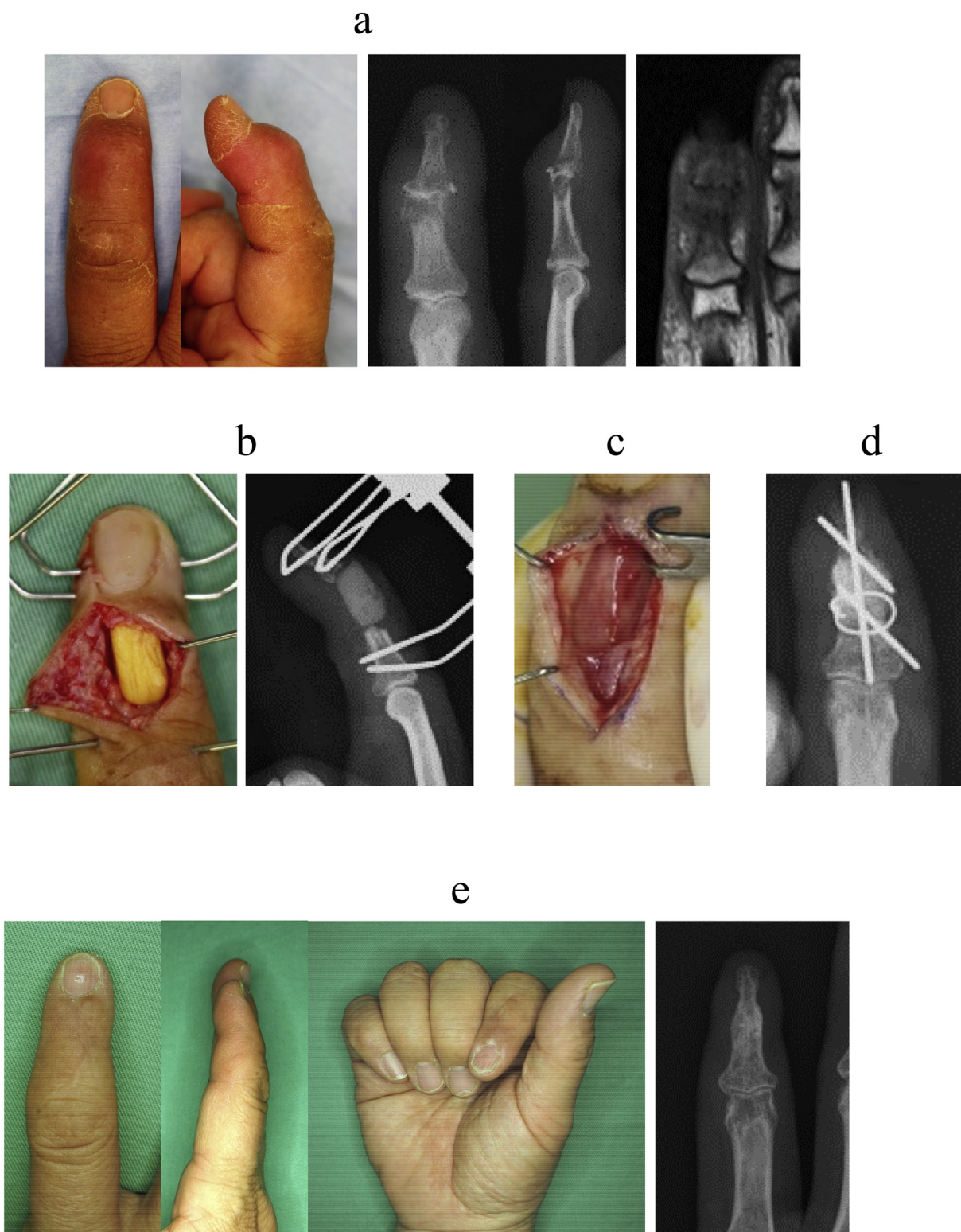


Fig. 1. (Case 1).

a Preoperative pictures, X-rays, and magnetic resonance imaging (MRI).

b Picture and X-ray after placing an external fixator and an antibiotic cement bead (the first surgical stage).

c picture after removing an antibiotic cement bead.

d X-ray after fixing the autograft using Kirschner wires and a soft wire (the second surgical stage).

e Pictures and X-ray at one year postoperatively.

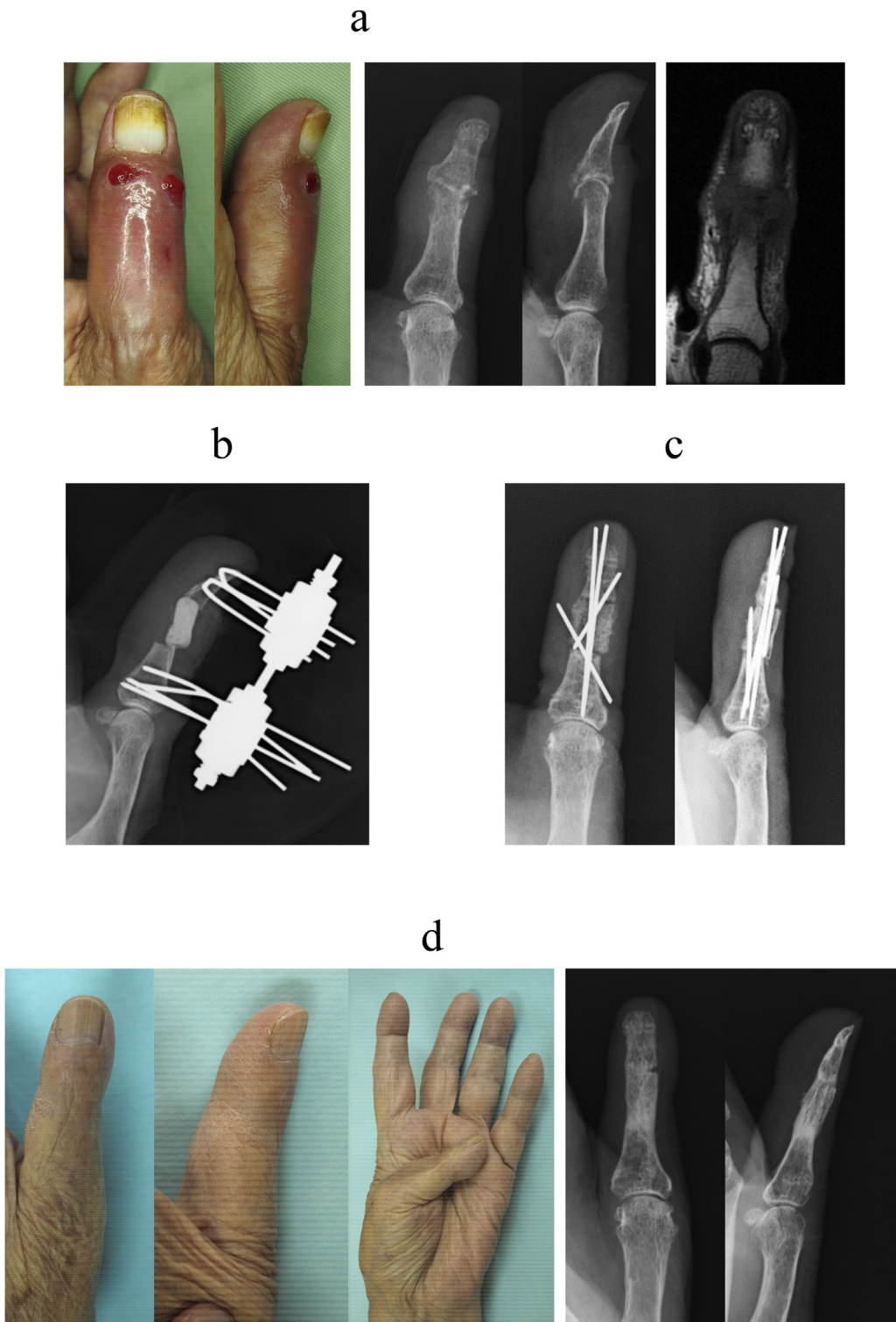
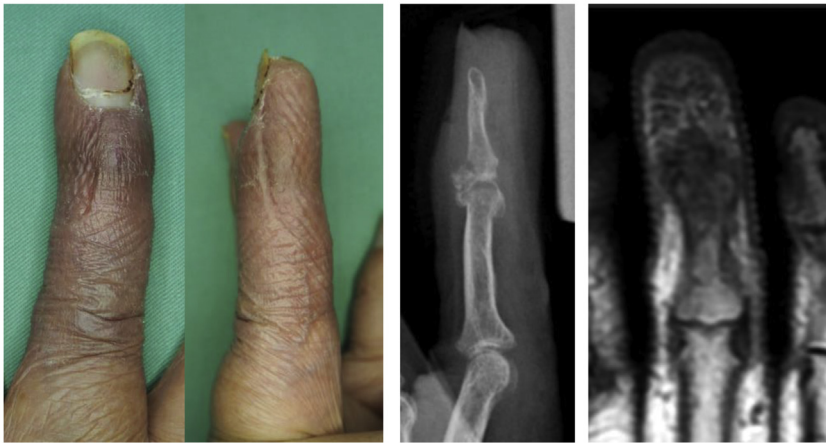
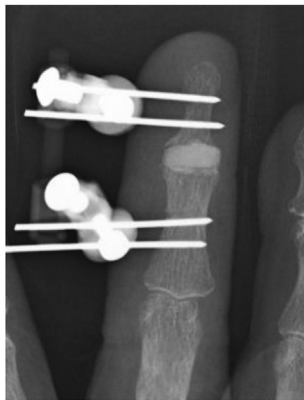

Fig. 2. (Case 2).
a Preoperative pictures, X-rays, and MRI.
b X-ray after the first surgical stage.
c X-rays after the second surgical stage.
d Pictures and X-rays at one year postoperatively.

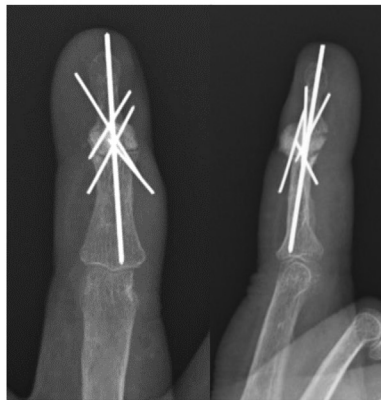
a



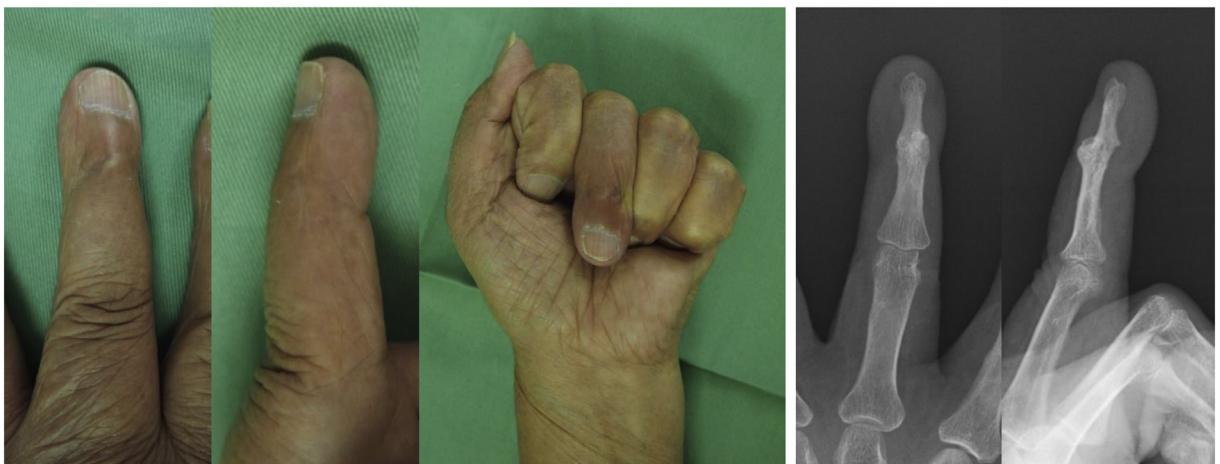b



c



d



(caption on next page)

Fig. 3. (Case 3).

- a Preoperative pictures, X-ray, and MRI.
 b X-ray after the first surgical stage.
 c X-rays after the second surgical stage.
 d Pictures and X-rays at one year postoperatively.

Discussion

In this study, we have reported good clinical and radiological outcomes of treatment using the Masquelet technique with iliac bone autograft for patients with septic arthritis in small joints of the hand. No complications such as non-union, recurrence of infection, or residual pain were observed.

Some methods for treatment of bone loss in the upper and lower extremity include bone grafting using the Masquelet technique, nonvascularized autograft, vascularized autograft, allograft, and distraction osteogenesis. Several studies have revealed good clinical and radiological outcomes for treatment of bone defects in the upper and lower extremities with the Masquelet technique [3,6]. For reconstruction after septic arthritis, the use of a nonvascularized autograft in a one-stage surgery without the Masquelet technique has risks of recurrent infection and bone graft absorption. Vascularized autograft is one of the recommended methods for reconstruction after infection [7]; however, this technique requires microsurgery skills.

The use of the Masquelet technique for septic arthritis in DIP joints has several advantages. First, the resolution of infection can be confirmed before the second surgery, therefore, reducing the risk of bone graft absorption. The induced membrane can prevent bone graft resorption by providing it with growth factors and through vascularization and inhibition of soft-tissue interposition [8]. The membrane functions as a barrier that prevents the outward diffusion of growth and osteoinductive factors. The patients in this report had untreated diabetes or RA, which are known risk factors for the development of septic arthritis [9]. Moreover, patients with diabetes or RA also have a higher risk of failure of surgical debridement for septic arthritis [10]. Even in such patients with a high risk of infection, we were able to successfully treat the septic arthritis and achieve bone union without recurrence of infection.

Second, we were able to preserve the finger length by placing a cement spacer in the site of infection till the infection had resolved and then a bone graft. Finger length is important for performing specific functional tasks such as typing [11]. Moreover, because the hand is a visible body part, several patients not only desire a functional hand but also anticipate an appearance that is as normal as possible [12], thus indicating the importance of finger length in obtaining a normal appearance [13]. For these reasons, the Masquelet technique is the effective method for the treatment of septic arthritis in DIP joints.

This report demonstrated that the Masquelet technique provides reliable outcomes for septic arthritis in DIP joints as well as for long bone osteomyelitis. The patients in this study demonstrated clinical healing and bone union. Although this technique entails two surgeries, it can lead to favorable clinical and radiological outcomes for infected small joints of the hand.

Declaration of competing interest

The authors declare that there is no conflict of interest regarding the publication of this article.

Acknowledgments

The authors would like to thank Enago (www.enago.jp) for the English language review.

References

- [1] S. Kamekura, S. Tsuge, H. Takamura, Y. Morizaki, K. Tanaka, T. Ohe, Small joint arthrodesis for the treatment of hand infection with external fixation using methylmethacrylate: a report of four cases, *Jpn. J. Trauma Emerg. Med.* 2 (2011) 53–57.
- [2] R.M. Braun, C.E. Rhoades, Dynamic compression for small bone arthrodesis, *J. Hand Surg.* 10 (1985) 340–343.
- [3] C. Mauffrey, M.E. Hake, V. Chadayammuri, A.C. Masquelet, Reconstruction of long bone infections using the induced membrane technique: tips and tricks, *J. Orthop. Trauma* 30 (2016) e188–e193.
- [4] A.M. Boustred, M. Singer, D.A. Hudson, G.E. Bolitho, Septic arthritis of the metacarpophalangeal and interphalangeal joints of the hand, *Ann. Plast. Surg.* 42 (1999) 623–628 (discussion 8–9).
- [5] M. Sinha, S. Jain, D.A. Woods, Septic arthritis of the small joints of the hand, *J. Hand Surg. (Br.)* 31 (2006) 665–672.
- [6] J. Muhlhauser, J. Winkler, R. Babst, F.J.P. Beerers, Infected tibia defect fractures treated with the Masquelet technique, *Medicine (Baltimore)* 96 (2017) e6948.
- [7] I. Grant, A.C. Berger, D.C. Ireland, A vascularised bone graft from the medial femoral condyle for recurrent failed arthrodesis of the distal interphalangeal joint, *Br. J. Plast. Surg.* 58 (2005) 1011–1013.
- [8] P.V. Giannoudis, O. Faour, T. Goff, N. Kanakaris, R. Dimitriou, Masquelet technique for the treatment of bone defects: tips-tricks and future directions, *Injury* 42 (2011) 591–598.
- [9] C.J. Kaandorp, D. Van Schaardenburg, P. Krijnen, J.D. Habbema, M.A. van de Laar, Risk factors for septic arthritis in patients with joint disease. A prospective study, *Arthritis Rheum.* 38 (1995) 1819–1825.
- [10] J.G. Hunter, J.M. Gross, J.D. Dahl, S.L. Amsdell, J.T. Gorczyca, Risk factors for failure of a single surgical debridement in adults with acute septic arthritis, *J. Bone Joint Surg. Am.* 97 (2015) 558–564.
- [11] A. Salibi, C. McArdle, A.N. Morrish, Pedicled distal phalanx fillet flap for finger length preservation in trauma, *J. Plast. Reconstr. Aesthet. Surg.* 69 (2016) 568–570.
- [12] P.R. Manske, *Aesthetic hand surgery*, *J. Hand Surg.* 27 (2002) 383–384.
- [13] R.G. Jakubietz, M.G. Jakubietz, D. Kloss, J.G. Gruenert, Defining the basic aesthetics of the hand, *Aesthet. Plast. Surg.* 29 (2005) 546–551.