



Original Article

Device implantation for patients on antiplatelets and anticoagulants: Use of suction drain

Sanjeev S. Mukherjee, Daljeet Saggu, Sridevi Chennapragada, Sachin Yalagudri, Sandeep G. Nair, CalamburNarasimhan*

Department of Cardiology, CARE Hospital, Banjara Hills, Hyderabad, India

ARTICLE INFO

Article history:

Received 23 November 2017

Accepted 31 December 2017

Available online 2 January 2018

Keywords:

Pocket hematoma
Antithrombotic treatment
Device implantation
Anticoagulation
Antiplatelets
Surgical drain

ABSTRACT

Background and objectives: Cardiovascular implantable electronic devices (CIED) are frequently implanted in patients on anti-thrombotic agents. Pocket hematomas are more likely to occur in these patients. The use of a sterile surgical drain in the pulse generator pocket site could prevent hematomas, but fear of infection precludes its use. The objective of the present study is to study the safety and efficacy of surgical drain in patients on antithrombotics undergoing CIED implantations.

Methods: This is a single-centre, retrospective study involving patients undergoing CIED implantations on antithrombotics (antiplatelets and anticoagulants) from August 2013 to July 2016. Patients with high risk of thromboembolism were continued on oral antithrombotics or were bridged with heparin after stopping oral antithrombotics. A sterile close wound suction drain was placed in device pockets following CIED implantations. Post procedure, pressure dressing was applied and removed after 12 h once the drain volume was less than 10 ml in 24 h.

Results: Sixty seven patients required surgical drain implantation. Major indications for antithrombotic use were presence of intracoronary stent, atrial fibrillation and mechanical valve replacements. The mean post-procedural hospital stay was 3 ± 0.9 days and mean overall drain was 16.6 ± 8.2 ml. At a mean follow up of 17.6 ± 8.2 months, one patient (1.4%) had pocket hematoma. There were no infections.

Conclusion: The use of a surgical drain in CIED implantation significantly reduces the risk of hematoma formation without increasing the risk of infection. Antithrombotic drugs can be safely continued at the time of implantation of cardiac devices.

© 2017 Published by Elsevier B.V. on behalf of Cardiological Society of India. This is an open access article under the CC BY-NC-ND license (<http://creativecommons.org/licenses/by-nc-nd/4.0/>).

1. Introduction

An increasing number of patients are undergoing cardiovascular implantable electronic device (CIED) procedures for various indications.^{1–3} A significant proportion of them are on antithrombotic therapy (anticoagulant, antiplatelet agents or both).^{4–6} Pocket hematoma is a well recognized complication associated with CIED procedures and its risk is significantly higher when patients are on antithrombotic therapy.^{7–10} It also increases the risk of infection in patients undergoing CIED implantations.^{11–13} Avoiding perioperative anticoagulation therapy on the other hand increases the risk of thromboembolic events, in particular, cerebral stroke.^{6,14,15} Interruption of anticoagulation therapy and bridging

with heparin has also not been found to be safe.^{16,17} Surgical drains during CIED implantation can prevent pocket hematoma and infection in patients who require continued use of antithrombotic therapy.

We evaluated the use of closed wound suction drainage system (surgical drain) in patients undergoing CIED implantations to prevent bleeding complications while on antithrombotic treatment. The aim was to evaluate the safety and efficacy of surgical drain in preventing pocket hematoma in patients who are at high risk for bleeding during CIED implantations.

2. Methods

Between August 2013 and December 2016, suction drain was used in 67 patients to prevent pocket hematoma during CIED implantations. All patients provided informed consent for the procedure. Indication for surgical drain was the use of antithrombotic treatment at the time of CIED implantation.

* Corresponding author at: Arrhythmia and Electrophysiology Services, Department of Cardiology CARE Hospital, Road No1, Banjara Hills, Hyderabad, 500 034, India.

E-mail address: calambur@hotmail.com (CalamburNarasimhan).

2.1. Data collection

In-hospital data during the time of CIED implantation was extracted from hospital medical records and follow-up data from device clinic where patients with CIED implantations report for routine follow-up. Data were tracked from baseline at implantation until last follow-up at the time of data acquisition.

2.2. Study outcomes

The incidence of pocket hematoma, other bleeding complications and the incidence of infection post procedure until last follow up.

3. Definitions

3.1. Pocket hematoma

Pocket hematomas were diagnosed by cardiologists according to standardized definitions. A hematoma was assumed to be present if there was any palpable swelling of the pacemaker pocket exceeding the size of the generator. In case of doubt, the presence of a hematoma was sonographically confirmed. Hematoma related pain, prolonged hospitalization (i.e., one day more than the scheduled hospital discharge), or the necessity for reoperation were recorded.

3.2. Infection

Refers to pocket infection,¹⁸ endocarditis¹⁹ (either valve or lead) or blood stream infection.

4. Peri-procedural management of antithrombotic drugs

Patients were either continued on oral anticoagulation or were bridged with heparin after stopping oral anticoagulants 3–4 days prior to the procedure. Device implantation was performed when the INR was within 2–3. We abandoned our practice of bridging with heparin in patients after the publication of BRIDGE trial results.²⁰

5. Device implantation and drain fixation

Implantations were performed according to our Institution's standard, which remained largely unchanged during the study period. Briefly, an infraclavicular incision was made and subfascial pocket was created under local anesthesia. Venous access was achieved by a separate extra-thoracic subclavian vein puncture. Electrocautery was used in all patients for making device pocket and pacemaker generators were routinely placed over pre-pectoral fascia. Prophylactic antibiotic treatment was given one hour prior the procedure with a bolus of one gram intravenous cephalosporin or intravenous clindamycin 600 mg bolus (for patients with allergy to penicillin). All implantations were performed by experienced operators.

Post procedure, a sterile, 50 ml capacity closed wound suction drain of size FG-08 (Mini Vac Set[®], Romsons Scientific & Surgical Industries Pvt. Ltd., Agra, India) was placed in all patients. The drain set comprises of two units: needle with extension tube and suction drain (Fig. 1). The drain was placed in the most dependent area of the device pocket using the sharp needle assembly. The distal part of connecting tube was clamped just proximal to needle hub which was then cut. The suction drain was de-aired and connected to distal plastic tube and the drain was released. The tube was fixed to skin by stay sutures. Oral antithrombotics, if withheld were restarted on the same day of the procedure. Post procedure, pressure dressing was applied in all patients for 12 h. The drain was removed when output was less than 10 ml over 24 h.

6. Discharge and follow-up

The patients were discharged from hospital when output from the drain was less than 10 ml. The pacemaker implantation site was checked in the device clinic at 3, 10, 30 days after discharge from the hospital. Further follow-up visits were scheduled every three months for one year and every six months thereafter. If patients did not report to device clinic for more than six months, they were contacted telephonically. If they did not report device clinic for more than six months and also do not respond to telephonic review, then they were considered lost to follow up.

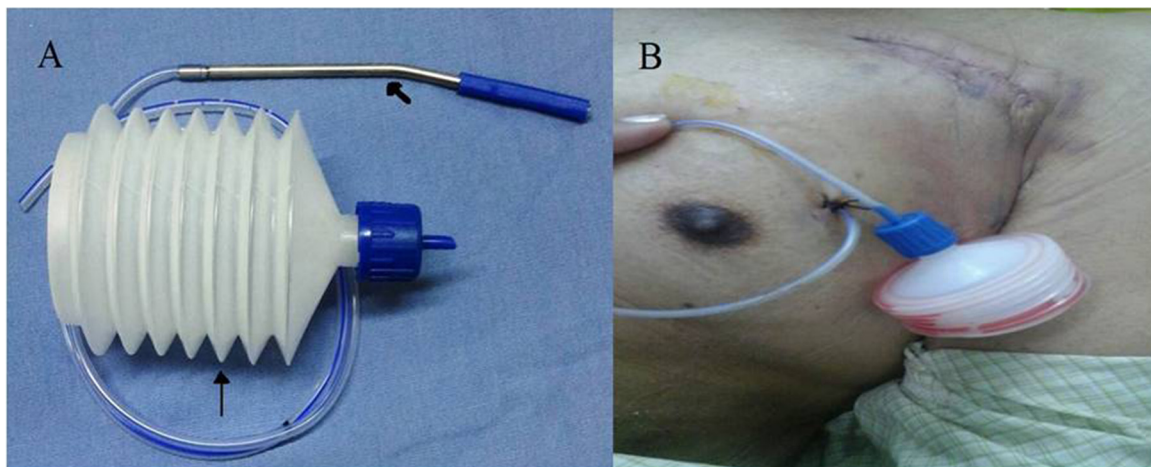


Fig. 1. Close Wound Suction Unit.

Panel A: The short arrow points to the needle with extension tube and long arrow points to the suction drain. Panel B: Shows the suction unit in situ in the pacemaker pocket of a patient who had undergone device implantation.

7. Statistical analysis

Descriptive statistics were used for patient baseline characteristics. Continuous variables are reported as mean \pm standard deviation and categorical variables as proportion with percentages.

8. Results

Seven hundred and fifty three patients underwent CIED implantations between August 2013 and December 2016 of which 67 (9%) required continued antithrombotic therapy during the peri-procedural period. Compelling indications for antithrombotic use was- recent revascularization for coronary artery disease (CAD) with coronary angioplasty and stenting/CABG in 22 patients (32%) followed by atrial fibrillation in 19 patients (28%). The other major indication was mechanical valve replacement in 11 patients (16%). The remaining patients included were- stroke in 6 (9%) patients, CAD without revascularization in 3(4%), recent bioprosthetic valve replacement in one (1%) and others (5 patients, 7%) **Table 1**. The majority were on anticoagulation (40%) or dual anti-platelets (30%). In 13 (19%) of patients, the procedure was done by withholding oral antithrombotics and bridging with heparin. The complete break up of indications and type of antithrombotic use is given in **Table 1**.

Thirty two patients (48%) underwent pacemaker implantation, 17 patients (25%) implantable cardioverter defibrillator (ICD) implantation, 15 (22%) underwent cardiac resynchronization therapy with ICD (CRT-D) and three (4%) underwent CRT implantation without ICD.

8.1. In-hospital stay

The mean post-procedure hospital stay was 3 ± 0.9 days ranging from 2 to 5 days. *Volume of drain*: The mean overall drain collected was 16.6 ± 8.2 ml. There was no bleeding beyond 48 h (second post-procedural day) in 38 (57%) patients and beyond the fourth day in two patients. At the end of first post implantation day, the average drain collected was 21.5 ± 9.3 ml, ranging from 3 ml to 64 ml. At the end of day 2, it was 16.3 ± 6.9 (range 3 ml to 40 ml) and day 3, it was $9.9 \pm (2.8)$ ml, range: 5 ml to 34 ml. One patient had a pocket hematoma in-hospital, which was managed conservatively. This patient was on dual antiplatelets for CAD. He had persistent, severe, unexplained thrombocytopenia which resulted in bleeding.

8.1.1. Follow up

At a mean follow up of 17.6 ± 8.2 months, there were no further hematomas. There were no infections. There were five deaths and no patients were lost to follow up.

Table 1

Indication and type of antithrombotics.

	Variables	Frequency (%)
Indications	S/P PTCA/CABG	22 (32%)
	CAD without revascularization	3 (4%)
	S/P valve replacement with mechanical valve	11(16%)
	S/P valve replacement with bioprosthetic valve	1 (1%)
	AF (variable cause)	19 (28%)
	CVA	6 (9%)
	Others ^a	5 (7%)
Antithrombotic drugs used	Anticoagulant only	27 (40%)
	Antiplatelet only	3 (4%)
	Antiplatelet + anticoagulant	17 (25%)
	Dual antiplatelets	20 (30%)

S/P: Status Post; PTCA: Percutaneous Transluminal Coronary Angioplasty; CABG: Coronary Artery Bypass Grafting; CAD: Coronary Artery Disease; AF: Atrial Fibrillation; CVA: Cerebrovascular Accident.

^a Other causes include atrial flutter in two patients, left ventricular clot in two patients, and arterial thrombosis in one patient.

9. Discussion

The major finding of the study is that, closed wound drainage unit during CIED implantations reduces the incidence of pocket hematoma without increasing the risk of infection in patients who are at increased risk of bleeding.

9.1. Bleeding complications with continuation of antithrombotic therapy

The need for antithrombotic therapy is increasing in a large number of patients undergoing CIED implantations. The procedure increases the risk of bleeding complications, especially pocket hematoma.^{21–23} Previous studies have reported high incidence of pocket hematoma with both continuation of anticoagulation and bridging with heparin. With warfarin continuation, the incidence ranged between 0% to 7.7%^{6,9,20,24–28} and with heparin bridging, it ranged from 5% to as high as 23.7%.^{9,20,24–28} Dual antiplatelet therapy is found to be an independent predictor of pocket hematoma in patients undergoing pacemaker implantations. In a recent study by Dai et al¹⁰ the incidence of pocket hematoma in this group was found to be 19.3%. In our study, the incidence in this group of 20 patients was 5%-in the only patient who developed hematoma. In this patient, the development of hematoma despite the suction drain is likely due to the underlying thrombocytopenia.

With relation to overall bleeding complications, a meta-analysis of 13 studies by Bernard et al²² found the incidence rate to be 2.8 for patients on anticoagulants, 3.9% for patients on single and 9.4% for dual antiplatelets and 14.6% in whom heparin bridging was used. With the use of the closed wound suction drain, we did not observe any bleeding complications except for the hematoma in one patient (1.4%).

9.2. Risk of infection

Infection is a devastating complication associated with CIED implantations. Several factors contribute to infections^{11,12,29} among which hematoma is considered an important factor. Hematoma is the only independent predictor and is associated with a > 7- fold increased risk of infection.¹ In about 1–2% of implant cases, re-explorations are needed to evacuate hematoma or arrest bleeders which in turn increases the risk of infection.² It is also known that empirical use of antibiotics do not prevent infection in the presence of hematoma due to poor penetration into extravascular space of pocket.¹ Thus modes to reduce blood collection is of paramount importance.

The present study emphasizes that surgical drain reduces hematoma incidence and has no associated long term increased risk of infection. The mean hospital stay was more than the usual

stay duration for patients without suction drains in our hospital. This implies increase in hospitalization costs but, this increase is offset by reduction in hematoma and subsequent infection which may significantly lengthen the hospital stay. With device implant rates and the indications of antithrombotics on the rise, this technique has the potential to benefit significant proportion of people undergoing CIEDs.

9.3. Study limitation

This is a retrospective collection of data in a small cohort of patients, which may be associated with selection bias. We considered device infection only when patient required hospitalization, which might overlook any outpatient treatment if received. But this was necessary as an objective and clinically meaningful end point. Decisions to re-intervene were not well defined. We had very few patients on novel anticoagulants and none on prasugrel/ticagrelor which are common in current practice. The procedures were done by experienced operators of a high volume centre and so results cannot be generalized.

10. Conclusion

Use of a surgical drain reduces the occurrence of pocket hematoma and subsequent infection in patients with high risk of bleeding undergoing cardiac device implantations.

Author contribution

Sanjeev S Mukherjee was involved in the design of the study, data analysis and interpretation, drafting article, critical revision of article and approval of the article.

Daljeet Saggi was involved in critical revision of article and approval of article.

Sridevi Chennapragada was involved in the concept of the study, critical revision and approval of the article.

Sachin Yalagudri was involved in critical revision and approval of the article.

Sandeep G. Nair was involved in critical revision and approval of article.

Calambur Narasimhan was involved in the concept of the study, drafting the article, critical revision and approval of article.

These high risk patients may be able to continue antiplatelet/anticoagulant therapy during implant of cardiac devices.

Financial assistance

None.

Conflict of interest

None to declare.

Acknowledgements

The authors acknowledge Ms. Nalla Swapna and Mr. David Sampathkumar, Physician Assistants for data retrieval and patient interviews and Mr. C. Ranjith for his assistance in data entry.

References

- Mond HG, Proclemer A. The 11th world survey of cardiac pacing and arrhythmia's project. *Pacing Clin Electrophysiol*. 2011;34(8):1013–1027.10.1111/j.1540-8159.2011.03150.x.
- Ector H, P.V. Current use of pacemakers, implantable cardioverter defibrillators, and resynchronization devices: data from the registry of the European Heart Rhythm Association. *Eur Hear J Suppl*. 2007;9:144–149.
- Shenthar J, Bohra S, Jetley V, et al. A survey of cardiac implantable electronic device implantation in India: by Indian Society of Electrocardiology and Indian Heart Rhythm Society. *Indian Heart J*. 2016;68(1):68–71.10.1016/j.ihj.2015.06.037.
- Bardy GH, Lee KL, Mark DB, et al. Amiodarone or an implantable cardioverter-defibrillator for congestive heart failure. *N Engl J Med*. 2005;352(3):225–237.10.1056/NEJMoa043399.
- Greenston Arnold J, Hart Robert G, Dawson David, et al. Predictors of stroke in patients paced for sick sinus syndrome. *J Am Coll Cardiol*. 2004;43(9):1617–1622.10.1016/j.jacc.2003.09.067.
- Tischenko A, Gula LJ, Yee R, Klein GJ, Skanes AC, Krahn AD. Implantation of cardiac rhythm devices without interruption of oral anticoagulation compared with perioperative bridging with low-molecular weight heparin. *Am Heart J*. 2009;158(2):252–256.10.1016/j.ahj.2009.06.005.
- Sridhar ARM, Yarlalagadda V, Kanmanthareddy A, et al. Incidence, predictors and outcomes of hematoma after ICD implantation: an analysis of a nationwide database of 85,276 patients. *Indian Pacing Electrophysiol J*. 2016;16(5):159–164.10.1016/j.ipej.2016.10.005.
- Yalcin M, Isilak Z, Bicakci B, Uz O. Risk factors of pocket hematoma in patients with electrophysiological device implantation. *Eur Rev Med Pharmacol Sci*. 2015;19(17):3135–3136 <http://www.ncbi.nlm.nih.gov/pubmed/26400510>. Accessed February 6, 2017.
- Proietti R, Porto I, Levi M, et al. Risk of pocket hematoma in patients on chronic anticoagulation with warfarin undergoing electrophysiological device implantation: a comparison of different peri-operative management strategies. *Eur Rev Med Pharmacol Sci*. 2015;19(8):1461–1479 <http://www.ncbi.nlm.nih.gov/pubmed/25967723>. Accessed February 6, 2017.
- Dai Y, Chen K-P, Hua W, Zhang J-T, Zhang S. Dual antiplatelet therapy increases pocket hematoma complications in Chinese patients with pacemaker implantation. *J Geriatr Cardiol*. 2015;12(4):383–387.10.11909/j.issn.1671-5411.2015.04.010.
- Klug D, Balde M, Pavin D, et al. Risk factors related to infections of implanted pacemakers and cardioverter-defibrillators: results of a large prospective study. *Circulation*. 2007;116(12):1349–1355.10.1161/CIRCULATIONAHA.106.678664.
- Lekkerkerker JC, van Nieuwkoop C, Trines SA, et al. Risk factors and time delay associated with cardiac device infections: leiden device registry. *Heart*. 2009;95(9):715–720.10.1136/hrt.2008.151985.
- Polyzos KA, Konstantelias AA, Falagas ME. Risk factors for cardiac implantable electronic device infection: a systematic review and meta-analysis. *Europace*. 2015;17(5):767–777.10.1093/europace/euv053.
- Healey Jeff S, Eikelboom John, Douketis James, et al. Perioperative bleeding and thromboembolic events with dabigatran compared with warfarin clinical perspective. *Circulation*. 2012;126(3).
- Patel MR, Hellkamp AS, Lokhnygina Y, et al. Outcomes of discontinuing rivaroxaban compared with warfarin in patients with nonvalvular atrial fibrillation. *J Am Coll Cardiol*. 2013;61(6):651–658.10.1016/j.jacc.2012.09.057.
- Marquie C, De Geeter G, Klug D, et al. Post-operative use of heparin increases morbidity of pacemaker implantation. *Europace*. 2006;8(4):283–287.10.1093/europace/eul011.
- Robinson M, Healey JS, Eikelboom J, et al. Postoperative low-molecular-weight heparin bridging is associated with an increase in wound hematoma following surgery for pacemakers and implantable defibrillators. *Pacing Clin Electrophysiol*. 2009;32(3):378–382.10.1111/j.1540-8159.2008.02247.x.
- Horan TC, Andrus M, Dudeck MA. CDC/NHSN surveillance definition of health care-associated infection and criteria for specific types of infections in the acute care setting. *Am J Infect Control*. 2008;36(5):309–321.10.1016/j.ajic.2008.03.002.
- Li JS, Sexton DJ, Mick N, et al. Proposed modifications to the duke criteria for the diagnosis of infective endocarditis. *Clin Infect Dis*. 2000;30(4):633–638.10.1086/313753.
- Wight JM, Columb MO. Perioperative bridging anticoagulation for atrial fibrillation—the first randomised controlled trial. *Perioper Med*. 2016;5(1):1410.1186/s13741-016-0040-5.
- Douketis JD, Spyropoulos AC, Spencer FA, et al. Perioperative management of antithrombotic therapy. *Chest*. 2012;141(2):e326S–e350S.10.1378/chest.11-2298.
- Bernard ML, Shotwell M, Nietert PJ, Gold MR. Meta-analysis of bleeding complications associated with cardiac rhythm device implantation. *Circ Arrhythm Electrophysiol*. 2012;5(3):468–474.10.1161/CIRCEP.111.969105.
- Thal S, Moukabary T, Boyella R, et al. The relationship between warfarin, aspirin, and clopidogre. *Pacing Clin Electrophysiol*. 2010;388:10.1111/j.1540-8159.2009.02674.x.
- Amara W, Ben Youssef I, Kamel J, Ghrissi I, Faron M, Khoudja ASJ. Hemorrhagic risk of different perioperative anticoagulation protocols in patients implanted with a cardiac pacemaker or defibrillator: retrospective analysis in patients implanted in a community hospital. *Ann Cardiol Angeiol*. 2009;58(5):265–271.
- Ahmed I, Gertner E, Nelson WB, et al. Continuing warfarin therapy is superior to interrupting warfarin with or without bridging anticoagulation therapy in patients undergoing pacemaker and defibrillator implantation. *Hear Rhythm*. 2010;7(6):745–749.10.1016/j.hrthm.2010.02.018.
- Cheng M, Hua W, Chen K, et al. Perioperative anticoagulation for patients with mechanical heart valve(s) undertaking pacemaker implantation. *Europace*. 2009;11(9):1183–1187.10.1093/europace/eup212.
- Tolosana JM, Berne Mont PL, et al. Preparation for pacemaker or implantable cardiac defibrillator implants in patients with high risk of thrombo-embolic

- events: oral anticoagulation or bridging with intravenous heparin? A prospective randomized trial. *Eur Heart J*. 2009;30(15):1880–1884. doi:10.1093/eurheartj/ehp194.
28. Milic D, Perisic Z, Zivic S, et al. Prevention of pocket related complications with fibrin sealant in patients undergoing pacemaker implantation who are receiving anticoagulant treatment. *Europace*. 2005;7(4):374–379. doi:10.1016/j.eupc.2005.03.007.
29. Sohail Muhammad R, Uslan Daniel Z, Khan Akbar H, et al. Baddour risk factor analysis of permanent pacemaker infection. *Clin Infect Dis*. 2007;45(2):166–173.