

Surgical therapy of cutaneous squamous cell carcinoma: our experience

Francesco Simonacci, Nicolò Bertozzi, Michele Pio Grieco, Eugenio Grignaffini, Edoardo Raposio

Department of Medicine and Surgery, Plastic Surgery Division, University of Parma, Parma, Italy and the Cutaneous, Mininvasive, Regenerative and Plastic Surgery Unit, Parma University Hospital, Parma, Italy

Summary. *Introduction:* Cutaneous squamous cell carcinoma (cSCC) is the second most common skin cancer, with an excellent prognosis after surgical removal. However, nodal metastasis are present in about 5% of cases and the death rate is about 2%. *Presentation of case:* The aim of this study is to report our experience about the surgical treatment of cSCC at the Cutaneous, Regenerative, Mininvasive and Plastic Surgery Unit, University of Parma, Italy, between January 2014 and February 2016. We statistically analyzed the group of patients regarding the average age, gender, localization and size of the lesions. The surgical margins of the excisions are studied and we report the results obtained after a follow up of 3 to 25 months. *Discussion:* Between January 2014 and February 2016 in our Cutaneous, Regenerative, Mininvasive and Plastic Surgery Unit, we removed 36 squamous cell carcinomas, including 11 cSCCs in situ. The average annual incidence of squamous cell carcinoma in northeast of Italy is about 28,9 cases per 100,000 individuals. The number of cSCCs that we removed is lower than the Italian average. In our opinion, this is due to an increase in the early diagnosis of precancerous lesions and their medical or surgical treatment. This reduces the incidence of squamous cell carcinomas developing from precancerous lesions. *Conclusion:* The excision of cutaneous squamous cell carcinoma should be undertaken with a safety margin of at least 0.9 mm to minimize recurrence and metastasis. (www.actabiomedica.it)

Key words: squamous cell carcinoma, incidence, surgical therapy

Introduction

Cutaneous squamous cell carcinoma (cSCC) is a common skin cancer characterized by the malignant proliferation of keratinizing cells of the epidermis that usually arises from precancerous lesions but can also grow *de novo* after chronic skin damage. Approximately 80% of non-melanoma skin cancers are basal cell carcinomas, and 20% are squamous cell carcinomas (1). Squamous cell carcinoma is the second most common cancer among whites (2). Squamous cell carcinoma usually occurs in older age (around 60 years) and is more common among men than among

women. Its annual incidence varies according to the region considered, as it increases the closer you get to the equator and/or at higher altitudes. In northeast of Italy, the calculated annual incidence is approximately 28,9 cases per 100,000 individuals (3). Risk factors for developing cSCC include actinic keratoses, advanced age, cumulative exposure to sunlight and fair skin (4-6). Chronic wounds and inflammatory lesions such as cutaneous ulcers, burns and scars, or exposure to carcinogenic substances (e.g., arsenic) and radiation can trigger malignant transformation. In immunosuppressed patients, there is a much higher incidence, and the course of the disease is less favorable. This also

applies to patients with iatrogenic immunosuppression following organ transplantation as well as immunosuppression in malignant diseases such as HIV infection (7). In immunosuppressed patients, malignant transformation is triggered by an increased rate of infection with carcinogenic human papilloma virus types (7). The relative risk of squamous cell carcinoma is three times as high among people born in areas that receive high amounts of ultraviolet radiation from the sun as among people who move to those areas in adulthood; two to five times as high in those with light skin, hazel or blue eyes, and blonde or red hair as in those with darker features; five times as high among those with outdoor occupations as among those who work indoors; and three to eight times as high among people with severe solar elastosis, freckling or facial telangiectasia as among others (8,9). The principal precursor of cSCC is actinic keratosis (10-12). Actinic keratoses are scaly lesions, typically measuring 2 to 6 mm in diameter, that are more easily felt than seen; they may be the same color as the skin, or pink or brown. They can involute or persist, and affected persons usually have many lesions, some of which may evolve into squamous cell carcinoma. The transition from actinic keratosis to invasive squamous cell carcinoma is rare, and probably occurs in only up to 5% of all lesions (6, 13). Bowen disease, erythroplasia of Queyrat and keratoacanthoma are considered intraepithelial squamous cell carcinoma (cSCC in situ) that over time can change to the infiltrative form. Most invasive squamous cell carcinomas occur on the head and neck; the next most common site is the trunk (2, 6). The 5-year rate of recurrence of primary cutaneous lesions is 8%, and the 5-year rate of metastasis is 5% (14-16). Large lesions (>2 cm in diameter) recur at a rate of 15%, which is twice that of smaller lesions, and they metastasize at a rate of 30%, three times that of smaller lesions (14). Squamous cell carcinomas of the lip and ear are aggressive lesions with rates of recurrence and metastasis ranging from 10% to 25% (14). The most common clinical presentation of invasive cSCC is an actinic keratosis that becomes hyperkeratotic, or its base becomes infiltrated, or else, it becomes tender or ulcerated (17). When the tumor arises de novo or the early keratosis phase is lacking, cSCC can present as an asymptomatic small plaque

or nodule that enlarges over time. It can become crateriform ('keratoacanthoma-like'), ulcerated, necrotic or botryomycotic. Alternatively, patients may present with a flat ulcer with a raised border (17). Predilection sites of cSCC are the chronically exposed areas, face (particularly the lip, ear, nose, cheek and eyelid) and the dorsum of the hands. The head and neck region is the preferential site in males, while the upper limbs followed by the head and neck are the more common locations in females (17). The classification and staging of cSCC are based on the most recent TNM system of the International Union Against Cancer, 2009 and the American Joint Committee on Cancer 2010 (Table 1) (18, 19). The T1 category is used to define 'low-risk' tumors based on a horizontal tumor size of <2 cm. T2 is used for 'high-risk' tumors based on a diameter of >2 cm. The first-line treatment for cSCC is complete surgical excision with histopathological control of excision margins (Table 2) (17, 19).

Prospective studies have shown that a 4-mm margin is sufficient to remove 95% of clinically well-defined low-risk tumors measuring less than 2 cm in diameter (20). Larger tumors require larger excision margins since they are more likely to have greater clinically undetectable microscopic tumor extension. For cSCCs measuring more than 2 cm in diameter or more than 6 mm in thickness and for tumors associated with other high-risk prognostic characteristics (moderate or poor differentiation, recurrent tumor, perineural invasion, extension deep into the subcutaneous layer and/or location on the ear or lip), a margin of at least 6 mm is considered necessary to obtain the same result (7). However, an extended margin of 10 mm is considered to be safer for these tumors. Patients with potentially aggressive local tumors may be considered as candidates for prophylactic irradiation of the regional lymph nodes after surgery (21). The treatment that offers the highest rates of cure for patients with high-risk primary or recurrent squamous cell carcinoma is Mohs micrographic surgery (1, 20, 22-25).

Materials and methods

This work is a retrospective study of 36 patients with cSCC who were treated at the Cutaneous, Re-

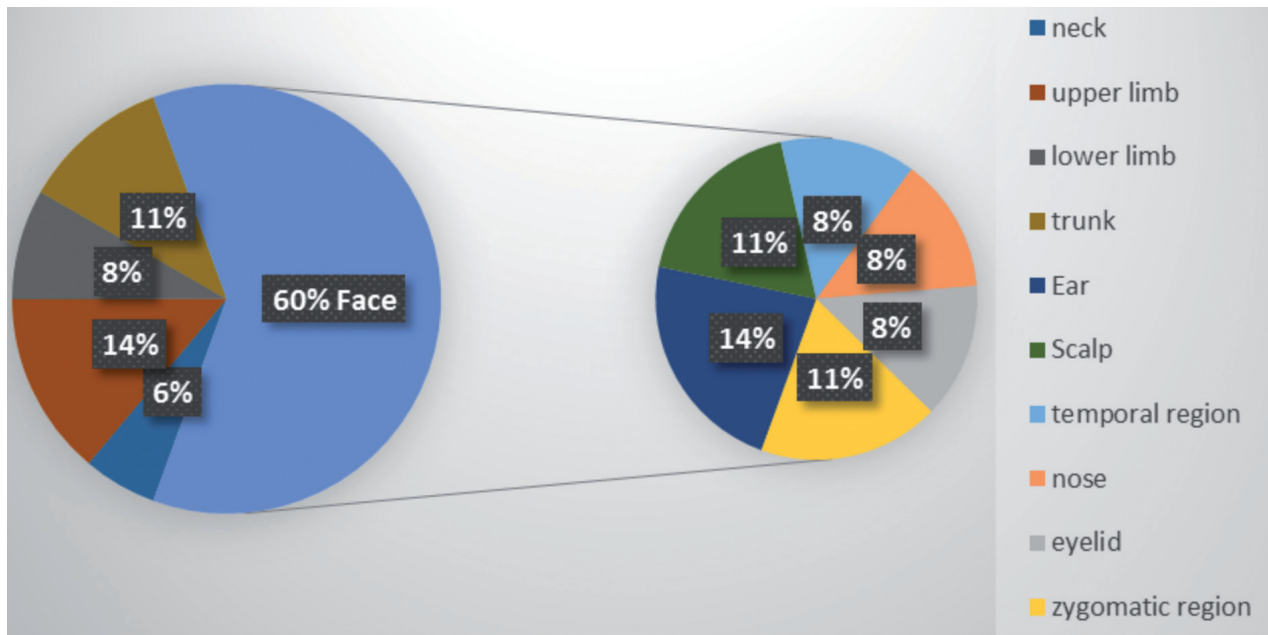


Figure 1. Percentage of different localization of cSCC in the group of patients

tients, 69.4%), local flap repair (8 patients, 22.2%) or skin grafting (3 patients, 8.3%). The average lesion size was 1.17 cm² (range: 0.15–5.75 cm²), and the mean area of surgical excision was 3.35 cm² (range: 1.04–10.16 cm²). The surgical safety margin adopted ranged from 0.6 mm to 10 mm, based on whether the lesions were considered to be low or high risk, with an average value of 0.92 mm (Figs. 2–4).

Results

Based on the histological examination of the 36 excised lesions, 11 (30.5%) were found to be cSCCs in situ, and 25 (69.5%) were found to be infiltrative cSCCs of varying grades (G1: 11 lesions, 44%; G2: 7 lesions, 28%; and G3: 7 lesions, 28%). The mean lesion thickness was 2.8 mm (range: 1–6 mm). All cSCCs were removed completely, with both the margins and the bottom of the lesions being negative at histological examination. Only 2 patients (5.55%) had a dehiscence of the surgical wound after primary suture. One patient (2.7%) developed partial necrosis of a scalp flap, and in one patient (2.7%), the dermo-epidermal skin graft did not take root. Two patients (5.55%) de-

veloped a surgical wound infection. Weekly dressing was used to treat all these postoperative complications until closure of the wound was achieved. The follow-up (range: 3–25 months) included a clinical examination at every 6 or 12 months during the next 2 years for cSCC in situ, a clinical examination at every 6 months during the next 2 years and an annual ultrasound examination for the next 3 years at T1, T2 (G2) and in addition an annual chest x-ray from T3. During the follow-up, no patient showed the presence of recurrences or metastases.

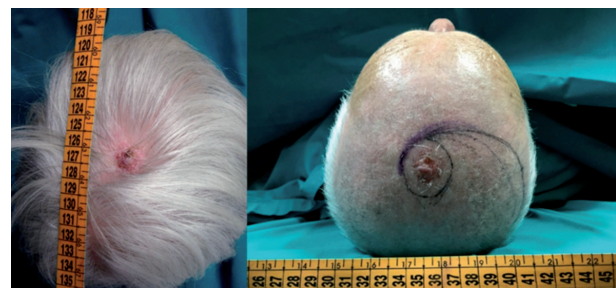

Figure 2. A 78-year-old man with a nodular cSCC (G2; thickness, 2 mm) on the scalp. We performed surgical excision under local anesthesia, with safety margins of 10 mm. The resulting defect was covered with a rotation flap

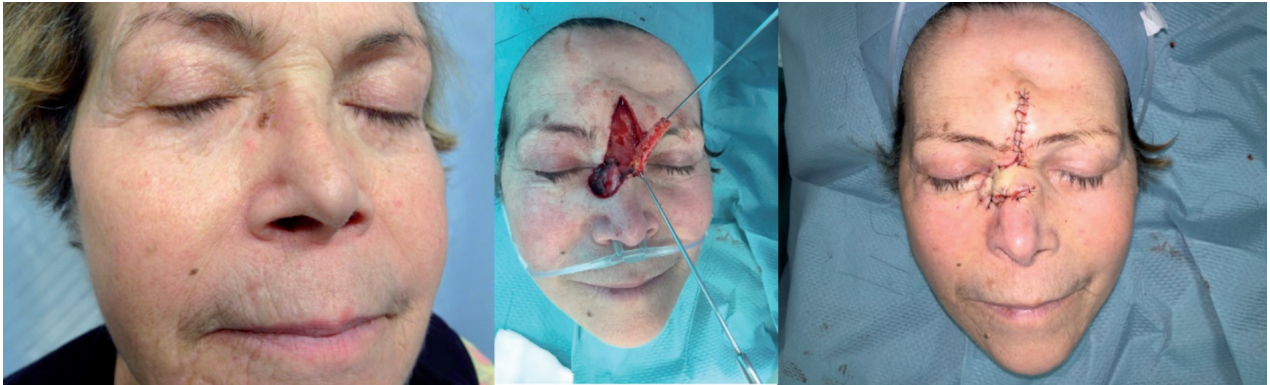

Figure 3. A 74-year-old woman with a cSCC (G1; thickness, 1 mm) at the level of the right medial canthus. After an incisional biopsy, we removed the lesion under local anesthesia with safety margins of 0.8 mm. A Marchac dorsal nasal flap was used to cover the resulting skin defect

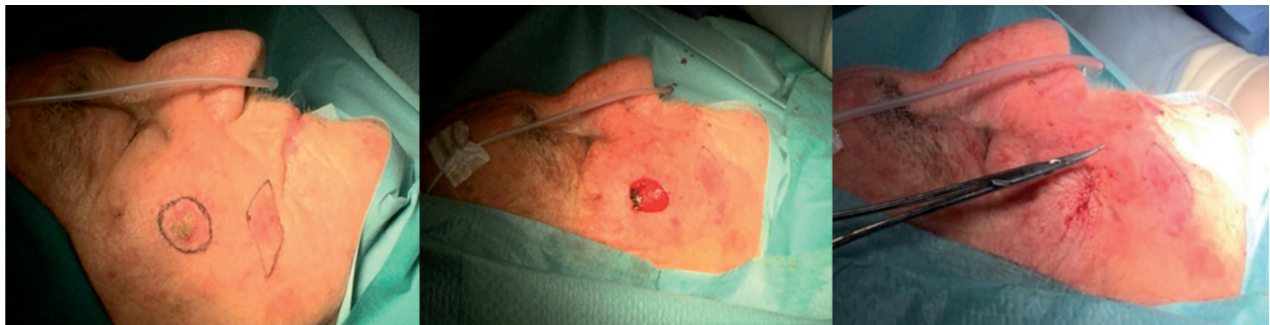

Figure 4. A 78-year-old woman with a cSCC in situ in the right zygomatic region. We excised the tumor under local anesthesia, with safety margins of 0.6 mm, and closed the wound with a round block suture

Discussion

Primary prevention through appropriate sun exposure and avoidance of carcinogens prevents the development of squamous cell carcinoma. Physicians should emphasize to their patients the prophylactic benefits of sun avoidance and protection from sunlight, beginning in childhood, to minimize the risk that this potentially life-threatening cancer will develop (26). The early diagnosis of cSCC has increased survival rates by reducing the incidence of metastases and the necessity of extensive local surgery (27, 28). Between January 2014 and February 2016 in our Cutaneous, Regenerative, Mininvasive and Plastic Surgery Unit, we removed 36 squamous cell carcinomas, including 11 cSCCs in situ. The average annual incidence of squamous cell carcinoma in northeast of Italy is about

28,9 cases per 100,000 individuals (3). The number of cSCCs that we removed is lower than the Italian average. In our opinion, this is due to an increase in the early diagnosis of precancerous lesions and their medical or surgical treatment. This reduces the incidence of squamous cell carcinomas developing from precancerous lesions. Brodland et al. (20) reported that a 4-mm safety margin is sufficient to remove 95% of clinically well-defined low-risk tumors measuring less than 2 cm in diameter, and a 6-mm safety margin is sufficient to remove cSCCs measuring more than 2 cm in diameter or more than 6 mm in thickness, or tumors that are associated with other high-risk prognostic characteristics. However, an extended margin of 10 mm is considered to be safer for these tumors (20). Our data confirm the literature; in fact, with a mean safety margin of 0.92 mm, we did not find any cases of incom-

plete excision, or recurrence or metastasis of squamous cell carcinoma during follow-up. As reported in the literature (17), we found that cSCC occurred in sun-exposed areas. In our study, 29 lesions were located on the face, neck and upper limbs, while only 7 lesions were located on the trunk or lower limbs. Most cSCCs (that is, 21 lesions, 58.3%) were located in the different aesthetic units of the face. The average age at which cSCC develops is around 70 years (29), which is consistent with the mean age of our patients (80.7 years). Furthermore, as reported in the literature (30), none of our patients was younger than 45 years (range: 46–101 years). A recent study from the Netherlands also reported a significant increase of cSCC in the European standardized rates from 22.2 to 35.4 per 100,000 male inhabitants and from 7.9 to 20.5 per 100,000 female inhabitants between 1989 and 2008 (31). Our group of patients consisted of 23 (63.8%) men and 13 (36.2%) women, yielding a male:female ratio of 1.7:1, which conforms with that reported in the literature.

Conclusion

In our experience, when possible, the excision of cSCC should be undertaken with a safety margin of at least 0.9 mm to minimize recurrence and metastasis.

“The patients in the study have given consent for the clinical study to be published”

References

1. Kwa RE, Campana K, Moy RL. Biology of cutaneous squamous cell carcinoma. *Am Acad Dermatol* 1992; 26: 1–26.
2. Johnson TM, Rowe DE, Nelson BR, Swanson NA. Squamous cell carcinoma of the skin (excluding lip and oral mucosa). *J Am Acad Dermatol* 1992; 26: 467–84.
3. Boi S, Cristofolini M, Micciolo R, Polla E, Dalla Palma P. Epidemiology of skin tumors: data from the cutaneous cancer registry in Trentino, Italy. *J Cutan Med Surg* 2003; 7: 300–5.
4. Motley R, Kersey P, Lawrence C. Multiprofessional guidelines for the management of the patient with primary cutaneous squamous cell carcinoma. *Br J Dermatol* 2002; 146: 18–25.
5. Rogers HW, Weinstock MA, Harris AR, et al. Incidence estimate of nonmelanoma skin cancer in the United States, 2006. *Arch Dermatol* 2010; 146: 283–7.
6. Glass A. The emerging epidemic of melanoma and squamous cell skin cancer. *JAMA* 1989; 262: 2097–100.
7. Breuninger H, Eigentler T, Bootz F, et al. Brief S2k guidelines–Cutaneous squamous cell carcinoma. *J Dtsch Dermatol Ges* 2013; 11: 37–45.
8. English DR, Armstrong BK, Kricger A, Winter MG, Heenan PJ, Randell PL. Demographic characteristics, pigmentary and cutaneous risk factors for squamous cell carcinoma of the skin: a case-control study. *Int J Cancer* 1998; 76: 628–34.
9. Green A, Battistutta D. Incidence and determinants of skin cancer in a high-risk Australian population. *Int J Cancer* 1990; 46: 356–61.
10. Gallagher RP, Hill GB, Bajdik CD, et al. Sunlight exposure, pigmentation factors, and risk of nonmelanocytic skin cancer. II. Squamous cell carcinoma. *Arch Dermatol* 1995; 131: 164–9.
11. Callen JP, Bickers DR, Moy RL. Actinic keratoses. *J Am Acad Dermatol* 1997; 36: 650–3.
12. Dinehart SM, Nelson-Adesokan P, Cockerell C, Russell S, Brown R. Metastatic cutaneous squamous cell carcinoma derived from actinic keratosis. *Cancer* 1997; 79: 920–3.
13. Gray DT, Su D, Clay RP, Harmsen S, Roenigk RK. Trends in population-based incidence of squamous cell carcinoma of the skin first diagnosed between 1984 and 1992. *Arch Dermatol* 1997; 133: 735–40.
14. Rowe DE, Carroll RJ, Day CL Jr. Prognostic factors for local recurrence, metastasis, and survival rates in squamous cell carcinoma of the skin, ear, and lip: implications for treatment modality selection. *J Am Acad Dermatol* 1992; 26: 976–90.
15. Czarnecki D, Staples M, Mar A, Giles G, Meehan C. Metastases from squamous cell carcinoma of the skin in southern Australia. *Dermatology* 1994; 189: 52–4.
16. Jackson A. Prevention, early detection and team management of skin cancer in primary care: contribution to the health of the nation objectives. *Br J Gen Pract* 1995; 45: 97–101.
17. Stratigos A, Garbe C, Lebbe C, et al. Diagnosis and treatment of invasive squamous cell carcinoma of the skin: European consensus-based interdisciplinary guideline. *Eur J Cancer* 2015; 51: 1989–2007.
18. Sobin LH, Gospodarowicz MK, Wittekind C. TNM classification of malignant tumors (UICC International Union Against Cancer). 7 ed. John Wiley & Sons; 2009.
19. Edge SB, Byrd DR, Compton CC, et al. AJCC cancer staging manual. 7 ed. New York, Dordrecht: Heidelberg, London, Springer; 2009.
20. Brodland DG, Zitelli JA. Surgical margins for excision of primary cutaneous squamous cell carcinoma. *J Am Acad Dermatol* 1992; 27: 241–8.
21. Guidelines of care for cutaneous squamous cell carcinoma: Committee on Guidelines of Care, Task Force on Cutaneous Squamous Cell Carcinoma. *J Am Acad Dermatol* 1993; 28: 628–31.
22. Holmkvist KA, Roenigk RK. Squamous cell carcinoma of

- the lip treated with Mohs micrographic surgery: outcome at 5 years. *J Am Acad Dermatol* 1998; 38: 960-6.
23. Lawrence N, Cotel WI. Squamous cell carcinoma of skin with perineural invasion. *J Am Acad Dermatol* 1994; 31: 30-3.
24. Fleming ID, Amonette R, Monaghan T, Fleming MD. Principles of management of basal and squamous cell carcinoma of the skin. *Cancer* 1995; 75: 699-704.
25. Robins P, Dzubow LM, Rigel DS. Squamous-cell carcinoma treated by Mohs' surgery: an experience with 414 cases in a period of 15 years. *J Dermatol Surg Oncol* 1981; 7: 800-1.
26. Alam M, Ratner D. Cutaneous squamous-cell carcinoma. *N Engl J Med* 2001; 344: 975-83.
27. Porro I, Schenone A, Fato M, Raposio E, Molinari E, Beltrame F. An integrated environment for plastic surgery support: building virtual patients, simulating interventions, and supporting intraoperative decisions. *Comput Med Imaging Graph* 2005; 29: 385-94.
28. Raposio E, Paternich W, Robello G, et al. Spectrophotometric technology for the early detection of cutaneous melanoma. *International Journal of Simulation: Systems, Science and Technology* 2007; 8: 46-54.
29. Brantsch KD, Meisner C, Schonfisch B, et al. Analysis of risk factors determining prognosis of cutaneous squamous-cell carcinoma: a prospective study. *Lancet Oncol* 2008; 9: 713-20.
30. Christenson LJ, Borrowman TA, Vachon CM, et al. Incidence of basal cell and squamous cell carcinomas in a population younger than 40 years. *JAMA* 2005; 294: 681-90.
31. Hollestein LM, de Vries E, Nijsten T. Trends of cutaneous squamous cell carcinoma in the Netherlands: increased incidence rates, but stable relative survival and mortality 1989-2008. *Eur J Cancer* 2012; 48: 2046-53.

Received: 11 February 2017

Accepted: 13 February 2017

Correspondence:

Francesco Simonacci, MD

Department of Medicine and Surgery,
Plastic Surgery Division, Cutaneous, Regenerative,
Minimally Invasive and Plastic Surgery Unit,
Parma University and Maggiore Hospital,
Via Gramsci 14 - 43126 Parma, Italy
E-mail: francescosimonacci@hotmail.it