

Comparison of anterior chamber angle changes following phakic intraocular lens with and without a central hole implantation for moderate to high myopic eyes

Tian'an Zhou, MM, Hui Jiang, MM, Yang Wang, Chen Xie, PhD, Jianhua Xia, MM, Ye Shen, MD, PhD*

Abstract

The aim of this study was to compare the anterior chamber angle changes after implantation of phakic intraocular lens with and without a central hole for moderate to high myopic eyes in Chinese people.

This study enrolled 106 eyes of 54 people with intraocular lens V4 implantation and 105 eyes of 53 people with intraocular lens V4c implantation. Postoperative vault, intraocular pressure, and anterior chamber angle changes were assessed using noncontact tonometer and ultrasound biomicroscope, respectively, at 1, 3, 6, and 12 months after the surgery.

There were no significant differences (all $P > .05$) between the 2 groups in the depth of the central vault, intraocular pressure, or the width of anterior chamber angle at any time point post-surgery. The anterior chamber angle width in degree had a baseline of 54.40 ± 10.51 in V4c group, and decreased to 27.80 ± 5.62 , 26.95 ± 5.56 , 27.32 ± 5.66 , 27.04 ± 5.47 at 1, 3, 6, and 12 months post-surgery, respectively. Mean preoperative value of 50.62 ± 11.77 decreased to 27.28 ± 6.53 , 26.82 ± 6.03 , 26.61 ± 5.80 , 26.83 ± 5.76 at 1, 3, 6, 12 months, respectively, in V4 group. It had sufficient evidence ($P < .001$) that anterior chamber angle will narrow done after surgery, but there were no statistically significant differences within groups at any time point after surgery.

The anterior chamber angle changes of the V4c group was essentially equivalent to that of conventional V4 group, although implantation of both models will lead to the decrease in anterior chamber angle width.

Abbreviations: ACA = anterior Chamber Angle, ACD = anterior chamber depth, BDVA = best corrected distance visual acuity, ICL = intraocular collamer lens, IOP = intraocular pressure, MRSE = manifest refraction sphere equivalent, OCT = optical coherence tomography, pIOL = phakic intraocular lens implantation, UBM = ultrasound biomicroscopy, UDVA = uncorrected distance visual acuity, V4 = Visian 4, V4c = Visian 4 with a central hole, WTW = White to white.

Keywords: anterior chamber angle, central vault, intraocular pressure, phakic intraocular lens

Editor: Choul Yong Park.

Tian'an Zhou and Hui Jiang contribute equally to this work.

This work was supported in part by the Natural Science Foundation of Zhejiang Province, China (code: Y13H120002) and Department of Education of Zhejiang Province, China (code: Y201226086).

The authors report no conflict of interest.

The datasets generated during and/or analyzed during the current study are available from the corresponding author on reasonable request.

Department of Ophthalmology, First Affiliated Hospital, College of Medicine, Zhejiang University, Hangzhou, Zhejiang, China.

* Correspondence: Ye Shen, Department of Ophthalmology, The First Affiliated Hospital, College of Medicine, Zhejiang University, 79 Qingchun Road, 310003 Hangzhou, China (e-mail: idrshen@zju.edu.cn).

Copyright © 2020 the Author(s). Published by Wolters Kluwer Health, Inc. This is an open access article distributed under the terms of the Creative Commons Attribution-Non Commercial License 4.0 (CCBY-NC), where it is permissible to download, share, remix, transform, and buildup the work provided it is properly cited. The work cannot be used commercially without permission from the journal.

How to cite this article: Zhou T, Jiang H, Wang Y, Xie C, Xia J, Shen Y. Comparison of anterior chamber angle changes following phakic intraocular lens with and without a central hole implantation for moderate to high myopic eyes. *Medicine* 2020;99:49(e23434).

Received: 27 April 2020 / Received in final form: 11 August 2020 / Accepted: 26 October 2020

<http://dx.doi.org/10.1097/MD.00000000000023434>

1. Introduction

Intraocular collamer lens (ICL) implantation is a way of intraocular refractive surgery, and its effectiveness and safety has been proved in many researches.^[1–3] However, complications such as anterior subcapsular (ASC) opacities and the rise of intraocular pressure (IOP) after surgery are remaining to be solved.^[1,4] Structural modification of the anterior eye segment after implantation, pigment dispersion, and pupillary block are main causes for postoperative elevation of IOP. The decrease of anterior chamber angle (ACA) width in degrees is due to ante-displacement of the iris. Vault, which has correlation with anterior chamber depth, spherical equivalent, patient age, and WTW measurement,^[5] is a factor accounting for ASC opacities.

The latest model of ICL (V4c) is designed with an artificial hole of 0.36 mm in the center of the optic, which has an influence on the aqueous humor dynamics and increases the aqueous humor perfusion of the crystalline lens,^[6] and seems to provide similar results as its predecessors for the correction of moderate to high myopia and maintenance of safe IOP levels without iridotomy.^[7,8]

Ultrasound biomicroscopy (UBM) is the most ideal method for observing ACA structures, as other optical devices are not able to penetrate the iris pigment epithelium, thus the structures behind the iris could not be evaluated.^[9–11] In this study, we use UBM to compare the ACA changes after implantation of a posterior

chamber phakic intraocular lens (pIOL) with and without a central artificial hole and evaluate the correlation between postoperative IOP, central vault and ACA width for moderate to high myopia in Chinese eyes.

2. Patients and methods

This retrospective study included 105 eyes of 53 patients implanted with the Visian ICL V4c model and 106 eyes of 54 patients implanted with the Visian ICL V4 model. ICL implantation procedure was performed at the Department of Ophthalmology, First Affiliated Hospital, College of Medicine, Zhejiang University, China, from January 2013 to January 2016 by a same surgeon. The ethical committee of the First Affiliated Hospital approved this study and all patients were fully informed with the details of the procedure and possible complications after surgery. A written informed consent was obtained from each patient. The including criteria were stable refraction for at least 12 months, a clear central cornea, and age between 20 and 45 years. The exclusion criteria included endothelial cell density less than 2000 cell/mm², anterior chamber depth less than 2.8 mm, cataract, previous refractive surgery, keratoconus, glaucoma or pigmentary dispersion, history of iritis or uveitis, retinal detachment, and monocular vision.

2.1. Preoperative examination

Preoperative ophthalmologic examinations included uncorrected distance visual acuity (UDVA), corrected distance visual acuity (CDVA), manifest and cycloplegic refractions, slit lamp microscopy (Haag-streit BM900, Koeniz, Switzerland), funduscopy (Volk Optical Inc., Mentor, OH, USA), pachymetry (Tomey, Aichi-ken, Japan), keratometry (Canon, Tokyo, Japan), corneal topography (Atlas, Dublin, California, USA), the horizontal white-to-white distance (Orbican II, Bausch & Lomb, New York, New York, USA), and A-scan ultrasonography (Aviso, Quantel Medical, France). IOP was evaluated by tonometry (Tomey, Aichi-ken, Japan), and ACA was observed by UBM (Tianjin Suowei Electronic Technology Co Ltd, Tianjin, China).

2.2. Intraocular lens

ICL power calculation was performed using a modified vertex formula according to the manufacturer and targeted refraction

was emmetropia in all cases. The diameter of the ICL was determined based on the horizontal WTW distance and ACD measured using scanning-slit corneal topography following the manufacturer's recommendations.

2.3. Surgical technique

Preoperative peripheral neodymium-YAG laser iridectomy was performed for patients in the ICL V4 group in order to prevent postoperative pupillary block and IOP elevation. All patients were given dilating and cycloplegia agents on the day of surgery and received peribulbar anesthesia before implantation procedures. After introduction of viscoelastic substance (Provisc; Alcon Laboratories, Inc), the pIOL was inserted through a 3.0 mm clear corneal incision with the use of an injector cartridge (STAAR Surgical Co). Centration was ensured before the injection of pupillary constriction agents. Viscoelastic substance then was removed with irrigation and aspiration. All the surgical procedures were performed by a same surgeon (Y.S.). After surgery, tobramycin-dexamethasone and levofloxacin medications were prescribed topically 4 times daily for 7 days, the dose being reduced gradually thereafter.

2.4. Outcome assessment

Postoperative follow ups were scheduled at 1 day, 1 week, and 1, 3, 6, 12 months, and this study mainly analysis data from 1 month to 12 months after surgery. The evaluations included slit-lamp microscopy, funduscopy, intraocular pressure, uncorrected distance visual acuity, and manifest refraction. Central vault, the central distance from implantable contact lens to crystalline lens, was obtained from each examination with the calipers provided by the manufacturer, which was in line with study by Cao et al.^[10] The ACA width was measured through ultrasound biomicroscope by the same examiner (Y.W.) using the SW-3200L full-scale 50 MHz digital system (Tianjin Suowei Electronic Technology Co Ltd), as shown in Figure 1.

2.5. Statistical analysis

Statistical analysis was performed using SPSS software (version 19; SPSS, Inc). Descriptive statistics were obtained. The difference between the 2 groups' outcomes was estimated by the independent samples *t* test, and in those cases with data that

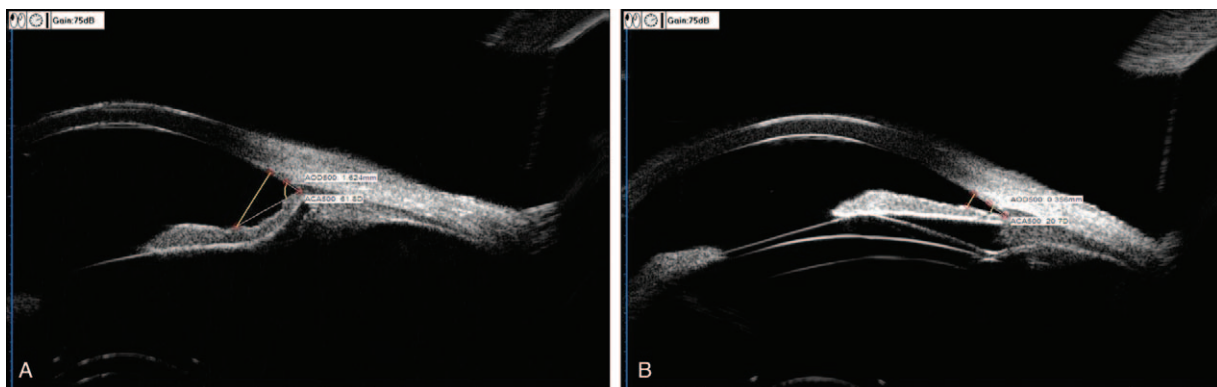


Figure 1. Measurement of the anterior chamber angle width, before (A) and after (B) pIOL implantation.

were not normally distributed, the Mann–Whitney *U* test was performed. Pearson correlation analysis was performed for normally distributed data; spearman correlation was performed for abnormally distributed data. Unless otherwise indicated, the results are expressed as mean ± SD, and differences with a *P* value less than .05 were considered statistically significant.

3. Results

This study enrolled 105 eyes of 53 patients implanted with the Visian ICL V4c model and 106 eyes of 54 patients implanted with the Visian ICL V4 model. We found no significant differences in terms of patient age, manifest spherical, manifest cylinder, or CDVA as shown in Table 1. There were no perioperative complications, and no eye required pIOL explantation or repositioning. No pigmentary glaucoma, pupillary block, cataract, or other vision-threatening complications occurred during the follow-up.

3.1. Refractive and visual outcomes

There was a statistically significant improvement between the preoperative and 12 months postoperative CDVA for the ICL V4c group (*P* < .001) and ICL V4 group (*P* < .001). No eye lost 1 line or more in either group. Both groups separately showed significant differences in manifest refractive spherical equivalent preoperatively 12 months postoperatively (ICL V4c group, *P* < .001; ICL V4 group, *P* < .001). There were no significant differences between groups in terms of UDVA, manifest refractive spherical equivalent, 12 months postoperatively (Table 2).

3.2. IOP

In ICL V4c group, the mean baseline IOP of 14.84 ± 2.08 mm Hg showed no statistically significant (*P* > .05) increase in IOP at 1 month postoperatively, and IOP remained nearly unchanged at 3, 6, 12 months postoperation, with a mean value of 15.00 ± 2.03, 14.95 ± 1.81, 15.12 ± 2.05, and 15.27 ± 2.22 mm Hg, respectively. There were also no statistically significant changes of IOP in the V4 group with a mean baseline of 15.19 ± 2.26 mm Hg, and mean value of 15.46 ± 2.36, 15.19 ± 2.20, 15.36 ± 2.14, 15.53 ± 2.34 mm Hg respectively for 1, 3, 6, and 12 months postopera-

Table 1
Preoperative patient demographic data in eyes undergoing implantation of implantable collamer lens with (ICL V4c) and without central artificial hole (ICL V4).

Parameter	ICL V4c	ICL V4	<i>P</i>
Patients			
Number of eyes	105	106	
Age, y	30.76 ± 7.35	29.25 ± 8.15	.315
Manifest refraction (D)			
Sphere	-15.53 ± 4.15	-15.47 ± 4.26	.909
Cylinder	1.26 ± 0.92	1.18 ± 1.22	.568
CDVA	0.79 ± 0.21	0.86 ± 0.21	.026
WTW distance, mm	11.48 ± 0.36	11.48 ± 0.32	.894
Length of ICL, mm	12.73 ± 0.38	12.19 ± 0.38	.000
IOP, mm Hg	14.84 ± 2.08	15.19 ± 2.26	.237
ACA width, °	54.40 ± 10.51	50.62 ± 11.77	.089

ACA = anterior chamber angle, D = diopter, ICL = implantable collamer lens, IOP = intraocular pressure, WTW = white to white.

Table 2
Twelve months postoperative clinical outcomes in eyes undergoing implantation of implantable collamer lens with (ICL V4c) and without central artificial hole (ICL V4).

Parameter	ICL V4c	ICL V4	<i>P</i>
Manifest refraction (D)			
Sphere equivalence	-.13 ± .63	-.19 ± .60	.524
Cylinder	.76 ± .66	.92 ± .73	.094
UDVA	.93 ± .16	.88 ± .20	.065

D = diopter, MRSE = manifest refraction sphere equivalent, UDVA = uncorrected distance visual acuity.

tively. There was no significant difference between the 2 groups at any time point (all *P* > .05) (Fig. 2).

3.3. Central vault

Postoperative central vault depths were 545 ± 173, 524 ± 167, 506 ± 161, 507 ± 170 μm at 1, 3, 6, and 12 months respectively in ICL V4c group, and 538 ± 185, 523 ± 190, 507 ± 185, 498 ± 173 μm, respectively, in ICL V4 group. There was no statistically significant within each group, but there was a tendency for the central vault to decrease, especially within 6 months postoperatively, then the vault depth tended to become stable. The differences in the central vault between the 2 groups were not statistically significant at any time point after surgery (all *P* > .05) (Fig. 3).

3.4. ACA500

ACA500 was the mean value of four measurements obtained along the major axis on which each pIOL haptic footplate was located. UBM measured ACA width in degree showed a statistically significant decrease at 1 month (*P* < .01) postoperatively in both groups. Mean preoperative value of 50.62 ± 11.77° decreased to 27.28 ± 6.53, 26.82 ± 6.03, 26.61 ± 5.80, 26.83 ± 5.76° at 1, 3, 6, 12 months respectively in ICL V4 group, and mean preoperative value of 54.40 ± 10.51° decreased to 27.80 ± 5.62, 26.94 ± 5.56, 27.32 ± 5.66, 27.04 ± 5.47° at 1, 3, 6, and 12 months, respectively, in ICL V4c group. There were no statistically significant differences within groups at any time point after surgery and the differences in ACA width between the 2 groups were not statistically significant at any time point neither (all *P* > .05) (Fig. 4).

3.5. Correlation

UBM measured ACA width in degrees showed no correlation with IOP or ICL central vault at all time points (all *r* < 0.2) in both groups.

4. Discussion

ASC opacities and IOP hypertension are the most common complications of pIOL implantation. Fujisawa et al^[12] reported that inserting an implantable Collamer Lens altered the dynamics of the aqueous humor and result in IOP elevation. By constantly improving the geometry of pIOLs, new generations such as ICL V4 and V4c were designed to reduce the incidence of such complications. The presence of a central hole in the ICL optic helped to improve the aqueous humor circulation to the anterior

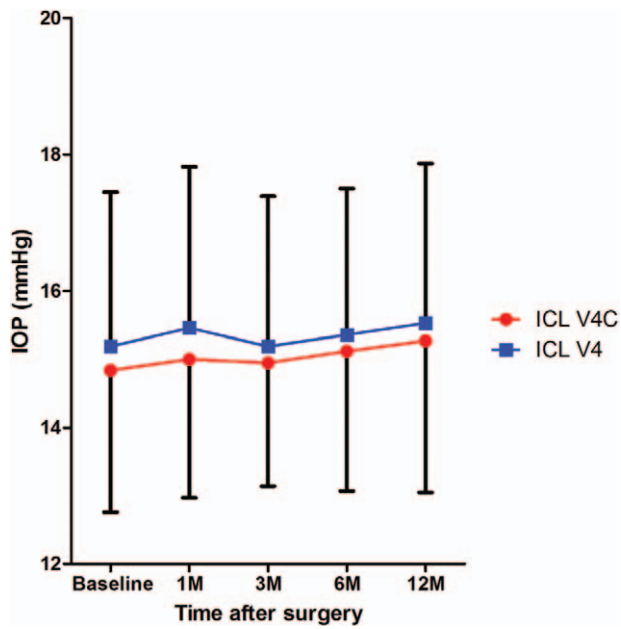


Figure 2. Time course of IOP changes after implantation of implantable collamer lens with (ICL V4c) and without central artificial hole (ICL V4).

surface of the crystalline lens, thus reducing the chance of ASC opacities.

Recent researches have shown that postoperative IOP can remain stable after ICL implantations (V4 and V4c model),^[7,13,14] with or without a transient IOP increase at 1 day or

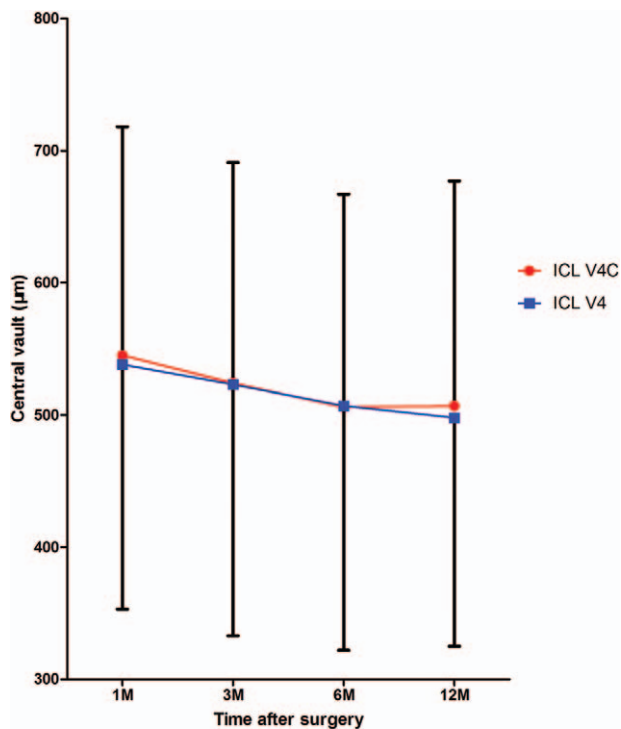


Figure 3. Time course of central vault changes after implantation of implantable collamer lens with (ICL V4c) and without central artificial hole (ICL V4).

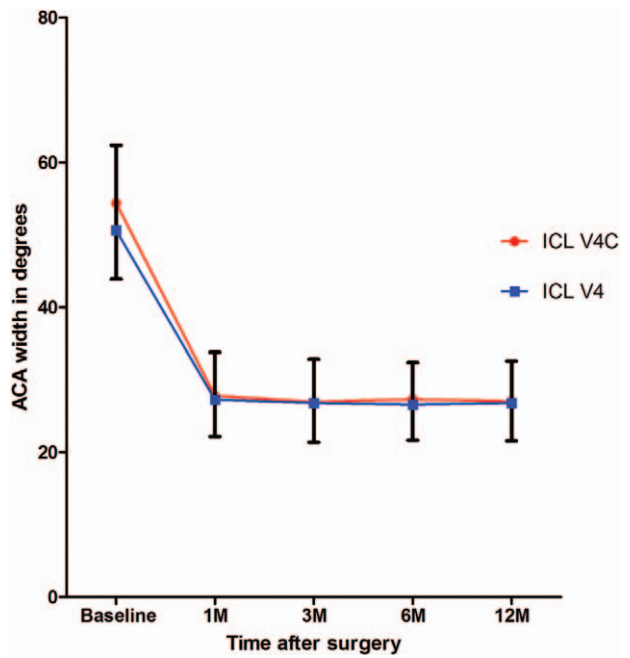


Figure 4. Time course of anterior chamber angle changes after implantation of implantable collamer lens with (ICL V4c) and without central artificial hole (ICL V4).

1 week post-surgery. Early acute intraocular pressure increase was reported to be relatively frequent, whereas acute pupillary block was less frequent and mostly resolved with additional iridotomies.^[15] Other factors leading to IOP elevation included pigment dispersion and steroid use. In Gonzalez-Lopez's retrospective case series,^[16] no eye had an IOP greater than 30 mm Hg at any time points after V4c-ICL implantation. In a retrospective study authored by Liu et al,^[17] which included 82 eyes implanted with V4c-ICL (STAAR Surgical), the author reported that IOP had a slightly increase on postoperatively day 1, and only one eye had an IOP over 21 mm Hg, which soon returned to normal range without any special treatment.

The vault changes following ICL implantation have always been a concern of many scholars.^[10,18,19] Packer^[13] concluded that low vault, together with higher levels of myopia, constituted risk factors for ASC cataract. Schmidinger et al^[18] reported consistent reduction of central vaulting over a 10-year period time and suggested that a minimum central vaulting of 230 µm was necessary to ensure total vaulting of the ICL (V4 and early models). Regarding ICL V4c models, a tendency of decrease in central vault depth after implantation was also observed in some reports.^[10,20,21] In a large retrospective study that included 3420 eyes implanted with ICL V4, V4b, and V4c models, 21 eyes (0.61%) of 15 patients had pIOL explantation (all model V4) because of cataract formation, with mean vault distance of 103 ± 69 µm.^[22] In our study, postoperative central vault depth were 545 ± 173, 524 ± 167, 506 ± 161, 507 ± 170 µm at 1, 3, 6, and 12 months, respectively, in ICL V4c group, and 538 ± 185, 523 ± 190, 507 ± 185, 498 ± 173, respectively, in ICL V4 group. Although no ASC opacities were found in our study, there was a tendency for the central vault depth to decrease over time in both groups, which is a risk factor for developing cataract. Age-related increase in the thickness of the crystalline lens and fixed position of the pIOL haptics are factors accounting for slight decrease with

time in vault.^[20,23,24] In addition, dynamic changes such as pupil constriction, especially under photopic conditions, might influence the lens vault in the posterior chamber.^[25,26] In our study, no correlation between central vault and ACA width was found, which had some discrepancies with study by Eissa et al.^[27]

In research by Eissa et al.^[27] of ACA evaluation following pIOL implantation, pentacam was used to observe ACA changes and its correlation with ICL vault and IOP. The study enrolled 54 eyes of 27 patients implanted with ICL V4c model. Pentacam-aided measurement of AC angle width in degrees showed a statistically significant decrease at 1 ($P=.025$), 6 ($P=.016$), and 18 ($P=.010$) months postoperatively. Mean ICL vault showed moderate correlation with Pentacam ACA width at 1 ($r=-0.435$) and 6 ($r=-0.424$) months and weak correlation ($r=-0.207$) at 18 months. Although in our study, UBM measured ACA width in degrees showed no correlation with IOP or ICL central vault at all time points (all $r < 0.2$) in both groups. Our study found a significant decrease in ACA width at 1 month postoperatively in both groups, but no eyes encountered IOP elevation or pupillary block. No significant changes of the AC angle were found during the follow-up time and showed no tendency for the ACA width in degrees to decrease over time.

In a study by Chung et al,^[28] 1-month postoperative angle opening distance values were significantly smaller than preoperative values by 31.8% ($P < .001$), but no significant progressive changes were observed thereafter. In our research, we found that 1-month postoperative ACA width in degree were decreased by 55.7% (V4c group) and 54.2% (V4 group); it may have a correlation with Chinese conditions that extremely high myopic eyes received ICL implantations. These patients had obvious posterior iris depression that can be observed through UBM examinations, leading to the measurement deviation (larger than actual ones) of preoperative AC angle width. It could have a significant decrease in ACA width in these patients after surgery, with a mean level of 27°. Our study also found that ICL footplate haptics might be supported by the ciliary body instead of resting on ciliary sulcus that could lead to narrowing of the AC angle, and it came to an agreement with research by Chung et al.^[28]

The limitations of this study include the relatively short follow-up time and lack of comparison of different methods for ACA evaluation. There is a tendency of decrease in central vault over time, so further observation is needed to confirm long-term safety of this procedure. Possibility of primary angle closure and increment of pigmentation of trabecular meshwork after long-term follow-up should also be concerned. Besides, vaulting and ACA measurements would have been better double checked with additional imaging modality such as Pentacam or anterior segment OCT. Anterior segment OCT can permit high-resolution cross-sectional anterior segment imaging with excellent reproducibility of measurements by using the interference profile of the reflections from the cornea, iris, and crystalline lens.^[27]

In summary, our comparative study found no significant differences in ACA width, central vault or IOP between ICL V4c and ICL V4 groups at any time point after surgery, suggesting that the ACA changes, post-surgery IOP, and central vault of the V4c group were essentially equivalent to that of conventional V4 group. There presented a tendency of decrease in central vault in both groups, so longer follow ups were needed for further longitudinal assessment. Implantation of ICLs (both V4c and V4 model) would result in a decrease in ACA width, but within acceptable physiological values at all time points and tended to be stable in the long run.

Author contributions

Conceptualization: TIAN'AN ZHOU, Ye Shen.

Data curation: TIAN'AN ZHOU, HUI JIANG, YANG WANG.

Formal analysis: JIANHUA XIA.

Investigation: HUI JIANG.

Methodology: TIAN'AN ZHOU, CHEN XIE.

Project administration: HUI JIANG, YANG WANG, CHEN XIE.

Resources: YANG WANG, CHEN XIE.

Supervision: Ye Shen.

Validation: CHEN XIE, JIANHUA XIA.

Writing – original draft: TIAN'AN ZHOU, HUI JIANG.

Writing – review & editing: TIAN'AN ZHOU.

References

- [1] Alfonso JF, Baamonde B, Fernandez-Vega L, et al. Posterior chamber collagen copolymer phakic intraocular lenses to correct myopia: five-year follow-up. *J Cataract Refract Surg* 2011;37:873–80.
- [2] Igarashi A, Shimizu K, Kamiya K. Eight-year follow-up of posterior chamber Phakic intraocular lens implantation for moderate to high myopia. *Am J Ophthalmol* 2014;157:532–9.
- [3] McLeod SD. Long-term clinical outcomes and cataract formation rates after posterior Phakic lens implantation for myopia. *JAMA Ophthalmol* 2016;134:494–5.
- [4] Guber I, Mouvet V, Bergin C, et al. Clinical outcomes and cataract formation rates in eyes 10 years after posterior Phakic lens implantation for myopia. *JAMA Ophthalmol* 2016.
- [5] Alfonso JF, Fernandez-Vega L, Lisa C, et al. Central vault after phakic intraocular lens implantation: correlation with anterior chamber depth, white-to-white distance, spherical equivalent, and patient age. *J Cataract Refract Surg* 2012;38:46–53.
- [6] Shiratani T, Shimizu K, Fujisawa K, et al. Crystalline lens changes in porcine eyes with implanted phakic IOL (ICL) with a central hole. *Graefes Arch Clin Exp Ophthalmol* 2008;246:719–28.
- [7] Shimizu K, Kamiya K, Igarashi A, et al. Long-term comparison of posterior chamber Phakic intraocular lens with and without a central hole (Hole ICL and Conventional ICL) implantation for moderate to high myopia and myopic astigmatism: consort-compliant article. *Medicine* 2016;95:e3270.
- [8] Higuera-Esteban A, Ortiz-Gomariz A, Gutierrez-Ortega R, et al. Intraocular pressure after implantation of the Visian implantable Collamer lens with CentraFLOW without iridotomy. *Am J Ophthalmol* 2013;156:800–5.
- [9] Cao X, Tong J, Wang Y, et al. Long-term ultrasound biomicroscopy observation of position changes of a copolymer posterior chamber phakic intraocular lens. *J Cataract Refract Surg* 2014;40:1454–61.
- [10] Cao X, Wu W, Wang Y, et al. Comparison over time of Vault in Chinese eyes receiving implantable contact lenses with or without a central hole. *Am J Ophthalmol* 2016;172:111–7.
- [11] Du C, Wang J, Wang X, et al. Ultrasound biomicroscopy of anterior segment accommodative changes with posterior chamber phakic intraocular lens in high myopia. *Ophthalmology* 2012;119:99–105.
- [12] Fujisawa K, Shimizu K, Uga S, et al. Changes in the crystalline lens resulting from insertion of a phakic IOL (ICL) into the porcine eye. *Graefes Arch Clin Exp Ophthalmol* 2007;245:114–22.
- [13] Packer M. Meta-analysis and review: effectiveness, safety, and central port design of the intraocular collamer lens. *Clin Ophthalmol* 2016;10:1059–77.
- [14] Lisa C, Naveiras M, Alfonso-Bartolozzi B, et al. Posterior chamber collagen copolymer phakic intraocular lens with a central hole to correct myopia: One-year follow-up. *J Cataract Refract Surg* 2015;41:1153–9.
- [15] Fernandes P, Gonzalez-Mejome JM, Madrid-Costa D, et al. Implantable collamer posterior chamber intraocular lenses: a review of potential complications. *J Refract Surg* 2011;27:765–76.
- [16] Gonzalez-Lopez F, Bilbao-Calabuig R, Mompean B, et al. Intraocular pressure during the early postoperative period after 100 consecutive implantations of posterior chamber phakic intraocular lenses with a central hole. *J Cataract Refract Surg* 2013;39:1859–63.

- [17] Liu T, Linghu S, Pan L, et al. Effects of V4c-ICL implantation on myopic patients' vision-related daily activities. *Ophthalmology* 2016; 5717932.
- [18] Schmidinger G, Lackner B, Pieh S, et al. Long-term changes in posterior chamber phakic intraocular collamer lens vaulting in myopic patients. *Ophthalmology* 2010;117:1506–11.
- [19] Gonvers M, Bornet C, Othenin-Girard P. Implantable contact lens for moderate to high myopia: relationship of vaulting to cataract formation. *J Cataract Refract Surg* 2003;29:918–24.
- [20] Kamiya K, Shimizu K, Ando W, et al. Comparison of vault after implantation of posterior chamber phakic intraocular lens with and without a central hole. *J Cataract Refract Surg* 2015;41:67–72.
- [21] Chen H, Niu G, Fan Y, et al. Comparison of intraocular pressure and vault after implantation of implantable collamer lens with and without a central hole. *BMC Ophthalmol* 2016;16:203.
- [22] Alfonso JF, Lisa C, Fernandez-Vega L, et al. Prevalence of cataract after collagen copolymer phakic intraocular lens implantation for myopia, hyperopia, and astigmatism. *J Cataract Refract Surg* 2015; 41:800–5.
- [23] Yan PS, Lin HT, Wang QL, et al. Anterior segment variations with age and accommodation demonstrated by slit-lamp-adapted optical coherence tomography. *Ophthalmology* 2010;117:2301–7.
- [24] Kamiya K, Shimizu K, Kawamorita T. Changes in vaulting and the effect on refraction after phakic posterior chamber intraocular lens implantation. *J Cataract Refract Surg* 2009;35:1582–6.
- [25] Lee H, Kang DS, Ha BJ, et al. Effect of accommodation on vaulting and movement of posterior chamber Phakic lenses in eyes with implantable collamer lenses. *Am J Ophthalmol* 2015;160:710–6.
- [26] Lee H, Kang SY, Seo KY, et al. Dynamic vaulting changes in V4c versus V4 posterior chamber phakic lenses under differing lighting conditions. *Am J Ophthalmol* 2014;158:1199–204.
- [27] Eissa SA, Sadek SH, El-Deeb MW. Anterior chamber angle evaluation following phakic posterior chamber collamer lens with CentraFLOW and its correlation with ICL Vault and intraocular pressure. *Ophthalmology* 2016;2016:1383289.
- [28] Chung TY, Park SC, Lee MO, et al. Changes in iridocorneal angle structure and trabecular pigmentation with STAAR implantable collamer lens during 2 years. *J Refract Surg* 2009;25:251–8.