



Contents lists available at ScienceDirect

International Journal of Surgery Case Reports

journal homepage: www.casereports.com

Is it an asymptomatic tracheal injury or misdiagnosis in treatment of vertebral fracture: A case report

Sinan Yılar^a, Serdar Toy^{b,*}^a Department of Orthopedics and Traumatology, Medical Faculty of Ataturk University, Erzurum, Turkey^b Department of Orthopedics and Traumatology, Ağrı Training and Research Hospital, Ağrı, Turkey

ARTICLE INFO

Article history:

Received 28 September 2020

Received in revised form 25 October 2020

Accepted 25 October 2020

Available online 2 November 2020

Keywords:

Fractures

Spine

Thoracic injuries

Thoracic vertebra

Viscera

ABSTRACT

INTRODUCTION: Pedicle screws are durable and safe instruments frequently used to treat vertebra injuries and deformities. There is also a possibility of medulla spinalis and visceral organ injury when the pedicle screws are delivered in unsuitable positions or dimensions. In this case, the authors want to draw attention to one of the visceral organ injuries during the thoracic pedicle screw placement.

PRESENTATION OF CASE: A 31 years old man underwent posterior instrumentation and fusion for T4 vertebra fractures. The patient was not symptomatic in the postoperative period. Tracheal pressure was observed at the 3rd thoracic vertebra level on the second day after the operation. No complications were encountered in the 3-year follow-up of the patient, who did not accept a second surgery recommended for screw replacement.

DISCUSSION: During surgery for thoracic vertebral fractures, the shoulder joint makes it difficult to imagine as the shoulder bones enter the field of view. Therefore, the number of misplaced screws increases. Moreover, it increases the risk of internal organ injury.

CONCLUSION: The use of navigation systems or cannulated pedicle screws to treat thoracic vertebral fractures reduces internal organ injuries.

© 2020 Published by Elsevier Ltd on behalf of IJS Publishing Group Ltd. This is an open access article under the CC BY-NC-ND license (<http://creativecommons.org/licenses/by-nc-nd/4.0/>).

1. Introduction

The use of pedicle screws (PS) in vertebra injuries has been used for many years after being first described in 1954 [1]. It is a method that has been used in thoracic vertebral injuries for about thirty years [2,3]. However, many complications have been reported in association with PS, such as many surgical instruments. The most important of these complications are vascular injuries, visceral organ injuries, and medulla spinalis injuries [4–6].

Since the visceral organs are highly close to vertebrae in the thoracic region, there is always a risk of injury [7]. Since the esophagus is the nearest organ to the vertebrae between T1 and T4, the possibility of injury is high [5,8]. The esophagus slides left at the T3 level. Therefore, the screw sent from the left side of the T3 vertebrae can move from the right side of the esophagus and put pressure on the trachea.

In this study, tracheal injury during posterior thoracic instrumentation was described because of the difficulty of imaging

caused by other fractures. Navigation systems and cannulated screws that can be used in these situations were also mentioned.

2. Case report

A 31-year-old man was involved in a motor vehicle accident. In the first examination of the patient, he was conscious and hemodynamically stable. The patient had severe back and wrist pain. No problem was observed in his neurological examination. The patient's radiographs and tomography, nondisplaced right radius distal end fracture, right glenoid fracture, and thoracic 4th vertebra fracture were present (Fig. 1). Since the patient had multiple fractures, an MRI scan was performed to investigate additional vertebral fracture injury. According to the MRI scan, there was no height loss in the vertebrae T2, T3, T5, T6, but severe bone edema was due to trauma (Fig. 1).

For the radial distal end fracture, percutaneous pinning was performed with closed reduction. It was decided to follow up on the glenoid fracture with the velpeau's bandage. For the thoracic 4th vertebra fracture, SY operated on the patient. In order not to separate the nondisplaced fracture in the left glenoid, the patient's shoulder joint was not subjected to forced hyper abduction, and the patient's arm was fixed to his trunk in the neutral position and then, he was taken into operation. Transpedicular screws were inserted bilaterally into the thoracic 2nd, 3rd, 5th, 6th vertebrae. All screws

* Corresponding author at: Department of Orthopedics and Traumatology, Ağrı Training and Research Hospital, Center, Ağrı, 04200, Turkey.

E-mail addresses: sinan.yilar@hotmail.com (S. Yılar), serdartyoy737@gmail.com (S. Toy).

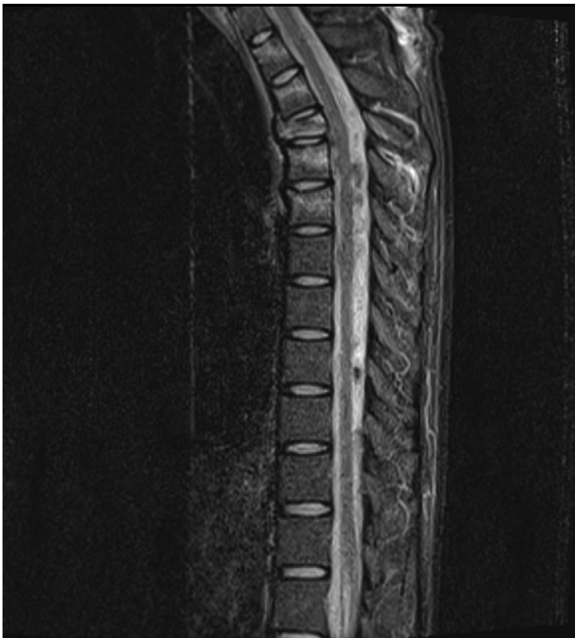


Fig. 1. At the preoperative period, the fracture of the 4th thoracic vertebra has been seen.

were calculated according to anatomical landmarks and delivered by the freehand method. The entry point was determined through the first path opener from the joint of the lamina's upper limit by the transverse process. The second path opener was used to pass through the pedicle and reach the corpus. Then, the corpus' anterior border went through the probe, and the length of the screw to be delivered was measured. According to these measurements, 5 × 35 mm screws were provided to T2 and T3, and 5 × 40 mm screws were supplied to T5 and T6 transpedicular. After the screws were applied, they were controlled by fluoroscopy. While no problem was observed in the anteroposterior image, no right image could be captured since the patient's left shoulder was attached to his trunk. During operation and early postoperative time, no problem was encountered, and the patient was sent to his room in the clinic.

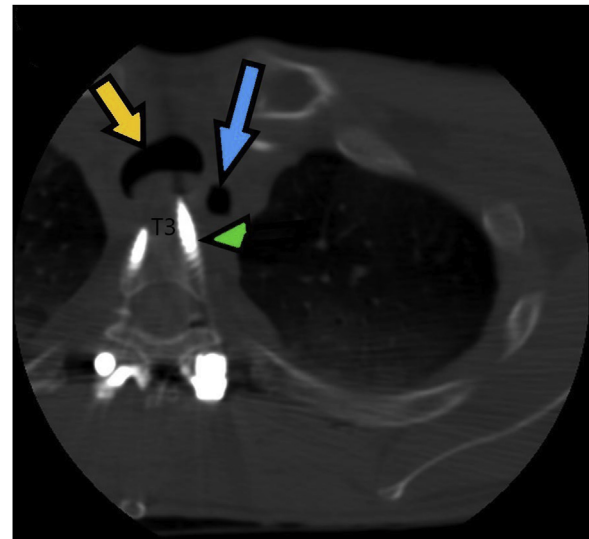


Fig. 3. At the axial tomography imaging, it has been seen that the screw that was delivered from the left pedicle of the vertebra T3 projected from the anterior cortex of the vertebra and passed through the medial of the esophagus and pushed the esophagus (yellow arrow: trachea, green arrowhead: long screw, blue arrow: esophagus).

On the 2nd postoperative day, X-rays were taken for the patient who had no problem in the postoperative period (Fig. 2). In the X-ray films taken, it has been seen that one of the screws that were delivered to T3 was long, and therefore, a tomography scan was performed on the same day. In the tomography scan, it was seen that the screw was delivered from the left pedicle of the vertebra T3 projected from the anterior cortex of the vertebra and passed through the medial of the esophagus and pushed the esophagus (Fig. 3). No problem was observed in the patient's respiratory function tests. The patient was told that this screw should have been replaced, but the patient refused the second operation, for he did not have any problem. By the end of the patient's 3-year follow-up, no respiratory function or swallowing problem was observed.

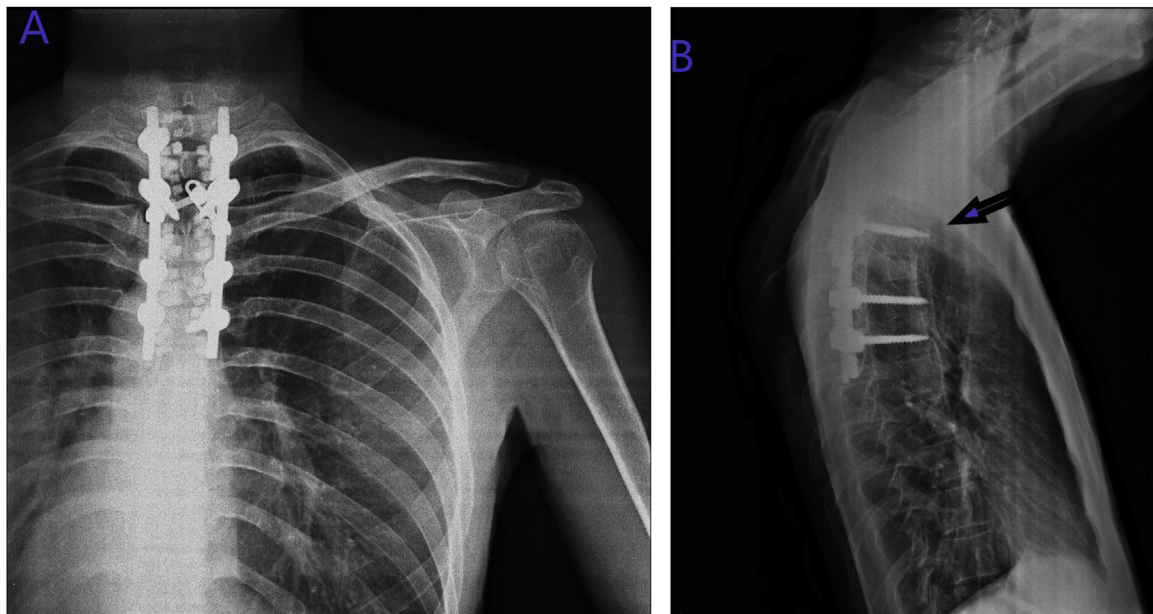


Fig. 2. On the 2nd postoperative day, the patient's direct radiography has taken (A). One of the screws that were sent to T3 was long (Arrow) (B).

This case-report study was prepared according to Scare Guidelines 2018 [9].

3. Discussion

Pedicle screws are robust fastening methods safely used for many years. The pedicles are thin and sclerotic in the upper thoracic area, and anatomic variations are common [7]. It enters the shoulder girdle bones' imaging site during the operation, and the intraoperative imaging systems remain inadequate. For these reasons, it is challenging to deliver pedicle screws in this area. Also, the percentage of incorrectly supplied screws is higher in this region than in other thoracic vertebrae [1].

The possibility of injury is high after spinal surgery since the visceral organs are close to the vertebrae [2]. Although vascular organ injuries are often reported [3], pleural injuries are also frequent [2]. Even though esophagus injuries are more common after anterior cervical surgeries [4], iatrogenic esophagus injuries caused by misrouted pedicle screws have also been reported in the literature, even if just a few [1,5]. No iatrogenic trachea injury caused by pedicle screws was reported to date. Two esophageal injuries have been reviewed in the literature; one was at the level T3 [1], and the other was at the level T4 [5]. Since, at these levels, the trachea is located just anterior to the esophagus, it is not possible for a screw delivered in the wrong position to reach the esophagus. Conversely, in our case, the screw was provided in the right place. Since the screw was supplied was too long, it passed through the esophagus's right side, and it did not harm the esophagus and pressed the trachea at the midline.

When we tried to understand why the delivered T3 screws were too long in our case, we have noted that the T3 screws were 5–35 mm in size, but when we tomographically measured, we found that the screw length was 45 mm. Furthermore, since the surgeon could not feel typical vertebra hardness because of the fractures of the vertebrae T2,3,5,6 in the MRI images of the patient, we believe that the sent screw was long. Also, although the screws were checked by fluoroscopy during operation, no appropriate image could be captured. It could not be noticed that the screw was long since the procedure was started with the patient's left arm attached to his trunk.

Studies have shown that medial wall injuries are less than lateral wall injuries, contrary to fear [6–8]. In recent years, the use of cannulated screws has been increased to reduce lateral perforation [10]. Various techniques have been proposed, such as fluoroscopic and CT guidance surgery intraoperative electromyography, somatosensory, and motor evoked potential monitoring to improve the accuracy of thoracic pedicle screws [11,12]. In this case, such systems were not used. But, we started to use cannulated screws more frequently in the following cases. We think that the use of this type of screws will reduce complications and the rate of additional organ injuries.

4. Conclusion

Pedicle screws can cause visceral organ injuries, although they are safe instruments frequently used in spinal stabilization. Since the trachea is close to vertebrae in the upper thoracic region, there is a possibility of injury due to the longer screws. Imaging methods, navigation systems, and cannulated pedicle screws should be used more frequently to reduce visceral organ injuries in the surgery of thoracic vertebral fractures.

Declaration of Competing Interest

The authors report no declarations of interest.

Sources of funding

This research did not receive any specific grant from funding agencies in the public, commercial, or not-for-profit sectors.

Ethical approval

Ethics committee approval was not received because it was a case report study.

Consent

Written informed consent was obtained from the patient for publication of this case report and accompanying images. A copy of the written consent is available for review by the Editor-in-Chief of this journal on request.

Author contribution

Sinan YILAR: Study concept and design, data collection, materials, literature review, writing the paper, critical review.

Serdar TOY: Study concept and design, data interpretation, literature review, writing the paper, critical review.

Registration of research studies

NA.

Guarantor

Serdar TOY.

Provenance and peer review

Not commissioned, externally peer-reviewed.

References

- [1] J. O'Brien, E. Krushinski, C. Zarro, M. Sciadini, D. Gelb, S. Ludwig, Esophageal injury from thoracic pedicle screw placement in a polytrauma patient: a case report and literature review, *J. Orthop. Trauma* 20 (6) (2006) 431–434.
- [2] N.A. Ebraheim, G. Jabaly, R. Xu, R.A. Yeasting, Anatomic relations of the thoracic pedicle to the adjacent neural structures, *Spine* 22 (14) (1997) 1553–1556.
- [3] K. Watanabe, A. Yamazaki, T. Hirano, T. Izumi, A. Sano, O. Morita, et al., Descending aortic injury by a thoracic pedicle screw during posterior reconstructive surgery: a case report, *Spine* 35 (20) (2010), E1064–E8.
- [4] M. Zdichavsky, M. Blauth, U. Bosch, H. Rosenthal, C. Knop, L. Bastian, Late esophageal perforation complicating anterior cervical plate fixation in ankylosing spondylitis: a case report and review of the literature, *Arch. Orthop. Trauma Surg.* 124 (5) (2004) 349–353.
- [5] K. Sariyilmaz, O. Ozkunt, M. Sungur, F. Dikici, U. Domanic, Esophageal perforation caused by a posterior pedicle screw: a case report, *J. Pediatr. Orthop.* 37 (2) (2017) 98–101.
- [6] R.A. Lehman Jr, L.G. Lenke, K.A. Keeler, Y.J. Kim, G. Cheh, Computed tomography evaluation of pedicle screws placed in the pediatric deformed spine over an 8-year period, *Spine* 32 (24) (2007) 2679–2684.
- [7] A.Y. Şarlak, B. Tosun, H. Atmaca, H.T. Sarisoy, L. Buluç, Evaluation of thoracic pedicle screw placement in adolescent idiopathic scoliosis, *Eur. Spine J.* 18 (12) (2009) 1892.
- [8] S. Yılar, Comparison of the accuracy of cannulated pedicle screw versus conventional pedicle screw in the treatment of adolescent idiopathic scoliosis: a randomized retrospective study, *Medicine* 98 (10) (2019).
- [9] R.A. Agha, M.R. Borrelli, R. Farwana, K. Koshy, A.J. Fowler, D.P. Orgill, et al., The SCARE 2018 statement: updating consensus Surgical CAse REport (SCARE) guidelines, *Int. J. Surg.* 60 (2018) 132–136.
- [10] C.K. Lee, C.Y.W. Chan, S.M. Abd Gani, M.K. Kwan, Accuracy of cannulated pedicle screw versus conventional pedicle screw for extra-pedicular screw

- placement in dysplastic pedicles without cancellous channel in adolescent idiopathic scoliosis: a computerized tomography (CT) analysis, *Eur. Spine J.* 26 (11) (2017) 2951–2960.
- [11] T. Fujimori, M. Iwasaki, Y. Nagamoto, M. Kashii, M. Takao, T. Sugiura, et al., Reliability and usefulness of intraoperative 3-dimensional imaging by mobile C-arm with flat-panel detector, *Clin. Spine Surg.* 30 (1) (2017) E64–E75.
- [12] X.-t. Meng, X.-f. Guan, H.-l. Zhang, S.-s. He, Computer navigation versus fluoroscopy-guided navigation for thoracic pedicle screw placement: a meta-analysis, *Neurosurg. Rev.* 39 (3) (2016) 385–391.

Open Access

This article is published Open Access at [sciencedirect.com](https://www.sciencedirect.com). It is distributed under the [IJSCR Supplemental terms and conditions](#), which permits unrestricted non commercial use, distribution, and reproduction in any medium, provided the original authors and source are credited.