

# Chronic Ocular Hypertension after Treated Multifocal Bacterial Keratitis

Theodoros Athanassios Papadopoulos Georgia Vrouva Maria Bafa  
Nikolaos Paterakis Maria Chounta

Department of Ophthalmology, 'Thriassion' General Hospital of Eleusis, Athens, Greece

## Key Words

Keratitis · Ocular hypertension · *Staphylococcus epidermidis*

## Abstract

**Purpose:** To report an unusual case of multifocal bacterial keratitis that despite successful treatment caused chronic ocular hypertension. **Methods:** A 67-year-old woman with unilateral multifocal keratitis and no previous ocular pathology was admitted to our hospital. Corneal scrapings and conjunctival samples were obtained for culture and the patient received intensive therapy with fortified vancomycin and tobramycin eye drops. **Results:** The cultures demonstrated two strains of *Staphylococcus epidermidis*, one resistant to ciprofloxacin and both sensitive to vancomycin. Treatment was effective and gradually discontinued after total cessation of the inflammatory activity. During the follow-up period, the patient developed late and persistent ocular hypertension of unknown etiology, in absence of any detectable inflammation or complication, and received permanent antiglaucoma therapy. **Conclusion:** Differential diagnosis between fungal and bacterial infection is critical in cases of multifocal keratitis. Patients with multifocal bacterial keratitis may need intraocular pressure monitoring, even after complete infection healing.

## Introduction

Bacterial keratitis is considered a leading cause of monocular blindness in the developing world [1]. *Staphylococcus* is a common Gram-positive bacterium causing keratitis that tends to present with a focal and well-defined white or yellow-white infiltrate. During the infection, corneal inflammation can lead to neovascularization and scarring, while internal ocular inflammation can cause synechia formation, elevated intraocular pressure and cataract [1, 2]. Several staphylococcal strains have been reported resistant to topical quinolone therapy [3, 4].

Theodoros Athanassios Papadopoulos, MD, PhD  
Department of Ophthalmology  
'Thriassion' General Hospital of Eleusis, G. Gennimatas Avenue  
GR–19600 Magoula, Athens (Greece)  
E-Mail thathpap@hotmail.com

We report an unusual case of quinolone-resistant multifocal staphylococcal keratitis without a history of previous ocular pathology, which caused chronic intraocular pressure elevation despite successful keratitis treatment and complete resolution of external and internal ocular inflammation.

### Case Presentation

A 67-year-old woman presented in the emergency section of our department with gradual onset of redness, tearing, photophobia and a 4-day history of blurred vision in her right eye. There was no history of contact lens wear, previous ocular disease, trauma or surgery. Examination of the right eye revealed visual acuity of counting fingers, intense conjunctival injection, mild corneal edema and three corneal ulcers of different extension (1–5 mm in diameter). A moderate aqueous flare was noted in the anterior chamber without presence of hypopyon or pupillary synechiae (fig. 1). Intraocular pressure and fundus were normal, and there were no pathological findings in her left eye.

Corneal scrapings and conjunctival samples were obtained from the right eye and sent to the laboratory for culture. The patient was hospitalized and received empirical treatment with fortified vancomycin + tobramycin (Voncon, Lilly + Tobrex, Alcon) eye drops every 30 min the first day, every hour the second day and afterwards every 2 h. Topical cyclopentolate (Cyclogyl, Alcon) 3 times daily was also administered.

The cultures demonstrated the presence of two strains of coagulase-negative *Staphylococcus epidermidis*, one resistant to ciprofloxacin and both sensitive to vancomycin.

One week after treatment implementation, the patient reported partial relief from her initial symptoms. A considerable reduction of the extension of corneal ulcers was noted, though aqueous flare and intraocular pressure increased (32 mm Hg) and corneal neovascularization appeared at the limbus adjacent to the corneal ulcers. Treatment was modified to topical vancomycin, dexamethasone (Maxidex, Alcon) and cyclopentolate initially 3 times daily, with a progressive tapering scheme during the following 3 weeks. Topical brinzolamide (Azopt, Alcon) twice daily was also administered. The patient was discharged from hospital and scheduled for examination twice a week.

After the 3-week-period, the corneal ulcers were completely healed; there was no conjunctival injection, no visible aqueous flare but only a mild scarring at the superior limbus (fig. 2). Corrected visual acuity was 0.8 and intraocular pressure was normal. Treatment was discontinued and follow-up was arranged twice monthly. Two months later, a persistent ocular hypertension (26–28 mm Hg) of unknown etiology and without any external or internal ocular inflammation was noted in the right eye at three consecutive visits. A Goldmann contact lens was used to perform a 360° gonioscopy that did not reveal any pathological findings. Intraocular pressure was normal in the left eye and corneal pachymetry was normal in both eyes. Topical brinzolamide was restarted and follow-up was continued monthly. For the next 6 months, intraocular pressure in the right eye fluctuated within normal limits and no inflammatory recurrence was observed. The patient remained under topical antiglaucoma therapy as described above.

### Discussion

Multifocal keratitis is often associated with fungal infection [1]. Occasionally, staphylococcal keratitis can present with predominantly multifocal epithelial infiltration, especially

in the setting of hydrophilic contact lens wear or after laser in situ keratomileusis. Multiple foci of abscesses resemble fungal satellite lesions [1, 5].

In the present case, none of the above stated predisposing factors for multifocal epithelial infiltration existed. Furthermore, we did not detect any predisposing factors for chronic intraocular pressure elevation, such as history of glaucoma or ocular hypertension, trauma, relapsing inflammation and anterior or posterior synechiae.

The existence of aqueous flare in the anterior chamber could explain the temporary intraocular pressure rise diagnosed in the second week, though after total cessation of the inflammatory activity the intraocular pressure returned to normal values as expected. Steroid-induced ocular hypertension does not seem to be relevant since steroid treatment was of limited duration, low dosed and gradually discontinued. A possible explanation for the late and persistent intraocular pressure elevation may be a permanent damage of the trabecular meshwork caused by staphylococcal toxins. Despite normal appearance of the iridocorneal angle on gonioscopy, invisible microscopic changes could not be excluded.

The resistance of one *S. epidermidis* strain to ciprofloxacin is in accordance with previous reports and indicates that microbial culture is necessary in cases of extensive bacterial corneal ulcers [3, 4]. Furthermore, it also shows that an initial empirical treatment with a combination of fortified topical antibiotics may be superior to topical quinolone monotherapy in these cases. However, further evidence is required to support the above hypothesis since there are studies showing equivalence of fluoroquinolone monotherapy to fortified medications in microbial keratitis [6, 7]. Unfortunately, it was not possible for our laboratory to test the sensitivity of the ciprofloxacin-resistant strain to newer-generation quinolones, which could have had better activity against these Gram-positive organisms.

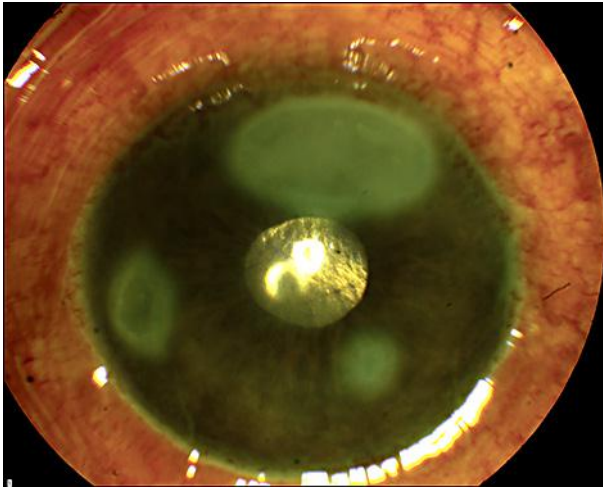
In conclusion, the present case demonstrates that in patients with multifocal keratitis, differential diagnosis between fungal and bacterial infection is critical for successful treatment. Besides treatment, patient follow-up and intraocular pressure monitoring may be needed, even after complete infection healing and resolution of inflammatory signs.

### Disclosure Statement

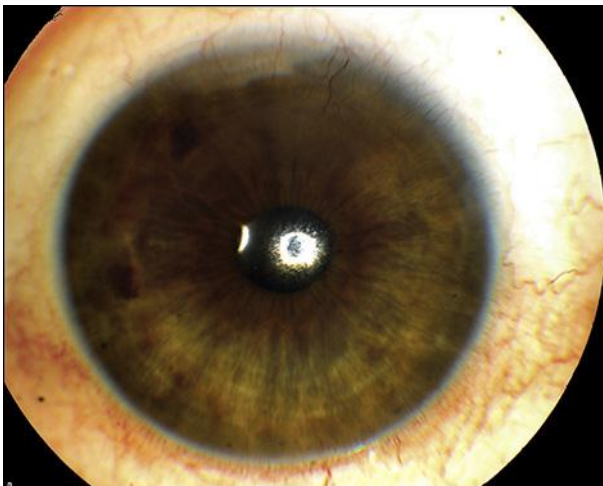
None of the authors have any conflict of interest relevant to this paper.

### References

- 1 McLeod SD: Bacterial keratitis; in Yanoff M, Duker JS (eds): Ophthalmology, ed 3. St. Louis, Mosby, 2008, pp 887–893.
- 2 Sharma S: Keratitis. Biosci Rep 2001;21:419–444.
- 3 Betanzos-Cabrera G, Juárez-Verdayes MA, González-González G, Cancino-Díaz ME, Cancino-Díaz JC: Gatifloxacin, moxifloxacin and balofloxacin resistance due to mutations in the *gyrA* and *parC* genes of *Staphylococcus epidermidis* strains isolated from patients with endophthalmitis, corneal ulcers and conjunctivitis. Ophthalmic Res 2009;42:43–48.
- 4 Sharma V, Sharma S, Garg P, Rao GN: Clinical resistance of *Staphylococcus* keratitis to ciprofloxacin monotherapy. Indian J Ophthalmol 2004;52:287–292.
- 5 Ritterband D, Kelly J, McNamara T, Kresloff M, Koplin R, Seedor J: Delayed-onset multifocal polymicrobial keratitis after laser in situ keratomileusis. J Cataract Refract Surg 2002;28:898–899.
- 6 O'Brien TP, Maguire MG, Fink NE, Alfonso E, McDonnell P: Efficacy of ofloxacin vs cefazolin and tobramycin in the therapy for bacterial keratitis. Report from the Bacterial Keratitis Study Research Group. Arch Ophthalmol 1995;113:1257–1265.
- 7 Khokhar S, Sindhu N, Mirdha BR: Comparison of topical 0.3% ofloxacin to fortified tobramycin-cefazolin in the therapy of bacterial keratitis. Infection 2000;28:149–152.



**Fig. 1.** Right eye before treatment. Intense conjunctival injection, mild corneal edema and three corneal ulcers of different extension.



**Fig. 2.** Right eye after treatment. The corneal ulcers completely healed with a mild scarring at the superior limbus.