

# Green Herring Syndrome: Bacterial Infection in Patients With Mucormycosis Cavitory Lung Disease

Driele Peixoto,<sup>1</sup> Sarah P. Hammond,<sup>1,5,6</sup> Nicolas C. Issa,<sup>1,5,6</sup> Rachna Madan,<sup>3,6</sup> Ritu R. Gill,<sup>3,6</sup> Danny A. Milner,<sup>4,6</sup> Yolonda L. Colson,<sup>2,6</sup> Sophia Koo,<sup>1,5,6</sup> Lindsey R. Baden,<sup>1,5,6</sup> and Francisco M. Marty<sup>1,5,6</sup>

Divisions of <sup>1</sup>Infectious Diseases, Department of Medicine, and <sup>2</sup>Thoracic Surgery, and Departments of <sup>3</sup>Radiology and <sup>4</sup>Pathology, Brigham and Women's Hospital, Boston, Massachusetts; <sup>5</sup>Department of Medical Oncology, Dana-Farber Cancer Institute, Boston, Massachusetts; and <sup>6</sup>Harvard Medical School, Boston, Massachusetts

**Mucormycosis is a life-threatening fungal disease in patients with hematological malignancies. The diagnosis of pulmonary mucormycosis is particularly challenging. We describe 3 mucormycosis cases with an uncommon presentation in patients whose cavitory lung disease was attributed to well documented bacterial infection, although evolution and reassessment established mucormycosis as the underlying disease.**

**Keywords.** bacterial coinfection; cavitory lung disease; mucormycosis; transplantation.

Mucormycosis is a life-threatening, angioinvasive fungal disease. It is caused by ubiquitous saprophytic fungi of the order Mucorales and predominantly occurs in immunocompromised patients [1]. Although uncommon, its frequency appears to have increased in recent years, particularly in transplant recipients and patients with hematological malignancies [2]. In a recent study of the frequency of invasive fungal disease in hematopoietic stem cell transplant (HSCT) recipients, mucormycosis was the third most common fungal infection, after candidiasis and aspergillosis [3], accounting for up to 8% of invasive fungal disease in HSCT recipients [4].

Received 9 January 2014; accepted 31 March 2014.

Correspondence: Francisco M. Marty, MD, Division of Infectious Diseases, Brigham & Women's Hospital, 75 Francis Street, PBB-A4, Boston, MA 02115 (fmarty@partners.org).

## Open Forum Infectious Diseases

© The Author 2014. Published by Oxford University Press on behalf of the Infectious Diseases Society of America. This is an Open Access article distributed under the terms of the Creative Commons Attribution-NonCommercial-NoDerivs licence (<http://creativecommons.org/licenses/by-nc-nd/3.0/>), which permits non-commercial reproduction and distribution of the work, in any medium, provided the original work is not altered or transformed in any way, and that the work is properly cited. For commercial re-use, please contact [journals.permissions@oup.com](mailto:journals.permissions@oup.com).

DOI: 10.1093/ofid/ofu014

Pulmonary mucormycosis is usually a rapidly progressive infection associated with debilitating morbidity and high mortality. Early recognition of this diagnosis, along with aggressive management, is critical to effective therapy and patient survival [5]. The diagnosis of pulmonary mucormycosis can be particularly challenging. Not only is this condition relatively rare, but it is also challenging to differentiate from other causes of pneumonia and other angioinvasive pulmonary diseases caused by molds [6].

In this report, we present 3 cases that highlight a misleading presentation of mucormycosis in which bacteria were identified as the causal etiology of necrotizing cavitory lung disease on initial diagnostic evaluation, but subsequent evolution and reassessment of the same cavitory disease demonstrated underlying mucormycosis. This bacterial and apparently parsimonious presentation, which we have termed the green herring syndrome, masked and delayed the diagnosis and treatment of the underlying cause of the pulmonary cavitory disease.

## CASES

### Patient A

A 60-year-old male with non-Hodgkin follicular lymphoma underwent reduced-intensity allogeneic HSCT from a related donor. On day +140 posttransplantation, the patient developed diarrhea and was found to have severe gastrointestinal acute graft-versus-host disease (GVHD) for which he received high-dose prednisone and tacrolimus (Table 1). He was admitted to the hospital with 2 days of shortness of breath and cough on day +177 posttransplantation. Admission chest computed tomography (CT) demonstrated a cavitory lesion surrounded by consolidation in his left lower lobe (Figure 1). He received metronidazole, levofloxacin, and voriconazole empirically.

During admission, the cavitory lung lesion progressed with development of a worsening ipsilateral pleural effusion with new pleural gas. On day +186 posttransplant, he underwent a bronchoalveolar lavage (BAL) with left lower lobe washings and left video-assisted thoracoscopic surgical exploration. Cloudy, foul-smelling pleural fluid was obtained, suggestive of bacterial empyema. Lung biopsy was not pursued given this finding. Cultures grew fluoroquinolone-resistant *Escherichia coli*, enterococci, and *Peptostreptococcus magnus*. Voriconazole was discontinued, and he received cefotaxime, metronidazole, and vancomycin.

Two days later, he developed altered mental status, and a head CT showed an area of heterogeneous attenuation in the left frontal lobe with surrounding mass effect. A repeat chest

**Table 1. Clinical Characteristics of Patients With Mucormycosis Presenting With Well Documented Bacterial Infection**

Characteristics	Patient A	Patient B	Patient C
Age at diagnosis (years)	60	57	49
Sex	Male	Male	Male
Underlying disease	Non-Hodgkin's lymphoma	Chronic lymphocytic leukemia	T-cell prolymphocytic leukemia
Oncologic status	Remission	Relapsed	Remission
GVHD	Yes	No	Yes
GVHD treatment	Prednisone, tacrolimus	No	Prednisone, interleukin-2, extracorporeal photopheresis
Initial bacterial infection	Pneumonia <i>Escherichia coli</i> , Enterococci, <i>Peptostreptococcus magnus</i>	Pneumonia <i>E coli</i>	Pneumonia and bacteremia with <i>Pseudomonas aeruginosa</i>
Days posttransplant	D+ 186	Before the transplant	D+ 650
Fungal disease diagnosis	Autopsy	Transbronchial biopsy	Brain mass biopsy and bronchoalveolar lavage
Days posttransplant	D+190	D+47	D+660
Fungal species	<i>Rhizopus microsporus/azygosporus</i>	<i>Rhizopus</i> species	<i>Rhizomucor pusillus</i>
Clinical presentation	Shortness of breath and cough	Cough	Shortness of breath and pleuritic pain
Hemoptysis	No	Yes	Yes
Neutropenia at diagnosis	No	No	No
Steroids before diagnosis	Yes	Yes	Yes
Antifungals before diagnosis	Fluconazole, voriconazole	Posaconazole, liposomal amphotericin B	Voriconazole
Site of infection	Lung, brain, thyroid	Lung	Lung and brain
Therapy	None	Liposomal amphotericin B, isavuconazole	Liposomal amphotericin B, isavuconazole
Days between mucormycosis diagnosis and death	0	229	29

Abbreviation: GVHD, graft-versus-host disease.

CT demonstrated new multifocal ground-glass opacities in the right lung. On day +188 posttransplant, the patient was intubated due to worsening dyspnea, and voriconazole was restarted. The patient died on day +190 posttransplant.

On autopsy, he had angioinvasive broad, ribbon-like hyphal forms with 90-degree branching suggestive of invasive mucormycosis in his lung, brain, and thyroid. Lung cultures grew *E coli*, enterococci, and *Rhizopus* species. The causative fungal species was identified by tissue polymerase chain reaction (PCR) as *Rhizopus microsporus/Rhizopus azygosporus*.

### Patient B

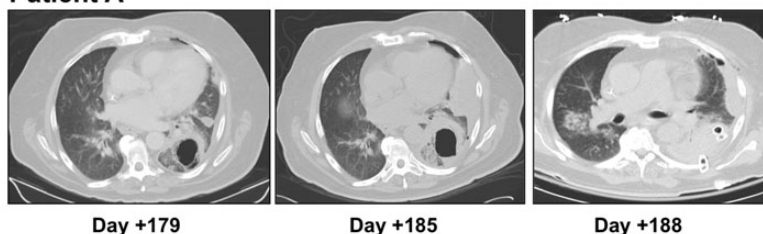
A 57-year-old male with relapsed B-cell chronic lymphocytic leukemia developed fevers, productive cough, and hemoptysis while receiving posaconazole prophylaxis after recent treatment with alemtuzumab and high-dose methylprednisolone (Table 1).

A chest CT demonstrated (1) a large dominant consolidative opacity in the right upper lobe (RUL) with focal dense consolidation and peripheral ground-glass and (2) another focal opacity superiorly to this dominant opacity with a dense peripheral

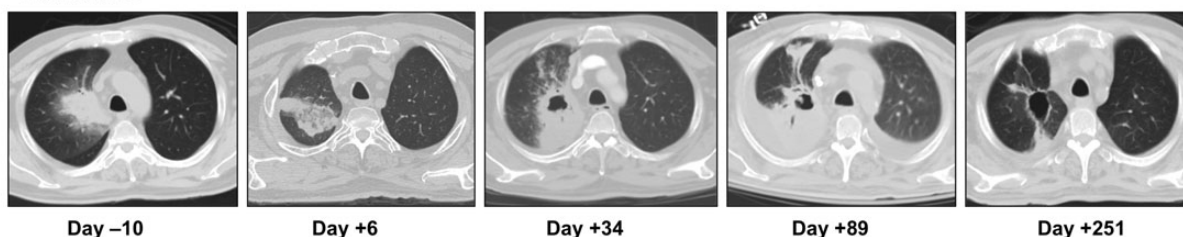
rind and central ground-glass opacity (reversed halo sign [RHS], Figure 1). He was started on ceftazidime, levofloxacin, and liposomal amphotericin B (5 mg/kg q24h) empirically. Bronchoalveolar lavage bacterial and fungal cultures were sterile; serum galactomannan and (1→3)-β-D-glucan were also negative. He improved clinically and his nodules were less prominent on a repeat chest CT. He was discharged on 400 mg of posaconazole twice daily.

Two weeks later, he underwent a reduced-intensity allogeneic HSCT from a matched unrelated donor. Posaconazole and levofloxacin were continued posttransplant. Posaconazole levels were not obtained. Serial chest CT scans performed to follow-up the RUL consolidation showed progression, and on day +6 posttransplant 2 new areas of focal consolidation were noted. He underwent a fine-needle aspiration under CT guidance of this RUL lesion, and bacterial cultures grew fluoroquinolone-resistant *E coli*. No fungus was cultured or seen on cytopathology. He was treated with ceftriaxone. On day +34 posttransplant, a repeat chest CT demonstrated increasing dense RUL consolidation with increased cavitation and liposomal amphotericin B was started.

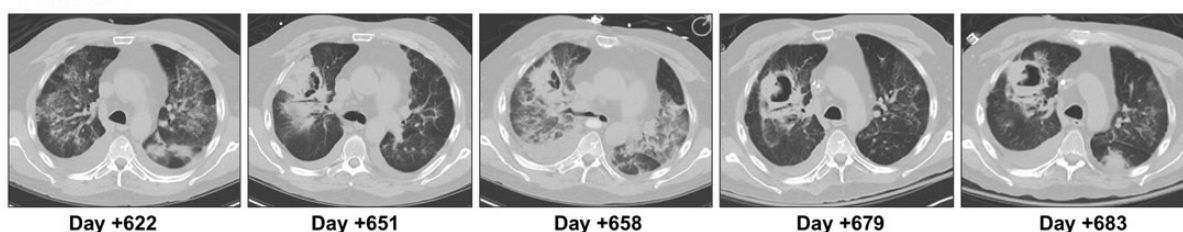
### Patient A



### Patient B



### Patient C



**Figure 1.** Representative chest computed tomography (CT) sections of patients with the green herring syndrome. Patient A: On day +179 after hematopoietic stem cell transplant (HSCT), a thick-walled cavity is seen in left lower lobe. Surrounding left lower lobe consolidation progresses, and on day +185 the cavitory lesion communicates with the pleural space, with a new loculated pleural collection. On day +188, a left-sided chest drain is seen for drainage of empyema. Note presence of reversed halo sign along the posteromedial aspect on days +179 and +185, irregular cavity wall, and internal cavity septations. Patient B: 10 days before HSCT, a focal dense consolidative opacity with surrounding ground-glass was seen in the medial right upper lobe (RUL). On day +6, the consolidation evolved, with central ground-glass and a solid peripheral rim (reversed halo sign). On day +34, this lesion had eccentric cavitation with an irregular cavity wall. On day +89, there was persistent cavitation, with consolidation and a new pleural effusion. On day +251, a residual thin-walled cavity is identified, whereas the consolidation resolved. Patient C: On day +622 after HSCT, CT showed multifocal extensive ground-glass and several small nodular opacities. On day +651, focal RUL consolidation with cavitation, internal septations, and an air crescent were noted. On day +658, multiple coalescing nodular consolidations were seen; note irregular cavitory wall and internal septations. On day +679, the cavity had a larger air component and a new air-fluid level. On day +683, new focal consolidations were seen in the left lower lobe.

Three days later, the patient developed massive hemoptysis and acute hypoxemic respiratory failure requiring intubation and endovascular right bronchial artery embolization. A transbronchial lung biopsy demonstrated hyphal forms consistent with mucormycosis; cultures were negative. The mold was identified as *Rhizopus* species by PCR/sequencing [7]. The patient continued treatment with liposomal amphotericin B for several months and developed acute renal failure requiring hemodialysis. He developed pancytopenia due to graft loss, and a donor-lymphocyte infusion was administered 7 months post-transplant. Isavuconazole was used for further treatment given ongoing renal dysfunction. One month later, the patient developed severe gastrointestinal and cutaneous GVHD and died from septic shock due to a carbapenem-resistant *Enterobacter cloacae*

bacteremia on day +276 posttransplantation. There was no radiological progression of his lung cavity during this period.

### Patient C

A 49-year-old male with T-cell prolymphocytic leukemia, status post-allogeneic HSCT complicated by chronic GVHD requiring prednisone, presented with fever, bronchopneumonia, and *Pseudomonas aeruginosa* bacteremia 1 year after transplant. Treatment with ciprofloxacin and ceftazidime was started. His serum (1→3)- $\beta$ -D-glucan was positive at 126 pg/mL and serum galactomannan was negative. Chest CT showed several small cavitory nodules and peribronchial nodular opacities in both lungs. He received treatment with voriconazole, with resolution of his respiratory symptoms and cavitory lesions.

He presented to the hospital on day +650 posttransplantation with dyspnea, fever, and pleuritic chest pain (Table 1). A chest radiograph revealed a nodular right lung opacity with cavitation. Blood cultures grew *P aeruginosa*. He had copious purulent secretions on BAL, so transbronchial biopsy was not performed; bacterial cultures of BAL fluid also grew *P aeruginosa*. The patient was treated with cefepime and levofloxacin (Figure 1).

Ten days later, he developed altered mental status, and a head CT demonstrated a new mass in the right caudate lobe with mass effect. A brain biopsy was performed and showed fungal forms suggestive of mucormycosis; cultures grew *Rhizomucor pusillus*. Repeat BAL cultures eventually grew the same organism. He received a dose of liposomal amphotericin B (5 mg/kg) followed by isavuconazole due to renal dysfunction.

The patient's neurologic function improved, and his brain and chest mucormycosis lesions decreased in size on isavuconazole therapy. Unfortunately, 1 month later, the patient died of multidrug-resistant *P aeruginosa* pneumonia and septic shock.

## DISCUSSION

The 3 patients in this series had cavitory pulmonary lesions that were attributed to bacterial infection based on an initial diagnostic evaluation, and they improved transiently with antibacterial therapy directed against the identified bacterial organisms. However, subsequent reassessments given an inadequate clinical response to antibacterial therapy led to the diagnosis of the underlying mucormycosis. The initial diagnosis of bacterial infection was plausible, parsimonious, and based on direct pulmonary cultures but ultimately misleading. This initial diagnosis resulted in delays and interruptions in appropriate antifungal treatment and increased morbidity, a scenario that we have termed the green herring syndrome. Despite a high degree of clinical suspicion and the use of various invasive and non-invasive diagnostic tools, the fungal diagnosis was difficult to establish and delayed.

Previous studies of pulmonary mucormycosis have demonstrated that clinical features of mucormycosis are nonspecific, leading to diagnostic difficulties and late diagnoses, with mortality rates as high as 65% among patients with hematological malignancies and 90% among bone marrow transplant recipients [5,8].

Chest CT imaging can be a useful tool for timely diagnosis of pulmonary mucormycosis, because cavitation is described as the common finding [9]. Moreover, the RHS or atoll sign, defined as a central ground-glass opacity with a surrounding rim of consolidation, is present early in the disease course and is more common among patients with mucormycosis than among those with other forms of invasive fungal pneumonia [10], especially when associated with negative serum galactomannan and (1→3)- $\beta$ -D-glucan [5]. However, neither of these radiographic findings is unique to pulmonary mucormycosis. The diagnosis often involves a multidisciplinary approach, aided by a combination of

imaging features, clinical picture, biochemical and microbiological evaluation, and pathological confirmation. The RHS is not pathognomonic and can be seen in patients with aspiration pneumonia and pulmonary infarction secondary to thromboembolic disease. Of interest, imaging in these patients demonstrated complex cavitory lesions with thick, irregular cavity walls and internal septations secondary to ischemic necrosis, which in our experience is not typically seen in bacterial lung abscesses. These lesions were preceded by the RHS in 2 of the 3 cases.

Due to the complex presentation and lack of reliable biochemical markers, methods to improve diagnosis and identification of mucormycosis and characterization of culture-negative invasive mold infection are essential. Some examples of emerging strategies that could be used to improve the diagnosis of mucormycosis are PCR detection of circulating DNA in serum [11] or detection of fungal species-specific breath volatile organic compound profiles [12].

These cases demonstrate that bacterial coinfection of pulmonary mucormycosis can lead to obscuration and delay in diagnosis of underlying mucormycosis. This diagnosis should be promptly considered in immunocompromised patients who present with complex cavitory lesions on CT with or without presence of RHS, even if receiving antimold prophylaxis, or when their lung disease progresses despite appropriate therapy against an identified bacterial pathogen.

## Notes

**Financial support.** This work was supported by departmental funds.

**Potential conflicts of interest.** F. M. M. has received research grant support from Astellas and consulting honoraria from Astellas and Merck. S. P. H. has received research grant support from Merck.

All authors have submitted the ICMJE Form for Disclosure of Potential Conflicts of Interest. Conflicts that the editors consider relevant to the content of the manuscript have been disclosed.

## References

1. Lanternier F, Dannaoui E, Morizot G, et al. A global analysis of mucormycosis in France: the RetroZygo Study (2005–2007). *Clin Infect Dis* **2012**; 54(Suppl 1):S35–43.
2. Marty FM, Cosimi LA, Baden LR. Breakthrough zygomycosis after voriconazole treatment in recipients of hematopoietic stem-cell transplants. *New Engl J Med* **2004**; 350:950–2.
3. Pagano L, Caira M, Candoni A, et al. The epidemiology of fungal infections in patients with hematologic malignancies: the SEIFEM-2004 study. *Haematologica*. **2006**; 91:1068–75.
4. Lanternier F, Sun HY, Ribaud P, et al. Mucormycosis in organ and stem cell transplant recipients. *Clin Infect Dis* **2012**; 54:1629–36.
5. Hammond SP, Baden LR, Marty FM. Mortality in hematologic malignancy and hematopoietic stem cell transplant patients with mucormycosis, 2001 to 2009. *Antimicrob Agents Chemother* **2011**; 55:5018–21.
6. Petrikos G, Skiada A, Lortholary O, et al. Epidemiology and clinical manifestations of mucormycosis. *Clin Infect Dis* **2012**; 54(Suppl 1): S23–34.
7. Hammond SP, Bialek R, Milner DA, et al. Molecular methods to improve diagnosis and identification of mucormycosis. *J Clin Microbiol* **2011**; 49:2151–3.
8. Pagano L, Offidani M, Fianchi L, et al. Mucormycosis in hematologic patients. *Haematologica* **2004**; 89:207–14.

9. Busca A, Limerutti G, Locatelli F, et al. The reversed halo sign as the initial radiographic sign of pulmonary zygomycosis. *Infection* **2012**; 40:77–80.
10. Wahba H, Truong MT, Lei X, et al. Reversed halo sign in invasive pulmonary fungal infections. *Clin Infect Dis* **2008**; 46:1733–7.
11. Millon L, Larosa F, Lepiller Q, et al. Quantitative polymerase chain reaction detection of circulating DNA in serum for early diagnosis of mucormycosis in immunocompromised patients. *Clin Infect Dis* **2013**; 56:e95–101.
12. Koo S, Thomas H, Rearden P, et al. An *Aspergillus fumigatus* (AF)-Specific Breath Volatile Organic Compound (VOC) Profile is Diagnostic of Invasive Aspergillosis (IA). 53rd Interscience Conference on Antimicrobial Agents and Chemotherapy (ICAAC). Denver, CO, **2013**.