

Complications of small incision lenticule extraction

Mohamed Ibrahime Asif^a, Rahul Kumar Bafna^a, Jodhbir Singh Mehta¹, Jagadesh Reddy², Jeewan Singh Titiyal, Prafulla K Maharana, Namrata Sharma

The procedure of small incision lenticule extraction (SMILE) was introduced in 2011, and since then there has been an increase in the number of cases undergoing this procedure worldwide. The surgery has a learning curve and may be associated with problems in the intraoperative and postoperative periods. The intraoperative problems during SMILE surgery include the loss of suction, the occurrence of altered or irregular opaque bubble layer and black spots, difficulty in lenticular dissection and extraction, cap perforation, incision-related problems, and decentered ablation. Most of the postoperative problems are similar as in other laser refractive procedures, but with decreased incidence. The identification of risk factors, clinical features, and management of complications of SMILE help to obtain optimum refractive outcomes.

Key words: Opaque bubble layer, refractive surgery, retained lenticule, small incision lenticule extraction, SMILE, SMILE complications, suction loss

Small incision lenticule extraction (SMILE) is a flapless femtosecond laser-assisted refractive procedure used for the treatment of refractive errors. It is being increasingly performed as it eliminates the flap-related complications of laser-assisted in-situ keratomileusis (LASIK). Further, it provides better biomechanical strength and has reduced the incidence of dry eye.^[1] Despite these advantages, the technique is more challenging to perform compared to the flap-based procedures and may have various intraoperative and postoperative complications. Early identification and appropriate management of these complications are required for achieving optimal refractive outcomes. In this review, we aim to highlight the risk factors, clinical features, management, and prevention of various intraoperative and postoperative complications of SMILE. [Fig. 1].

Methods

A review of the literature was conducted by searching the following databases: PubMed (United States National Library of Medicine), Embase (Reed Elsevier Properties SA), Web of Science (Thomson Reuters), and Scopus (Elsevier BV). Only peer-reviewed scientific reports were included. Articles in languages other than English were included if the abstract

Department of Ophthalmology, Dr Rajendra Prasad Centre for Ophthalmic Sciences, All India Institute of Medical Sciences, New Delhi, India, ¹Singapore Eye Research Institute, Singapore; Singapore National Eye Centre, 168751, Singapore; Ophthalmology and Visual Sciences Academic Clinical Programme, Duke-NUS Medical School, Singapore, ²Cataract and Refractive Services, Cornea Institute, L V Prasad Eye Institute, Hyderabad, Telangana, India

^aBoth the authors have contributed equally

Correspondence to: Dr. Namrata Sharma, Professor, Department of Ophthalmology, Room- 482, 4th Floor, Dr. Rajendra Prasad Center for Ophthalmic Sciences, All India Institute of Medical Sciences, New Delhi - 110 029, India. E-mail: namrata.sharma@gmail.com

Received: 10-Oct-2020

Revision: 31-Oct-2020

Accepted: 03-Nov-2020

Published: 23-Nov-2020

Access this article online

Website:

www.ijo.in

DOI:

10.4103/ijo.IJO_3258_20

Quick Response Code:



was available in English or if the translated version of the article was available. The literature search used combinations of the following keywords: SMILE complications; small incision lenticule extraction complications intraoperative; postoperative; suction loss; opaque bubble layer; black spots; ablation decentration; dry eyes, diffuse lamellar keratitis; infectious keratitis; ectasia; epithelial ingrowth; PISK; TLSS; residual refractive error; regression.

Intraoperative Complications

The intraoperative complications of SMILE include loss of suction, the formation of the altered opaque bubble layer (OBL), black spots, difficulty in lenticular dissection and extraction, cap perforation, incision-related problems, and decentered ablation [Fig. 1].

Suction loss

The incidence of suction loss during SMILE ranges from 0.9 to 4.4%.^[2,3] However, in recent times, with the use of current software and experienced surgeons, this has reduced to 0.17 to 0.93%.^[3-8] Majority of the cases (>50%) had a suction loss during the creation of the anterior lenticular surface.^[4,5,7,8] The risk factors identified for loss of suction include Bell's phenomenon, anxiety, pain, tears in conjunctival sac, pseudo suction, improper docking, low docking pressure system, and novice surgeon [Fig. 2a].^[5,6,8] Among these, Bell's phenomenon and inappropriate eye fixation contribute to most of the cases.^[8]

This is an open access journal, and articles are distributed under the terms of the Creative Commons Attribution-NonCommercial-ShareAlike 4.0 License, which allows others to remix, tweak, and build upon the work non-commercially, as long as appropriate credit is given and the new creations are licensed under the identical terms.

For reprints contact: WKHLRPMedknow_reprints@wolterskluwer.com

Cite this article as: Asif MI, Bafna RK, Mehta JS, Reddy J, Titiyal JS, Maharana PK, et al. Complications of small incision lenticule extraction. Indian J Ophthalmol 2020;68:2711-22.

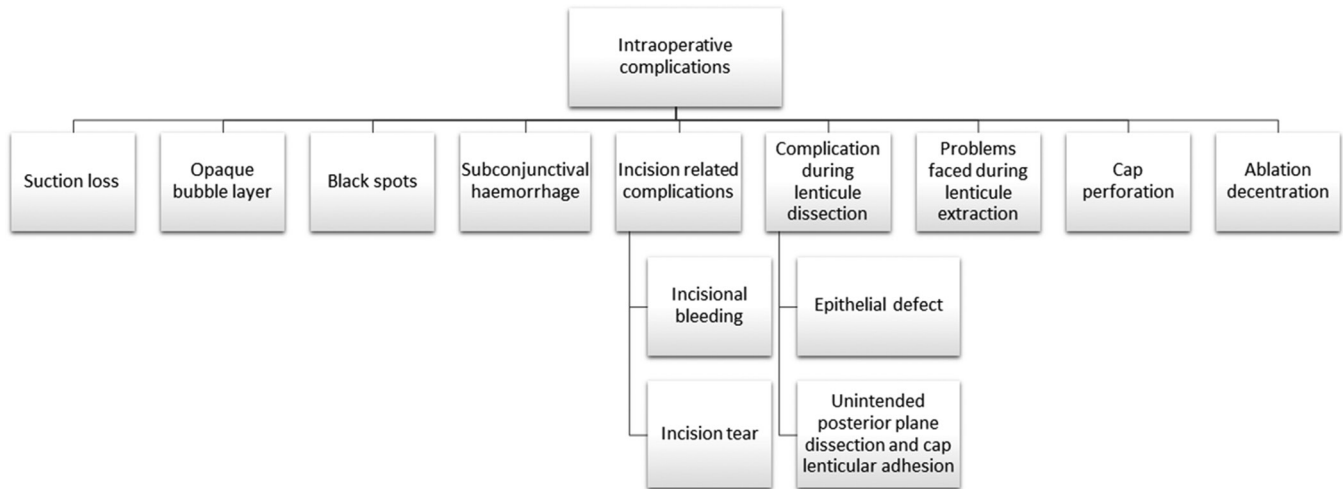


Figure 1: Flowchart of intraoperative complications of SMILE

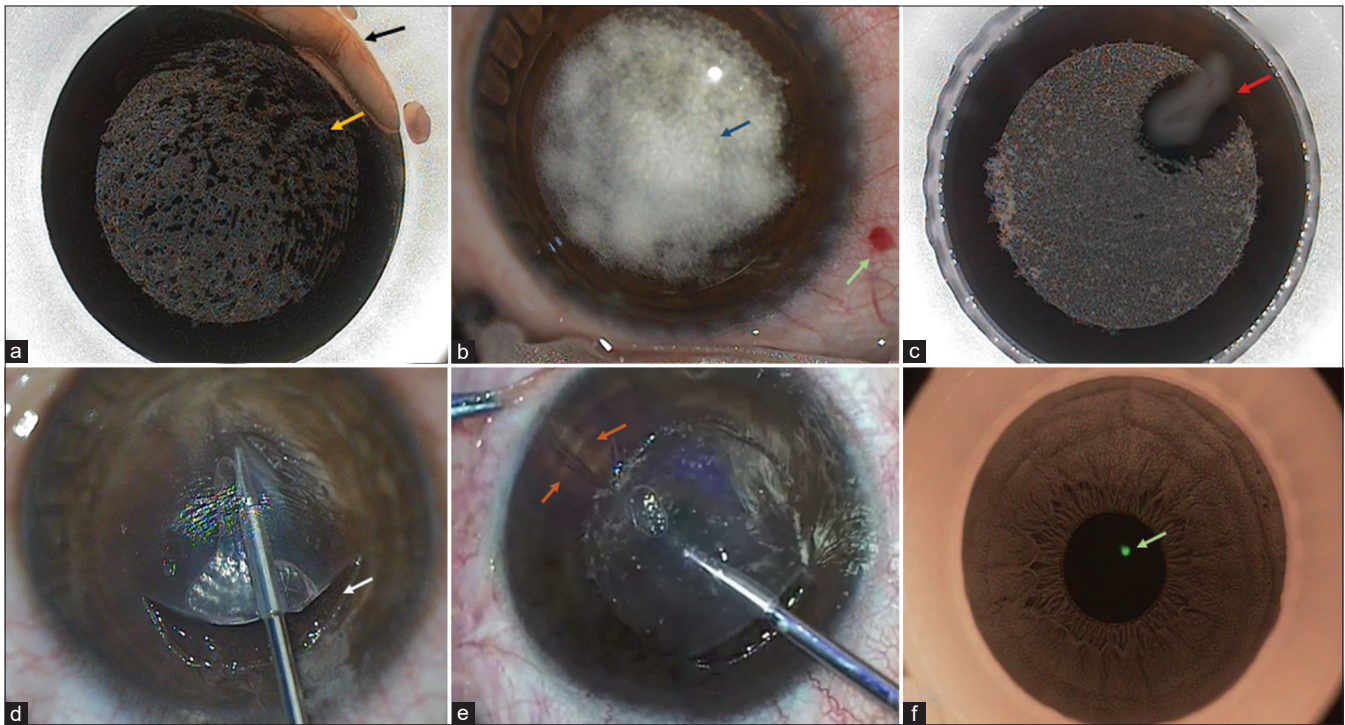


Figure 2: (a) Black spots (yellow arrow) with pseudo suction due to conjunctiva entrapment (black arrow) between the suction cup and cornea (b) OBL (blue arrow) and subconjunctival hemorrhage (green arrow) (c) Black island (red arrow) with cotton fiber between cornea and suction cup (d) Incisional tear (white arrow) (e) Tractional striae (orange arrow) formed in the attempt of pulling adherent lenticule during extraction (f) Decentered coaxial light reflex imaged in infrared mode (green arrow)

Guidelines have been recommended by the manufacturer for the management of suction loss at each surgical step. In cases of suction loss before laser initiation (1st step) or during the creation of <10% of the posterior lenticule surface (2nd step), the retreatment may be done with the same parameters. If the suction loss occurs after the creation of >10% of the posterior lenticule surface, retreatment should be done with decreased cap thickness, or the procedure may be converted to femtosecond-assisted LASIK (FS-LASIK) (3rd step). In cases of suction loss during the creation of lenticular side cut, retreatment is done after decreasing the lenticule diameter by 0.4 mm (4th step); however, if it occurs during the creation of the anterior cap surface or the incision, retreatment may be

done using the same parameters (5th and 6th).^[5] In the event of suction loss after the lenticular side cut, retreatment in the same sitting could result in hyperopic correction due to the shift of the lenticule anteriorly by the gas bubble expansion.^[4] A study done by Gab-Alla *et al.*^[9] demonstrated that the postoperative visual acuity was better if retreatment was done after 24 h rather than immediately in cases where the suction loss occurred after the lenticular side cut. Transepithelial photorefractive keratectomy (PRK) may also be used for retreatment after a suction loss. Chung *et al.*^[10] demonstrated that the visual outcomes were comparable in patients who underwent transepithelial PRK after a suction loss in such cases when compared with cases who had uneventful SMILE surgery.

However, there was a significant increase in higher-order aberrations (HOA), especially a spherical aberration in the transepithelial group. Qin *et al.*^[11] described a novel method for retreatment in patients with suction loss.

Prevention: Proper preoperative counseling of the patients is mandatory to prevent suction loss; further, the contact lens should be clear and the conjunctival surface should be dried with Merocel sponges before suction application.

Opaque bubble layer

The treatment of corneal stroma with the femtosecond laser pulses generates plasma, followed by cavitation which expands and aids in tissue separation. Entrapment of these cavitation bubbles under suction pressure results in the formation of an OBL [Fig. 2b]. In a retrospective study by Wang *et al.*^[7] the incidence of OBL was 0.73% (22/3004 eyes). The risk factors for altered OBL formation are thick cornea, thin lenticule, stiffer cornea, higher laser energy settings, and increased line spacing of laser spots.^[7,12-15] Increased force during docking and repeated docking could also increase the risk of OBL. Ma *et al.*^[14] classified OBL as phase 1 (OBL in the posterior lenticule interface) and phase 2 (OBL in the anterior lenticule interface). OBL poses surgical difficulty to the surgeon in identifying the lenticule edge and at times, may lead to the creation of false planes.

The management includes push-up or push-down techniques to identify the lenticule edge.^[16]

Prevention: Irrigation of ocular surface with a sterile solution to remove debris, followed by instillation of preservative-free artificial tears and removal of excess fluid using Merocel sponge could be used along with a soft docking technique, low laser energy, and deeper lenticule separation to reduce the incidence of OBL.^[14,17]

Black spots

Black spots refer to the occurrence of multiple small black islands of incomplete photo disruption after femtosecond laser and when these spots form a large single confluent black area, it is termed as a black island [Fig. 2a and b]. The incidence of black spot/island ranges from 0.33 to 11% in various studies.^[2,18-21] Unsuccessful photo disruption may be due to the entrapment of debris such as water droplets,^[18] air,^[19] and meibomian or conjunctival mucus secretion^[7] at the interface between the laser coupling device and the corneal surface which blocks the laser. This makes the dissection of the lenticule difficult due to the micro adhesions between the lenticule and the corneal stroma. However, this does not hamper the visual outcomes in these cases. In the event of the occurrence of a black island, the procedure may be aborted.

Prevention: Preoperatively, meibomian gland disease should be treated and intraoperatively it should be ensured that there is no debris on the corneal surface.^[19]

Subconjunctival hemorrhage

Subconjunctival hemorrhage (SCH) occurs due to the disruption of conjunctival blood vessels when high suction pressure is applied. SCH is a rare complication reported in one study with an incidence of 0.67%.^[7]

Treatment includes the application of pressure with sterilized cotton swabs and intraoperative use of vasoconstrictive eye drops [Fig. 2b].

Incision-related complications

Incisional bleeding

The incidence of incisional bleeding varies from 0.93 to 7.45%.^[7,20,21] Eccentric docking of suction cup on the corneal surface and presence of the corneal pannus causes the femtosecond laser pulses to transect the vessels and cause bleeding.

Treatment includes application of pressure with sterilized cotton swabs and intraoperative use of vasoconstrictive eye drops along with balanced salt wash under the corneal cap to reduce visual blurring after surgery.^[7]

Incision tear

The incidence of incision tears varies from 2.09 to 11.05%.^[3,19,21] The higher frequency of this complication may be encountered during the early learning curve. The causes of incision tear are increased manipulation during dissection, smaller incision site, and the strong Bell's phenomenon along with the head movement of the patient while the instrument is still in the interface.^[3,7,21]

A bandage contact lens may be used intraoperatively along with the copious amount of lubricants. Irregular tears with excessive dissection can disrupt the epithelial cells at the site of the tear and maybe a source of epithelial ingrowth [Fig. 2d].

Complications during lenticule dissection

Epithelial defect

Epithelial defects in SMILE may occur at the incision site or in the center. The incidence of incision site epithelial defect varies from 0.17 to 11.25%.^[3,7,19-21] One study reported central epithelial defect in 0.3% of patients.^[3] An epithelial defect may occur in the beginners' hands due to excessive surgical manipulation at the incision site.^[18] However, the presence of an epithelial defect at the incision site has no impact on visual outcome. In patients who had a central epithelial defect, interface inflammation was noted postoperatively.^[3]

Treatment includes the application of a bandage contact lens and the use of copious lubricants.^[3,7,19,21]

Unintended posterior plane dissection and cap lenticular adhesion

Conventionally, the anterior plane of the cap is dissected first, followed by the posterior plane dissection. In the event of unintended posterior plane dissection, identifying lenticule edge becomes difficult which may lead to the creation of false plane or cap lenticular adhesion. The incidence of unintended posterior plane dissection varies between 0.33 to 7%.^[7,19,20] Various signs such as white ring sign, meniscus sign, shimmer sign, and stop sign have been described which help in the identification of the correct plane of dissection.^[22-25] [Table 1].

Kim *et al.*^[26] described a technique where the posterior lenticule plane is separated first using a fan-shaped spatula known as Chung's swing technique. Titiyal *et al.*^[27] described a technique for separation of cap-lenticular adhesion using a Sinsky hook. Urkude *et al.*^[28] described the use of intraoperative optical coherence tomography (OCT) for management of cap lenticule adhesion wherein the edge of the lenticule was lifted from the anterior stroma by direct visualization using intraoperative OCT.

Problems during lenticule extraction

The incidence of problems during lenticule extraction varies from 2.16 to 9%.^[3,19] The lenticule extraction may be difficult due to incomplete photo disruption [Fig. 2e], especially in the

Table 1: Different signs described for identification of the plane of the lenticule during SMILE surgery

Sign	Described by	Time of visualization	Details	Description	Implication
White Ring Sign	Jacob <i>et al.</i> 2016	During dissection of both posterior and anterior planes, the position of the white ring changes	Light reflex from the lenticule side cut is seen in darker iris under oblique illumination	Seen as a white ring posterior to the dissecting instrument during anterior plane dissection and anterior to the instrument during posterior plane dissection	Prevention and detection of unintentional initial posterior plane dissection, thereby preventing lenticule cap adhesions
Shimmer Sign	Shetty <i>et al.</i> 2017	Visible during dissection of the posterior plane	A distinct shining reflection is seen around the instrument as it enters the posterior plane and extends through the length of the instrument as it advances further	Seen as a bright reflex around the dissecting instrument. Not visible during dissection of the anterior plane	Helps in identifying the correct plane of dissection
Meniscus Sign	Titiyal <i>et al.</i> 2018	During delineation of the posterior lamellar plane.	Pushing the lenticule edge away from the surgeon creates a gap between the inner diameter of the cut and the lenticule edge.	Seen as a meniscus shaped gap between the inner cut and the lenticular edge	Provides for easy identification of lenticule edge. Prevents cap lenticular adhesion.
Stop Sign	Sachdev <i>et al.</i> 2020	After delineation of the anterior plane in the right half and posterior plane in the left half	Point of resistance noted at the junction between dissected and undissected halves of both anterior and posterior planes	Subsequent lateral movement of the instrument is difficult (left to right in the posterior plane and right to left in the anterior plane).	Confirms ideal delineation of both planes

Table 2: Various studies depicting the effect of cyclotorsion correction on the refractive outcomes after SMILE

Author; Year	Study	Purpose	Results
Kose <i>et al.</i> ^[112] ; 2020	Retrospective	To evaluate the effect of cyclotorsion compensation with an image-guided system (Callisto) on the visual and refractive outcomes after SMILE	Mean astigmatic error in the cyclotorsion compensated group was significantly lower than the standard group. The combination of the Callisto eye system with a VisuMax laser might be an efficacious and reliable approach to enhance astigmatism treatment
Chen <i>et al.</i> ^[113] ; 2019	Prospective	To evaluate the add-on effect of manual cyclotorsion error correction by the cornea-marking method over standard SMILE	SMILE surgery combined with cyclotorsion error compensation yielded a significant improvement in surgical outcomes regarding safety, efficiency, and predictability for patients with astigmatism.
Xu <i>et al.</i> ^[114] ; 2019	Prospective, double-blinded, RCT which included patients who underwent SMILE. Two eyes of a single patient were randomly divided into the static cyclotorsion compensation (SCC) group and the control group	To compare the clinical outcomes of SMILE with or without cyclotorsion	The ocular rotation in SMILE surgery using a well-controlled position was too small to affect the astigmatic outcomes or postoperative visual quality
Ganesh <i>et al.</i> ^[115] ; 2017	Prospective	To study the safety, efficacy, and outcomes of manual cyclotorsion compensation in SMILE for myopic astigmatism.	Manual compensation may be a safe, feasible, and effective approach to refine the results of astigmatism with a SMILE, especially in higher degrees of cylinders.

RCT- randomized control trial; SMILE- small incision lenticule extraction

hands of novice refractive surgeons. If the lenticule is retrieved successfully, there is no impact on visual outcomes; however, retention of the part of lenticule results in interface haze and may cause refractive surprise. The retained lenticule may be identified by various methods which include the following: use of retro illumination with fully dilated pupil, intraoperative triamcinolone acetate which highlights the edge of the lenticule,^[29] inadvertent entry of air which also delineates the edge of the lenticule, and the application of anterior segment OCT and intraoperative OCT which will identify the edge of the lenticule.

Treatment of lenticule remnant may be done in the same sitting using microscope-integrated OCT-guided lenticule extraction or

as a secondary procedure. This depends on the amount of retained lenticule for partially retained lenticule, topography custom surface ablation, or remnant removal may be done; however, for the complete retained lenticule, PRK, or LASIK may be done.^[19,28,30-32] The CIRCLE software has also been used which converts the cap into the flap and helps in the removal of the retained lenticule.^[29]

Cap perforation

Excessive manipulation of the anterior lenticule during dissection leads to cap tear or cap perforation. The incidence ranges from 0.25 to 4.38%.^[3,7,18-20] The reasons are rough maneuvers by the beginners^[19,21] and the use of sharp instruments^[7] or thick blunt dissectors.^[18]

Treatment is usually conservative as it heals by minimal scarring with little impact on visual outcomes.^[3,19]

Prevention: Gentle dissection and the use of thin blunt dissectors decreases the incidence of this complication.

Ablation decentration

Decentered treatment zone may result in unwanted aberrations and a decrease in visual acuity which may be attributed to the surgeon’s inexperience, intraoperative involuntary ocular drift, and astigmatism of >2.5D [Fig. 2f].^[21,33,34] Many studies attribute the presence of postoperative coma and spherical aberration to decentration. A prospective study by Huang *et al.*^[33] reported that 12.5% of eyes with high astigmatism had visual acuity between 20/20 to 20/40. Out of all the centration zones which have been described, the coaxial sighted corneal light reflex or tear film method is the closest to the visual axis and has better outcomes.^[33-36] Decentration of more than 0.3 mm may cause visual problems.^[33-39]

Despite the lack of eye-tracking in the SMILE system, centration of treatment zone improved with surgical experience and this has been found to have a good correlation when compared with the eye-tracking system in LASIK.^[39,40] Decentration can also be checked immediately after docking, by turning on the infrared mode after the suction is turned on. This helps to have a properly centered ablation.

Prevention: Preoperative marking on slit lamp, in cases of astigmatism more than -1 dioptre can aid in better centration. Besides, some authors have reported the use of triple marking in astigmatic cases.^[41] The incidence of ablation decentration can also be reduced by checking the preoperative angle kappa of the eye and ensuring that the patient is looking into the fixation light. In cases with large angle kappa, the fixation light may appear to be decentered in relation to the pupil center, and it

is not necessary to undock and recenter. In cases with high astigmatism, accurate marking of the limbus at 0–180 degrees may prevent cyclotorsion error.

Postoperative Complications

Various postoperative problems which may occur include dry eyes, diffuse lamellar keratitis, corneal ectasia, epithelial ingrowth, transient light sensitivity syndrome (TLSS), pressure-induced stromal keratitis, interface fluid syndrome, interface debris, and infectious keratitis [Fig. 3].

Dry eyes

Dry eye is the most common complication after LASIK surgery in the early postoperative period though its incidence is lower (95% vs 56% at 1 week) after SMILE surgery.^[42] In most patients who underwent SMILE, the symptoms returned to baseline after 3 months. In a study by Qui *et al.*^[42] the Schirmer test and tear meniscus height post SMILE was found to be increased in the immediate postoperative period but significantly reduced at 1 week and 1 month. Baseline values were achieved at 3-months post-SMILE in contrast to LASIK which had significantly reduced values even at 3 months. This difference could be attributed to the smaller incision, superior incision, and reduced damage to the nerve plexus (leads to reduced impact on corneal sensation and tear production) after SMILE.^[43,44] However, Cetinkaya *et al.*^[45] showed that different incision sizes in SMILE (2-, 3-, 4 mm) had no impact on the dry eye symptoms. The reduced contact area of the suction cup with perilimbal conjunctiva during the SMILE procedure could result in less damage to Goblet cells and mucin production.^[46,47] The amount of negative pressure applied during SMILE is much lower than LASIK causing less damage and surface irregularity to the corneal epithelial cells promoting quick healing with a decreased inflammatory

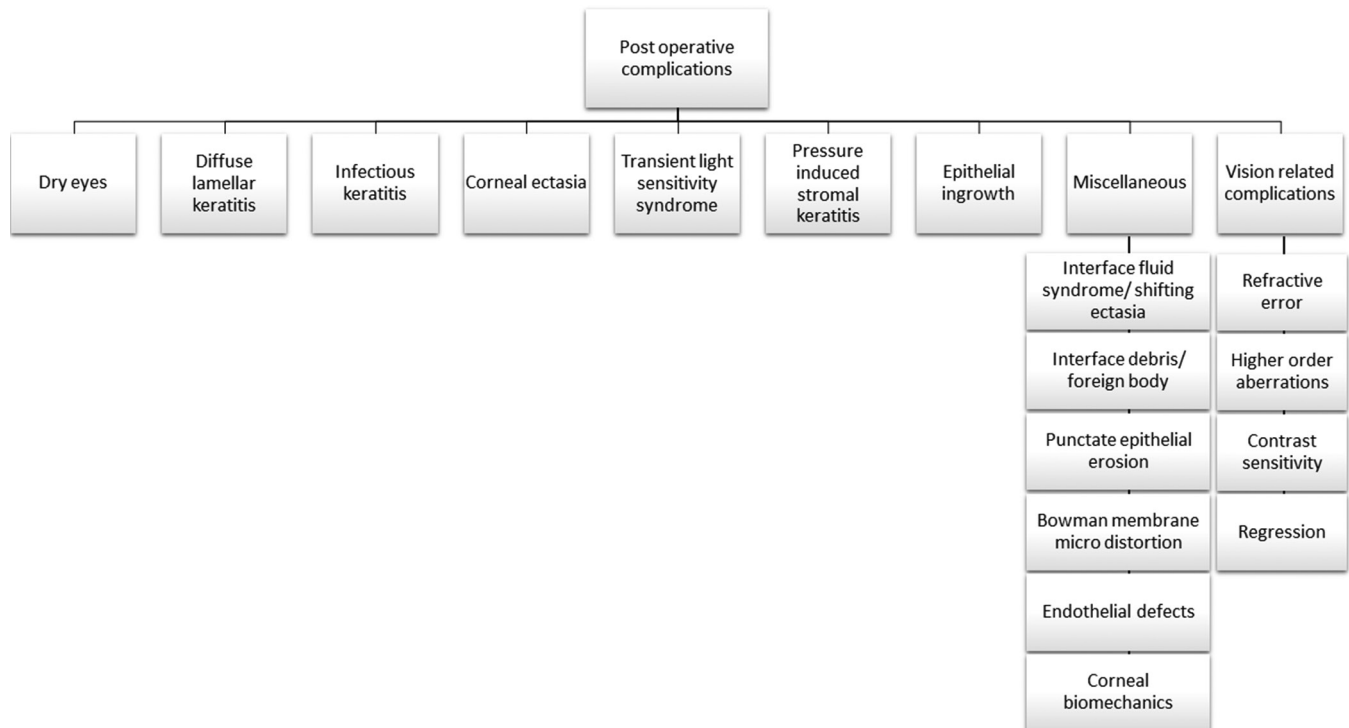


Figure 3: Flowchart of postoperative complications of SMILE

response. Zhang *et al.*^[48] suggested that surface irregularity in post-SMILE affects the tear film stability leading to reduced TBUT with normal Schirmer test.

Prevention: It is important to do a thorough preoperative examination to look for signs and symptoms of dry eyes. SMILE could be advised over LASIK, especially in patients with mild dry eye symptoms if required. Postoperatively preservative-free drops should be prescribed. In patients with severe symptoms, one may consider punctal plugs or low concentration of topical cyclosporine.

Diffuse lamellar keratitis

Diffuse lamellar keratitis (DLK) is a noninfectious inflammatory condition that occurs in the early postoperative period. DLK usually presents within 24–48 h, can range from asymptomatic interface haze in the peripheral edge of the flap to marked diffuse haze involving the center. Clinically, four grades of DLK has been described by Linebarger *et al.* along with appropriate intervention. In a retrospective study by Reinstein *et al.*^[49] the incidence of DLK grade 1 or 2 was 0.45% (18/4000 eyes). Of them, 12 eyes (67%) had a classic appearance and six eyes (33%) presented with sterile multifocal inflammatory keratitis. Similarly, Wang *et al.*^[50] found an incidence of 2.17% among 6373 eyes retrospectively. Although it commonly occurs in the early postoperative period, several reports of late-onset DLK had been described post-LASIK and post-SMILE.^[51,52] Late-onset DLK is usually caused secondary to trauma resulting in epithelial injury.^[52] Though generally the corneal infiltrates are diffusely scattered in the interface, an atypical presentation as multifocal infiltrates has also been described in the literature.^[53] Etiology or pathogenesis of DLK is not clear, yet multiple risk factors have been implicated. Risk factors for DLK include glove talc, marking pen, high energy femtosecond laser, atopy, epithelial defects, chemical toxin, bacterial endotoxin on instruments, and meibomian gland secretions.^[54,55] In a study by Zhao *et al.*^[56] the overall incidence was 1.6%, which was lower than those reported in LASIK. The decreased incidence of DLK in SMILE is due to the high pulse frequency and lower pulse energy used during the procedure which results in decreased tissue injury and inflammatory response. The excimer laser in LASIK stimulates more inflammation which could also possibly contribute to an increased incidence in LASIK over SMILE. SMILE has much smaller incision size with less surface disruption, inflammation and keratocyte apoptosis which was shown in a study by Dong *et al.*^[57] Larger lenticule diameter and thinner lenticules were associated with the development of DLK, possibly due to closer proximity to the limbus which facilitates diffusion of inflammatory cells from limbal vessels. Cap thickness and the incision size were not associated with increased incidence.^[56]

Stage 1 and 2 cases are managed with intensive topical steroid regimen. Follow-up is done at 24–48 h for early identification of cases progressing to Stage 3. More severe inflammation is managed by irrigating the interface along with intensive topical steroids though a study by Gritz *et al.*^[58] who reported good outcomes without irrigation.

Prevention: Preoperatively, a scrupulous wash with a suction cannula attached to special aspiration speculum can aid in a thorough clean-up of meibomian secretions and tear film debris thus decreasing the incidence of DLK. Intraoperative use of powder-free gloves, drape to cover lid margin to avoid lash contact is also a useful measure in prevention of

DLK. During the procedure, tear film debris is avoided from reaching interface. Topical steroids should be judiciously used postoperatively.

Infectious keratitis

SMILE is a much safe and efficacious procedure compared to LASIK due to decreased risk of complications. Infectious keratitis is rare following this procedure and there are few reported cases in the literature. The risk factors are similar to those of LASIK which include dry eye, blepharitis, immunocompromised state, contamination of surgical instruments or surroundings, intraoperative epithelial defect, use of contact lens, retreatment, and trauma.^[59] In a retrospective study by Wang *et al.*^[50] the incidence of corneal infiltrates was found to be 0.39% among 6373 eyes. Chen *et al.*^[60] described a case of intracapsular infection following SMILE which resolved with frequent use of antibiotics and steroids. Steroids were started 3 days after commencing antibiotics. Liu *et al.*^[61] reported a case of bilateral non-tuberculous mycobacterial ulcer post-SMILE with multiple white infiltrates and interface pocket abscess which eventually resolved with topical and oral therapy. A similar case of bilateral infectious keratitis post-SMILE was reported by Chehaibou *et al.*^[62] in which the authors emphasized the importance of sterilization to avoid cross-infection during the surgery.

Immediate interface irrigation with bactericidal agents like povidone-iodine and antibiotic solution is recommended for improvement and better visual outcomes.^[62] Topical antibiotics should be increased in frequency and systemic antibiotics, if required, could be helpful.

Prevention: Preoperative screening and treatment of any ocular surface disorders, using a sterile gown, mask, cap and gloves by surgeon and assistant, proper sterilization of surgical instruments, betadine preparation of lid and eye as performed for cataract surgery, and use of separate instruments for both eyes could decrease the risk of infection.

Corneal ectasia

Postrefractive surgery ectasia is a serious complication causing a decrease in the visual outcome of the patient. Theoretically, SMILE has better biomechanical integrity of the cornea than LASIK because the plane of the lenticule removed is much deeper than in LASIK. Anterior corneal stroma which is physiologically stronger due to strongly interwoven, increased density and steeper angles of the collagen bundles, remains unaltered during SMILE.^[63,64] In a study by Moshirfar *et al.*^[65] four cases (seven eyes) who underwent SMILE and developed ectasia, three of them had preoperative abnormal topography which suggested that any refractive procedure including SMILE might not be suitable for patients with abnormal topography or subclinical keratoconus.

Collagen cross-linking of the cornea is performed in cases with progressive ectasia. Visual rehabilitation can be achieved by refractive correction using spectacles, rigid gas permeable contact lens, or intracorneal ring segments. Large diameter contact lenses/scleral lenses are particularly useful as they do not rest on the corneal surface, thus being more comfortable to the patient with good visual outcomes. Advanced cases may require anterior lamellar keratoplasty.

Prevention: All patients should be screened preoperatively as done for LASIK or PRK. Risk factors such as age, eye rubbing, hormonal influences, thyroid profile etc., must be considered.

Stringent screening criteria for corneal topography also reduces the risk of corneal ectasia.

Transient light sensitivity syndrome

TLSS is a complication particularly associated with the femtosecond laser. It is a rare and minor complication after SMILE. Patients usually present at 2–8 weeks with photosensitivity but good visual acuity and without any signs of inflammation.^[66,67] They have a robust response to steroids. Though the etiology is not known, a migratory phase in which the gas bubbles, cytokines, and cellular debris generated during femtosecond laser move laterally to irritate the ciliary body which results in the classical symptoms.^[66,68] A single case of TLSS post-SMILE has been reported by Desautels *et al.*^[69] It has been suggested that the TLSS incidence is proportional to the energy of the femtosecond laser.

Prevention: Reducing the laser parameters and increasing the postoperative steroid treatment has shown to reduce the occurrence of TLSS.^[66,68]

Pressure-induced stromal keratitis

Pressure-induced stroma keratitis (PISK) or interface fluid syndrome or pressure-induced stromal keratopathy has been reported due to elevation in intraocular pressure (IOP) leading to visible fluid clefts in the interface. It is difficult to diagnose considering its variable presentation. It is often misdiagnosed as DLK, but unlike DLK, it presents usually in the 1st week post-operatively.^[70-72] Patients usually present with worsening vision, pain along with elevated IOP. Interface haze is noted in mild cases while severe cases have fluid clefts in the interface. Elevated IOP secondary to steroid response is the presumed cause for fluid accumulation in the interface. This fluid accumulation could lead to falsely low IOP reading when recorded from the central cornea; therefore, IOP should be measured from the corneal periphery.^[73] Dynamic contour tonometry and tonopen (reading from the peripheral cornea) are superior to Goldman applanation tonometry for these cases. Also, *in-vivo* confocal microscopy (IVCM) shows an absence of mononuclear cells and granulocytes in the interface, unlike DLK. Only two cases of PISK have been reported after SMILE in the literature,^[74,75] both of them have Asian descent with myopia and darkly pigmented iris, which placed them as high risk for developing ocular hypertension and PISK.^[76]

Management includes the lowering of IOP with topical beta-blockers and cessation of steroid therapy. Certain antiglaucoma medications like dorzolamide could affect the endothelial pump function and could exacerbate PISK theoretically. Early diagnosis and appropriate management with antiglaucoma medication is essential to avoid glaucomatous optic neuropathy in these cases.^[73]

Epithelial ingrowth

Epithelial ingrowth occurs when the epithelial cells get implanted in the interface accidentally during surgery or migration of these cells through the incision site in the postoperative period. Since SMILE does not involve corneal flap creation, unlike LASIK, this complication is rare. The patient could present with glare, foreign body sensation or diminution of vision in later stages. Incision/side cut tears, cap rupture, and diabetes could be a potential risk factor for epithelial ingrowth post SMILE.^[77] Few cases of epithelial ingrowth after SMILE have been reported in the literature.^[77,78]

They are usually treated with irrigation of the interface and removal of the epithelial ingrowth using a blunt spatula and micro vitreoretinal forceps followed by suturing of the incision.^[78] A case of recalcitrant epithelial ingrowth which did not respond to the routine management was treated with hydrogel ocular sealant after epithelial scraping.^[77] This hydrogel sealant, to avoid epithelial ingrowth post-LASIK had been described earlier. Postoperatively, topical steroids and antibiotics should be prescribed.

Miscellaneous

Interface fluid syndrome/shifting ectasia: This is a rare complication post SMILE. Bansal *et al.*^[79] reported a case of interface fluid collection after SMILE. There was shifting ectasia (steepening) which was the diagnostic sign for fluid collection. Topical hypertonic saline could be used to treat this condition.

Interface debris/foreign body: Variable incidence of interface debris has been reported in the literature. In a large retrospective study by Wang *et al.*^[50] the incidence was found to be 0.30% among 6373 eyes. It is usually identified postoperatively on slit-lamp examination and should be carefully differentiated from an inflammatory or infectious reaction. The debris could be talc from gloves, fibers from sponges used to dry the ocular surface, metallic particles from instruments, meibomian gland secretion, and eyelash.^[37] Most debris are biodegradable and do not induce any inflammation; hence, can be observed. However, in case it involves the central visual axis or is suspected to cause inflammation, it is managed by irrigation of interface. DLK and irregular astigmatism are complications reported following interface debris.^[54]

Prevention: Proper draping of the eyes to keep the eyelashes away. Meibomian gland secretions should be washed away from the surgical site. Using powder-free gloves, non-fragmenting sponges, proper instruments, and fibrocellulose ring (Chayet ring) could also help prevent any debris during the procedure.

Punctate epithelial erosions: In a retrospective study by Wang *et al.*^[50] the incidence was found to be 0.39% among 6373 eyes. This could be due to the associated dry eye. This could be treated with lubricating eye drops prophylactic antibiotics and mild potent steroids if required.

Bowman's Membrane microdistortions: Bowman's membrane (BM) microdistortions were observed by OCT after SMILE. These microdistortions were common with SMILE rather than FS-LASIK.^[80] They were more common in the inferior quadrant on the 1st day but there was no difference in the long-term follow-up. These distortions were related to increase in lenticule thickness or refractive error correction, however, they had no significant impact on long-term visual outcomes.^[81] Luo *et al.*^[82] found that eyes with >-6D had more microdistortions than those with -3 to -6D (65% vs 30.8%). In a study by Shetty *et al.*^[83] intraoperative cap repositioning was found to reduce the extent of BM microdistortions.

Endothelial effects: Dissection plane of SMILE in the cornea is closer to the corneal endothelium than LASIK and the suction duration during SMILE is twice compared to that of LASIK. Because of the above reasons, there could be a possible endothelial damage post SMILE, but a study by Zhang *et al.*^[84] found no difference in short- and long-term effects on endothelial cells.

Altered corneal biomechanics: Biomechanical property of cornea is majorly important to be considered to reduce the risk of postoperative ectasia. This could lead to underestimation of intraocular pressure in the postoperative period.^[85] Many studies in the literature compared the biomechanical property of LASIK versus SMILE using Ocular Response Analyzer (ORA) and Corvis ST. Using ORA, few studies have found that there was a larger reduction in corneal hysteresis (CH) and corneal resistance factor (CRF) post LASIK than SMILE,^[78,79] especially in the early postoperative period. Various studies concluded CRF was significantly affected after LASIK compared to SMILE^[86-88] whereas few reported no differences.^[89,90]

Few studies reported a comparable biomechanical response after LASIK and SMILE using Corvis ST,^[91,92] however, Osman *et al.*^[93] found significantly less reduction in A1 (first applanation), A2 (second applanation), highest concavity time (HC), time after SMILE compared to LASIK. Pederson *et al.*^[89] concluded that after adjustment for postoperative intraocular pressure, central corneal thickness and age, only HC time was significantly shorter in LASIK than SMILE which suggests LASIK corneas reached the highest concavity earlier (more compliant).

In a study by Kanellopoulos *et al.*^[94] the tensile strength reduction measured using extensimetry was found to be comparable between LASIK and SMILE in higher myopic corrections but less strength reduction in LASIK than SMILE for the low myopic group. This could be explained as SMILE requires removal of more tissue than ablated in LASIK to reach the same correction.

Vision-Related Changes

Various vision-related changes are part of the outcome of any refractive procedure. These includes residual refractive error or induction of residual error due to regression, change in contrast sensitivity (CS), and induction of HOA. These complications would affect the final visual quality of the patient.

Refractive error

In previous studies, LASIK was found superior to SMILE in terms of all visual parameters. Recent studies show comparable outcomes between the two procedures in terms of safety, efficacy, and predictability but the recovery in SMILE is prolonged compared to LASIK.^[95]

In a meta-analysis by Zhang *et al.*^[96] both SMILE and FS-LASIK were comparable in terms of safety and efficacy. In a study by Ganesh *et al.*^[97] 3-month refractive accuracy was found to be better following SMILE compared to LASIK. Qin *et al.*^[81] reported that the visual outcomes showed similar results following SMILE for myopic correction despite the magnitude of refractive error (>-10 D and ≤-10 D). Refractive outcomes showed slightly under-correction in higher myopic eyes. Shetty *et al.*^[98] concluded that the eyes which underwent SMILE tend to be under-corrected compared to LASIK, and this under-correction was greater when the magnitude of preoperative cylinder exceeded 0.75D. Any cyclotorsion during the treatment could result in a shift in the treatment axis, resulting in refractive error and HOA. A simple technique for cyclotorsion compensation in SMILE surgery using an image-guided system has been described by Kose *et al.*^[91] Various studies depicting the effect of cyclotorsion correction on the refractive outcomes after SMILE have been summarized in Table 2.

Induction of higher-order aberrations

HOA in the postoperative period could compromise the visual quality leading to symptoms like glare, haloes, monocular diplopia, and reduced CS.

There are various studies which showed an increase in the HOA post SMILE. Coma and spherical aberration were found to be consistently affected. Induction of coma is associated with the magnitude of decentration and spherical aberration was associated with the magnitude of the dioptric correction.^[99] Large pupil diameter and small Optic zone (OZ) could result in blur circles which, in turn, could result in a poor quality of vision.

Chan *et al.*^[35] found out that the anterior corneal astigmatism affected the treatment centration in SMILE but not in LASIK which lead to induction of coma and total HOA without affecting the lower order aberrations. Xia *et al.*^[100] compared HOA between pre and post SMILE and concluded that the total HOA and vertical coma increased significantly, whereas, no significant differences were found in trefoil and spherical aberration. Jin *et al.*^[101] found there was an increase in total HOA, horizontal coma, spherical aberration, oblique quadrafoil, and vertical secondary astigmatism post SMILE. Spherical aberration increase was higher in the high myopic group compared to those with mild-moderate myopia. In a study by Ji *et al.*^[102] SMILE using femtosecond energy of less than 115 nJ facilitates better visual acuity with less induction of corneal aberrations in the early postoperative period.

Alteration in contrast sensitivity

CS helps in better assessment of patient satisfaction in terms of quality of vision subjectively rather than just a purely objective measurement of HOA. CS may be transiently affected in the initial postoperative period without any significant changes in the long-term follow-ups. Studies have shown that neither the mesopic nor the photopic CS showed any significant changes at 1-year follow-up.^[103]

Regression

Blum *et al.*^[104] evaluated the 10-year results of SMILE for myopia and myopic astigmatism. At 10 years postoperatively, there was no significant change from the 6-month results. Mean spherical equivalent was -0.35 ± 0.66 D which was close to the target refraction. Sixteen of the 56 eyes (29%) had gained one to two Snellen lines. There was no loss of two or more lines in the long term. Regression was -0.35 ± 0.66 D over the 10 years.

Management of Residual Refractive Error

Retreatment after SMILE is required if there is any overcorrection, under correction, or optical regression. The incidence of retreatment following SMILE ranges from 1 to 4%.^[105,106] Major risk factors include high refractive error (>6.0 D), high astigmatism (>3 D), suction loss, and older age (>35 years).^[107] There are various ways of correcting the residual error which includes surface ablation (PRK), LASIK, cap-flap conversion procedure (CIRCLE), and secondary SMILE procedure. PRK, though a simpler procedure, would result in postoperative haze. If the initial cap is thick, then a thin flap LASIK could be considered. However, this could result in flap buttonholes if ultrathin flaps are created. CIRCLE uses Visumax femtosecond laser to make a side cut which converts SMILE cap into LASIK flap. Riau *et al.*^[108] found that flap created using pattern A and D resulted in a

Table 3: Summary of a various meta-analysis published on complications of SMILE

Study; year	Inclusion	Purpose	Results
He <i>et al.</i> ^[116] ; 2015	Five studies involving 245 patients (363 eyes; 189 eyes in the FS-LASIK group and 174 eyes in the SMILE group) were included in the meta-analysis	To evaluate central corneal sensitivity after SMILE versus LASIK for myopia	Central corneal sensitivity exhibited a small decrease and a faster recovery after the SMILE procedure compared to FS-LASIK during the first three postoperative months. Corneal sensitivity after SMILE and FS-LASIK was similar at 6 months after surgery.
Zhang <i>et al.</i> ^[96] ; 2016	Eleven studies from a review of 102 articles, involving a total of 1,101 eyes, of which 532 eyes (48.32%) underwent SMILE and 569 eyes (51.68%) underwent FS-LASIK	Systematic review and meta-analysis to assess possible differences in clinical outcomes	SMILE and FS-LASIK were comparable in terms of both safety and efficacy. SMILE may create fewer dry eye symptoms than FS-LASIK. Corneal sensitivity was greater after SMILE than FS-LASIK.
Shen <i>et al.</i> ^[117] ; 2016	Five cohorts and one RCT were identified for comparing dry eye after SMILE (291 eyes) and FS-LASIK (277 eyes)	To compare postoperative dry eye between SMILE and LASIK	Dry eye after both SMILE and FS-LASIK usually occurs transiently. SMILE does not show obvious superiority over FS-LASIK by exhibiting similar and acceptable objective parameters, and SMILE may have milder subjective symptoms.
Kobashi <i>et al.</i> ^[118] ; 2017	This included 5 prospective comparative studies	To compare postoperative ocular surface integrity and innervation between SMILE and LASIK	SMILE procedure has fewer negative impacts on the ocular surface and corneal innervation than does FS-LASIK. Furthermore, SMILE shows superiority over FS-LASIK by exhibiting a lower risk of postoperative dry eye
Wen <i>et al.</i> ^[119] ; 2017	Forty-eight RCT was identified	To compare the postoperative efficacy, predictability, safety, and visual quality of all major forms of laser corneal refractive surgeries for correcting myopia (FS-LASIK, LASIK, SMILE, FLEX, PRK, LASEK, Epi LASIK, T-PRK)	This network meta-analysis shows that there were no statistically significant differences in either visual outcomes (efficacy and safety) or visual quality (HOAs and CS). FS-LASIK behaved better in predictability than any other type of surgery.
Guo <i>et al.</i> ^[11] ; 2019	Twenty-two studies were included: 5 randomized controlled trials (RCTs), 9 prospective and 6 retrospective cohort studies, and 2 cross-sectional studies	To compare the postoperative corneal biomechanical properties between small incision lenticule extraction (SMILE) and other corneal refractive surgeries	In terms of preserving corneal biomechanical strength after surgeries, SMILE was superior to either FS-LASIK or LASIK, while comparable to FLEX or PRK/LASEK group based on the results from ORA. Corvis ST summary score post SMILE was comparable to FS-LASIK, but more studies need to apply Corvis ST on evaluation.

CS- Contrast sensitivity; FS-LASIK- Femtosecond laser-assisted *in situ* keratomileusis; FLEX-; HOA- Higher-order aberration; LASEK-;

LASIK- Laser-assisted *in situ* keratomileusis; PRK- Photorefractive keratectomy; SMILE- small incision lenticule extraction; T-PRK- Topography-guided photorefractive keratectomy

smooth and undisrupted stromal bed. CIRCLE resulted in more inflammatory and apoptotic changes than secondary SMILE; however, this procedure has been found to be safe and effective with better visual outcome than PRK.^[109] Secondary SMILE could be performed by creation of another pocket anterior or posterior to the original plane. Theoretically, of all the retreatment options, this procedure maintains the biomechanical stability of the cornea.^[110] Various meta-analysis published on complications of SMILE have been summarized in Table 3.

Limitations

There are few limitations for the SMILE procedure. At present, the procedure is not FDA approved for hyperopic and presbyopia correction; however, there are few reports for hyperopic correction which suggests comparable outcomes to LASIK.^[111] Further options for tracking of pupil and iris are not available.

Conclusion

SMILE requires greater technical skill, and it has a steeper learning curve compared to the previous ablative procedures. Hence, in-depth knowledge of various complications, preventive measures, and management is required, which could result in good visual outcomes.

Financial support and sponsorship

Nil.

Conflicts of interest

There are no conflicts of interest.

References

1. Guo H, Hosseini-Moghaddam SM, Hodge W. Corneal biomechanical properties after SMILE versus FLEX, LASIK, LASEK, or PRK: A systematic review and meta-analysis. *BMC Ophthalmol* 2019;19:167.

2. Wong CW, Chan C, Tan D, Mehta JS. Incidence and management of suction loss in refractive lenticule extraction. *J Cataract Refract Surg* 2014;40:2002-10.
3. Ivarsen A, Asp S, Hjortdal J. Safety and complications of more than 1500 small-incision lenticule extraction procedures. *Ophthalmology* 2014;121:822-8.
4. Park JH, Koo HJ. Comparison of immediate small-incision lenticule extraction after suction loss with uneventful small-incision lenticule extraction. *J Cataract Refract Surg* 2017;43:466-72.
5. Liu M, Wang J, Zhong W, Wang D, Zhou Y, Liu Q. Impact of suction loss during Small Incision Lenticule Extraction (SMILE). *J Refract Surg* 2016;32:686-92.
6. Osman IM, Awad R, Shi W, Abou Shousha M. Suction loss during femtosecond laser-assisted small-incision lenticule extraction: Incidence and analysis of risk factors. *J Cataract Refract Surg* 2016;42:246-50.
7. Wang Y, Ma J, Zhang J, Dou R, Zhang H, Li L, *et al.* Incidence and management of intraoperative complications during small-incision lenticule extraction in 3004 cases. *J Cataract Refract Surg* 2017;43:796-802.
8. Reinstein DZ, Archer TJ, Vida RS, Carp GI. Suction stability management in small incision lenticule extraction: Incidence and outcomes of suction loss in 4000 consecutive procedures. *Acta Ophthalmol* 2020;98:e72-80.
9. Gab-Alla AA. Refraction outcomes after suction loss during small-incision lenticule extraction (SMILE). *Clin Ophthalmol* 2017;11:511-5.
10. Chung B, Kang DSY, Kim JH, Arba-Mosquera S, Jean SK, Jun I, *et al.* Clinical outcomes of immediate transepithelial photorefractive keratectomy after suction loss during small-incision lenticule extraction. *J Cataract Refract Surg* 2020;46:756-61.
11. Qin B, Li M, Shen Y, Zeng L, Wang X, Sekundo W, *et al.* Management of suction loss during SMILE in 12,057 eyes: Incidence, outcomes, risk factors, and a Novel method of same-day recutting of refractive lenticules. *J Refract Surg* 2020;36:308-16.
12. Son G, Lee J, Jang C, Choi KY, Cho BJ, Lim TH. Possible risk factors and clinical effects of opaque bubble layer in small incision lenticule extraction (SMILE). *J Refract Surg* 2017;33:24-9.
13. Li L, Schallhorn JM, Ma J, Zhang L, Dou R, Wang Y. Risk factors for opaque bubble layer in Small Incision Lenticule Extraction (SMILE). *J Refract Surg* 2017;33:759-64.
14. Ma J, Wang Y, Li L, Zhang J. Corneal thickness, residual stromal thickness, and its effect on opaque bubble layer in small-incision lenticule extraction. *Int Ophthalmol* 2018;38:2013-20.
15. Ma JN, Wang Y, Song Y, Shao T, Cai Y. [The effect of corneal biomechanical properties on opaque bubble layer in small incision lenticule extraction (SMILE)]. *Zhonghua Yan Ke Za Zhi* 2019;55:115-21.
16. Hamed A, Fekry A. Refractive small-incision lenticule extraction: Push-up and push-down techniques. *J Cataract Refract Surg* 2016;42:1713-5.
17. Koh IH, Seo KY, Park SB, Yang H, Kim I, Nam SM. Enhancement of refractive outcomes of small-incision lenticule extraction via tear-film control. *Graefes Arch Clin Exp Ophthalmol* 2018 Nov; 256:2259-68.
18. Ramirez-Miranda A, Ramirez-Luquin T, Navas A, Graue-Hernandez EO. Refractive lenticule extraction complications. *Cornea* 2015 Oct; 34(Suppl 10):S65-7.
19. Titiyal JS, Kaur M, Rathi A, Falera R, Chaniyara M, Sharma N. Learning curve of small incision lenticule extraction: Challenges and complications. *Cornea* 2017;36:1377-82.
20. Hamed AM, Abdelwahab SM, Soliman TT. Intraoperative complications of refractive small incision lenticule extraction in the early learning curve. *Clin Ophthalmol* 2018;12:665-8.
21. Hamed AM, Heikal MA, Soliman TT, Daifalla A, Said-Ahmed KE. SMILE intraoperative complications: Incidence and management. *Int J Ophthalmol* 2019;12:280-3.
22. Jacob S, Nariani A, Figus M, Agarwal A, Agarwal A. White ring sign for uneventful lenticule separation in small-incision lenticule extraction. *J Cataract Refract Surg* 2016;42:1251-4.
23. Titiyal JS, Kaur M, Brar AS, Falera R. "Meniscus sign" to identify the lenticule edge in small-incision lenticule extraction. *Cornea* 2018 Jun; 37:799-801.
24. Sachdev GS, Ramamurthy S, Dandapani R. Stop sign for correct tissue plane identification in small incision lenticule extraction. *Indian J Ophthalmol* 2020;68:895-6.
25. Shetty R, Negalur N, Shroff R, Deshpande K, Jayadev C. Cap lenticular adhesion during small incision lenticular extraction surgery: Causative factors and outcomes. *Asia Pac J Ophthalmol (Phila)* 2017;6:233-7.
26. Kim BK, Mun SJ, Lee DG, Choi HT, Chung YT. Chung's swing technique: A new technique for small-incision lenticule extraction. *BMC Ophthalmol* 2016 Sep 1;16:154.
27. Titiyal JS, Kaur M, Shaikh F, Sahay P. Double crescentic edge separation for the management of cap-lenticular adhesion in small incision lenticule extraction. *Indian J Ophthalmol* 2020;68:897-9.
28. Urkude J, Titiyal JS, Sharma N. Intraoperative optical coherence tomography-guided management of cap-lenticule adhesion during SMILE. *J Refract Surg* 2017;33:783-6.
29. Ganesh S, Brar S, Lazaridis A. Management and Outcomes of Retained Lenticules and Lenticule Fragments Removal After Failed Primary SMILE: A Case Series. *J Refract Surg*. 2017;33:848-53.
30. Ng ALK, Kwok PSK, Chan TCY. Secondary lenticule remnant removal after SMILE. *J Refract Surg* 2017;33:779-82.
31. Ganesh S, Brar S, Lazaridis A. Management and outcomes of retained lenticules and lenticule fragments removal after failed primary SMILE: A case series. *J Refract Surg* 2017;33:848-53.
32. Titiyal JS, Rathi A, Kaur M, Falera R. AS-OCT as a rescue tool during difficult lenticule extraction in SMILE. *J Refract Surg* 2017;33:352-4.
33. Huang J, Zhou X, Qian Y. Decentration following femtosecond laser small incision lenticule extraction (SMILE) in eyes with high astigmatism and its impact on visual quality. *BMC Ophthalmol* 2019;19:151.
34. Li M, Zhao J, Miao H, Shen Y, Sun L, Tian M, *et al.* Mild decentration measured by a Scheimpflug camera and its impact on visual quality following SMILE in the early learning curve. *Invest Ophthalmol Vis Sci* 2014;55:3886-92.
35. Chan TCY, Wan KH, Kang DSY, Tso THK, Cheng GPM, Wang Y. Effect of corneal curvature on optical zone decentration and its impact on astigmatism and higher-order aberrations in SMILE and LASIK. *Graefes Arch Clin Exp Ophthalmol* 2019;257:233-40.
36. Chung B, Lee H, Roberts CJ, Kang DSY, Reinstein DZ, Jean SK, *et al.* Decentration measurements using Placido corneal tangential curvature topography and Scheimpflug tomography pachymetry difference maps after small-incision lenticule extraction. *J Cataract Refract Surg* 2019;45:1067-73.
37. Melki SA, Azar DT. LASIK complications: Etiology, management, and prevention. *Surv Ophthalmol* 2001;46:95-116.
38. Wong JX, Wong EP, Htoon HM, Mehta JS. Intraoperative centration during small incision lenticule extraction (SMILE). *Medicine (Baltimore)* 2017;96:e0076.
39. Reinstein DZ, Gobbe M, Gobbe L, Archer TJ, Carp GI. Optical zone centration accuracy using corneal fixation-based SMILE compared to eye tracker-based femtosecond laser-assisted LASIK for myopia. *J Refract Surg* 2015;31:586-92.
40. Lazaridis A, Droutsas K, Sekundo W. Topographic analysis of the centration of the treatment zone after SMILE for myopia and comparison to FS-LASIK: Subjective versus objective alignment. *J Refract Surg* 2014;30:680-6.
41. Kang DSY, Lee H, Reinstein DZ, Roberts CJ, Arba-Mosquera S, Archer TJ, *et al.* Comparison of the distribution of lenticule decentration following SMILE by subjective patient fixation or triple marking centration. *J Refract Surg* 2018;34:446-52.
42. Qiu P-J, Yang Y-B. Early changes to dry eye and ocular surface after small-incision lenticule extraction for myopia. *Int J Ophthalmol* 2016;9:575-9.
43. Huang JC-C, Sun C-C, Chang C-K, Ma DH-K, Lin Y-F. Effect of hinge position on corneal sensation and dry eye parameters after

- femtosecond laser-assisted LASIK. *J Refract Surg* 2012;28:625-31.
44. Cai W-T, Liu Q-Y, Ren C-D, Wei Q-Q, Liu J-L, Wang Q-Y, et al. Dry eye and corneal sensitivity after small incision lenticule extraction and femtosecond laser-assisted *in situ* keratomileusis: A Meta-analysis. *Int J Ophthalmol* 2017;10:632-8.
 45. Cetinkaya S, Gulmez M, Mestan E, Ucar F, Ali N. Influence of incision size on dry eye symptoms in the small incision lenticule extraction procedure. *Cornea* 2019;38:18-23.
 46. Battat L, Macri A, Dursun D, Pflugfelder SC. Effects of laser *in situ* keratomileusis on tear production, clearance, and the ocular surface. *Ophthalmology* 2001;108:1230-5.
 47. Mian SI, Shtein RM, Nelson A, Musch DC. Effect of hinge position on corneal sensation and dry eye after laser *in situ* keratomileusis using a femtosecond laser. *J Cataract Refract Surg* 2007;33:1190-4.
 48. Zhang H, Wang Y. Dry eye evaluation and correlation analysis between tear film stability and corneal surface regularity after small incision lenticule extraction. *Int Ophthalmol* 2018;38:2283-8.
 49. Reinstein DZ, Stuart AJ, Vida RS, Archer TJ, Carp GI. Incidence and outcomes of sterile multifocal inflammatory keratitis and diffuse lamellar keratitis after SMILE. *J Refract Surg* 2018;34:751-9.
 50. Wang Y, Ma J, Zhang L, Zou H, Li J, Zhang Y, et al. Postoperative corneal complications in small incision lenticule extraction: Long-term study. *J Refract Surg* 2019;35:146-52.
 51. Li M, Yang D, Chen Y, Li M, Han T, Zhou X, et al. Late-onset diffuse lamellar keratitis 4 years after femtosecond laser-assisted small incision lenticule extraction: A case report. *BMC Ophthalmol* 2017;17:244.
 52. Haw WW, Manche EE. Late onset diffuse lamellar keratitis associated with an epithelial defect in six eyes. *J Refract Surg* 2000;16:744-8.
 53. Stuart A, Reinstein DZ, Vida RS, Archer TJ, Carp G. Atypical presentation of diffuse lamellar keratitis after small-incision lenticule extraction: Sterile multifocal inflammatory keratitis. *J Cataract Refract Surg* 2018;44:774-9.
 54. Segev F, Mimouni M, Sela T, Munzer G, Kaiserman I. Risk factors for sporadic diffuse lamellar keratitis after microkeratome laser-assisted *in situ* keratomileusis: A retrospective large database analysis. *Cornea* 2018;37:1124-9.
 55. de Paula FH, Khairallah CG, Niziol LM, Musch DC, Shtein RM. Diffuse lamellar keratitis after laser *in situ* keratomileusis with femtosecond laser flap creation. *J Cataract Refract Surg* 2012;38:1014-9.
 56. Zhao J, He L, Yao P, Shen Y, Zhou Z, Miao H, et al. Diffuse lamellar keratitis after small-incision lenticule extraction. *J Cataract Refract Surg* 2015;41:400-7.
 57. Dong Z, Zhou X, Wu J, Zhang Z, Li T, Zhou Z, et al. Small incision lenticule extraction (SMILE) and femtosecond laser LASIK: Comparison of corneal wound healing and inflammation. *Br J Ophthalmol* 2014;98:263-9.
 58. Gritz DC. LASIK interface keratitis: Epidemiology, diagnosis and care. *Curr Opin Ophthalmol* 2011;22:251-5.
 59. Chang MA, Jain S, Azar DT. Infections following laser *in situ* keratomileusis: An integration of the published literature. *Surv Ophthalmol* 2004;49:269-80.
 60. Chen M, Li D. Intracapsular infection after small-incision lenticule extraction. *J Cataract Refract Surg* 2018;44:1394-5.
 61. Liu H-Y, Chu H-S, Chen W-L, Hu F-R, Wang I-J. Bilateral non-tuberculous mycobacterial keratitis after small incision lenticule extraction. *J Refract Surg* 2018;34:633-6.
 62. Chehaibou I, Sandali O, Ameline B, Bouheraoua N, Borderie V, Laroche L. Bilateral infectious keratitis after small-incision lenticule extraction. *J Cataract Refract Surg* 2016;42:626-30.
 63. Jester JV, Winkler M, Jester BE, Nien C, Chai D, Brown DJ. Evaluating corneal collagen organization using high-resolution nonlinear optical microscopy. *Eye Contact Lens* 2010;36:260-4.
 64. Seven I, Vahdati A, Pedersen IB, Vestergaard A, Hjortdal J, Roberts CJ, et al. Contralateral eye comparison of SMILE and flap-based corneal refractive surgery: Computational analysis of biomechanical impact. *J Refract Surg* 2017;33:444-53.
 65. Moshirfar M, Albarracin JC, Desautels JD, Birdsong OC, Linn SH, Hoopes PC. Ectasia following small-incision lenticule extraction (SMILE): A review of the literature. *Clin Ophthalmol* 2017;11:1683-8.
 66. Stonecipher K, Ignacio TS, Stonecipher M. Advances in refractive surgery: Microkeratome and femtosecond laser flap creation in relation to safety, efficacy, predictability, and biomechanical stability. *Curr Opin Ophthalmol* 2006;17:368-72.
 67. Haft P, Yoo SH, Kymionis GD, Ide T, O'Brien TP, Culbertson WW. Complications of LASIK flaps made by the IntraLase 15- and 30-kHz femtosecond lasers. *J Refract Surg* 2009;25:979-84.
 68. Muñoz G, Albarrán-Diego C, Sakla HF, Javaloy J, Alió JL. Transient light-sensitivity syndrome after laser *in situ* keratomileusis with the femtosecond laser Incidence and prevention. *J Cataract Refract Surg* 2006;32:2075-9.
 69. Desautels JD, Moshirfar M, Quist TS, Skanchy DF, Hoopes PC. Case of presumed transient light-sensitivity syndrome after small-incision lenticule extraction. *Cornea* 2017;36:1139-40.
 70. Tourtas T, Kopsachilis N, Meiller R, Kruse FE, Cursiefen C. Pressure-induced interlamellar stromal keratitis after laser *in situ* keratomileusis. *Cornea* 2011;30:920-3.
 71. Galal A, Artola A, Belda J, Rodríguez-Prats J, Claramonte P, Sánchez A, et al. Interface corneal edema secondary to steroid-induced elevation of intraocular pressure simulating diffuse lamellar keratitis. *J Refract Surg* 2006;22:441-7.
 72. Nordlund ML, Grimm S, Lane S, Holland EJ. Pressure-induced interface keratitis: A late complication following LASIK. *Cornea* 2004;23:225-34.
 73. Cabral-Macias J, García-De la Rosa G, Rodríguez-Matilde DF, Vela-Barrera ID, Ledesma-Gil J, Ramirez-Miranda A, et al. Pressure-induced stromal keratopathy after laser *in situ* keratomileusis: Acute and late-onset presentations. *J Cataract Refract Surg* 2018;44:1284-90.
 74. Moshirfar M, Somani AN, Vaidyanathan U, Ronquillo YC, Hoopes PC. Pressure-induced interlamellar stromal keratitis after small-incision lenticule extraction procedure: A case report. *Cornea* 2020;39:254-7.
 75. Zheng K, Han T, Li M, Han Y, Xu Y, Shah R, et al. Corneal densitometry changes in a patient with interface fluid syndrome after small incision lenticule extraction. *BMC Ophthalmol* 2017;17:34.
 76. Hiller R, Sperduto RD, Krueger DE. Race, iris pigmentation, and intraocular pressure. *Am J Epidemiol* 1982;115:674-83.
 77. Thulasi P, Kim SW, Shetty R, Randleman JB. Recalcitrant epithelial ingrowth after SMILE treated with a hydrogel ocular sealant. *J Refract Surg* 2015;31:847-50.
 78. Kamiya K, Takahashi M, Shoji N, Naruse S. Two cases of epithelial ingrowth after small incision lenticule extraction. *Am J Ophthalmol Case Rep* 2020;19:100819. doi: 10.1016/j.ajoc.2020.100819.
 79. Bansal AK, Murthy SI, Maaz SM, Sachdev MS. Shifting "Ectasia": Interface Fluid Collection After Small Incision Lenticule Extraction (SMILE). *J Refract Surg* 2016 Nov 1;32:773-5.
 80. Yao P, Zhao J, Li M, Shen Y, Dong Z, Zhou X. Microdistortions in Bowman's layer following femtosecond laser small incision lenticule extraction observed by Fourier-Domain OCT. *J Refract Surg* 2013;29:668-74.
 81. Qin B, Zhao J, Li M, Yao P, Zhou X. The comparison of visual outcomes, aberrations, and Bowman's layer micro-distortions after femtosecond laser small-incision lenticule extraction (SMILE) for the correction of high and moderate myopia and myopic astigmatism. *BMC Ophthalmol* 2019;19:138.
 82. Luo J, Yao P, Li M, Xu G, Zhao J, Tian M, et al. Quantitative analysis of Microdistortions in Bowman's Layer using optical coherence tomography after SMILE among different myopic corrections. *J Refract Surg* 2015;31:104-9.
 83. Shetty R, Shroff R, Kaweri L, Jayadev C, Kummelil MK, Sinha Roy A. Intra-operative cap repositioning in Small Incision Lenticule Extraction (SMILE) for enhanced visual recovery. *Curr Eye Res* 2016;41:1532-8.

84. Zhang H, Wang Y, Xie S, Wu D, Wu W, Xu L. Short-term and long-term effects of small incision lenticule extraction (SMILE) on corneal endothelial cells. *Cont Lens Anterior Eye* 2015;38:334-8.
85. Li H, Wang Y, Dou R, Wei P, Zhang J, Zhao W, *et al.* Intraocular pressure changes and relationship with corneal biomechanics after SMILE and FS-LASIK. *Invest Ophthalmol Vis Sci* 2016;57:4180-6.
86. Xia L, Zhang J, Wu J, Yu K. Comparison of corneal biological healing after femtosecond LASIK and small incision lenticule extraction procedure. *Curr Eye Res* 2016;41:1202-8.
87. Wang B, Zhang Z, Naidu RK, Chu R, Dai J, Qu X, *et al.* Comparison of the change in posterior corneal elevation and corneal biomechanical parameters after small incision lenticule extraction and femtosecond laser-assisted LASIK for high myopia correction. *Cont Lens Anterior Eye* 2016;39:191-6.
88. Wu D, Wang Y, Zhang L, Wei S, Tang X. Corneal biomechanical effects: Small-incision lenticule extraction versus femtosecond laser-assisted laser *in situ* keratomileusis. *J Cataract Refract Surg* 2014;40:954-62.
89. Pedersen IB, Bak-Nielsen S, Vestergaard AH, Ivarsen A, Hjortdal J. Corneal biomechanical properties after LASIK, ReLEx flex, and ReLEx smile by Scheimpflug-based dynamic tonometry. *Graefes Arch Clin Exp Ophthalmol* 2014;252:1329-35.
90. Zhang J, Zheng L, Zhao X, Xu Y, Chen S. Corneal biomechanics after small-incision lenticule extraction versus Q-value-guided femtosecond laser-assisted *in situ* keratomileusis. *J Curr Ophthalmol* 2016;28:181-7.
91. Shen Y, Chen Z, Knorz MC, Li M, Zhao J, Zhou X. Comparison of corneal deformation parameters after SMILE, LASEK, and femtosecond laser-assisted LASIK. *J Refract Surg* 2014;30:310-8.
92. Sefat SMM, Wiltfang R, Bechmann M, Mayer WJ, Kampik A, Kook D. Evaluation of changes in human corneas after femtosecond laser-assisted LASIK and Small-Incision Lenticule Extraction (SMILE) using non-contact tonometry and ultra-high-speed camera (Corvis ST). *Curr Eye Res* 2016;41:917-22.
93. Osman IM, Helaly HA, Abdalla M, Shousha MA. Corneal biomechanical changes in eyes with small incision lenticule extraction and laser assisted *in situ* keratomileusis. *BMC Ophthalmol* 2016;16:123.
94. Kanellopoulos AJ. Comparison of corneal biomechanics after myopic small-incision lenticule extraction compared to LASIK: An *ex vivo* study. *Clin Ophthalmol* 2018;12:237-45.
95. Lau YT-Y, Shih KC, Tse RH-K, Chan TC-Y, Jhanji V. Comparison of visual, refractive and ocular surface outcomes between small incision lenticule extraction and laser-assisted *in situ* keratomileusis for myopia and myopic astigmatism. *Ophthalmol Ther* 2019;8:373-86.
96. Zhang Y, Shen Q, Jia Y, Zhou D, Zhou J. Clinical outcomes of SMILE and FS-LASIK used to treat myopia: A meta-analysis. *J Refract Surg* 2016;32:256-65.
97. Ganesh S, Gupta R. Comparison of visual and refractive outcomes following femtosecond laser-assisted lasik with smile in patients with myopia or myopic astigmatism. *J Refract Surg* 2014;30:590-6.
98. Shetty N, Dadachanji Z, Narasimhan R, Kundu G, Khamar P, Ahuja P, *et al.* Status of residual refractive error, ocular aberrations, and accommodation after myopic LASIK, SMILE, and TransPRK. *J Refract Surg* 2019;35:624-31.
99. Qin B, Li M, Chen X, Sekundo W, Zhou X. Early visual outcomes and optical quality after femtosecond laser small-incision lenticule extraction for myopia and myopic astigmatism correction of over -10 dioptres. *Acta Ophthalmol* 2018;96:e341-6.
100. Xia F, Shen Y, Han T, Zhao J, Xu H, Zhou X. Small Incision Lenticule Extraction (SMILE) for moderate and high myopia: Seven-year outcomes of refraction, corneal tomography, and wavefront aberrations. *J Ophthalmol* 2020;2020:3825864. doi: 10.1155/2020/3825864.
101. Jin H-Y, Wan T, Wu F, Yao K. Comparison of visual results and higher-order aberrations after small incision lenticule extraction (SMILE): High myopia vs. mild to moderate myopia. *BMC Ophthalmol* 2017;17:118.
102. Ji YW, Kim M, Kang DSY, Reinstein DZ, Archer TJ, Choi JY, *et al.* Lower laser energy levels lead to better visual recovery after small-incision lenticule extraction: Prospective randomized clinical trial. *Am J Ophthalmol* 2017;179:159-70.
103. Sekundo W, Gertnere J, Bertelmann T, Solomatin I. One-year refractive results, contrast sensitivity, high-order aberrations and complications after myopic small-incision lenticule extraction (ReLEx SMILE). *Graefes Arch Clin Exp Ophthalmol* 2014;252:837-43.
104. Blum M, Lauer AS, Kunert KS, Sekundo W. 10-year results of small incision lenticule extraction. *J Refract Surg* 2019;35:618-23.
105. Siedlecki J, Luft N, Mayer WJ, Siedlecki M, Kook D, Meyer B, *et al.* CIRCLE enhancement after myopic SMILE. *J Refract Surg* 2018;34:304-9.
106. Reinstein DZ, Carp GI, Archer TJ, Gobbe M. Outcomes of small incision lenticule extraction (SMILE) in low myopia. *J Refract Surg* 2014;30:812-8.
107. Liu Y-C, Rosman M, Mehta JS. Enhancement after small-incision lenticule extraction: Incidence, risk factors, and outcomes. *Ophthalmology* 2017;124:813-21.
108. Riau AK, Ang HP, Lwin NC, Chaurasia SS, Tan DT, Mehta JS. Comparison of four different VisuMax circle patterns for flap creation after small incision lenticule extraction. *J Refract Surg* 2013;29:236-44.
109. Siedlecki J, Siedlecki M, Luft N, Kook D, Meyer B, Bechmann M, *et al.* Surface Ablation versus CIRCLE for myopic enhancement after SMILE: A matched comparative study. *J Refract Surg* 2019;35:294-300.
110. Donate D, Thaëron R. Preliminary evidence of successful enhancement after a primary SMILE procedure with the sub-cap-lenticule-extraction technique. *J Refract Surg* 2015;31:708-10.
111. Reinstein DZ, Pradhan KR, Carp GI, Archer TJ, Day AC, Sekundo W, *et al.* Small incision lenticule extraction for hyperopia: 3-month refractive and visual outcomes. *J Refract Surg* 2019;35:24-30.
112. Kose B, Sakarya Y. A simple technique for cyclotorsion compensation in SMILE surgery. *Cornea* 2020;39:e16.
113. Chen P, Ye Y, Yu N, Zhang X, He J, Zheng H, *et al.* Comparison of small incision lenticule extraction surgery with and without cyclotorsion error correction for patients with astigmatism. *Cornea* 2019;38:723-9.
114. Xu J, Liu F, Liu M, Yang X, Weng S, Lin L, *et al.* Effect of cyclotorsion compensation with a novel technique in small incision lenticule extraction surgery for the correction of myopic astigmatism. *J Refract Surg* 2019;35:301-8.
115. Ganesh S, Brar S, Pawar A. Results of intraoperative manual cyclotorsion compensation for myopic astigmatism in patients undergoing Small Incision Lenticule Extraction (SMILE). *J Refract Surg* 2017;33:506-12.
116. He M, Huang W, Zhong X. Central corneal sensitivity after small incision lenticule extraction versus femtosecond laser-assisted LASIK for myopia: A meta-analysis of comparative studies. *BMC Ophthalmol* 2015;15:141.
117. Shen Z, Zhu Y, Song X, Yan J, Yao K. Dry eye after Small Incision Lenticule Extraction (SMILE) versus Femtosecond Laser-Assisted *in Situ* Keratomileusis (FS-LASIK) for myopia: A meta-analysis. *PLoS One* 2016;11:e0168081.
118. Kobashi H, Kamiya K, Shimizu K. Dry eye after small incision lenticule extraction and femtosecond laser-assisted LASIK: Meta-analysis. *Cornea* 2017;36:85-91.
119. Wen D, McAlinden C, Flitcroft I, Tu R, Wang Q, Alió J, *et al.* Postoperative efficacy, predictability, safety, and visual quality of laser corneal refractive surgery: A network meta-analysis. *Am J Ophthalmol* 2017;178:65-78.