

Hybrid Transvaginal NOTES and Mini-Laparoscopic Colectomy: Benefit Through Synergy

Jayson M. Moloney, MBBS, Philip S. L. Gan, MBBS

ABSTRACT

Background and Objectives: Hybrid-natural orifice surgery combines the advantages of traditional transabdominal laparoscopic surgery, while limiting surgical trauma to the abdominal wall. Among various routes of intra-abdominal access, the transvaginal method is most appealing because of its utility and proven safety. We describe a series of 4 colonic resections performed with this approach, combined with minilaparoscopy and needlescopic approaches, and discuss the technical aspects, efficacy, and applicability of this technique.

Methods: Three patients were selected to undergo hybrid transvaginal natural-orifice right hemicolectomy. A fourth patient, who underwent a segmental resection of a splenic flexure carcinoma, was included. Transvaginal port access was obtained via posterior colpotomy, and was used for dissection, vascular ligation, bowel division, and anastomosis. We used a combination of standard laparoscopic, minilaparoscopic, and needlescopic instruments transabdominally, focusing on reduced size and number of access points.

Results: Duration of laparoscopy, oncologic outcomes and rate of operative morbidity were comparable to the published literature. Early return of gastrointestinal function and low analgesic requirements was observed in all patients. No morbidity related to transvaginal access was observed and the procedure was performed without difficulty in all cases.

Conclusion: Colonic resection performed by hybrid natural-orifice technique offers several advantages over purely transabdominal laparoscopic procedures. Trans-

vaginal access is easy to perform and offers excellent safety, efficacy, and versatility, especially for right hemicolectomy. Techniques to reduce abdominal wall surgical trauma, such as minilaparoscopy and needlescopic graspers, can be combined effectively in colonic resections, and may act synergistically to reduce postoperative pain and improve outcomes.

Key Words: Colectomy, Colpotomy, Natural-orifice endoscopic surgery, Treatment outcome.

INTRODUCTION

Natural-orifice transluminal endoscopic surgery (NOTES) is a continually evolving field in gastrointestinal surgery and has significant potential to improve patient outcomes. Pure NOTES (total avoidance of abdominal incisions) procedures have been performed for cholecystectomy, appendectomy, ventral hernia repair, and colectomies, among others. There is evidence to suggest improved cosmesis,^{1,2} without significant added morbidity or adverse effect on outcomes. Anecdotal evidence points toward a reduction in postoperative pain, but this outcome has not been proven in a randomized trial.³ In standard transabdominal laparoscopic surgery, the specimens must be removed through an extended incision. NOTES procedures avoid this limitation, helping to obviate the risk of wound infection and incisional hernia. Pure NOTES, however, brings with it limitations of access and loss of triangulation.

Natural orifice specimen extraction (NOSE) can be used as an adjunct to conventional transabdominal laparoscopic procedures and has been shown to be safe and effective in several case series in the literature using the transvaginal, transrectal, transanal, or transgastric routes.^{4,5} Transvaginal access to the abdomen and pelvis was described and used routinely by gynecologists long before the advent of laparoscopic surgery.^{6,7} After the description of transvaginal access for specimen extraction over 20 years ago, contemporary data demonstrating its safety and validity for this purpose continue to emerge.⁸

Hybrid NOTES (natural-orifice surgery with adjunctive transabdominal access) is an attempt to bring together the

Department of General Surgery, Barwon Health, Geelong, Victoria, Australia (Dr Moloney).

Department of General Surgery, Southwest Healthcare, Warrnambool, Victoria, Australia (Dr Gan).

Financial support: none.

Address correspondence to: Jayson M. Moloney, MBBS, 41 Durham Street, Newington, Victoria 3350, Australia. Phone: +61 400 511 780, Fax: +61 3 5562 9527, E-mail: jayson.moloney@gmail.com

DOI: 10.4293/JSLS.2016.00062

© 2016 by JSLS, *Journal of the Society of Laparoendoscopic Surgeons*. Published by the Society of Laparoendoscopic Surgeons, Inc.

advantages of transabdominal incisions, such as visualization and triangulation, while allowing these incisions to be minimized by virtue of the natural-orifice port and specimen extraction. The abdominal incisions can be minimized further with the use of minilaparoscopic and needlescopic instruments, with potential synergy from using this combination of approaches. In comparison to NOSE and pure NOTES in colorectal surgery; however, the literature surrounding hybrid NOTES is confined to very small case series; hence, a standardized operative approach is yet to be proposed and further data are needed to assess potential benefits.

We report a series of 3 hybrid transvaginal NOTES right hemicolectomies and 1 segmental resection of splenic flexure carcinoma performed by a single surgeon at our institution. Although the initial intent was to confine our series to right hemicolectomies, the significant comorbidities, advanced age and frailty of a patient with splenic flexure carcinoma were such that the most minimally invasive approach possible was vital. The patient was therefore included in this series and presents interesting considerations for discussion.

METHODS

Four suitable elective patients were identified (**Table 1**). Informed consent for potential use of the transvaginal approach was obtained in each case, the criteria being female gender, intact uterus, limited abdominal surgical history, and normal body mass index (BMI). Vaginal examination to assess suitability and safety of this route of access was performed on-table. The surgeon had 12 years of experience in laparoscopic colorectal resections and had been performing selected NOSE procedures in these for more than 2 years, initially in conjunction with a gynecologist. Surgeries were performed between 1 April and 11 May, 2016.

All patients were positioned in the lithotomy position. Skin preparation was performed using 70–1% alcohol-chlorhexidine solution for the abdomen, and 10% povidone-iodine solution for the vagina. In all cases, pneumoperitoneum was established by a through-umbilicus open cutdown technique with an Applied Medical (Rancho Santa Margarita, California, USA) 5-mm Kii Balloon Blunt Tip port. Two further transabdominal access sites were added, in which a variable combination of access ports was used: a Teleflex MiniLap Clutch percutaneous 2.3-mm grasper; Karl Storz (Tuttlingen, Germany) 3.5-mm port; or a 5-mm Versaport Bladeless Trocar (Covidien-Medtronic, Minneapolis, Minnesota, USA) (**Table 2**).

In all cases, transvaginal access was achieved by the method described by Clark et al.⁹ The posterior lip of the cervix was grasped with a Teale-Vulsellum (INKA Surgical Instruments, Jandakot, Western Australia) forceps and retracted anteriorly. Two 0 Vicryl (Ethicon, Somerville, New Jersey, USA) stay sutures were placed in the posterior fornix at either end of the wound, using a Finocchio needle holder which aided in visualization and closure. A small transverse posterior colpotomy was then performed with diathermy dissection, and a VersaStep Plus Long Insufflation/Access Needle with Radially Expandable Sleeve (Medtronic-Covidien) was introduced under direct laparoscopic vision, followed by insertion of the matching VersaStep Plus Long 12-mm Cannula and Dilator through the sleeve (**Figures 4** and **5**). The stay sutures on the posterior fornix were secured around the loops on the cannula head to prevent dislodgment. This port facilitated the introduction of the Endo GIA Universal Stapler and reloads as well as standard laparoscopic (graspers) and LigaSure instruments (all from Medtronic-Covidien). A medial-to-lateral approach was used for the right hemicolectomies. A right-side-up position was used to allow the

Table 1.
Patient Characteristics

	Age	BMI (kg/m ²)	ASA Grade	Prior Abdominal Surgery
Patient 1	45	24.7	I	Laparoscopic salpingectomy
Patient 2	63	21.7	II	Open cholecystectomy (right subcostal incision); laparoscopic tubal ligation
Patient 3	88	15.6	III	Open appendectomy (right transverse incision) for perforated appendicitis
Patient 4	41	19	I	Nil
Mean (range)	59 (41–88)	20.3 (15.6–24.7)		

ASA, American Society of Anesthesiologists.

Table 2.
Intraoperative and Postoperative Details and Outcomes

	Operation Performed	Access Ports	Duration of Laparoscopy (minutes)	Length of stay (days)	Postsurgical Morbidity
Patient 1	Right hemicolectomy	5-mm intraumbilical 3.5-mm KS port (LIF); 2.3-mm MiniLap Clutch (epigastrium); 12-mm posterior fornix	150 (including laparoscopic cholecystectomy)	4	Nil
Patient 2	Right hemicolectomy	5-mm intra-umbilical 3.5-mm KS port (LIF); 3.5-mm KS port (RUQ); 12-mm posterior fornix	143	3	Nil
Patient 3	Segmental resection of transverse colon	5-mm intra-umbilical 3.5-mm KS port (RIF); 3.5-mm KS port (epigastrium); 12-mm posterior fornix	267	8	Urinary retention; anastomotic bleeding
Patient 4	Right hemicolectomy	5-mm intra-umbilical 5-mm (LIF); 2.3-mm MiniLap™ Clutch (epigastrium); 12-mm posterior fornix	123	2	Nil
Mean			171	4.25	

Table 3.
Pathology

	Tumor Size	Tumor Location	Proximal Margin (cm)	Distal Margin (cm)	Lymph Node Yield (n)	Histological Differentiation	Tumor Stage
Patient 1	4-mm focus in 13-mm polyp	Ascending colon	1.5	>10	23	Moderate-poor	pT1 N0
Patient 2	3.8 × 3.8 cm	Ascending colon	5	8	20	Well	pT3 N0
Patient 3	2.5 × 2.4 cm	Distal transverse colon	7	11	4 (palliative resection)	Moderate	pT3, N1 (2/4)
Patient 4	High-grade dysplasia in tubular adenoma	Ascending colon	8	>12	8	High-grade dysplasia only	N/A

small bowel to drop away from the ascending colon. The most superior grasper (Teleflex Clutch or mini-laparoscopic grasper) was used to retract the mesenteric border of the mid ascending colon, to expose the right colic vessels. These were cleared near the origin with hook diathermy, then transected with an Endo GIA white (2.5 mm) vascular stapler (Medtronic-Covidien). The plane between the right mesentery and retroperitoneum was then developed, and the ileocolic vessels were followed to the distal ileum, dividing the mesentery with a combination of diathermy and LigaSure. The right branch of middle colic vessels was then separated with LigaSure, dividing the mesentery to the proximal transverse colon.

The greater omentum was dissected from the proximal transverse colon with LigaSure. A lateral mobilization was performed with a combination of diathermy and Ligasure dissection, taking down the hepatic flexure. Upon complete mobilization of the right colon, the distal ileum and proximal transverse colon were each divided with a 60 × 3.5-mm stapler. After transection of each end of the resected bowel, the 2 limbs to be joined were aligned side by side with a continuous seromuscular absorbable 3-0 V-Loc suture (Medtronic-Covidien). An enterotomy was then made in each limb, and a stapled side-to-side anastomosis was performed, with laparoscopically sutured closure of the enterotomies using 3-0 15-cm V-Loc absorb-

able, full-thickness sutures (Medtronic-Covidien). This technique allowed for easier introduction of the Endo GIA into the bowel from the trajectory of the transvaginal port, as it required less angulation and articulation than a totally stapled technique. Furthermore, the resected specimens were free of enterotomies, preventing potential spillage during extraction. The anastomosis was routinely inspected for bleeding, but no leak test was performed, as insufflation of the segment would have required on-table colonoscopy. For specimen extraction, an extra-small Alexis wound-protecting retractor (Applied Medical) was inserted into the posterior colpotomy by grasping the lip of the internal part of the retractor ring with a laparoscopic Babcock grasper alongside an S-retractor which had been already inserted into the colpotomy. The 12-mm Versaport was then inserted through the Alexis wound retractor, sealing the CO₂ leak by hand. This method made insertion of the laparoscopic Babcock into the pelvis easier for specimen grasping. Specimen extraction was performed with ease in all cases and without the use of an endoscopic retrieval bag (Figure 6). The posterior colpotomy was closed with interrupted 0 Vicryl full-thickness sutures in each case. The stay sutures facilitated good exposure for placement of the closure sutures. No peritoneal drains were inserted. The linea alba was closed with a 0 Vicryl interrupted suture, and 5-mm incision wounds were closed with interrupted 3-0 Monocryl (Ethicon) sutures. The minilaparoscopic or needlescopic wounds did not require suturing and were closed with adhesive tape. Each of the 4 patients was cared for by using Enhanced Recovery After Surgery (ERAS) principles,¹⁰ which allows a light ward diet as tolerated on the same day of surgery, removal of the urethral catheter on day 1 after surgery, and a graduated reduction in intravenous fluid support balanced against oral intake.

RESULTS

No recruited patients were later excluded because of inability to gain transvaginal access. All patients passed flatus on day 1 after surgery and had bowel action by day 2 or 3. None developed an ileus, and only the 88-year-old patient failed her initial trial of voiding, but was successful on the second attempt. All patients were comfortable on oral analgesia alone from day 1, typically with regular paracetamol (acetaminophen) supplemented with oxycodone on request. None required parenteral narcotic analgesia from day 1 onward, and no discharge medications were provided for Patient 4 who went home on day 2 after her right hemicolectomy.

Patient characteristics are summarized in **Table 1**, and tumour characteristics are summarised in **Table 3**. All tumors in patients undergoing right hemicolectomy were located in the ascending colon. The tumor in Patient 3 was at the splenic flexure. This patient underwent a segmental resection. Three of 4 patients had undergone abdominal surgery. Notably, 2 patients had undergone open surgery (1 cholecystectomy and 1 appendectomy for perforated appendicitis). Intra-abdominal adhesions were encountered in both patients, necessitating adhesiolysis, which did not significantly prolong the operative time. Two patients had undergone laparoscopic pelvic surgery.

Operative detail, postoperative recovery, and outcome data are summarized in **Table 2**. Transvaginal access was easily achieved in all cases. The mean duration of laparoscopy was 171 minutes, which included a combination of right hemicolectomy and laparoscopic cholecystectomy in Patient 1. Mean length of stay was 3 postoperative days for the right hemicolectomies.²⁻⁴ All patients passed flatus within 2 days and opened their bowels by day 3.

No vaginal morbidity or pelvic organ injury was observed in any of the cases. Urinary retention in the 88-year-old patient required catheterization for 24 hours. In the same patient, who had very poor tissue strength, rectal bleeding occurred on postoperative day 7 which required transfusion of 2 units of packed blood cells. Cosmetic outcomes are shown in **Figures 1-2**.

DISCUSSION

The recovery of all 4 patients was notable for minimal analgesia requirements from day 1 after surgery and rapid progression to passage of flatus. The length of stay of the patients who underwent right hemicolectomy dropped

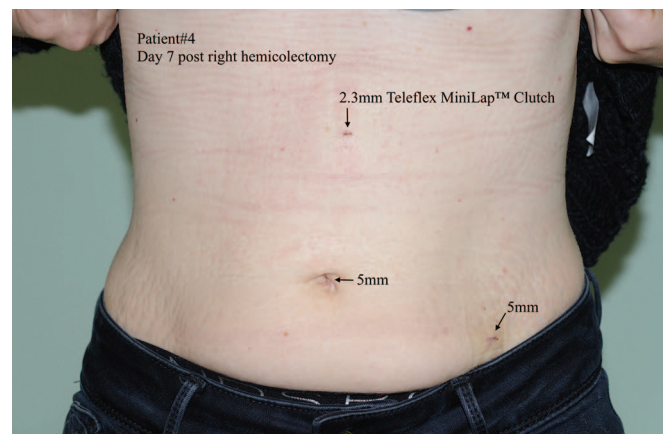


Figure 1. Postoperative photograph, Patient 1.

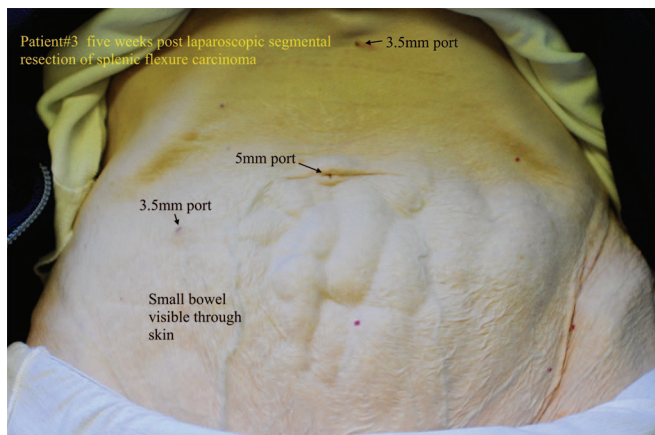


Figure 2. Postoperative photograph, Patient 3.

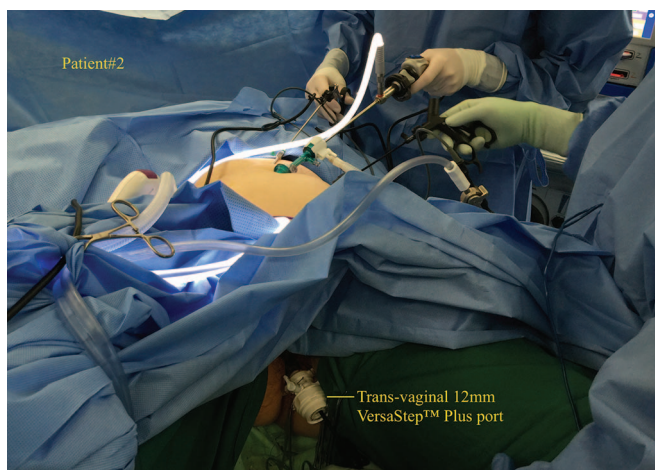


Figure 3. Intra-operative photograph, Patient 2.

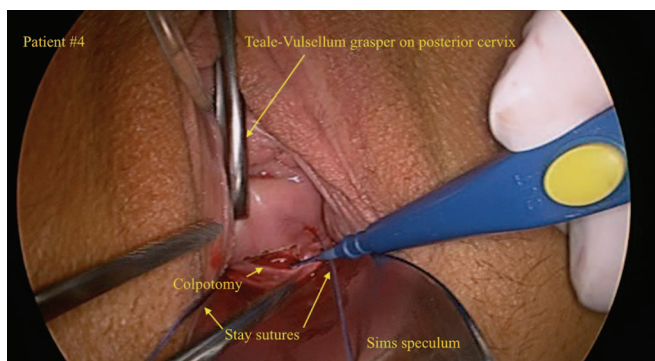


Figure 4. Performing the posterior colpotomy.

sequentially from 4 to 3 d, then to 2 d after surgery, partly reflecting the increasing confidence in early discharge with experience. Although this was not a randomized comparative study, the minimal analgesia requirements,

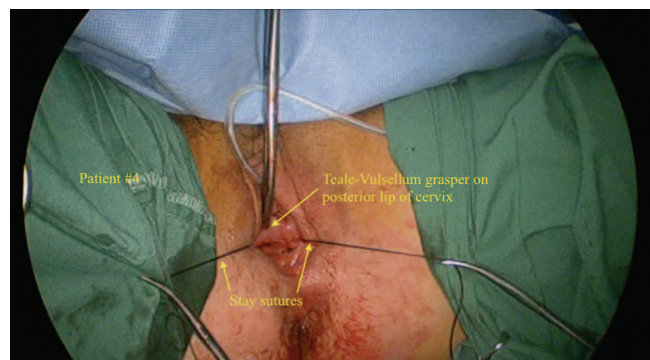

Figure 5. Completed posterior colpotomy.

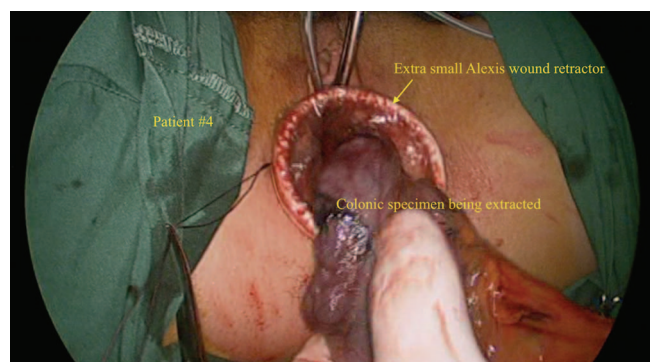


Figure 6. Transvaginal specimen extraction.

early return of bowel function and length of stay were well within the norms for this procedure compared with published data,¹¹ and favorable compared with the author's anecdotal institutional experience. A randomized trial between conventional laparoscopic and hybrid transvaginal NOTES right hemicolectomy would be valuable in addressing these questions and should address not only the cost of healthcare delivery but also quality of life and patient satisfaction measures.

It is worth noting the different focus on recovery by comparing Patients 1 and 3. Patient 1 was a fit 45-year-old woman who was eager to return to her sport (rowing) after her surgery, whereas Patient 2 was an 88-year-old woman with exceedingly thin abdominal wall tissues (as little as 1.8 mm on computed tomographic scan), who represented a group of patients at very high risk of wound dehiscence or incisional hernia from a laparotomy or extended laparoscopic incision for abdominal wound extraction (**Figure 3**). Both of these patients only had one 5-mm abdominal (umbilical) port. Patient 1 was able to return rapidly to normal activities, and the risk of abdominal wall complications was potentially averted in Patient 2. Notably,

the frail 88-year-old patient returned to independent living in her own home, without any wound-related morbidity.

As shown in **Table 2**, a combination of minilaparoscopic 3.5-mm (Karl Storz) and 5-mm ports, as well as needle-scope portless graspers (Teleflex Clutch), was used in various combinations. In the 2 cases where the Teleflex MiniLap Clutch was used as a tissue grasper, it was found to be effective, whether in combination with the Karl Storz instruments (Patient 1) or with the standard laparoscopic instruments (Patient 4). In Patients 2 and 4, Karl Storz minilaparoscopic 3.5-mm instruments were used for all transabdominal grasping, dissecting, and anastomotic suturing and were found to be effective in all these roles.

Although no statistically significant conclusions can be drawn, the operative time and morbidity rates of our small series are comparable to those of the literature for conventional laparoscopic colonic resection.^{12,13} Notably, Patient 3 was an elderly woman who underwent a palliative segmental resection of a splenic flexure tumor, rather than an extended right hemicolectomy, in view of advanced age, poor tissue strength, and comorbidities. As a result, lymph node yield was expected to be low in this nononcological resection. Patient 4 had a full oncological resection despite her benign histology, yet had an unexpectedly low lymph node yield. Her specimen had been sent to another pathology service because of unavailability of the institution's usual pathologist.

The transvaginal route for NOTES offers advantages for colonic resections. Large specimens can be extracted without the need for a potentially large abdominal incision. Because of the elasticity of the vagina, successful transvaginal extraction of specimens up to 19 cm in size have been reported in the literature—commonly up to 10 cm diameter, via posterior colpotomy.^{9,14,15} Transvaginal NOTES appears to be the most advantageous route for colonic resections where transanal extraction would require a separate rectal colotomy, particularly for right hemicolectomy (or extended right hemicolectomy) and including limited resections in this territory.

Evidence suggests a significant reduction in postoperative pain when the transvaginal route is used. The posterior fornix of the vagina has relatively little innervation, and reduced postoperative pain scores and analgesic requirements have been demonstrated in randomized, controlled trials of transvaginal NOSE versus conventional transabdominal specimen extraction.^{16,17} Studies comparing cosmetic outcomes of transvaginal and transabdominal specimen extraction have shown superior patient satisfaction with the transvaginal approach.^{18,19} The transvaginal

NOTES approach does not carry the same concerns of opening hollow organs (stomach, rectum, bladder) that other NOTES techniques engender, and should be considered separately from those.

Rates of morbidity relating to transvaginal access appear acceptable. Possible local vaginal complications include bleeding, vaginal infection, herniation, and organ injury. Such complications range from 0 to 8% in the reported gynecologic literature and are most commonly vaginal infections treated with oral antibiotics.^{15,20,21} The risk of herniation of abdominal contents after posterior colpotomy appears very low. It has not been reported in any of the larger gynecologic case series or more contemporary NOTES trials.^{15,17,20–22} Despite concerns regarding bacterial seeding of the abdominal cavity by opening a natural orifice, infection rates appear comparable to those of the transabdominal approach, and no strong evidence from bacteriological studies supports these fears. Impact on female sexual function is worthy of strong consideration. Postoperative dyspareunia is reported in 0–6.3% of patients after transvaginal NOTES,²³ but randomized trials have shown no difference in the incidence of dyspareunia or return to sexual activity compared with transabdominal laparoscopic procedures.^{18,24–26} While injury to the rectum, bowel, pelvic organs, or vasculature with insertion of instruments via vaginal access ports is possible, the risk appears negligible if the procedure is always performed under direct laparoscopic vision.

The posterior fornix approach to the pelvis has a long and safe history in gynecology, and any resistance among colorectal or general surgeons to using this technique may reflect a lack of exposure during training. Despite the pioneering work of Bergamaschi et al.²⁷ with colonic intracorporeal anastomosis, colorectal anastomoses are still frequently performed extracorporeally. In this regard, it is worth noting that upper gastrointestinal and bariatric surgeons routinely use totally intracorporeal anastomotic techniques. Cross-pollination between specialties can only increase the broader skill set of all concerned.

The purpose of our small observational case series was to explore the potential advantages of hybrid NOTES colonic resections over other techniques with respect to right hemicolectomy. In this context, hybrid NOTES has the potential for a compounding beneficial effect on patient outcomes. These include reducing surgical trauma, associated pain, and narcotic requirements; (2) improving cosmesis; (3) increasing the uptake of natural orifice surgery; and (4) cost savings. Surgical trauma can be reduced by the use of the transvaginal port for mobilization, pedicle

ligation, and totally intracorporeal anastomosis, in addition to specimen extraction, thereby facilitating a reduction in the size and number of transabdominal ports required. In our series, the hybrid NOTES approach allowed the use of transabdominal ports of a maximum of 5 mm, compared to the conventional transabdominal approach, which requires at least one 12-mm port. Only 3 small transabdominal incisions were needed in all cases. Pure NOTES procedures rely on dedicated, costly instruments and platforms to be performed safely and effectively. Training of the surgeon is arduous, and similar training requirements are placed on surgical assistants and operating theatre staff. The use of standard laparoscopic rigid instruments in hybrid NOTES avoids the need for experience with, and access to, the articulating instruments necessary for pure NOTES procedures, perhaps broadening the access to NOTES among minimally invasive surgeons.

The use of minilaparoscopic and needlescopic instruments in our case series helps to demonstrate their utility in laparoscopic colorectal surgery. Conversion to standard laparoscopic instruments was not required in any of our cases, and our mean operative time was comparable to that of conventional laparoscopic colectomy in the published literature.¹²

The benefits of minilaparoscopy include reduced postoperative pain and improved cosmesis, which have been evaluated in several comparative studies, predominantly with regard to cholecystectomy. A trend toward reduced postoperative pain has been shown in comparative studies.^{28–31} Statistical significance, however, has not been shown. Comparative studies evaluating cosmetic outcomes have shown similar findings.³¹ Carvalho et al.³² also make note of the lack of uniformity of positive results among those trials showing a trend toward reduction in postoperative pain. Some systematic reviews have concluded that, while the proven benefit on postoperative pain and cosmesis remains marginal, further evaluation to quantify the potential advantages is still needed.^{33,34} The largest wound is likely to be the leading contributor to abdominal wall pain, therefore, where minilaparoscopy has been performed in cases where a wound has been extended for specimen extraction, the benefits of the other minilaparoscopic ports may be less apparent. It stands to reason, therefore, that the benefits of smaller size and number of abdominal ports are more likely to be demonstrated if the intra-abdominal dissection and technique are performed as atraumatically as possible, with no extension of abdominal wounds by virtue of the natural-orifice access.

CONCLUSION

The combination of transvaginal NOTES and minilaparoscopic/percutaneous approaches in this series of 3 laparoscopic right hemicolectomies was associated with minimal analgesia requirements, rapid return of bowel function, shortened length of stay, and superb cosmesis. The same approach to a splenic flexure carcinoma in a very frail 88-year-old patient averted major concerns regarding the integrity of her abdominal wall and recovery from major surgery. Transvaginal access is not a technically difficult technique, and the synergy between this minimal transabdominal approach and totally intracorporeal anastomosis warrants further consideration and investigation by colorectal and general surgeons, facilitated by collaboration between surgical specialties. Whereas the presently reported series is clearly small, it serves to highlight areas for further innovation and investigation in minimally invasive abdominal surgery. Larger case series and controlled trials are needed to quantify the potential benefits of the hybrid NOTES approach.

References:

1. Bulian DR, Knuth J, Cerasani N, et al. Transvaginal hybrid NOTES cholecystectomy: results of a randomized clinical trial after 6 months. *Langenbecks Arch Surg*. 2014;399:717–724.
2. van den Boezem PB, Velthuis S, Lourens HJ, Cuesta MA, Sietses C. Single-incision and NOTES cholecystectomy: are there clinical or cosmetic advantages when compared to conventional laparoscopic cholecystectomy? A case–control study comparing single-incision, transvaginal, and conventional laparoscopic technique for cholecystectomy. *World J Surg*. 2013;38:25–32.
3. Borchert DH, Federlein M, Fritze-Büttner F. Postoperative pain after transvaginal cholecystectomy: single-center, double-blind, randomized controlled trial. *Surg Endosc*. 2014;28:1886–1894.
4. Wolthuis AM, de Buck van Overstraeten A, D’Hoore A. Laparoscopic natural orifice specimen extraction-colectomy: a systematic review. *World J Gastroenterol*. 2014;20:12981–12992.
5. Dostalík J, Gunkova P, Gunka I, Mazur M, Mrazek T. Laparoscopic gastric resection with natural orifice specimen extraction for postulcer pyloric stenosis. *Wideochir Inne Tech Maloinwazyjne*. 2014;9:282–285.
6. Bueno B. Primer caso de apendicectomia por via vaginal. *Tokoginecol Pract*. 1949;8:152–158.
7. Traiman P, De Luca LA, Rodrigues JR, Rudge MV, Antonini Filho R. Transvaginal tubal ligation. *J Bras Ginecol*. 1984;9:433–436.
8. Delvaux G, Devroey P, De Waele B, Willems G. Transvaginal removal of gallbladders with large stones after lapa-

roscopic cholecystectomy. *Surg Laparosc Endosc.* 1993;3:307–309.

9. Clark LE, Menderes G, Tower AM, Silasi D-A, Azodi M. A simple approach to specimen retrieval via posterior colpotomy incision. *JLS.* Apr-Jun;19(2):e2015.00222. DOI: 10.4293/JLS.2014.00222.

10. Gustafsson UO, Scott MJ, Schwenk W, et al. Guidelines for perioperative care in elective colonic surgery: Enhanced Recovery After Surgery (ERAS®) Society recommendations. *World J Surg.* 2013;37:259–284.

11. Salimath J, Jones MW, Hunt DL, Lane MK. Comparison of return of bowel function and length of stay in patients undergoing laparoscopic versus open colectomy. *JLS.* 2007;11:72–75.

12. Tong DKH, Law WL. Laparoscopic versus open right hemicolectomy for carcinoma of the colon. *JLS.* 2007;11:76–80.

13. Franklin MEJ, Gonzalez JJJ, Miter DB, et al. Laparoscopic right hemicolectomy for cancer: 11-year experience. *Rev Gastroenterol Mex.* 2004;69(Suppl. 1):65–72.

14. Torres RA, Orban RD, Tocaimaza L, Vallejos Pereira G, Arevalo JR. Transvaginal specimen extraction after laparoscopic colectomy. *World J Surg.* 2012;36:1699–1702.

15. Ghezzi F, Raio L, Mueller MD, Gyr T, Buttarelli M, Franchi M. Vaginal extraction of pelvic masses following operative laparoscopy. *Surg Endosc* 2002;16:1691–1696.

16. Ghezzi F, Cromi A, Uccella S, Bogani G, Serati M, Bolis P. Transumbilical versus transvaginal retrieval of surgical specimens at laparoscopy: a randomized trial. *Am J Obstet Gynecol.* 2012;207:112.e1–6.

17. Park JS, Choi G-S, Kim HJ, Park SY, Jun SH. Natural orifice specimen extraction versus conventional laparoscopically assisted right hemicolectomy. *Br J Surg.* 2011;98:710–715.

18. Bulian DR, Knuth J, Lehmann KS, Sauerwald A, Heiss MM. Systematic analysis of the safety and benefits of transvaginal hybrid-NOTES cholecystectomy. *World J Gastroenterol.* 2015;21:10915–10925.

19. Awad ZT, Griffin R. Laparoscopic right hemicolectomy: a comparison of natural orifice versus transabdominal specimen extraction. *Surg Endosc.* 2014;28:2871–2876.

20. Tolcher MC, Kalogera E, Hopkins MR, Weaver AL, Bingener J, Dowdy SC. Safety of culdotomy as a surgical approach: implications for natural orifice transluminal endoscopic surgery. *JLS.* 2012;16:413–420.

21. Ayhan A, Boynukalin K, Salman MC. Tubal ligation via posterior colpotomy. *Int J Gynaecol Obstet.* 2006;93:254–255.

22. Sodergren MH, Markar S, Pucher PH, Badran IA, Jiao LR, Darzi A. Safety of transvaginal hybrid NOTES cholecystectomy: a

systematic review and meta-analysis. *Surg Endosc.* 2015;29:2077–2090.

23. Xu B, Xu B, Zheng W-Y, et al. Transvaginal cholecystectomy vs conventional laparoscopic cholecystectomy for gallbladder disease: a meta-analysis. *World J Gastroenterol.* 2015;21:5393–5406.

24. El-Toukhy TA, Hefni M, Davies A, Mahadevan S. The effect of different types of hysterectomy on urinary and sexual functions: a prospective study. *J Obstet Gynaecol.* 2004;24:420–425.

25. Roussis NP, Waltrous L, Kerr A, Robertazzi R, Cabbad MF. Sexual response in the patient after hysterectomy: total abdominal versus supracervical versus vaginal procedure. *Am J Obstet Gynecol.* 2004;190:1427–1428.

26. Long CY, Fang JH, Chen WC, Su JH, Hsu SC. Comparison of total laparoscopic hysterectomy and laparoscopically assisted vaginal hysterectomy. *Gynecol Obstet Invest.* 2002;53:214–219.

27. Bergamaschi R, Schochet E, Haughn C, Burke M, Reed JF, Arnaud J-P. Standardized laparoscopic intracorporeal right colectomy for cancer: short-term outcome in 111 unselected patients. *Dis Colon Rectum.* 2008;51:1350–1355.

28. Bisgaard T, Klarskov B, Trap R, Kehlet H, Rosenberg J. Microlaparoscopic vs conventional laparoscopic cholecystectomy: a prospective randomized double-blind trial. *Surg Endosc.* 2002;16:458–464.

29. Bisgaard T, Klarskov B, Trap R, Kehlet H, Rosenberg J. Pain after microlaparoscopic cholecystectomy: a randomized double-blind controlled study. *Surg Endosc.* 2000;14:340–344.

30. Schwenk W, Neudecker J, Mall J, Böhm B, Müller JM. Prospective randomized blinded trial of pulmonary function, pain, and cosmetic results after laparoscopic vs. microlaparoscopic cholecystectomy. *Surg Endosc.* 2000;14:345–348.

31. Novitsky YW, Kercher KW, Czerniach DR, et al. Advantages of mini-laparoscopic vs conventional laparoscopic cholecystectomy: results of a prospective randomized trial. *Arch Surg.* 2005;140:1178–1183.

32. de Carvalho LFA, Fierens K, Kint M. Mini-laparoscopic versus conventional laparoscopic cholecystectomy: a randomized controlled trial. *J Laparoendosc Adv Surg Tech A.* 2013;23:109–116.

33. McCloy R, Randall D, Schug SA, et al. Is smaller necessarily better? A systematic review comparing the effects of minilaparoscopic and conventional laparoscopic cholecystectomy on patient outcomes. *Surg. Endosc.* 2008;22:2541–2553.

34. Thakur V, Schlachta CM, Jayaraman S. Minilaparoscopic versus conventional laparoscopic cholecystectomy a systematic review and meta-analysis. *Ann Surg.* 2011;253:244–258.