

Eosinophilia Due to Central Venous Catheter in Hemodialysis Patients



To the editor: Mild eosinophilia is not uncommon in hemodialysis patients. It is historically related in most cases to allergic reactions to the extra-corporeal circuit components and more rarely to various conditions ranging from infections to malignancies.^{1,2}

We report on six patients (Table 1) who developed an acute severe eosinophilia (median peak of eosinophil count, 8.6 ± 3.3 G/) that was induced by the insertion of tunneled central venous catheters. The link between eosinophilia and central venous catheters is substantiated by causality assessment,³ based first on chronological criteria (Figure 1): while eosinophil blood count was normal for several years, it dramatically increased after the catheter insertion, persisted at high levels as long as the catheter was left in place and resolved shortly after catheter withdrawal. Besides, in patients 3 and 4, eosinophilia recurred after a further venous catheter insertion. Furthermore, comprehensive etiological work-up (parasites culture and serological tests, autoantibodies

tests, bone marrow aspiration, tests for FIP1L1-PDGFR α and BCR-ABL rearrangements, thoraco-abdominal and pelvic CT-scan) for underlying malignancy, infection, allergy or autoimmune disease and assessment for medications and dialysis membrane replacement, failed to identify any alternative cause for eosinophilia (semiological criteria for causality).^{4,S1}

The cases presented here are peculiar for the severity of eosinophilia. It was associated to rather mild symptoms in the majority of patients, mostly pruritus, sweating and urticarial rash during dialysis sessions. However, in one patient, eosinophilia was associated to the occurrence of pulmonary nodules, eosinophilic alveolitis and colitis (Figure 2). In this patient, as well as in two additional ones, eosinophilia work-up led to a significant delay in the access to renal transplantation, due to temporary contraindication. In two other patients, severe reactions with hypotension, dyspnea occurred repeatedly after start of dialysis session.

To the best of our knowledge, this is the first description of severe eosinophilia induced by dialysis catheter. Nephrologists should be aware that indwelling venous catheter is a potential reversible cause of severe eosinophilia in hemodialysis patients whose mechanism remains to be understood. This will help avoiding useless etiological investigations and,

Table 1. Characteristics of six dialysis patients with tunneled catheter-related eosinophilia

Patient Gender, Age (y)	Type of venous catheter (brand)	Time from catheter insertion to Eo (days)	Eo peak (G/L) (time from catheter, days)	Eo related manifestations	Eo duration (months)	Eo recovery time after catheter withdrawal (days)
P1 M, 48	Tunneled jugular catheter (HEMOTEC®)	90 (first available test after catheter)	10 (183)	Ulcerative colitis Pulmonary nodules (Figure 2)	13	15
P2 M, 50	Tunneled jugular catheter (HEMOTEC®) Intermittent use of fistula	322 (first available test after catheter)	4.8 (336)	Urticarial rash	12.5	0
P3 F, 57	Tunneled jugular catheter (OPTIMED®)	277	1.9 (281)	No	0.5	NA
	Tunneled jugular catheter (VYGON®)	68 (first available test after catheter)	1.8 (68)	No	6	30
	Tunneled jugular catheter (HEMOTEC®)	18	5.2 (40)	No	1	15
	Tunneled jugular catheter (HEMOTEC®)	21	8.5 (37)	No	1.5	NA
P4 M, 57	Tunneled jugular catheter (VYGON®)	37	2 (112)	No	3	4
	Tunneled jugular catheter (VYGON®)	32	14.3 (37)	Pruritus, sweats	8.5	1
P5 F, 54	Palindrome catheter (METRONIC®)	93	6.1 (387)	Pruritus, sweats and urticarial rash	14	21 (renal transplantation)
P6 M, 37	Tunneled jugular catheter (HEMOTEC®)	47	9.8 (1230)	Pruritus, sweats and urticarial rash	39	NA (renal transplantation)

Eo, eosinophilia; F, female; M, male; NA, not available; P, patient; y, year

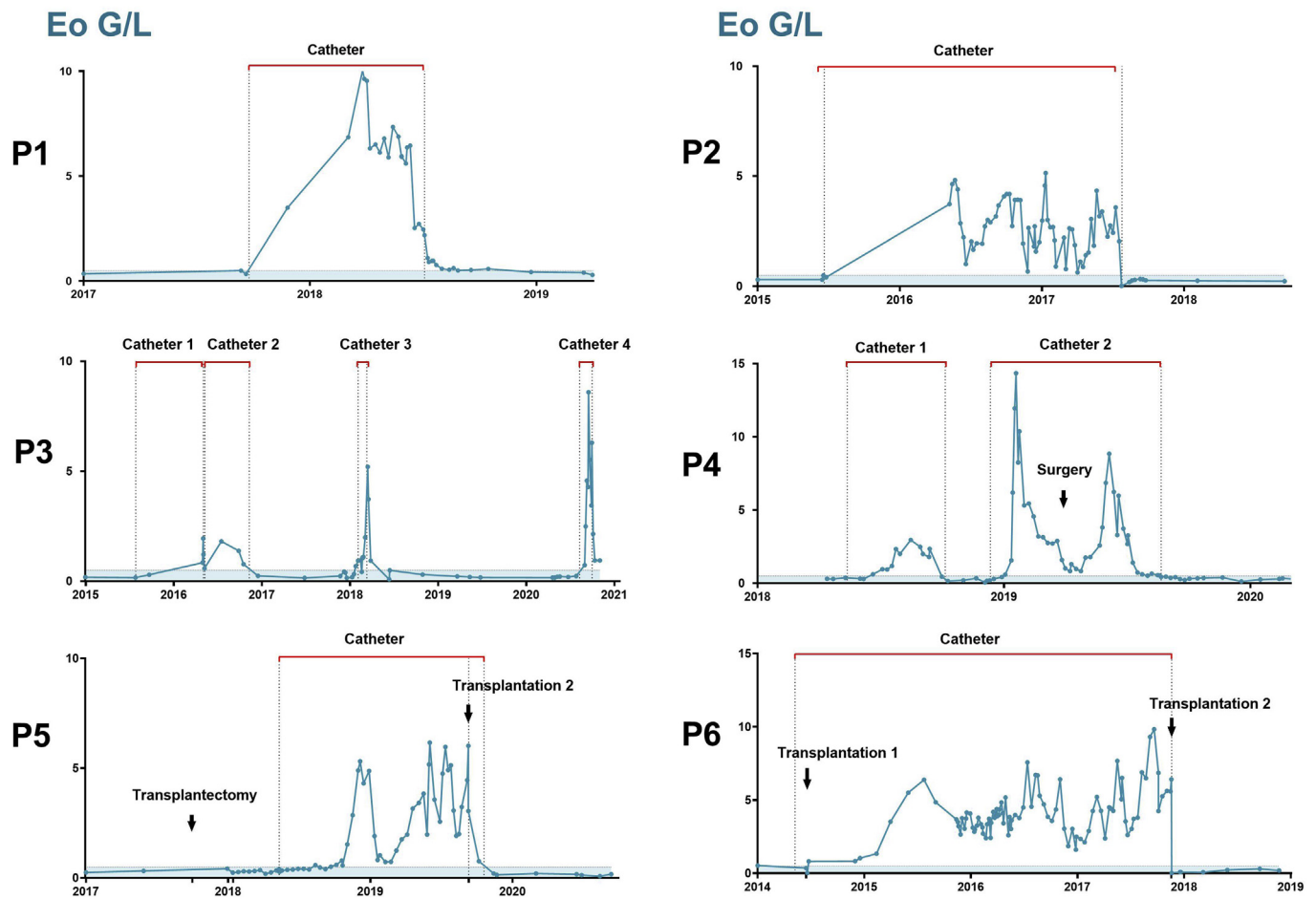


Figure 1. Time evolution of eosinophil counts in six patients with hemodialysis catheter induced eosinophilia.

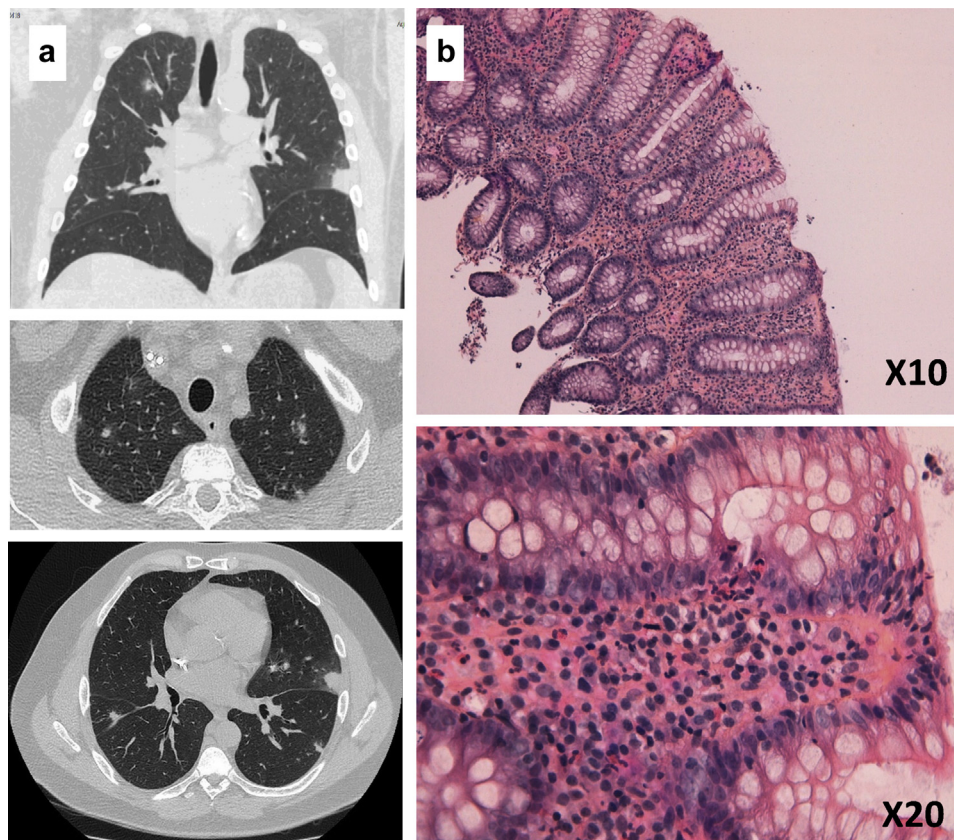


Figure 2. Patient 1 had severe eosinophilia associated to the occurrence of pulmonary nodules (a), eosinophilic alveolitis and colitis (b).

more importantly, delays in the access to renal transplantation for these patients.

SUPPLEMENTARY MATERIAL

Supplementary File (PDF)

Supplementary Reference.

1. Hildebrand S, Corbett R, Duncan N, Ashby D. Increased prevalence of eosinophilia in a hemodialysis population: Longitudinal and case control studies. *Hemodial Int.* 2016;20(3):414–420.
2. Gauckler P, Shin JI, Mayer G, Kronbichler A. Eosinophilia and Kidney Disease: More than Just an Incidental Finding? *J Clin Med.* 2018;7(12).
3. Miremont-Salamé G, Théophile H, Haramburu F, et al. Causality assessment in pharmacovigilance: The French method and its successive updates. *Thérapie.* 2016 Apr;71(2):179–186.
4. Gotlib J. World Health Organization-defined eosinophilic disorders: 2017 update on diagnosis, risk stratification, and management. *Am J Hematol.* 2017;92(11):1243–1259.

Agnès Chapelet-Debout^{1,5}, Stéphanie Coupel^{2,5}, Géraldine de Geyer d'Orth², Caroline Gourraud-Vercel¹, Gaëlle Lefrançois², Sophie Parahy², Clément Deltombe¹, Simon Ville^{1,3} and Fadi Fakhouri⁴

¹Institute of Transplantation Urology Nephrology (ITUN), Nantes University Hospital, Nantes, France; ²Association ECHO, Pôle de Santé CONFLUENT, Nantes, France; ³Centre de Recherche en Transplantation et Immunologie UMR1064, INSERM, Université de Nantes, Nantes, France; and ⁴Service of Nephrology and Hypertension, Department of Medicine, Lausanne University Hospital and University of Lausanne, Lausanne, Switzerland

Correspondence: Agnès Chapelet-Debout, department of Nephrology and Transplantation, CHU de Nantes, 30 boulevard Jean Monnet, 44000, Nantes, France.

E-mail: agnes.chapelet@chu-nantes.fr

⁵These authors contributed equally to the work.

Received 24 December 2020; accepted 29 December 2020; published online 12 January 2021

Kidney Int Rep (2021) **6**, 1189–1191; <https://doi.org/10.1016/j.ekir.2020.12.033>

© 2021 Published by Elsevier, Inc., on behalf of the International Society of Nephrology. This is an open access article under the CC BY-NC-ND license (<http://creativecommons.org/licenses/by-nc-nd/4.0/>).