



CASE REPORT

REVISED Case Report: IgG multiple myeloma and chronic myeloid leukemia in a single patient [version 2; peer review: 2 approved]

Neeraja Swaminathan ¹, Sorab Gupta², Claudia Dourado²

¹Department of Internal Medicine, Albert Einstein Medical Center, Philadelphia, PA, 19141, USA

²Department of Hematology, Albert Einstein Medical Center, Philadelphia, PA, 19141, USA

V2 First published: 01 Jun 2020, 9:488
<https://doi.org/10.12688/f1000research.24086.1>
 Latest published: 23 Sep 2020, 9:488
<https://doi.org/10.12688/f1000research.24086.2>

Abstract

A 58-year-old man presented with recurrence of chronic myeloid leukemia (CML) after complete molecular remission in the setting of non-compliance with imatinib. He was restarted on imatinib and was also noted to have IgG kappa monoclonal gammopathy of undetermined significance (MGUS). The patient re-achieved molecular remission after resumption of imatinib, but his MGUS progressed to smoldering myeloma and he was eventually diagnosed with multiple myeloma (MM) and initiated on treatment for MM with thalidomide, bortezomib and dexamethasone. He has responded well to treatment of the myeloma and continues concurrent maintenance imatinib treatment for CML and is being evaluated for bone marrow transplant. The association of two concurrent hematological malignancies, CML and MM, is very rare and has been infrequently reported in literature. The pathophysiology of this has not yet been fully understood. This case report reviews the various theories to explain this and discusses the potential challenges of simultaneous treatment of MM and CML.

Keywords

multiple myeloma, MGUS, CML, chronic myeloid leukemia

Open Peer Review

Reviewer Status

	Invited Reviewers	
	1	2
version 2 (revision) 23 Sep 2020	 report	
version 1 01 Jun 2020	 report	 report

1. **Mahesh Swaminathan** , Roswell Park Comprehensive Cancer Center, Buffalo, USA
2. **Pritish K. Bhattacharyya** , Hackensack University Medical Center, Hackensack, USA
Rutgers New Jersey Medical School, Newark, USA

Any reports and responses or comments on the article can be found at the end of the article.

Corresponding author: Neeraja Swaminathan (neeraja1991@yahoo.co.in)

Author roles: **Swaminathan N:** Writing – Original Draft Preparation, Writing – Review & Editing; **Gupta S:** Supervision, Writing – Review & Editing; **Dourado C:** Supervision

Competing interests: No competing interests were disclosed.

Grant information: The author(s) declared that no grants were involved in supporting this work.

Copyright: © 2020 Swaminathan N *et al.* This is an open access article distributed under the terms of the [Creative Commons Attribution License](#), which permits unrestricted use, distribution, and reproduction in any medium, provided the original work is properly cited.

How to cite this article: Swaminathan N, Gupta S and Dourado C. **Case Report: IgG multiple myeloma and chronic myeloid leukemia in a single patient [version 2; peer review: 2 approved]** F1000Research 2020, 9:488
<https://doi.org/10.12688/f1000research.24086.2>

First published: 01 Jun 2020, 9:488 <https://doi.org/10.12688/f1000research.24086.1>

REVISED Amendments from Version 1

This submission clarifies a few aspects in the presentation and clinical course of this patient.

1. The transcripts at the time of diagnosis of CML were typical.
2. At the time of CML relapse, patient was in chronic phase as evidenced by peripheral smear showing only rare blasts, but bone marrow biopsy was not done
3. Prior to diagnosis of MGUS, bone marrow biopsy confirmed < 10% plasma cells
4. Side-effects of concurrent myeloma treatment and imatinib seen in this patient are described in more detail.

Any further responses from the reviewers can be found at the end of the article

Introduction

Chronic myeloid leukemia (CML) is a clonal myeloproliferative disorder of pluripotent hematopoietic stem cells. It results from a translocation t (9;22) (q34;q11) known as the Philadelphia chromosome creating a BCR-ABL fusion gene, which is transcribed into proteins with abnormal tyrosine kinase activity that drives abnormal white blood cell (WBC) proliferation¹. Multiple myeloma (MM) is a monoclonal disorder of plasma cells which have differentiated from lymphoid B cells. Therefore, the abnormal cell types in CML and MM are distinctly different. The instances of both MM and CML in the same patient occurring in a synchronous or metachronous manner are extremely rare. There are several factors that have been postulated to be related to this occurrence. These include age, gender, race, exposure to environmental carcinogens or radiation, epigenetic upregulation/downregulation, as a result of progression or treatment of one malignancy potentiating the development of malignant cells (which acquire antiapoptotic ability) and mechanisms to evade immune surveillance, chronic antigenic stimulation, genetic polymorphisms. At present there are multiple theories but insufficient data to make any definite conclusions about the mechanism of co-existence of CML and MM. With the advent of novel therapies and improving survival in patients with CML and MM, there is value in further investigation regarding the pathophysiology and clinical characteristics of such cases^{2,3}. Additionally, the occurrence of more than one hematological malignancy in the same patient presents treatment challenges because it can lead to the possibilities of drug-drug interactions and medication toxicities. Analysis of the treatment protocols of these patients and their follow-up will be required to assess the risks and benefits of different treatment options. At this time, due to paucity of data, the management is tailored according to the patient's individual risk factors and clinician's judgement.

This is a rare case of the occurrence of IgG MM and CML in a single patient and reviews the management of these diseases.

Case report

A 58-year-old man with history of CML presented in December 2015 for re-establishment of care after being lost to follow-up.

He was first diagnosed in December 2007 with CML and was treated with imatinib (400mg daily). He achieved complete molecular remission but was unfortunately lost to follow-up after 2012. The patient stated that he had stopped taking imatinib in September 2015 due to family issues and stressors. When he presented in December 2015, he had no specific complaints. He was noted to have mild pallor on exam, but no lymphadenopathy or hepatosplenomegaly. Labs were significant for leukocytosis and blasts noted on peripheral smear. BCR-ABL FISH/PCR was also positive indicating relapse of CML and the transcripts at the time of diagnosis were typical. His peripheral smear showed only rare blasts (< 10 %) and the patient appeared to be in the chronic phase of CML. A bone marrow biopsy was not repeated at this time.

The patient was re-initiated on treatment with imatinib 400mg daily. Within 2 weeks of resuming treatment he was noted to have an improvement in WBC count. However, he was incidentally detected to have an elevated total protein level. In view of this serum protein, electrophoresis was ordered and the patient was found to have an IgG kappa monoclonal gammopathy of undetermined significance (MGUS). This diagnosis was established because the total M protein spike was <3g/dL, bone marrow biopsy showed < 10% plasma cells and the patient had no evidence of end organ damage. Skeletal survey was done which showed no lytic lesions. Imatinib was continued for CML and he was monitored closely for progression of plasma cell dyscrasia.

With regard to the patient's CML, he achieved molecular remission in November 2016 with 3 log reduction in the 3 tested transcripts b2a2, b3a2, e1a2 and without detectable Philadelphia chromosome. However, he had a steady increase in the paraprotein level from December 2015 to April 2019 without any symptoms. He did not develop myeloma defining events such as hypercalcemia (>1mg/dL over the upper limit of normal OR >11mg/dL), renal insufficiency (creatinine clearance <40mL/min or serum creatinine >2mg/dL), anemia (Hemoglobin > 2g/dL below lower limit of normal or <10g/dL) or bony pain/lytic lesions (on skeletal radiography/CT/PET). These are together referred to as the CRAB phenomenon. His serum free light chain ratio remained at <100mg/L.

In May 2019, the patient had further rise in creatinine and paraprotein level and had an increase in serum free light chain ratio. Therefore, he underwent a PET CT in June 2019. This showed increased uptake in the left 4th rib, left and right ischium, and a lesion in the second lumbar (L2) vertebra. He also underwent a bone marrow biopsy in July 2019, which showed 50% plasma cells expressing CD 38, CD 138, dim/partial CD 117, CD 56 and kappa light chain restriction. No BCR ABL gene rearrangement was noted. Thus, it confirmed the diagnosis of MM.

MM interphase fluorescence in situ hybridization (FISH) panel analysis of CD138+ enriched plasma cells was positive for three CCND1 signals consistent with trisomy 11 and for extra signals for chromosomes 7, 9 and 15. There were no cells with FGFR3-IGH, CCND1-IGH, or IGH-MAF fusions. Results for

1p/1q, 13q and TP53 were normal. Extra signals for probes targeting the chromosomes reported above suggest the presence of a hyperdiploid clone. Thus, the patient’s cytogenetic testing was negative for high risk factors.

platelet count, and creatinine are seen in [Figure 3–Figure 6](#), respectively.

The trends of serum protein electrophoresis are seen in [Table 1](#), and [Figure 1](#) and [Figure 2](#). Trends of WBC count, hemoglobin,

The patient was started on treatment for ISS stage II standard risk myeloma with thalidomide (50mg/day daily for 21 days followed by 7 days off), weekly bortezomib (1.3mg/m²) and dexamethasone (40mg/day once a week) in September 2019.

Table 1. Serum electrophoresis results.

	A/G ratio	alpha 1 globulin	alpha 2 globulin	beta globulin	gamma globulin	M spike	kappa lambda ratio	IgG	IgA	IgM	beta 2 microglobulin	Lactate dehydrogenase
Dec-15	1.1	0.2	0.6	0.8	2.1	0.8						
Nov-16	0.9	0.2	0.5	0.7	4.1	1.8	6.89	3103	<5	27		
Apr-17	0.8	0.2	0.6	0.8	3.2	2.3		3239	<5	19		
Aug-17	0.8	0.1	0.5	0.8	3.3	2.6	10.3	3770	<5	17		233
Dec-17							10.84	3826	<5	16		
Jul-18	0.7	0.2	0.6	0.9	3.7	2.9		3931	<5	13		
Oct-18	0.8	0.1	0.5	0.7	3.7	3.2	14.5	3871	<5	14		
Apr-19	0.7	0.2	0.6	0.8	4.1	3.5	24.35					
May-19	0.7	0.2	0.6	0.8	4.1	3.6	20.91	4456	<5	11	4.2	
Sep-19	0.6	0.2	0.7	0.8	4.5	4	25.47	5367	<5	9	4	169
Oct-19	0.8	0.2	0.6	0.7	2.5	2.3	15.48					175
Nov-19	1.1	0.2	0.7	0.8	1.1	0.8	1.75	1176	<5	26		377
Dec-19	1.4	0.2	0.6	0.8	0.8	0.3	1.43					
Jan-20	1.6	0.2	0.6	0.7	0.7	faint	1.35					

Abbreviations used: A/G ratio- albumin/globulin ratio, M spike- monoclonal spike, Ig- immunoglobulin, LDH-lactate dehydrogenase.

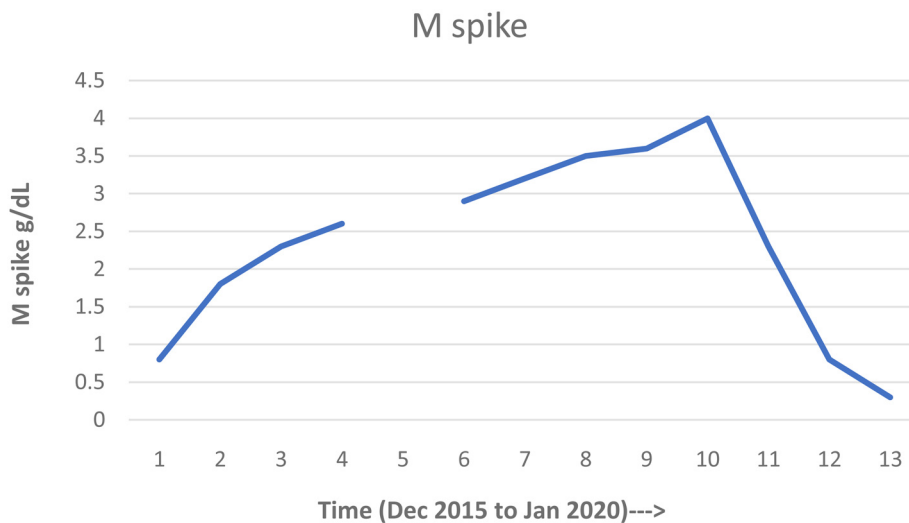


Figure 1. Graphical trend of M spike.

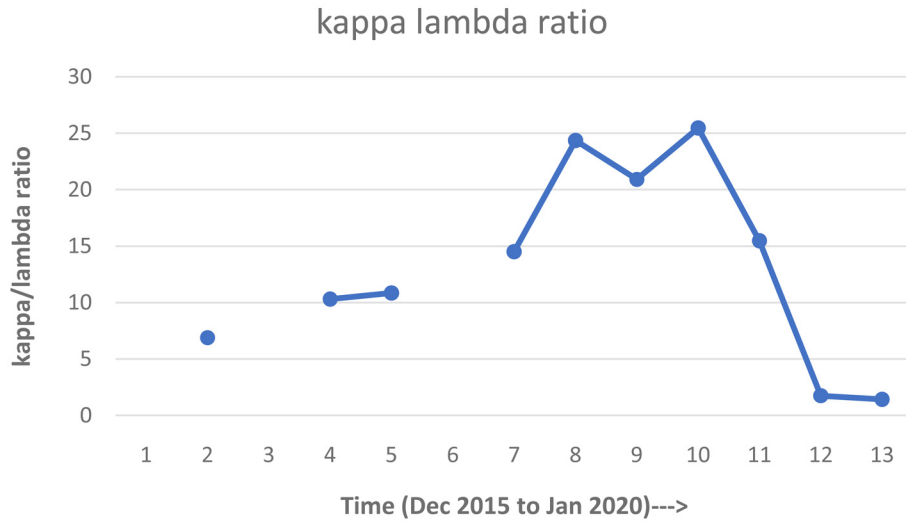


Figure 2. Graphical trend of kappa/lambda ratio.

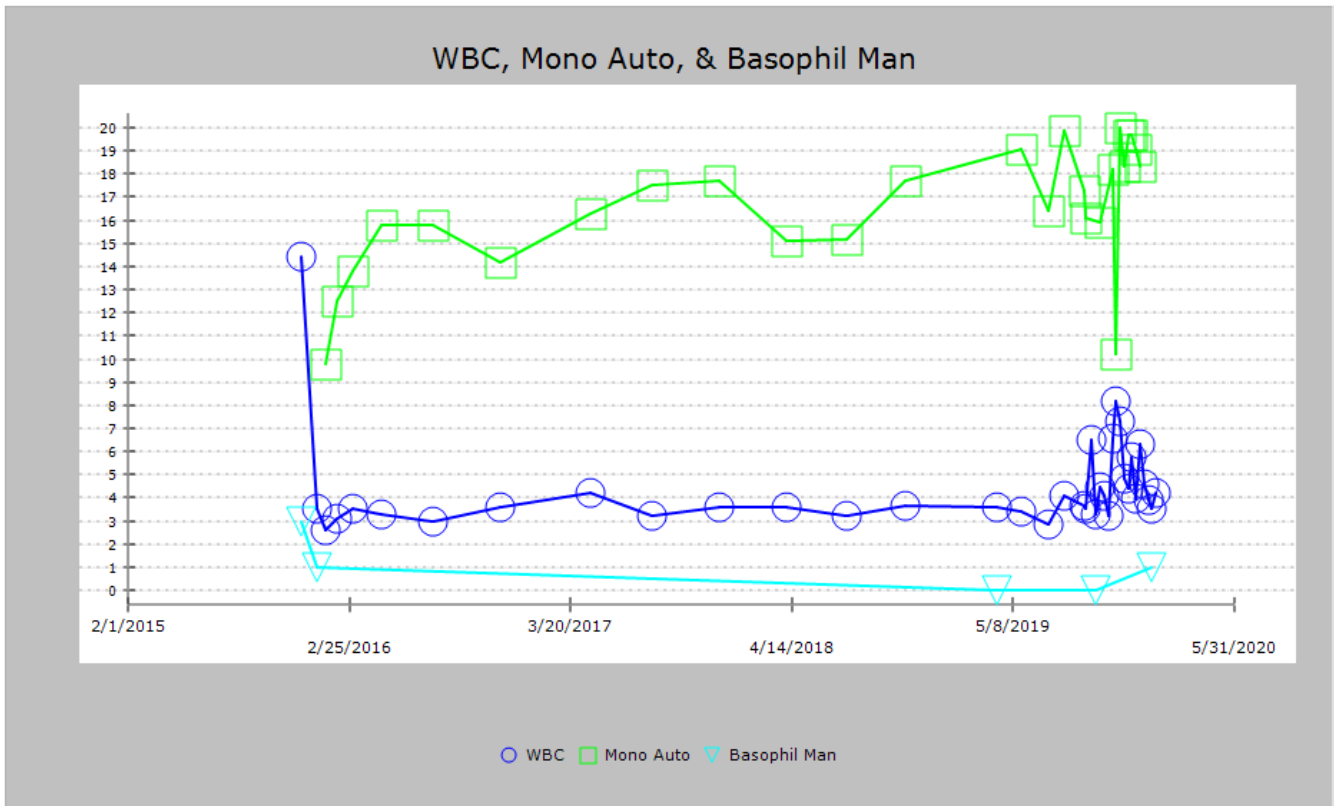


Figure 3. Graphical trend of white blood cell (WBC) count, lymphocytes and basophils.

This regimen was preferred over the VRd (lenalidomide, bortezomib and dexamethasone) due to the concern for increased risk of pancytopenia with concurrent use of imatinib and lenalidomide.

After cycle 2 of the myeloma treatment, this patient developed a morbilliform pruritic rash over trunk and bilateral

upper extremities which has been described as a side effect of thalidomide. He was managed with a short course of steroids. After cycle 5, he had recurrence of above described rash and also developed conjunctival injection bilaterally. He was seen by ophthalmology and diagnosed to have meibomian gland dysfunction. Due to the rash and ocular symptoms, there were delays in his myeloma treatment but these were

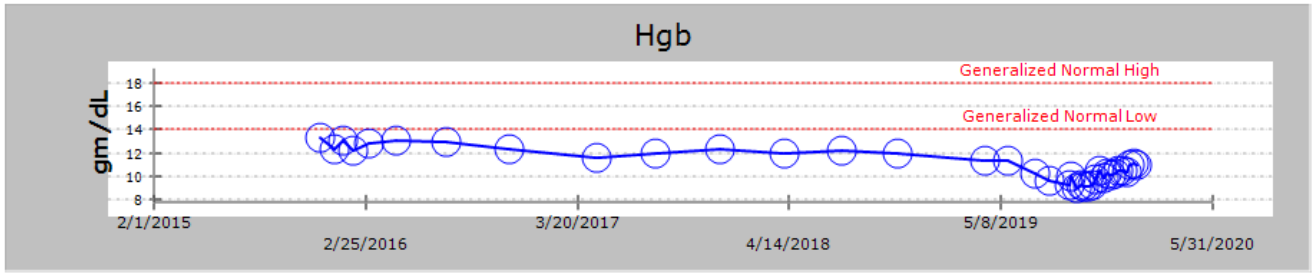


Figure 4. Graphical trend of hemoglobin.

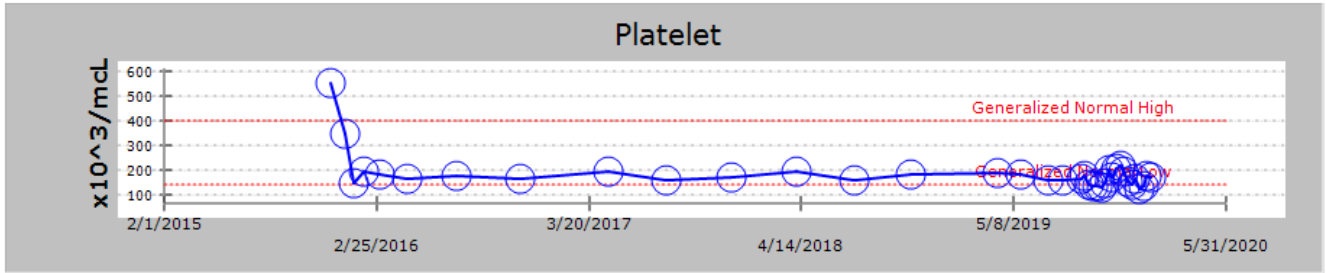


Figure 5. Graphical trend of platelet count.

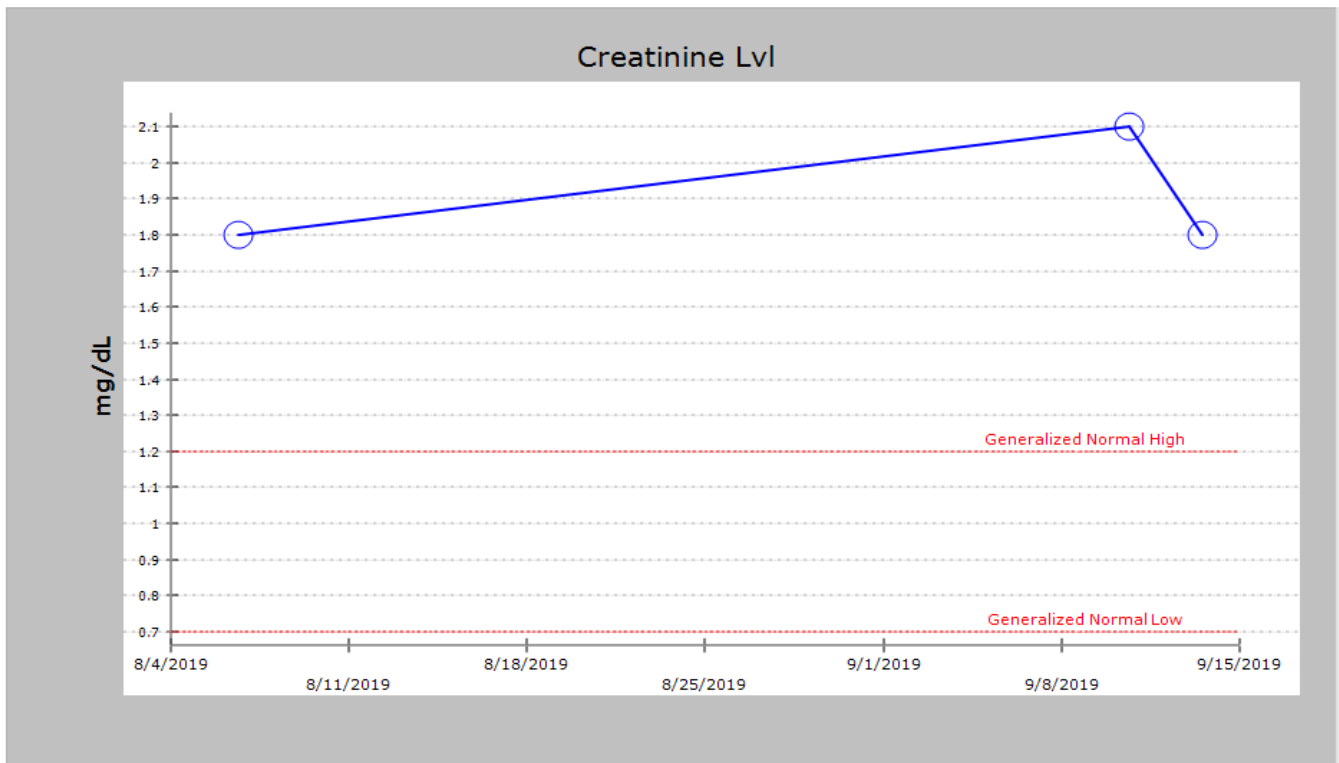


Figure 6. Graphical trend of creatinine.

not dose-limiting toxicities. His symptoms improved with supportive care (oral steroids and steroid eye drops) and resolved completely. Thus far he has completed 6 cycles of treatment for myeloma with concurrent imatinib and has been referred to a transplant center to assess his eligibility for the same.

Discussion

The occurrence of CML and MM together is very rare. There are multiple explanations that have been suggested for co-existence of more than one hematological malignancy. One of the theories is that there is a common progenitor stem

cell. The Philadelphia chromosome is observed not only in granulocytes but also in cells of the monocytic, erythroid, megakaryocytic and lymphoid series. This finding supports the concept of a common pluripotent progenitor cell. The transformation to lymphoid cells in the blast phase of the CML also suggests a relationship between the myeloid and lymphoid lineage⁴.

The role of imatinib in promoting development of MM is debatable. There is some evidence from Pandiella *et al.*⁵ that imatinib inhibits MM cell proliferation *in vitro*. On the contrary, it has been reported that imatinib has a stimulatory effect on MM cells through activation of Erk1 and Erk2 mitogen activated protein kinases (MAP kinases). There have also been reports of MM developing in non CML patients such as those with gastrointestinal stromal tumors treated with imatinib⁶ Carulli *et al.*⁷ looked at the possible interference of imatinib with plasma cell phenotype. Their study looked at 30 patients and found that 70% of these patients had an abnormal plasma cell phenotype, which they defined as plasma cells which lack CD 19. Some of these cells showed additional aberrations such as expression of CD 56. Although this cannot establish a causal relationship between imatinib and MM, it merits further investigation.

Imatinib mesylate is a tyrosine kinase inhibitor, which is the standard of care for CML as a first line agent. It has activity against different genes involved in cellular transformation such as BCR-ABL1, c-KIT, PGFR- α and β and Jak 2. Imatinib in CML acts by competing with ATP to bind to the BCR ABL1 tyrosine kinase and thereby inhibiting the WBC proliferation that it effects⁷.

Treatment of MM is based on whether the patient has standard or high-risk disease, which in turn is determined by cytogenetic analysis. High risk features constitute t (14;16), t (4;20), del17p13, t (4;14) and 1q gain. Additionally, patients should be assessed for eligibility to receive an autologous stem cell transplant. In standard risk patients such as ours the standard first line treatment is RVD regimen, which comprises lenalidomide, bortezomib and dexamethasone. Post induction therapy, if patients are eligible for hematopoietic cell transplant (HCT), they may choose either an early HCT or delayed HCT strategy. Autologous HCT is the mainstay, although allogenic HCT is still largely investigational. Post-transplant patients need maintenance therapy as well. Transplant in eligible patients receive either a two/three drug induction regimen followed by maintenance therapy. Melphalan, cyclophosphamide and thalidomide are also part of first line treatment options for myeloma. In patients with relapse, several of the newer agents are being used, which include the new proteasome inhibitor (carfilzomib), immunomodulatory drugs (like pomalidomide), inhibitors of NF- κ B, MAPK and AKT, histone deacetylase inhibitors (like vorinostat and panobinostat), and monoclonal antibodies (such as daratumumab, elotuzumab and siltuximab)⁸.

Due to the rarity of coexistence of more than one hematological malignancy in the same patient, we do not have robust data on treatment regimens. Current treatment is based on

factoring in the patient's individual risk factors and the physician's judgement and experience. Even though there is concern for imatinib being associated with MGUS and myeloma, co-administration of imatinib with myeloma treatment seems to be reasonable. Myeloma treatment both for high risk and standard risk group patients involves a proteasome inhibitor, such as bortezomib. Both bortezomib and imatinib are metabolized by microsomal enzyme CYP3A4. However, imatinib is a potent inhibitor of CYP3A4, while bortezomib is only a weaker inhibitor. Reduction of bortezomib dosing to once weekly instead of twice seems to be associated with less adverse effects when used in conjunction with imatinib⁹.

Additionally, bisphosphonates, which are used as supportive treatment in myeloma, have also been shown to inhibit CML cell lines and induce apoptosis synergistically with imatinib through the inhibition of prenylation of Ras and Ras-related proteins¹⁰

This case report presents an experience with a CML patient who over time progressed to develop the entire spectrum of myeloma, starting with MGUS followed by smoldering myeloma and ultimately MM requiring treatment. At this point it is difficult to say if this association is coincidental or related to some other mechanism and this is a subject that requires further research.

Conclusion

The most essential take-home points from this case are as follows:

1. MM can be diagnosed in patients with one of the following: >10% plasma cells in bone marrow OR biopsy proven bony/extramedullary plasmacytoma and any one of the CRAB phenomenon OR any of the following- \geq 60% plasma cells in bone marrow OR serum free light chain ratio \geq 100 OR >1 focal lesion on MRI studies.
2. Both MGUS and smoldering myeloma are characterized by an absence of myeloma defining events. In MGUS: paraprotein level <3 g/dL, bone marrow plasma cells $<10\%$; while in smoldering myeloma: paraprotein level >3 g/dL or urinary monoclonal protein \geq 500mg in 24 hours and/or clonal bone marrow plasma cells 10 to 60%
3. Co-existence of CML and MM is very rare. Etiology is probably multifactorial but there is a possibility that this is because CML and MM share a common pluripotent progenitor stem cell which can differentiate into both lymphoid and myeloid lines.
4. There is concern that the imatinib may lead to alteration of the plasma cell phenotype and it may be worthwhile to monitor serum electrophoresis and protein levels in patients who have received imatinib treatment.
5. Co-administration of bortezomib and imatinib is feasible. Since CYP3A4 is important for metabolism of both drugs, administration of bortezomib as weekly instead of twice weekly may help to reduce adverse effects of bortezomib.

Data availability

All data underlying the results are available as part of the article and no additional source data are required.

Consent

Written informed consent for the publication of the case report and any associated images was obtained from the patient.

References

1. Hehlmann R, Hochhaus A, Baccarani M, *et al.*: **"Chronic myeloid leukaemia"** *Lancet*. 2007; **370**(9584): 342–350.
[PubMed Abstract](#) | [Publisher Full Text](#)
2. Ali N, Pickens PV, Auerbach HE: **Immunoglobulin D multiple myeloma, plasma cell leukemia and chronic myelogenous leukemia in a single patient treated simultaneously with lenalidomide, bortezomib, dexamethasone and imatinib.** *Hematol Rep*. 2016; **8**(1): 6295.
[PubMed Abstract](#) | [Publisher Full Text](#) | [Free Full Text](#)
3. Maerki J, Katava G, Siegel D, *et al.*: **Unusual Case of Simultaneous Presentation of Plasma Cell Myeloma, Chronic Myelogenous Leukemia, and a Jak2 Positive Myeloproliferative Disorder.** *Case Rep Hematol*. 2014; **2014**: 738428.
[PubMed Abstract](#) | [Publisher Full Text](#) | [Free Full Text](#)
4. Klenn PJ, Hyun BH, Lee YH, *et al.*: **Multiple myeloma and chronic myelogenous leukemia: a case report with literature review.** *Yonsei Med J*. 1993; **34**(3): 293–300.
[PubMed Abstract](#) | [Publisher Full Text](#)
5. Pandiella A, Carvajal-Vergara X, Tabera S, *et al.*: **Imatinib mesylate (STI571) inhibits multiple myeloma cell proliferation and potentiates the effect of common antimyeloma agents.** *Br J Haematol*. 2003; **123**(5): 858–868.
[PubMed Abstract](#) | [Publisher Full Text](#)
6. Ide M, Kuwahara N, Matsuishi E, *et al.*: **Uncommon case of chronic myeloid leukemia with multiple myeloma.** *Int J Hematol*. 2010; **91**(4): 699–704.
[PubMed Abstract](#) | [Publisher Full Text](#)
7. Carulli G, Cannizzo E, Ottaviano V, *et al.*: **Abnormal phenotype of bone marrow plasma cells in patients with chronic myeloid leukemia undergoing therapy with Imatinib.** *Leuk Res*. 2010; **34**(10): 1336–1339.
[PubMed Abstract](#) | [Publisher Full Text](#)
8. Rajkumar SV: **Multiple myeloma: Every year a new standard?** *Hematol Oncol*. 2019; **37** Suppl 1(Suppl 1): 62–65.
[PubMed Abstract](#) | [Publisher Full Text](#) | [Free Full Text](#)
9. Maral S, Bakanay SM, Yikilmaz AS, *et al.*: **Development of plasma cell leukemia in a patient with chronic myeloid leukemia while on treatment with imatinib mesylate.** *J Cancer Res Ther*. 2018; **14**(6): 1431–33.
[PubMed Abstract](#) | [Publisher Full Text](#)
10. Chuah C, Barnes DJ, Kwok M, *et al.*: **Zolendronate inhibits proliferation and induces apoptosis of imatinib-resistant chronic myeloid leukaemia cells.** *Leukemia*. 2005; **19**(11): 1896–1904.
[PubMed Abstract](#) | [Publisher Full Text](#)

Open Peer Review

Current Peer Review Status:  

Version 2

Reviewer Report 30 September 2020

<https://doi.org/10.5256/f1000research.28094.r71881>

© 2020 Swaminathan M. This is an open access peer review report distributed under the terms of the [Creative Commons Attribution License](#), which permits unrestricted use, distribution, and reproduction in any medium, provided the original work is properly cited.



Mahesh Swaminathan 

Roswell Park Comprehensive Cancer Center, Buffalo, NY, USA

No further comments.

Competing Interests: No competing interests were disclosed.

Reviewer Expertise: Myeloid leukemias, clinical trials, Genetic syndromes in leukemia.

I confirm that I have read this submission and believe that I have an appropriate level of expertise to confirm that it is of an acceptable scientific standard.

Version 1

Reviewer Report 09 July 2020

<https://doi.org/10.5256/f1000research.26569.r65599>

© 2020 Bhattacharyya P. This is an open access peer review report distributed under the terms of the [Creative Commons Attribution License](#), which permits unrestricted use, distribution, and reproduction in any medium, provided the original work is properly cited.



Pritish K. Bhattacharyya 

¹ Department of Pathology, Hackensack University Medical Center, Hackensack, NJ, USA

² Rutgers New Jersey Medical School, Newark, NJ, USA

This is an uncommon case presentation of two apparently unrelated hematopoietic malignancies.

Association of Multiple myeloma following CLL or other low grade B cell lymphoma may be related

to terminal changes of B cell to Plasma cells (Jaffe *et al.*, NIH)

We had published a similar case in 2014 in a patient of CML with t9:22) along with JAK2 mutation and Myeloma (Maerki *et al.*, 2014¹). We suggested another potential theory of multiple simultaneous malignancies includes the sharing of a common malignant pluripotent progenitor stem cell which may allow further transformation of both lymphoid and myeloid differentiations.

It has been proposed that plasma cell myeloma and CML may evolve from the same hematopoietic stem cell [1, 8, 12]. There have been multiple accounts in which plasma cell neoplasms, including plasma cell leukemia and multiple myeloma, have been seen in coexistence with or arising in the background of CML [37–39]. It is suggested that the simultaneous occurrence of CML and multiple myeloma is analogous to acute lymphoblastic leukemia arising in the blastic phase of CML [5, 6, 8, 12, 15]. This reveals the capability of CML in differentiating into either myeloid lineage or lymphoid lineage. Furthermore, the Philadelphia chromosome (Ph) has been linked to increased cell survival, proliferation, and malignant transformation [1, 40] and has been found in all hematopoietic cell lineages including erythropoietic cells, megakaryocytes, macrophages, and B-lymphocytes [1,12, 41].

References

1. Maerki J, Katava G, Siegel D, Silberberg J, et al.: Unusual case of simultaneous presentation of plasma cell myeloma, chronic myelogenous leukemia, and a jak2 positive myeloproliferative disorder. *Case Rep Hematol.* 2014; **2014**: 738428 [PubMed Abstract](#) | [Publisher Full Text](#)

Is the background of the case's history and progression described in sufficient detail?

Yes

Are enough details provided of any physical examination and diagnostic tests, treatment given and outcomes?

Yes

Is sufficient discussion included of the importance of the findings and their relevance to future understanding of disease processes, diagnosis or treatment?

Yes

Is the case presented with sufficient detail to be useful for other practitioners?

Partly

Competing Interests: No competing interests were disclosed.

Reviewer Expertise: Leukemia, Lymphoma, Myeloma with molecular genetic applications

I confirm that I have read this submission and believe that I have an appropriate level of expertise to confirm that it is of an acceptable scientific standard.

Reviewer Report 08 June 2020

<https://doi.org/10.5256/f1000research.26569.r64202>

© 2020 Swaminathan M. This is an open access peer review report distributed under the terms of the [Creative Commons Attribution License](#), which permits unrestricted use, distribution, and reproduction in any medium, provided the original work is properly cited.



Mahesh Swaminathan

Roswell Park Comprehensive Cancer Center, Buffalo, NY, USA

In this case report, the authors have discussed a patient with chronic myeloid leukemia and metachronous IgG multiple myeloma. The clinical presentation and disease course are well described and discussed.

Adding the following details would add more clarity to the case and help readers:

1. Please mention the transcripts at diagnosis (as knowing typical versus atypical transcripts is important for follow up, the latter might not be detectable in routine PCR and warrants RT-PCR).
2. At CML disease relapse, please indicate if the patient was still in the chronic phase. Was there a bone marrow biopsy done at that time, if so what was the percentage of plasma cells.
3. As the diagnosis of MGUS requires BMBx? Please indicate if the clonal plasma cells were <10% facilitating the diagnosis of MGUS.
4. Please indicate if the x-axis in Figure 1-2 denotes months?
5. It will be interesting to know the most common Grade >3 AEs experienced by the patient (to know if there were any specific side effects that were more common with concomitant imatinib and myeloma therapy).

References

1. Rajkumar S, Dimopoulos M, Palumbo A, Blade J, et al.: International Myeloma Working Group updated criteria for the diagnosis of multiple myeloma. *The Lancet Oncology*. 2014; **15** (12): e538-e548 [Publisher Full Text](#)

Is the background of the case's history and progression described in sufficient detail?

Yes

Are enough details provided of any physical examination and diagnostic tests, treatment given and outcomes?

Yes

Is sufficient discussion included of the importance of the findings and their relevance to future understanding of disease processes, diagnosis or treatment?

Yes

Is the case presented with sufficient detail to be useful for other practitioners?

Partly

Competing Interests: No competing interests were disclosed.

Reviewer Expertise: Myeloid leukemias, clinical trials, Genetic syndromes in leukemia.

I confirm that I have read this submission and believe that I have an appropriate level of expertise to confirm that it is of an acceptable scientific standard, however I have significant reservations, as outlined above.

Author Response 13 Jun 2020

Neeraja Swaminathan, Albert Einstein Medical Center, Philadelphia, USA

Thank you for the feedback and comments provided.

1. Yes, the transcripts at the time of diagnosis were also typical.
2. At the time of relapse, the patient was in the chronic phase. Only rare blasts were seen on peripheral blood smear. There were fewer than 10% blast cells in the blood and a bone marrow biopsy was not performed.
3. When patient was noted to have an abnormal M-protein spike on serum electrophoresis, a bone marrow biopsy was repeated which showed < 10% plasma cells. The total M protein spike was <3g/dL and the patient had no evidence of end organ damage. All of this helped establish the diagnosis of MGUS and he was monitored clinically and with labs until May-June 2019 when he developed an increase in creatinine and eventually had a bone marrow biopsy which confirmed the diagnosis of multiple myeloma.
4. Yes, the x-axis in figures 1 and 2 denotes time in months.
5. This patient developed a morbilliform pruritic rash over trunk and bilateral upper extremities which has been described as a side effect of thalidomide. This occurred after cycle 2 and was managed with short course of steroids. After cycle 5, he had recurrence of above described rash and also developed conjunctival injection bilaterally. He was seen by ophthalmology and diagnosed to have meibomian gland dysfunction. In view of these symptoms, there was a delay in his myeloma treatment but his symptoms improved with supportive care (oral steroids and steroid eye drops) and resolved completely. He has now completed 6 cycles of treatment for myeloma and is being evaluated for bone marrow transplant. He has had no other side effects.

Competing Interests: none

Reviewer Response 14 Jul 2020

Mahesh Swaminathan, Roswell Park Comprehensive Cancer Center, Buffalo, USA

Thanks for updating.

Please make necessary inclusions of those comments in the manuscript.

Competing Interests: None

The benefits of publishing with F1000Research:

- Your article is published within days, with no editorial bias
- You can publish traditional articles, null/negative results, case reports, data notes and more
- The peer review process is transparent and collaborative
- Your article is indexed in PubMed after passing peer review
- Dedicated customer support at every stage

For pre-submission enquiries, contact research@f1000.com

F1000Research