

Pure Endoscopic Management of Fourth Ventricle Arachnoid Cyst: Case Report and Literature Review

Abstract

Arachnoid cysts (ACs) within the fourth ventricle are rare, and only a few cases have been reported in the literature. These are benign lesions within the arachnoid membrane, and they have been reported to occur in almost all locations where arachnoid is present. Different procedures have been performed to restore a normal cerebrospinal fluid dynamic and/or pressure, including shunting and partial or complete excision of the cyst by open microsurgery or endoscopic fenestration. We report the case of a fourth ventricle AC successfully treated using only endoscopic anterior trans-frontal cyst fenestration/marsupialization and standard third ventriculostomy. Clinical and technical features are discussed, along with the pertinent literature.

Keywords: Arachnoid cyst, endoscopy, fenestration, fourth ventricle, marsupialization

Introduction

Arachnoid cysts (ACs) are common anomalies of the central nervous system constituting about 1% of all nontraumatic intracranial space-occupying lesions. They are benign, congenital, nonneoplastic, extra-axial, arachnoidal lesions filled with fluid similar to cerebrospinal fluid (CSF). However, ACs in the fourth ventricle are particularly uncommon; the first report was published in 1979 on a pediatric patient.^[1] Since then, to the best of our knowledge, only 12 cases have been reported to date [Table 1]. The incidence of AC in the general population is estimated to be around 0.1% from autopsy series.^[4] The incidence is similar in computed tomography (CT) imaging series (0.2%)^[8] and greater in magnetic resonance imaging (MRI) series (0.8–1.7%).^[11] The pathologic hallmarks of ACs have generally been established, but their pathogenesis is still controversial and debated. The occurrence of cysts in neonates and siblings, the anatomic relationship of cysts to the cisterns, and the association of ACs with other developmental anomalies all lend credence to the supposition that these cysts are usually developmental in origin and not acquired from other pathologic conditions. ACs are most commonly present during childhood. About 75% of intracranial ACs

present before 3 years of age. Typical manifestations of AC of the fourth ventricle are chronic hydrocephalus, vertigo, ataxia, and less frequently, symptoms related to brain stem compression. In the neurosurgical literature, considerable debate continues regarding whether it is best to place a shunt, excise, fenestrate, or undertake a nonsurgical observational approach. We report our experience with a patient harboring a large fourth ventricle AC causing hydrocephalus and thus progressive increased intracranial pressure (ICP).

Case Report

We report the case of a 55-year-old woman, otherwise healthy, presenting to our outpatient clinic with a 6-month history of progressive deterioration of short-term memory associated with loss of balance, walking problems, and repeated episodes of falling. An urgent brain CT scan followed by MRI showed a dilated fourth ventricle due to an AC causing tri-ventricular hydrocephalus with trans-ependymal CSF resorption [Figure 1]. The patient was immediately admitted, whereupon neurological examination revealed a Mini-Mental State Examination (MMSE) score of 22 with light disorientation in time and space and unsteady waking with paraparesis globally estimated at 3/5 (MRC). After patient information

Hani Aljohani,
A. Romano¹,
C. Iaccarino¹,
M. Ganau¹,
P. Diemidio¹,
S. Chibbaro¹

Department of Neurosurgery,
Pasteur Hospital of Colmar,
Colmar, France, ¹Department of
Neurosurgery, Parma University
Hospital, Parma, Italy

Address for correspondence:

Dr. Hani Aljohani,
Department of Neurosurgery,
Hospital Civil de Colmar,
39 Avenue de la Liberté,
68024 Colmar Cedex, France.
E-mail: dr_h_aljohani@hotmail.
com

Access this article online

Website: www.asianjns.org

DOI: 10.4103/1793-5482.180956

Quick Response Code:



How to cite this article: Aljohani H, Romano A, Iaccarino C, Ganau M, Diemidio P, Chibbaro S. Pure endoscopic management of fourth ventricle arachnoid cyst: Case report and literature review. Asian J Neurosurg 2018;13:184-7.

This is an open access article distributed under the terms of the Creative Commons Attribution-NonCommercial-ShareAlike 3.0 License, which allows others to remix, tweak, and build upon the work non-commercially, as long as the author is credited and the new creations are licensed under the identical terms.

For reprints contact: reprints@medknow.com

Table 1: Literature review

Author (reference)	Age	Symptoms	Procedure	Outcome
Di Rocco <i>et al.</i> ^[1]	7 years	Chronic hydrocephalus, delayed mental and physical development, worsening of preexisting hemiparesis	VP shunt Complete excision	Temporary improvement Good outcome with persistent slight hemiparesis
Korosue <i>et al.</i> ^[2]	67 years	Chronic hydrocephalus	VP shunt Complete excision	Improvement of urinary function persistent of intellectual impairment Good outcome
Turgut <i>et al.</i> ^[3]	29 years	Chronic hydrocephalus	Complete excision	Progressive improvement of symptoms
Nadkarni <i>et al.</i> ^[4]	18 months	Delayed mental and physical development, ataxia, signs of raised ICP, vomiting	VP shunt Partial excision	Symptoms of raised ICP improved, ataxia worsened Slow improvement after rehabilitation
Azzimondi <i>et al.</i> ^[5]	68 years	Chronic hydrocephalus	Subtotal excision	Progressive ataxia, persistent urinary incontinence and memory impairment
Acar <i>et al.</i> ^[6]	73 years	Normal pressure hydrocephalus	Complete excision	Died from ischemic stroke; size of the fourth ventricle had normalized postoperatively
Szucs <i>et al.</i> ^[7]	32 years	Depression, signs of acute occlusive hydrocephalus	Subtotal excision	Good outcome
Bonde <i>et al.</i> ^[8]	27 years	Headache, truncal ataxia	Complete excision	Good outcome
	3 years	Headache, vomiting, drowsiness, ataxia	VP shunt Partial excision	Symptoms of raised ICP improved, ataxia worsened Good outcome
	52 years	Headache, vomiting, truncal ataxia	VP shunt Partial excision	Good outcome Symptoms of raised ICP improved, ataxia worsened
Westermaier <i>et al.</i> ^[9]	34 years	Progressive vertigo, slight ataxia	Complete excision	Good outcome Good outcome
Martinoni <i>et al.</i> ^[10]	32 years	Normal pressure hydrocephalus	Endoscopic cyst marsupialization and 3 rd ventriculostomy	Good outcome
Present case	55 years	Progressive loss of memory, unsteady gait, paraparesis	Endoscopic cyst marsupialization and 3 rd ventriculostomy	Good outcome

VP – Ventriculoperitoneal; ICP – Intracranial pressure

and consent, surgery was performed by pure anterior trans-frontal endoscopic cyst fenestration/marsupialization and standard third ventriculostomy. The wake-up was uneventful; the patient improved rapidly and can be discharged home on the seventh postoperative day. Four weeks later, clinical follow up showed a patient in a good condition able to walk independently, and her MMSE score had improved from 22 to 28/30. Brain MRI checks at 2, 6, and 12 months showed a progressive reduction in the size of the cyst and aqueduct as well as of the ventricular cavities [Figure 2]. Patient follow-up has continued for 22 months, with all checks showing neurological stability; neither delayed hydrocephalus and oculomotor problems nor hypothalamic dysfunction has, so far, been recorded, and the patient reports a generalized sense of well-being.

Surgical Technique

The procedure is usually performed with the patient under general anesthesia and in a supine position. The head is

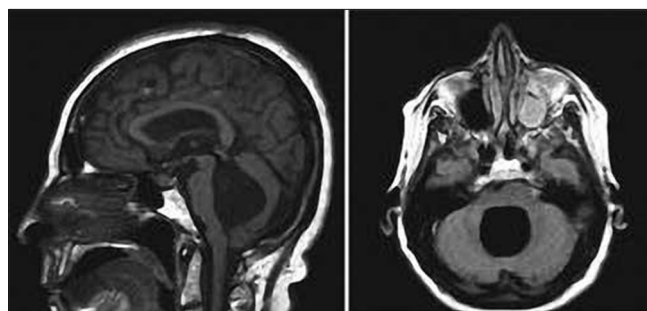


Figure 1: Sagittal and axial magnetic resonance imaging T1-Weighted showed a dilated fourth ventricle due to an arachnoid cyst causing tri-ventricular hydrocephalus with trans-ependymal cerebrospinal fluid resorption

lightly flexed. The operation is planned and completed with the aid of a rigid endoscope of 0° and 30° using a free-hand technique. We used the Hopkins II optical system (Endoscopy-America, Charlton, MA), with an operative channel by Karl Storz (Tuttlingen, Germany), 30 cm long and 2.9 mm in diameter. An Image-Guided

Surgery (IGS) system was used (BrainLab VectorVision). A single frontal right-sided burr hole is performed, and its position was chosen and verified by the IGS to obtain a trajectory to reach easily the aqueduct, the fourth ventricle, and the floor of the third ventricle simultaneously. The operative approach consists of a linear (1.5 cm) right frontal incision placed rather anteriorly, possibly along the hairline [Figure 3], to easily direct the endoscope toward the posterior portion of the third ventricle and aqueduct.^[12] Following placement of the burr hole, dural coagulation, and pial piercing, the endoscope is advanced toward the lateral ventricle; after entering the foramen of Monro, the endoscope direction is readjusted and following the ventricular landmarks and the indications of the neuronavigation system, aimed toward the aqueduct and then the fourth ventricle. The cyst is identified and after visual inspection, a careful coagulation of its surface is performed aiming for as large a fenestration as possible, completed by forceps [Figure 4]. Following cyst marsupialization, a standard endoscopic third ventriculostomy was done via the same hole/approach to treat the hydrocephalus.

Discussion

ACs within the fourth ventricle have rarely been reported in the literature. It is reasonable to think that ACs are congenital anomalies resulting from a duplication of the arachnoid membrane during embryological arachnoid cistern formation.^[13,14] Frequently, ACs are found incidentally; when clinical symptoms arise, they are directly in relation to the cyst location. MRI is currently the diagnostic gold standard for such a pathology as it allows detailed study and analysis of the various cysts features. MRI flowmetry is most important to delineate the flow of CSF, which can differentiate an AC from a trapped fourth ventricle. Ventriculoperitoneal (VP) shunting can provide transient or incomplete improvement of symptoms,^[1,2,8] and a third ventriculostomy may only release ICP in occlusive hydrocephalus.^[2] However, unchanged or even worsened signs of cerebellar or brainstem dysfunction following VP shunts have been reported,^[1,2,4,8] suggesting that the CSF diversion procedure does not constitute a durable solution. Currently, endoscopic fenestration is a worldwide accepted procedure for managing ACs in many locations except within the fourth ventricle. A fourth ventricle AC may be approached either via the third or the fourth ventricle.^[15] Endoscopic fenestration of a fourth ventricle AC cyst has already been described with good postoperative results, although, until date, there have been only a few attempts to treat such a pathology in a purely endoscopic fashion. The first case of a fourth ventricle AC successfully managed by an endoscopic procedure alone via the third ventricle was recently reported by Martinoni *et al.*;^[10] the former technique has the advantage of allowing both a cyst fenestration and a third ventriculocisternostomy at the

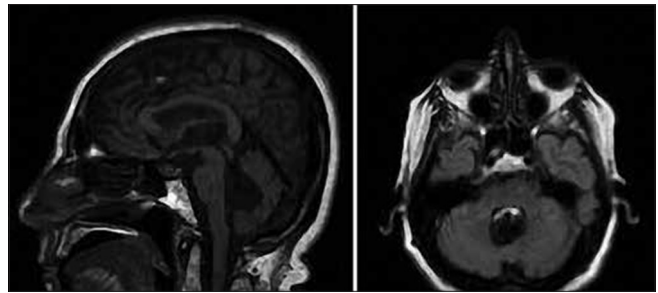


Figure 2: Sagittal and axial magnetic resonance imaging T1-Weighted showed a progressive reduction in size of the cyst and aqueduct as well as of the ventricular cavities

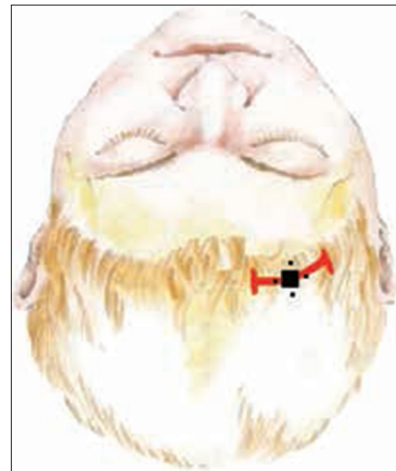


Figure 3: Linear (1.5 cm) right frontal incision placed anteriorly on a frontal wrinkle or along the hairline

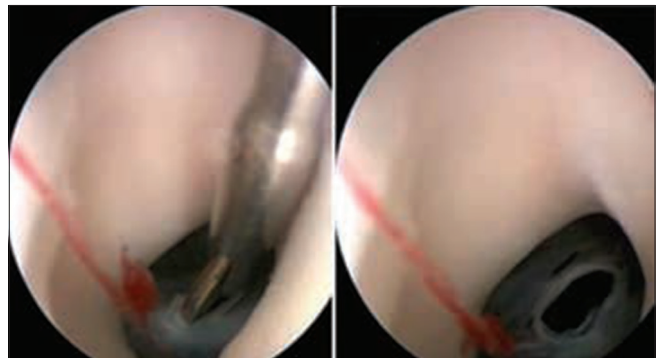


Figure 4: Endoscopic photos showing cyst fenestration/marsupialization and third ventriculostomy

same stage. This procedure might prevent the occurrence of hydrocephalus in case of impeded free pericystic CSF circulation or cyst recurrence, representing a remarkable advantage compared to simple CSF diversion. In fact, a case of sudden death in a fourth ventricle AC has been reported due to shunt failure.^[16] From our experience, we believe that, when possible, pure endoscopic cyst fenestration/marsupialization and third ventriculostomy could represent a valid and less invasive option to manage such a pathology as an alternative to cyst open complete or partial microsurgical resection. However, the latter

should still be considered in case of tonsillar herniation; it is also important to consider that the former technique presents a few limitations as follows: (1) The absence of hydrocephalus (ventriculomegaly constitutes a crucial anatomical condition), (2) the presence of a narrow (not dilated) aqueduct, and (3) the presence of intracystic septation, each of which make endoscopic AC fenestration/marsupialization not possible. Finally, it is worth of noting that open microsurgical procedures have a globally higher postoperative morbidity related to vermis manipulation/splitting.

Conclusion

Fourth ventricle ACs are rare entities and sometimes either mistaken or misdiagnosed as communicating hydrocephalus. MRI is the most important diagnostic tool, which can help to identify and analyze cysts in detail. Different procedures have been performed to restore normal CSF dynamic and pressure, including shunting and partial or complete excision of the cyst by open microsurgery. Endoscopic fenestration is now considered the procedure of choice for the treatment of symptomatic ACs in other locations, and the procedure could constitute an effective, less invasive, less morbid, and elegant way to manage the fourth ventricle AC as well.

Financial support and sponsorship

Nil.

Conflicts of interest

There are no conflicts of interest.

References

- Di Rocco C, Di Trapani G, Iannelli A. Arachnoid cyst of the fourth ventricle and “arrested” hydrocephalus. *Surg Neurol* 1979;12:467-71.
- Korosue K, Tamaki N, Fujiwara K, Matsumoto S. Arachnoid cyst of the fourth ventricle manifesting normal pressure hydrocephalus. *Neurosurgery* 1983;12:108-10.
- Turgut M, Ozcan OE, Onol B. Case report and review of the literature: Arachnoid cyst of the fourth ventricle presenting as a syndrome of normal pressure hydrocephalus. *J Neurosurg Sci* 1992;36:55-7.
- Nadkarni T, Hande A, Nagpal R. Arachnoid cyst within the fourth ventricle – A case report. *Br J Neurosurg* 1995;9:675-8.
- Azzimondi G, Calbucci F, Rinaldi R, Vignatelli L, D’Alessandro R. Arachnoid cyst in the region of the fourth ventricle mimicking clinical picture of normal pressure hydrocephalus. *Neurosurg Rev* 1995;18:269-71.
- Acar O, Kocaogullar Y, Güney O. Arachnoid cyst within the fourth ventricle: A case report. *Clin Neurol Neurosurg* 2003;105:93-4.
- Szucs A, Várady P, Pestality P, Dániel F, Lalit N, Kenéz J. Occlusive hydrocephalus caused by a fourth ventricle arachnoid cyst. *Ideggyogy Sz* 2008;61:54-8.
- Bonde V, Muzumdar D, Goel A. Fourth ventricle arachnoid cyst. *J Clin Neurosci* 2008;15:26-8.
- Westermaier T, Vince GH, Meinhardt M, Monoranu C, Roosen K, Matthies C. Arachnoid cysts of the fourth ventricle – Short illustrated review. *Acta Neurochir (Wien)* 2010;152:119-24.
- Martinoni M, Toni F, Lefosse M, Pozzati E, Marliani AF, Mascari C. Endoscopic treatment of a fourth ventricle arachnoid cyst via the third ventricle: A case report. *Neurosurgery* 2014;10 Suppl 2:E374-7.
- Vernooij MW, Ikram MA, Tanghe HL, Vincent AJ, Hofman A, Krestin GP, *et al.* Incidental findings on brain MRI in the general population. *N Engl J Med* 2007;357:1821-8.
- Chibbaro S, Di Rocco F, Makiese O, Reiss A, Poczos P, Mirone G, *et al.* Neuroendoscopic management of posterior third ventricle and pineal region tumors: Technique, limitation, and possible complication avoidance. *Neurosurg Rev* 2012;35:331-38.
- Miyagami M, Tsubokawa T. Histological and ultrastructural findings of benign intracranial cysts. *Noshuyo Byori* 1993;10:151-60.
- Rengachary SS, Kennedy JD. Intracranial arachnoid and ependymal cysts. *Neurosurgery* 1996;3:3709-28.
- Cinalli G, Spennato P, Savarese L, Ruggiero C, Aliberti F, Cuomo L, *et al.* Endoscopic aqueductoplasty and placement of a stent in the cerebral aqueduct in the management of isolated fourth ventricle in children. *J Neurosurg* 2006;104 1 Suppl:21-7.
- Prezerakos GK, Kouyialis AT, Ziaka DS, Boviatsis EJ. Sudden death due to 4th ventricle arachnoid cyst. *Ir J Med Sci* 2011;180:769-70.