

Table 1 Reported cases of lichen planus associated with COVID vaccination

	Sex/Age	COVID-vaccine	LP onset	Successive doses	Type of LP	Diagnosis	Treatment
Troeltzsch M, <i>et al.</i> ⁵	Male/ 49 year	Ad26.COVS.2.S (Johnson & Johnson)	6 days after	NA	Oral	Oral mucosa biopsy	Topical clobetasol
Merhy R, <i>et al.</i> ⁶	Female/ 56 year	Pfizer-BioNTech COVID-19 vaccine	1 week after 1 st dose	NR	Cutaneous	Skin biopsy	NR
Hiltun I. <i>et al.</i> ⁷	Female/ 56 year	Pfizer-BioNTech COVID-19 vaccine	2 days after 2 nd dose	NA	Flare of preexisting cutaneous LP	Skin biopsy	High-potency topical corticosteroids
Sharda P, <i>et al.</i> ⁸	Female / 35 year	NR	2 weeks after	NA	Oral	Oral mucosa biopsy	NR
Piccolo V, <i>et al.</i> ⁹	Female 64 year	Pfizer-BioNTech COVID-19 vaccine	5 days after 1 st dose	Recurrence	Cutaneous LP over vitiligo areas	Clinical findings	Topical and systemic corticosteroids
Present report	Female/ 29 year	Pfizer-BioNTech COVID-19 vaccine	1 week after 1 st dose	Exacerbation	Cutaneous LP over vitiligo and normal skin areas	Skin biopsy	Topical and systemic corticosteroids methotrexate

NA, non-applicable; NR, non-registered.

Conflicts of interest

The authors have no conflicts of interest to declare.

Data availability statement

The data presented in this study are available on request from the corresponding author.

E. Bularca,*  J. Monte-Serrano,  P. Villagrasa-Boli, A. Lapeña-Casado, S. de-la-Fuente 

Department of Dermatology, Lozano Blesa University Clinical Hospital of Zaragoza, Zaragoza, Spain

*Correspondence: E. Bularca. E-mail: eabularca@gmail.com

References

- Zafar M, Ewnetu B, Ahmed S, Iqbal U, Whitehead M. COVID-19 vaccination-induced rash: does the choice of vaccine matter? *Cureus* 2021; **13**(6): e15490. <https://doi.org/10.7759/cureus.15490>
- Lai YC, Yew YW. Lichen planus and lichenoid drug eruption after vaccination. *Cutis* 2017; **100**(6): E6–E20.
- Nogueira PA, Carneiro S, Ramos-e-Silva M. Oral lichen planus: an update on its pathogenesis. *Int J Dermatol* 2015; **54**(9): 1005–1010. <https://doi.org/10.1111/ijd.12918>
- Alter G, Yu J, Liu J *et al.* Immunogenicity of Ad26.COVS.2.S vaccine against SARS-CoV-2 variants in humans. *Nature* 2021; **596**(7871): 268–272. <https://doi.org/10.1038/s41586-021-03681-2>
- Troeltzsch M, Gogl M, Berndt R, Troeltzsch M. Oral lichen planus following the administration of vector-based COVID-19 vaccine (Ad26.COVS.2.S). *Oral Dis* 2021. <https://doi.org/10.1111/odi.14025>. Online ahead of print.
- Merhy R, Sarkis AS, Kaikati J, El Khoury L, Ghosn S, Stephan F. New-onset cutaneous lichen planus triggered by COVID-19 vaccination. *J Eur Acad Dermatol Venereol* 2021; **35**(11): e729–e730. <https://doi.org/10.1111/jdv.17504>
- Hiltun I, Sarriguarte J, Martínez-de-Espronedea I *et al.* Lichen planus arising after COVID-19 vaccination. *J Eur Acad Dermatol Venereol* 2021; **35**(7): e414–e415. <https://doi.org/10.1111/jdv.17221>

8 Sharda P, Mohta A, Ghiya BC, Mehta RD. Development of oral lichen planus after COVID-19 vaccination – a rare case report. [published online ahead of print, 2021 Oct 4]. *J Eur Acad Dermatol Venereol*. 2022; **36**(2): e82–e83. <https://doi.org/10.1111/jdv.17718>

9 Piccolo V, Mazzatenta C, Bassi A *et al.* COVID vaccine-induced lichen planus on areas previously affected by vitiligo. *J Eur Acad Dermatol Venereol*. 2022; **36**(1): e28–e30. <https://doi.org/10.1111/jdv.17687>.

DOI: 10.1111/jdv.18001

Reply to “Dermatoses caused by face mask wearing during the COVID-19 pandemic”

Editor,

We read with interest the paper of Yu Olisova *et al.* recently published on JEADV¹ about different dermatoses caused by face mask wearing during the COVID-19 pandemic. The authors warned on the localization of lesions, typically observed only under the mask on cheeks, chin, and nasal bridge. We present a case series observed in our centre, which adds some hints of discussion.

Ten patients (four females and six males, aged 32–74 years) presented with psoriasis on retro-auricular area induced by COVID mask. Eight of them were affected by psoriasis and received biological treatment, including etanercept (2/8 pts), adalimumab (2/8 pts), brodalumab (1/8 pt), ustekinumab (1/8 pt), secukinumab (1/8 pt) and guselkumab (1/8 pt). The patients had good control of the psoriasis with 5/8 patients with complete remission, while 3/8 patients presented a minimal residual

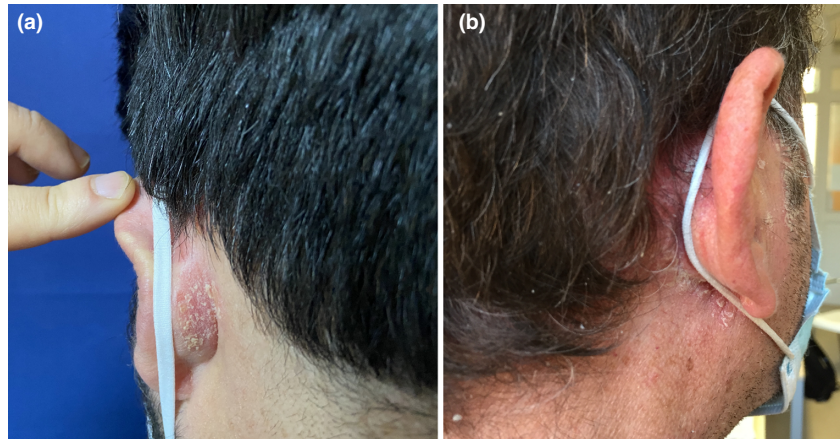


Figure 1 (a, b) Retro-auricular Koebner phenomenon in psoriatic patients wearing ear-looped masks.

psoriasis on the scalp and/or face. Two other patients were under adalimumab for Crohn's disease (CD) and denied a history of psoriasis. All the patients reported that the skin manifestation had appeared after the use of ear-looped masks, and all of them showed bilateral involvement of retro-auricular area. Therefore, a diagnosis of retro-auricular Koebner phenomenon (KP) was made in psoriatic patients, while a diagnosis of paradoxical psoriasis induced by KP was made in CD patients (Fig. 1).

The KP, also known as isomorphic reaction, describes the appearance of new lesions induced by an injury on unaffected skin totally identical to the underlying cutaneous disease in a predisposed patient. This condition is well known in psoriatic patients. KP is strictly related to the underlying skin disease affecting the patient. It is usually of modest entity, although more severe forms have been reported.^{2,3} In general, the management of the skin lesions induced by KP does not differ from the treatment of the underlying condition, although removing the cause represents the first step.

Our patients developed KP in the retro-auricular area due to the prolonged use of ear-looped masks. Interestingly, none of them had experienced KP before, not only in the retro-auricular area or on the adjoining scalp, but neither anywhere on the whole-body surface. The trauma causing KP may be mild, such as a scratch or injection, and the pressure exerted by the elastic of the mask behind the ear can be considered a minor injury, even though it is protracted over time.

Generally, koebnerization can be considered a clinical indicator of a relatively active or eruptive phase of the underlying dermatological condition.⁴ On the contrary, all our psoriatic patients were in a remission phase or showed minimal psoriasis, suggesting that even a minimal injury, if protracted, can induce a KP, also in psoriatic patients under treatment with total or

almost total control of the disease. The use of ear-looped masks induced a paradoxical psoriasis by KP in CD patients under anti-TNFs. An increasing number of skin manifestations secondary to face mask use have been reported among health care workers and in the general population.⁵ Bothra *et al.*⁶ reported retro-auricular dermatitis in individuals with prolonged use of ear-looped masks.

Topical steroids were prescribed in all cases, but the treatment solved the problem only temporarily. Consequently, the patients were invited to use masks without ear loops or to position them on the occipital area and nape. We also suggested using gaiters in order to by-pass the ears. After these changes in the use of the mask, all patients experienced retro-auricular psoriasis remission.

Acknowledgment

The patients in this manuscript have given written informed consent to the publication of their case details.

Conflicts of interest

Nothing to disclose.

Funding sources

None.

Data availability statement

Research data are not shared.

F. Bardazzi, L. Sacchelli,  C. Loi, F. Filippi, 
A. Guglielmo 

Dermatology Division - IRCCS Policlinico di Sant'Orsola, Department of Experimental, Diagnostic and Specialty Medicine (DIMES), Alma Mater Studiorum, University of Bologna, Bologna, Italy

*Correspondence: A. Guglielmo. E-mail: albaguglielmo@gmail.com

References

- 1 Olisova OY, Teplyuk NP, Grekova EV, Lepekhova AA. Dermatoses caused by face mask wearing during the COVID-19 pandemic. *J Eur Acad Dermatol Venereol* 2021; **35**: e738–e741.
- 2 Mutalik SD, Inamdar AC. Mask-induced psoriasis lesions as Köbner phenomenon during COVID-19 pandemic. *Dermatol Ther* 2020; **33**: e14323.
- 3 Kluger N. Tattooing and psoriasis: demographics, motivations and attitudes, complications, and impact on body image in a series of 90 Finnish patients. *Acta Dermatovenereol Alp Pannonica Adriat* 2017; **26**: 29–32.
- 4 van Geel N, Speeckaert R, De Wolf J *et al*. Clinical significance of Koebner phenomenon in vitiligo. *Br J Dermatol* 2012; **167**: 1017–1024.
- 5 Techasatian L, Lebsing S, Uppala R *et al*. The effects of the face mask on the skin underneath: a prospective survey during the COVID-19 pandemic. *J Prim Care Community Health* 2020; **11**: 2150132720966167.
- 6 Bothra A, Das S, Singh M, Pawar M, Maheswari A. Retroauricular dermatitis with vehement use of ear loop face masks during COVID-19 pandemic. *J Eur Acad Dermatol Venereol* 2020; **34**: e549–e552.

DOI: 10.1111/jdv.18012

A case of psoriatic spondyloarthritis exacerbation triggered by COVID-19 messenger RNA vaccine

Editor,

The coronavirus disease (COVID-19) vaccines have been rapidly delivered to prevent the spread of the disease. In Japan, the mRNA vaccines ‘BNT162b2’ (Pfizer–Biotech) and ‘mRNA-1273’ (Moderna) have been approved. Although the vaccines have effectively reduced the morbidity and severity of the disease, some patients developed autoimmune phenomena, such as thrombosis with thrombocytopenia and myocarditis.^{1,2} Also, exacerbations occurred in psoriasis patients after their vaccination.^{3,4} We report a case of psoriatic spondyloarthritis (SpA) exacerbation triggered by COVID-19 mRNA vaccine.

The patient was a 30-year-old man with a history of plaque psoriasis, well-controlled with topical treatment, for more than 10 years. He experienced lower back pain for several years, but he did not take any medications. Aside from that, the patient had no other subjective complaints. He had an unremarkable family history. Prior to vaccination, the patient reported no allergies, new medications or infectious symptoms. He received the second dose of the Moderna mRNA vaccine by the end of September 2021. One day following his second vaccination, the patient developed a low-grade fever of 37.5°C. Also, the patient’s psoriatic lesions, scattered throughout his entire body, worsened. This was associated with severe neck and hip pain, which appeared two days after the vaccination. He visited another hospital 40 days after the vaccination because of persistent fever with neck and hip pain. The blood tests showed a high C-

reactive protein (CRP) level, whilst the whole-body computed tomography scan showed no specific lesions. His COVID-19 antigen test was negative. He received loxoprofen, but it failed to alleviate his pain. Therefore, he was referred to our department 62 days after the vaccination.

On admission, he had normal vital signs. Physical examination revealed erythema with scaling throughout his entire body. Scalp and nail lesions were also observed (Fig. 1). His Psoriasis Area Severity Index, evaluated by a dermatologist, was 23.1. Joint swelling and tenderness were not noted, but he had enthesitis with a Spondyloarthritis Research Consortium of Canada Enthesitis Index of 8. The sacroiliac compression test was bilaterally positive. Blood testing revealed a CRP level of 4.90 mg/dL and an erythrocyte sedimentation rate level of 56 mm/h. Tests for bacterial and viral infection markers, antinuclear antibody, rheumatoid factor, anticyclic citrullinated peptide antibody and human leukocyte Antigen-B27 were negative. Radiography of sacroiliac joint showed bilateral narrowing space. Cervical magnetic resonance imaging (MRI) showed enhancement effects on cervical interspinous ligament and sacroiliac MRI showed bilateral sacroiliitis (Fig. 2). Based on these findings, he was diagnosed with psoriatic SpA exacerbation, and he was treated with ixekizumab, to which he had a good clinical response.

To the best of our knowledge, this is the first report of psoriatic SpA exacerbation triggered by COVID-19 mRNA vaccination. The mechanism behind psoriasis exacerbation after COVID-19 vaccination is likely similar to that of other vaccines. Vaccination induces interleukin (IL)-6, which stimulates T-helper 17 cells to produce IL-22, a significant contributor to keratinocyte proliferation in psoriasis.^{5,6}

In one report, all patients experienced psoriasis exacerbation within 14 days after their vaccination. Most exacerbations occurred after the second vaccination dose.^{3,4} However, there were no significant differences regarding the exacerbation of psoriasis between the vaccine types.^{3,4}

Although a high safety profile against the COVID-19 mRNA vaccine was observed in almost all psoriasis patients, and psoriasis patients should be recommended to receive COVID-19 vaccine,^{7,8} factors associated with psoriasis exacerbation after the COVID-19 vaccination have not been clarified yet. Further prospective studies are warranted to investigate the exacerbation in patients with psoriasis after COVID-19 mRNA vaccine. In conclusion, clinicians should be carefully aware of the occurrence of psoriasis exacerbation after COVID-19 vaccination.

Acknowledgement

The patient in this manuscript has given written informed consent to the publication of his case details.

Conflicts of interest

All authors declare no conflicts of interest.