

Single Case – General Neurology

Acute Susac Syndrome in a Recent User of Adulterated Cocaine: Levamisole as a Triggering Factor?

Klara De Baerdemaeker^a Chiara Mabilia^b Philippe Hantson^a
Vincent Di Fazio^c Thierry Duprez^b Alexandra Kozyreff^d
Vincent van Pesch^e Amina Sellimi^e

^aDepartment of Intensive Care, Cliniques St-Luc, Université catholique de Louvain, Brussels, Belgium; ^bDepartment of Neuroradiology, Cliniques St-Luc, Université catholique de Louvain, Brussels, Belgium; ^cNational Institute for Criminology and Criminalistics, Brussels, Belgium; ^dDepartment of Ophthalmology, Cliniques St-Luc, Université catholique de Louvain, Brussels, Belgium; ^eDepartment of Neurology, Cliniques St-Luc, Université catholique de Louvain, Brussels, Belgium

Keywords

Cocaine · Levamisole · Multifocal inflammatory leukoencephalopathy · Susac syndrome

Abstract

Susac syndrome (SS) is a central nervous system vasculitis characterized by the clinical triad of encephalopathy, sensorineural hearing loss, and visual disturbance caused by branch retinal artery occlusion. It is considered as an inflammatory disorder, and an autoimmune etiology is suggested. A 29-year-old man with a history of recent cocaine abuse developed the clinical features of SS. Toxicological analysis including hair testing revealed that cocaine had been adulterated with levamisole. After an initial clinical improvement following corticosteroid therapy, the introduction of mycophenolate mofetil was justified a few weeks later by the progression (or relapse) of the retinal injury, followed by complete recovery. The presence of levamisole has been documented in patients with multifocal inflammatory leukoencephalopathy (MIL). Further investigations are needed to determine if levamisole as an adulterant of cocaine could also play a role in the development of rapidly progressive

leukoencephalopathy in young men, with Susac or Susac-like syndromes as possible variants of MIL.

© 2020 The Author(s)
Published by S. Karger AG, Basel

Introduction

Susac syndrome (SS) is a rare central nervous system vasculitis characterized by the combination of encephalopathy, sensorineural hearing loss, and visual disturbance due to branch retinal artery occlusion [1]. Since its initial description by Susac et al. [2] in 1979, more than 300 cases have been reported. Female patients are more frequently affected than male patients who generally suffer from more aggressive forms of the disorder. The pathogenesis of SS is not yet fully understood but is usually considered as an inflammatory disease of putative autoimmune etiology [3]. On the other hand, exposure to levamisole in monotherapy has been associated with multifocal inflammatory leukoencephalopathy (MIL). The lesions are then prominent in the centrum ovale, per-lateral ventricles, and basal ganglia bilaterally [4]. These lesions appear distinct from those of cocaine-related leukoencephalopathy. Toxic agents have been rarely hypothesized as triggering cofactors of SS or variants [5]. We report a case of acute SS developed in a young man shortly after the start of levamisole-adulterated cocaine abuse.

Case Presentation

A 29-year-old man was referred to the emergency department (ED) due to severe headache and behavioral changes.

The symptoms had started 12 days before admission with the headache considered as migraine and treated by oral pain killers. The patient came back to the ED 2 days later with persisting headache and right-sided paresthesia. Brain computed tomography (CT) failed to reveal any abnormality, and the patient was sent home again with nonsteroidal anti-inflammatory drugs and tramadol.

Two days later, he developed severe behavioral and cognitive changes with incomprehensible vocalizations, anterograde amnesia, aggressiveness towards his family members, and agitation. Sleeping rhythm was inverted with alternating periods of apathy/somnolence and agitation.

Patient's medical history was unremarkable, and he did not take any medication. Occasional use of tobacco and alcohol was reported. We learned from his father that he had started regular cocaine consumption 3 months ago but should have stopped about one week before admission.

On admission, the patient was awake, but disorientated in time and place, and did not properly answer to questions. There was no sign of lateralization and cerebellar tests were normal. Neck stiffness and photophobia were noted.

Routine laboratory investigations were unremarkable, as well as blood and urine toxicological screening. Repeated brain CT was also normal. Lumbar puncture showed a normal opening pressure, and cerebrospinal fluid (CSF) analysis revealed 7 mononuclear cells/mm³ and a high protein level at 224 mg/dL. The albumin quotient was highly increased (37.9, normal value <6.5 under 40 years of age), confirming, together with the further brain magnetic resonance imaging (MRI) findings, significant alteration of the blood-CSF barrier permeability. Microbiological and viral CSF tests were negative. No CSF-specific IgG oligoclonal bands

were found. As infectious encephalitis was ruled out, antimicrobial and antiviral therapy was interrupted.

While staying in the ICU, the patient had been less agitated but remained disoriented in time and space and had suffered from transcortical sensitive aphasia. Brain MRI was performed 14 days after symptom onset which showed ubiquitous small lesions within white matter displaying high signal intensity on diffusion-weighted images and water diffusivity restriction on apparent diffusion coefficient (ADC) maps. The radiologist initially considered the hypothesis of disseminated ischemic foci due to cocaine-related vasoconstriction (not illustrated). Brain MRI examination was repeated after 3 days and showed numerous additional punctate lesions involving the corpus callosum, together with abnormal meningeal enhancement and contrast agent leakage in the CSF (Fig. 1).

Retinal fluoroangiography revealed multiple segmental occlusions of the central retinal artery (Fig. 2), and an audiogram showed bilateral but asymmetric sensorineural hearing loss, with a left predominance.

After the diagnosis of SS, bolus corticosteroid therapy was initiated using methylprednisolone 1 g daily for 5 days, followed by tapering oral doses. Toxicological investigations were completed by hair analysis using ultra-performance liquid chromatography tandem mass spectrometry operating in positive electrospray mode (Quattro Premier, Waters, Milford, MA, USA). Hair samples were cut into six segments of 1 cm, and the presence of cocaine, levamisole, opioids, and several amphetamines was investigated. Only cocaine together with metabolites, levamisole, and tramadol were detected. Quantification was possible using deuterated analogues: cocaine-D3 for cocaine and norcocaine, benzoylecgonine-D8 for benzoylecgonine, methylecgonine-D3 for methylecgonine, 6-acetylmorphine-D6 for levamisole, and tramadol-D3 for tramadol. The following concentration ranges were found in the hair: cocaine (>5,000 pg/mg), benzoylecgonine (>5,000 pg/mg), methylecgonine (68–113 pg/mg), norcocaine (581 to >1,000 pg/mg), levamisole (73–139 pg/mg), and tramadol (1,378–2,155 pg/mg). The patient was transferred from our institution to a rehabilitation center 13 days after admission. Cognitive status progressively improved, but the patient remained dysexecutive and had features of frontal lobe syndrome. Five weeks after discharge, the patient presented with a subacute left-eye central scotoma and altitudinal visual field deficit while still on a daily oral dose of 16 mg methylprednisolone. New retinal branch artery occlusions were documented on fluoroangiography (Fig. 2). However, brain MRI did not show additional microvascular ischemic lesions when compared to previous examination, and lepto-meningeal enhancement had significantly decreased (not shown). This relapse (or progression of the initial lesions) was again treated by repeated methylprednisolone pulse therapy followed by oral tapering. Immunosuppressive treatment with mycophenolate mofetil was started. At 10-month follow-up, the patient was asymptomatic. He resumed work and did not report any residual cognitive deficit, as confirmed by neuropsychological testing performed 3 months after the initial episode.

Discussion

Levamisole is an “old” antihelminthic and immunomodulatory drug still used in veterinary medicine. No more indications exist in human medicine, but it is unlawfully used to adulterate cocaine. The Dutch drug monitoring system has observed an increase of up to >70% of cocaine adulterated with levamisole from 2006 to 2014. Levamisole is cheap, has similar

physical properties as cocaine, and its metabolite (aminorex) has a longer half-life and amphetamine-like effects that can lengthen the effects of cocaine [6–8].

Significant complications were reported with levamisole use in human inflammatory disorders. They included leukopenia and agranulocytosis, as well as several forms of vasculitis (leukocytoclastic vasculitis, cutaneous necrotizing vasculitis, thrombotic vasculopathy). Most of these adverse effects may improve after discontinuation of levamisole therapy, but corticosteroid therapy was required in some cases [6, 7]. The most severe but rare cerebral complication of levamisole exposure is MIL which was not usually observed after the use of cocaine alone [7]. A large review of 203 cocaine users with suspected levamisole-related side effects failed to report a single case of MIL [6, 7]. Similarly, several observational reports of MIL-like syndrome after cocaine use failed to reveal the presence of levamisole [9–11]. In turn, recent case reports have documented the presence of levamisole in patients with MIL or related forms of the disorder with cocaine use [4, 12, 13]. As in a previously reported case, the patient presented a rapidly progressive leukoencephalopathy with clinical and radiological signs consistent with SS, including numerous inflammatory white matter foci with synchronous contrast-enhancement and decreased ADC value prominently involving the corpus callosum. The only significant difference between the two patients was the strong meningeal thickening and contrast enhancement observed in the herein reported patient, which was not present in the previously reported case [5]. Usually, features of levamisole-induced MIL include the subacute onset of cognitive disturbances together with motor and sensitive dysfunctions. The delay between exposure and symptoms ranges from days to weeks. The most severe neurological impairment usually occurs several days after symptom onset [14]. Multiple white matter lesions disclosing ring enhancement at post-contrast MR images are usually seen. Gray matter is usually spared in MIL. In turn, gray matter involvement is frequent in SS together with highly suggestive lesions of the mid-portion of the corpus callosum and leptomeningeal inflammation [2, 3].

SS is usually considered as a monophasic disorder contrasting with the relapsing-remitting (RR) course of multiple sclerosis, but longer follow-up of some SS patients has highlighted a possible RR course of the disorder [15].

Conclusion

An inflammatory and autoimmune physiopathology for the SS has been hypothesized, but the triggering conditions/antigens remain poorly identified. The documented relationship between levamisole and MIL and the observation of SS after the exposure to cocaine adulterated with levamisole raise the hypothesis that the latter could play a synergistic role as a triggering cofactor in the onset of Susac or Susac-like syndromes in cocaine users.

Statement of Ethics

The authors have no ethical conflicts to disclose. Written consent has been obtained from the patient.

Disclosure Statement

The authors have no conflicts of interest to declare.

Funding Sources

No sources to declare.

Author Contributions

K.D.B. was the ICU fellow in charge of the patient and wrote the draft of the manuscript; C.M. and T.D. were the neuroradiologists responsible for MR investigations and interpretation; P.H. was the ICU supervisor who revised and approved the final version of the manuscript; V.D.F. conducted hair testing; A.K. investigated visual complications; V.V.P. and A.S. were the neurologists who supervised the immune therapy.

References

- Vishnevskia-Dai V, Chapman J, Sheinfeld R, Sharon T, Huna-Baron R, Manor RS, et al. Susac syndrome: clinical characteristics, clinical classification, and long-term prognosis. *Medicine (Baltimore)*. 2016 Oct;95(43):e5223.
- Dörr J, Krautwald S, Wildemann B, Jarius S, Ringelstein M, Duning T, et al. Characteristics of Susac syndrome: a review of all reported cases. *Nat Rev Neurol*. 2013 Jun;9(6):307–16.
- Yan R, Wu Q, Ren J, Cui H, Zhai K, Zhai Z, et al. Clinical features and magnetic resonance image analysis of 15 cases of demyelinating leukoencephalopathy induced by levamisole. *Exp Ther Med*. 2013 Jul;6(1):71–4.
- Marrodan M, Acosta JN, Alessandro L, Fernandez VC, Carnero Contentti E, Arakaki N, et al. Clinical and imaging features distinguishing Susac syndrome from primary angiitis of the central nervous system. *J Neurol Sci*. 2018 Dec;395:29–34.
- Hantson P, Di Fazio V, Del Mar Ramirez Fernandez M, Samyn N, Duprez T, van Pesch V. Susac-like syndrome in a chronic cocaine abuser: could levamisole play a role? *J Med Toxicol*. 2015 Mar;11(1):124–8.
- Brunt TM, van den Berg J, Pennings E, Venhuis B. Adverse effects of levamisole in cocaine users: a review and risk assessment. *Arch Toxicol*. 2017 Jun;91(6):2303–13.
- Larocque A, Hoffman RS. Levamisole in cocaine: unexpected news from an old acquaintance. *Clin Toxicol (Phila)*. 2012 Apr;50(4):231–41.
- Vonmoos M, Hirsiger S, Preller KH, Hulka LM, Allemann D, Herdener M, et al. Cognitive and neuroanatomical impairments associated with chronic exposure to levamisole-contaminated cocaine. *Transl Psychiatry*. 2018;27:8(1):235.
- Blanc PD, Chin C, Lynch KL. Multifocal inflammatory leukoencephalopathy associated with cocaine abuse: is levamisole responsible? *Clin Toxicol (Phila)*. 2012 Jul;50(6):534–5.
- Vosoughi R, Schmidt BJ. Multifocal leukoencephalopathy in cocaine users: a report of two cases and review of the literature. *BMC Neurol*. 2015 Oct;15(1):208.
- Li S, Manyevitch R, Sedaliu K, Abdelbaki A, Gupta N, Kumar A, et al. Cocaine abuse: longitudinal MR imaging of lasting diffused leukoencephalopathy. *Neuroradiol J*. 2018 Apr;31(2):186–9.
- Vitt JR, Brown EG, Chow DS, Josephson SA. Confirmed case of levamisole-associated multifocal inflammatory leukoencephalopathy in a cocaine user. *J Neuroimmunol*. 2017 Apr;305:128–30.
- González-Duarte A, Williams R. Cocaine-induced recurrent leukoencephalopathy. *Neuroradiol J*. 2013 Oct;26(5):511–3.
- Wu VC, Huang JW, Lien HC, Hsieh ST, Liu HM, Yang CC, et al. Levamisole-induced multifocal inflammatory leukoencephalopathy: clinical characteristics, outcome, and impact of treatment in 31 patients. *Medicine (Baltimore)*. 2006 Jul;85(4):203–13.
- Vodopivec I, Prasad S. Short Follow-up Bias Confounds Estimates of the “Typical” Clinical Course of Susac Syndrome. *J Neuroophthalmol*. 2017 Jun;37(2):149–53.

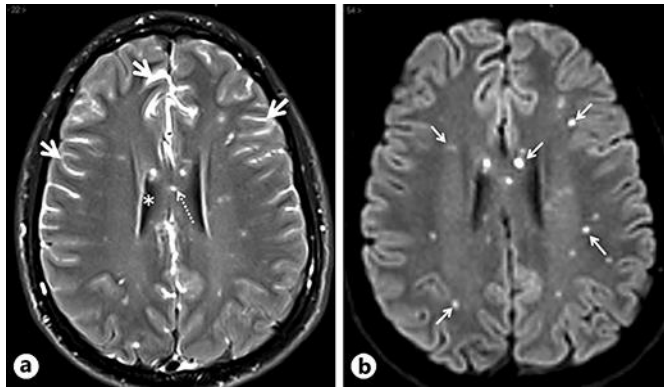


Fig. 1. Magnetic resonance workup. **a** Contrast-enhanced transverse fluid-attenuated inversion recovery view showing numerous hyperintense foci within brain parenchyma, i.e. within corpus callosum (dotted arrow), together with strong enhancement of peripheral subarachnoid spaces (arrows) contrasting with normal signal suppression of intraventricular CSF (asterisk). This unusual feature assessed intense meningeal inflammation with subsequent massive leakage of contrast agent molecules within surrounding CSF. **b** Transverse diffusion-weighted (DW) view in similar slice location as **a** with b factor at $1,000 \text{ mm}^2/\text{s}^2$ showing punctate foci seen on previous images as hyperintense foci of restricted water diffusivity with strongly decreased apparent diffusion coefficient (ADC) values (parametric ADC map not shown). Synchronous DW positivity of all lesions closely matched the synchronous enhancement of all lesions seen on post-contrast T1-weighted views (not shown).

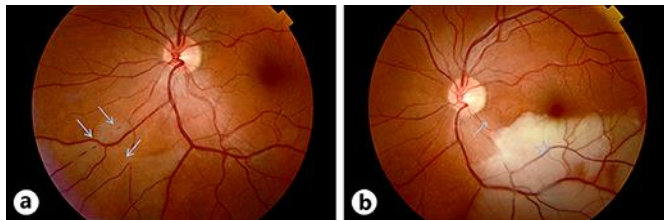


Fig. 2. Fluoroangiography at 1 week (**a**) and 6 weeks (**b**). **a** Segmented arterial occlusions (arrows) on the nasal-inferior branch of the central retinal artery. **b** Whitish ischemic retinal edema (star) on the inferior part of the macula due to a new episode of arterial occlusion affecting the temporal-inferior branch of the central retinal artery (arrow).