

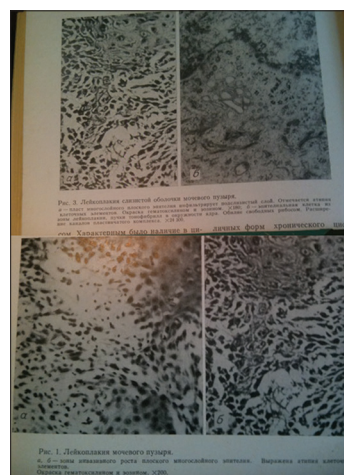
## Urological concern after nuclear accidents

This article<sup>[1]</sup> has cited the letter<sup>[2]</sup> along with several reports on the urinary bladder carcinogenesis.<sup>[3-6]</sup> Moreover, the statement “at least, chronic exposure to ionizing radiation is considered as an important stress and can result in deoxyribonucleic acid dysfunction,”<sup>[1]</sup> given with references to,<sup>[2,4]</sup> does not agree with.<sup>[2]</sup> In fact, the letter<sup>[2]</sup> is commenting on the studies.<sup>[4,6]</sup> The following should be added to the previously published comments.<sup>[2,7]</sup>

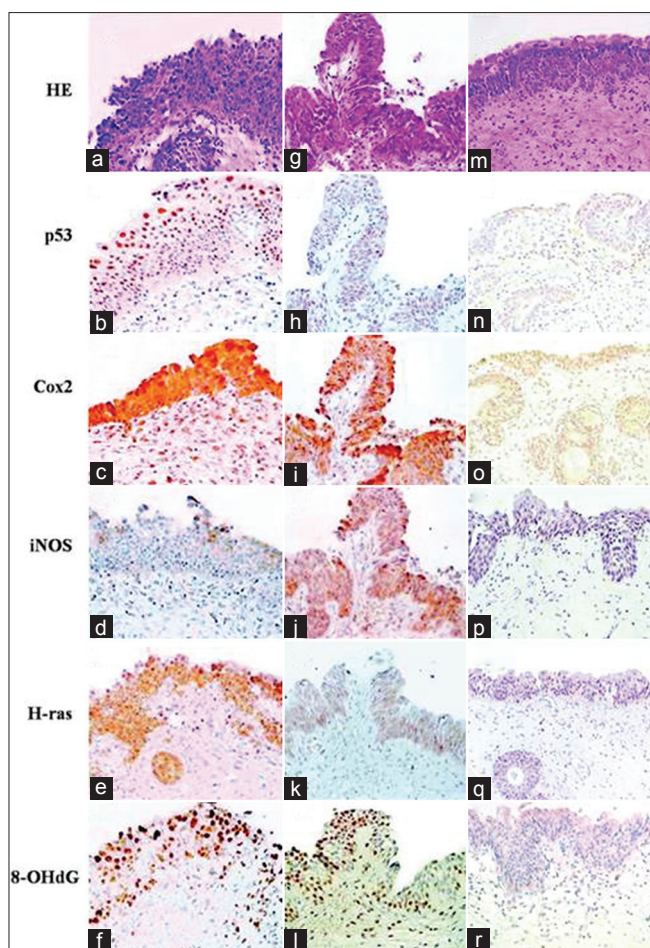
In the research series,<sup>[3-12]</sup> in different groups of patients with benign prostatic hyperplasia (BPH), from the contaminated areas after the Chernobyl accident and the city of Kiev (not officially counting to the contaminated territories), severe urothelial dysplasia and/or carcinoma *in situ* (CIS) were found by bladder biopsy as frequently as in 56-96% of all randomly selected cases.<sup>[3,6]</sup> The random character of the bladder specimens was pointed out: “The Institute of Urology (Academy of Medical Sciences of Ukraine) in Kiev during 1994-2006 collected all BPH patients who underwent suprapubic prostatectomy and all these patients were included in our study in different years without exception, along with a small number of females with chronic cystitis.”<sup>[3]</sup> The following was stated about the patients with BPH studied by the bladder biopsy: “Irradiation cystitis with multiple foci of severe urothelial dysplasia/CIS and some invasive transitional cell carcinoma (TCC) were observed in 96/66, 76/56 and 56/8% of patients in groups I, II and III respectively” (the group III was from non-contaminated areas).<sup>[8]</sup> In the Handout by the same authors, distributed at the XXIII International Congress of the International Academy of Pathology on October 15-20, 2000 in Nagoya, Japan, the following was written: “Histologically the different forms of proliferative cystitis, which were frequently combined and had features of irradiation cystitis with multiple areas of severe dysplasia and CIS, sometimes associated with small TCC, occurred in 97% of patients from the radiocontaminated areas of Ukraine.” These percentages are obviously unrealistic and indicative of false-positivity.

Looking at the figures in the earlier articles,<sup>[10,11]</sup> it appears probable that overdiagnosis of dysplastic and neoplastic bladder lesions could have happened also before: both articles<sup>[10,11]</sup> used one and the same image of bladder leukoplakia with invasion (according to the legend). However,

invasive growth is not clearly recognizable [Figure 1]. Furthermore, the illustrations from the article,<sup>[3]</sup> available online, should be commented (compare Figures 2 and 3 available at <http://www.carcin.oxfordjournals.org/content/30/11/1821.long> Figure 2. From the caption: “Small developing papillary urothelial carcinoma with severe dysplasia (G-L),”<sup>[3]</sup> our comment: thick sections; in some plates the nuclei are insufficiently stained. No severe dysplasia is recognizable. A small papilloma or papillary cystitis cannot be excluded [Figure 3]. From the caption: “...dysplasia (A-D) and small papillary urothelial carcinoma (E-G),”<sup>[3]</sup> Comment: mild to moderate atypia might be present; but neither severe dysplasia nor carcinoma are recognizable. All the slides are obviously too thick for reliable diagnostics. Insufficient quality of specimens could have been caused also by fixation, processing-related factors and electrocoagulation. The same is true for the similar images in the article<sup>[9]</sup> available at [http://www.onlinelibrary.wiley.com/doi/10.1002/\(SICI\)1097-0215\(20000615\)86:6%3C790:AID-IJC6%3E3.0.CO;2-Q/full](http://www.onlinelibrary.wiley.com/doi/10.1002/(SICI)1097-0215(20000615)86:6%3C790:AID-IJC6%3E3.0.CO;2-Q/full). Figure 4a from<sup>[9]</sup> and Figure 2g from<sup>[3]</sup> are identical. Note that overdiagnosis could have entailed over-manipulation (cystoscopy) and overtreatment. It cannot be excluded that the above-mentioned irradiation cystitis or “Chernobyl cystitis,”<sup>[3,12]</sup> characterized among others by the “reactive epithelial proliferation associated



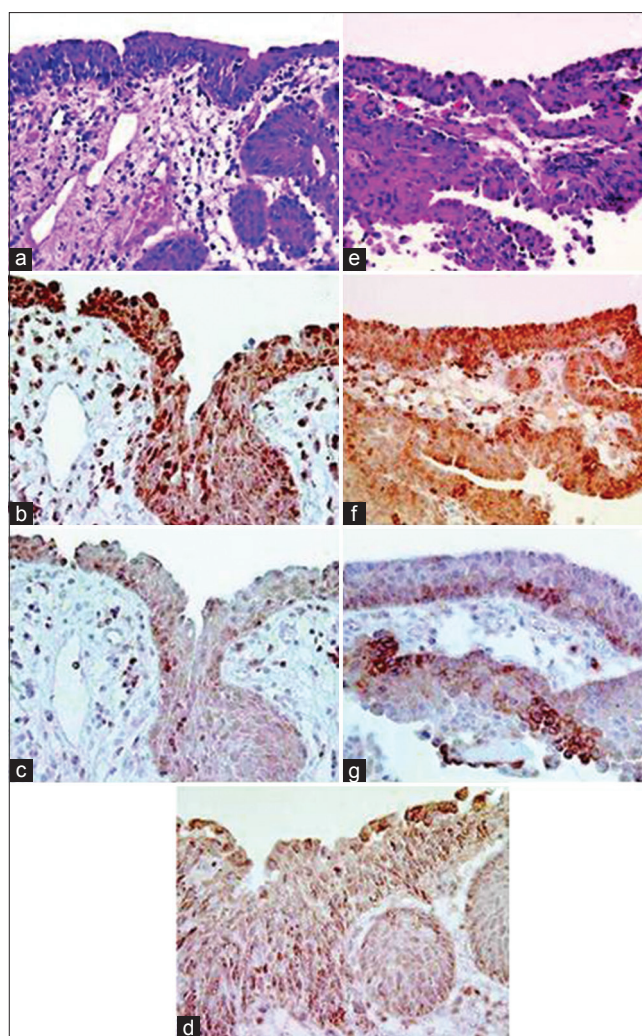
**Figure 1:** Bladder leukoplakia with invasion. Poor quality of the images and obviously also of the specimens. The invasive growth is not clearly recognizable. The images top left and bottom right are identical. Commented in the text



**Figure 2:** Histological and immunohistochemical findings: CIS (a-f), small developing papillary urothelial carcinoma with dysplasia (g-r). (a, g and m) H and E, (b, h and n) p53 expression, (c, i and o) Cox2 expression, (d, j and p) iNOS expression, (e, k and q) H-ras expression and (f, l and r) 8-OHdG expression. Magnification  $\times 100$

with hemorrhage, fibrin deposits, fibrinoid vascular changes and multinuclear stromal cells<sup>[12]</sup> was at least in part caused and/or maintained by repeated cystoscopies with mapping biopsies, electrocoagulation etc.

Furthermore, the cesium-137 activity concentration in urine (the mean value in the most exposed group was 6.47 Bq/L), reported,<sup>[3,6]</sup> and possible radiation doses that could have resulted from it, were discussed.<sup>[7,13]</sup> It was concluded that the doses would be too low to cause any increase in bladder malignancy or the “radiation induced chronic proliferative atypical cystitis,” reportedly characterized by multiple areas of severe dysplasia and CIS.<sup>[3]</sup> Retractions are on the up today,<sup>[14]</sup> but not in the former Soviet Union, where, as far as we know, no articles have been retracted so far.<sup>[15]</sup> The authors of the papers<sup>[3-6]</sup> should consider retraction to prevent repetition of suboptimal practices.<sup>[16]</sup> Although some screening programs are very effective at saving lives, excessive screening for cancer and precancerous lesions can be associated with a risk of

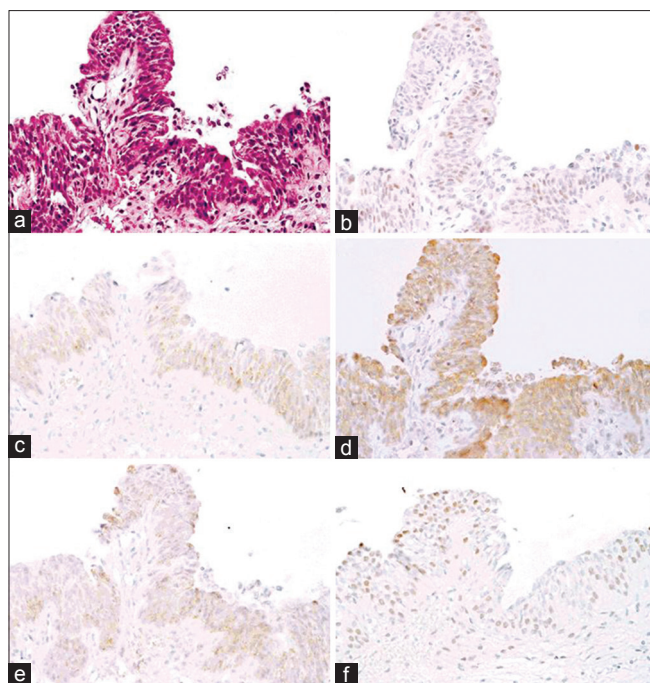


**Figure 3:** Urothelial dysplasia (a-d) and small papillary urothelial carcinoma (e-g). (a) H and E, (b) p65 expression, (c) p50 expression, (d) p38 expression, (e) H and E, (f) p65 expression and (g) p50 expression. Magnification  $\times 100$

overdiagnosis and overtreatment,<sup>[17]</sup> especially if diagnostic facilities are not perfect, including at the same time invasive manipulations.

Pathology of the prostate gland and erectile dysfunctions after the Chernobyl accident, discussed<sup>[1]</sup> are different topics, deserving a separate review of the literature. However the study,<sup>[18]</sup> not cited in,<sup>[1]</sup> should be mentioned, the more so as histopathological data are absent from the PubMed abstract of this article published in the principal journal of Russian pathologists “Arkiv Patologii” (Archives of Pathology): in 75.6% of testicles picked at random (forensic cases, residents of Kaluga district of Russian Federation) was found paucity or absence of germ cells, affecting  $> 10\%$  of spermatid tubules, which was interpreted as “hypospermatogenesis” associated with decreased fertility and attributed to the radiation exposure due to the Chernobyl accident.<sup>[18]</sup>





**Figure 4:** Small developing papillary TCC with severe dysplasia. (a) H and E. (b) p53 expression. (c) H-ras expression. (d) COX-2 expression. (e) iNOS expression. (f) 8-OHdG expression. Magnification x100

### Financial support and sponsorship

Nil.

### Conflicts of interest

There are no conflicts of interest.

Sergei V. Jargin

Department of Pathology, People's Friendship University of Russia, Clementovski per 6-82, 115184 Moscow, Russia

#### Address for correspondence:

Dr. Sergei V. Jargin,  
Department of Pathology, People's Friendship University of  
Russia, Clementovski per 6-82, Moscow 115184, Russia.  
E-mail: sjargin@mail.ru

### REFERENCES

1. Wiwanitkit V. Urological concern and postcrisis Japanese nuclear accident. *J Urol* 2012;4:135-6.
2. Jargin SV. Re: Involvement of ubiquitination and sumoylation in bladder lesions induced by persistent long-term low dose ionizing radiation in humans and Re: DNA damage repair in bladder urothelium after the Chernobyl accident in Ukraine. *J Urol* 2007;177:794.
3. Romanenko A, Kakehashi A, Morimura K, Wanibuchi H, Wei M, Vozianov A, *et al.* Urinary bladder carcinogenesis induced by chronic exposure to persistent low-dose ionizing radiation after Chernobyl accident. *Carcinogenesis* 2009;30:1821-31.
4. Romanenko A, Morimura K, Wei M, Zaporin W, Vozianov A,

5. Fukushima S. DNA damage repair in bladder urothelium after the Chernobyl accident in Ukraine. *J Urol* 2002;168:973-7.
6. Romanenko AM, Morimura K, Kinoshita A, Wanibuchi H, Takahashi S, Zaporin WK, *et al.* Upregulation of fibroblast growth factor receptor 3 and epidermal growth factor receptors, in association with Raf-1, in urothelial dysplasia and carcinoma *in situ* after the Chernobyl accident. *Cancer Sci* 2006;97:1168-74.
7. Romanenko AM, Kinoshita A, Wanibuchi H, Wei M, Zaporin WK, Vinnichenko WI, *et al.* Involvement of ubiquitination and sumoylation in bladder lesions induced by persistent long-term low dose ionizing radiation in humans. *J Urol* 2006;175:739-43.
8. Jargin SV. Overestimation of Chernobyl consequences: Biophysical aspects. *Radiat Environ Biophys* 2009;48:341-4.
9. Romanenko A, Fukushima S. Prediction of urinary bladder cancer induction in Ukraine after the Chernobyl accident. XXIII International Congress of the International Academy of Pathology and 14<sup>th</sup> World Congress of Academic and Environmental Pathology, 15-20 October 2000, Nagoya, Japan. *Pathol Int* 2000;50 Suppl: A70.
10. Romanenko A, Morimura K, Wanibuchi H, Salim EI, Kinoshita A, Kaneko M, *et al.* Increased oxidative stress with gene alteration in urinary bladder urothelium after the Chernobyl accident. *Int J Cancer* 2000;86:790-8.
11. Romanenko AM, Klimenko IA, Iurakh GIu. Leukoplakia of the bladder. *Arkh Patol* 1985;47:52-8.
12. Romanenko AM. Chronic cystitis in the aspect of its relationship with precancerous conditions. *Arkh Patol* 1982;44:52-8.
13. Romanenko A, Vozianov A, Morimura K, Fukushima S. Correspondence re: W. Paile's letter to the editor. *Cancer Res.*, 60:1146, 2000. *Cancer Res* 2001;61:6964-5.
14. Jargin SV. On overestimation of Chernobyl accident effects: Urinary bladder tumors. *Med Radiol Radiat Safety (Moscow)* 2007;52:83-4.
15. Van Noorden R. Meeting targets lab lapses. *Nature* 2013;497:300-1.
16. Jargin S. Criticism of scientific misconduct in the former SU. Retraction watch. Available from: <http://www.retractionwatch.com/what-people-are-saying-about-retraction-watch/>. [2014 Feb 22].
17. Jargin SV. Renal biopsy research in the former Soviet union: Prevention of a negligent custom. *ISRN Nephrol* 2013; Volume 2013, Article ID 980859, 5 pages, <http://dx.doi.org/10.5402/2013/980859>
18. Early warnings. *Nature* 2009;458:679.
19. Lysenko AI, Kirpatovskii ID, Pisarenko SS. Morphological changes in male sexual glands in Kaluga regions contaminated with radionuclides. *Arkh Patol* 2000;62:27-31.

This is an open access journal, and articles are distributed under the terms of the Creative Commons Attribution-NonCommercial-ShareAlike 4.0 License, which allows others to remix, tweak, and build upon the work non-commercially, as long as appropriate credit is given and the new creations are licensed under the identical terms.

Access this article online	
Quick Response Code:	Website: <a href="http://www.urologyannals.com">www.urologyannals.com</a>
	DOI: 10.4103/0974-7796.236525

**How to cite this article:** Jargin SV. Urological concern after nuclear accidents. *Urol Ann* 2018;10:240-2.