
An unusual case of spontaneous pneumomediastinum secondary to tracheal tear in a trumpeter

INTRODUCTION

Music brings happiness to people but it can be hazardous to those playing the music instrument. Playing musical instruments are associated with variety of health hazards such as hypersensitivity pneumonitis, anthrax, tuberculosis, asthma, inguinal hernia, and laryngocele.^[1,2] Herein, we describe a rare case of spontaneous pneumomediastinum due to tracheal tear in a trumpeter. Spontaneous pneumomediastinum can be defined as presence of free air from the airways or the lung parenchyma in the mediastinum without any apparent antecedent cause.^[1-3] It excludes cases with definite cause such as infections, thoracic trauma, hollow organ perforation, and iatrogenic injuries.^[3] It was first described by Louis Hamman in

1939, hence, it is also called as Hamman's syndrome. It is a rare condition generally affecting young adults.^[1,4] The most common clinical presentation is chest pain, dyspnea, and subcutaneous emphysema.^[1,5] There are only a few published case reports of pneumomediastinum but tracheal tear due to trumpet blowing has not been reported as an etiology to the best of our knowledge and this might be the first case report of pneumomediastinum secondary to tracheal tear in a trumpeter.

CASE REPORT

A 28-year-old reformed smoker, trumpeter by profession presented with complaints of acute onset chest pain and breathlessness of 1-year duration. The chest pain was central

in location with no radiation. He gave a history of worsening of symptoms on blowing trumpet and on exertional activities. His general physical examination was within normal limits and on auscultation there was vesicular breath sounds bilaterally and Hamman's crunch was not heard. His chest radiograph was normal and computed tomography (CT) of chest showed focal irregularity and loss of integrity of the right posterolateral wall of the trachea at DV1 level, at about 6.3 cm proximal to level of carina. There was also subcentimetric air attenuating pockets seen outside the lumen of trachea [Figure 1]. He underwent fiber-optic bronchoscopy which confirmed the lesion [Figure 2]. He was managed conservatively.

DISCUSSION

Spontaneous pneumomediastinum was first described by Louis Hamman in 1939. The incidence of pneumomediastinum has not been clearly established mainly because there are few case series and case reports. The entity is also underestimated especially when there is low index of suspicion as the clinical signs and symptoms are not specific and radiographic signs are not easy to identify.^[1,5-7]

It generally affects young adult males with mean age of 20 years. The cause of pneumomediastinum can be described by these mechanisms: (a) infection of mediastinum with

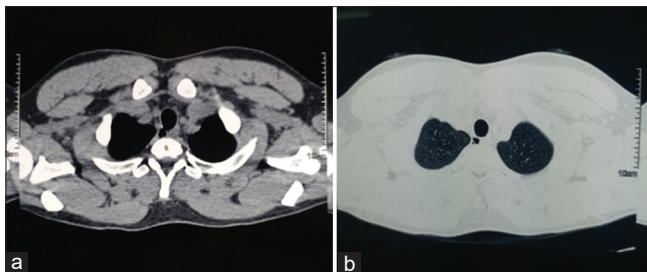


Figure 1: High-resolution computed tomography of chest showing (a) defect in the trachea and (b) air in the mediastinum (pneumomediastinum)

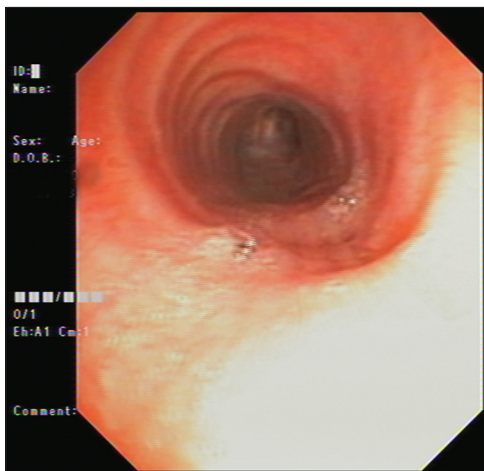


Figure 2: Bronchoscopy picture of the trachea showing defect in the lumen

gas forming organisms, (b) perforation of the esophagus or tracheobronchial tree causing break in cutaneous or mucosal barrier leading to air entry into the mediastinum, and (c) alveolar rupture due to the presence of a decreasing pressure gradient between the alveoli and the lung interstitium.^[1,3,5,7]

The incidence of spontaneous pneumomediastinum in trumpeter has been rarely reported in literatures. One of the studies reported increased maximal respiratory pressure in young people who played wind instruments.^[2,8] These individuals have increased chances of mechanical injury to oropharyngeal tissue due to increased expiratory pressures. In a study by Bouhuys reported that the average expiratory pressure was highest in trumpeter (150 cm H₂O) as compared to people playing flute (50 cm H₂O and Oboe (25 H₂O)).^[9]

The predisposing condition includes bronchial asthma, coughing, sneezing, and corticosteroids.^[1,4,6] The usual presenting symptoms include acute onset, centrally located chest pain radiating to neck and shoulders, dyspnea, odynophagia, and cough. The clinical findings include subcutaneous emphysema and Hamman's sign which is considered pathognomonic of pneumomediastinum is characterized by crackling sound on auscultation which is synchronous with the heartbeat.^[1,4,5,7,8]

The diagnostic test includes chest radiograph and CT of chest. The finding includes: A radiolucent band (hyperlucency) in the retrosternal area (on lateral view), a band of hyperlucency parallel to the left side of the cardiac silhouette with a fine radiopaque line indicating the elevated mediastinal pleura, radiolucent lines in the mediastinum extending toward the neck; and air surrounding mediastinal structures such as the aorta, trachea, esophagus, or thymus gland. The chest CT scan is considered the gold standard of imaging tests, capable of detecting pneumomediastinum even in patients with small amounts of mediastinal air.^[1,2,4,5,10] The defect in the trachea-bronchial tree can be confirmed by bronchoscopy.

The treatment of spontaneous pneumomediastinum is generally conservative. The course of disease is generally self-limiting and there is no significant complications.^[1,4,5,11]

CONCLUSION

We conclude that spontaneous pneumothorax is a rare entity and it presenting secondary to tracheal tear in a trumpeter has not been reported earlier. It can be diagnosed on the basis of clinical and radiological findings. The treatment is mainly conservative.

Declaration of patient consent

The authors certify that they have obtained all appropriate patient consent forms. In the form the patient(s) has/have given his/her/their consent for his/her/their images and other clinical information to be reported in the journal. The patients understand that their names and initials will

not be published and due efforts will be made to conceal their identity, but anonymity cannot be guaranteed.

Financial support and sponsorship

Nil.

Conflicts of interest

There are no conflicts of interest.

**Vikas Marwah¹, C. D. S. Katoch¹, Robin Choudhary¹,
Gaurav Bhati¹**

¹Department of Pulmonary, Critical Care and Sleep Medicine,
AICTS, Pune, Maharashtra, India.
E-mail: robinch19@gmail.com

Submitted: 03-Jan-2020 Accepted: 03-Aug-2020

Published: 30-Oct-2020

REFERENCES

- Macia I, Moya J, Ramos R, Morera R, Escobar I, Saumench J, et al. Spontaneous pneumomediastinum: 41 cases. *Eur J Cardiothorac Surg* 2007;31:1110-4.
- Okoshi K, Minami T, Kikuchi M, Tomizawa Y. Musical instrument-associated health issues and their management. *Tohoku J Exp Med* 2017;243:49-56.
- Cheng C, Varghese T, Park D. Pneumomediastinum and Mediastinitis. In: Broaddus V, editor-in-chief. *Murray & Nadel's Textbook of Respiratory Medicine*, 6th Edition. Canada: Elsevier Publications;2016. p. 1496-503.
- Freixinet J, García F, Rodríguez PM, Santana NB, Quintero CO, Hussein M. Spontaneous pneumomediastinum long-term follow-up. *Respir Med* 2005;99:1160-3.
- Koullias GJ, Korkolis DP, Wang XJ, Hammond GL. Current assessment and management of spontaneous pneumomediastinum: Experience in 24 adult patients. *Eur J Cardiothorac Surg* 2004;25:852-5.
- Vardhan V, Marwah V, Rai SP, Patil AP, Murlidhar R, Pethe M. Spontaneous pneumomediastinum in a case of mixed connective tissue disorder. *Med J Armed Forces India* 2008;64:367-8.
- Newcomb AE, Clarke CP. Spontaneous pneumomediastinum: A benign curiosity or a significant problem? *Chest* 2005;128:3298-302.
- Wilkinson CG, Adams PC. Pneumomediastinum in a trumpeter diagnosed by the presence of Hamman's crunch. *Case Reports* 2012; 2012:1-2.
- Bouhuys A. Physiology and musical instruments. *Nature* 1969;221:1199-204.
- Images in clinical medicine. *N Engl J Med* 2006;354:11.
- Abolnik I, Lossos IS, Breuer R. Spontaneous pneumomediastinum. A report of 25 cases. *Chest* 1991;100:93-5.

This is an open access journal, and articles are distributed under the terms of the Creative Commons Attribution-NonCommercial-ShareAlike 4.0 License, which allows others to remix, tweak, and build upon the work non-commercially, as long as appropriate credit is given and the new creations are licensed under the identical terms.

Access this article online

Quick Response Code:



Website:

www.lungindia.com

DOI:

10.4103/lungindia.lungindia_2_20

How to cite this article: Marwah V, Katoch CD, Choudhary R, Bhati G. An unusual case of spontaneous pneumomediastinum secondary to tracheal tear in a trumpeter. *Lung India* 2020;37:547-9.

© 2020 Indian Chest Society | Published by Wolters Kluwer - Medknow