

| |
|---|
| Access this article online |
| Quick Response Code: |
|  |
| Website: http://www.braincirculation.org |
| DOI: 10.4103/bc.bc_35_20 |

Casper stent in the treatment of pulsatile tinnitus in fibromuscular dysplasia: Therapeutic review and case report

José Ricardo Vanzin, Artur Eduardo Martio, Luciano Bambini Manzato, Daniel Giansante Abud¹

Abstract:

Fibromuscular dysplasia (FMD) is a known cause of pulsatile tinnitus that can, on rare occasion, evolve into an incapacitating condition. It is a noninflammatory and nonatherosclerotic arteriopathy of unknown cause that affects medium-sized vessels, such as the carotid and renal arteries, occurring mainly in women. We describe a 72-year-old woman suffering from pulsatile tinnitus refractory to medical treatment who was successfully treated with Casper stent in the carotid artery. The different treatment strategies published in the literature were reviewed.

Keywords:

Carotid artery angioplasty stenting, Casper stent, dual-layer stent, fibromuscular dysplasia, tinnitus

Introduction

Although tinnitus is a common symptom, with an incidence of 4%–20%, pulsatile tinnitus affects <10% of all tinnitus patients.^[1] Unlike permanent tinnitus, pulsatile tinnitus is mainly related to vascular pathologies, which cause a change in blood volume and pressure or a change in vessel lumen.^[2] The differential diagnosis of pulsatile tinnitus includes dural arteriovenous fistulas, dural sinus stenosis, glomus tumors of the jugular foramen, or atherosclerotic diseases of the carotid artery.^[3] Fibromuscular dysplasia (FMD) is a known cause of pulsatile tinnitus that can, on rare occasions, evolve into an incapacitating condition. FMD generates a turbulent blood flow in the carotid artery, and the swirling effect created can cause tinnitus. It is a noninflammatory, nonatherosclerotic arteriopathy of unknown

cause that affects medium-sized vessels, such as the carotid and renal arteries, occurring mainly in women.^[4] The typical finding in angiography is a multifocal concentric luminal narrowing alternating with areas of mural dilation, which gives the appearance of a string of beads.^[5] FMD can also cause stenosis, aneurysm, dissection, occlusion, and artery tortuosity.^[6] We describe herein the case of a woman with refractory pulsatile tinnitus who was successfully treated with Casper stent placement in the carotid artery.

Case Report

A female in her 70s reported pulsatile tinnitus on the right and left retromastoid region, described “as the sound of her heart beating in her head.” Initially, symptoms appeared with physical activity and at night. Overtime, symptoms started occurring during daily activities and waking the patient during the night. Physical examination showed a bilateral carotid murmur, more intense on the right.

This is an open access journal, and articles are distributed under the terms of the Creative Commons Attribution-NonCommercial-ShareAlike 4.0 License, which allows others to remix, tweak, and build upon the work non-commercially, as long as appropriate credit is given and the new creations are licensed under the identical terms.

For reprints contact: WKHLRPMedknow_reprints@wolterskluwer.com

How to cite this article: Vanzin JR, Martio AE, Manzato LB, Abud DG. Casper stent in the treatment of pulsatile tinnitus in fibromuscular dysplasia: Therapeutic review and case report. *Brain Circ* 2021;7:281-4.

Division of Interventional Neuroradiology, Medical School of Passo Fundo, Federal University of South Frontier, ¹Division of Interventional Neuroradiology, Medical School of Ribeirão Preto, University of São Paulo, Ribeirão Preto, SP, Brazil

Address for correspondence:

Mr. José Ricardo Vanzin, Division of Interventional Neuroradiology, Medical School of Passo Fundo, Federal University of South Frontier, RS, Brazil. E-mail: jrvanzin@gmail.com

Submission: 10-08-2020
Revised: 11-05-2021
Accepted: 11-06-2021
Published: 21-12-2021

Computed tomography (CT) angiography showed signs of FMD in both cervical carotid arteries. Propranolol (40 mg twice a day) partially relieved the symptoms, but they kept worsening and clonazepam (0.25 mg three times a day) and zolpidem (10 mg) were prescribed. The symptoms kept progressing and became unbearable (10 out of 10 intensity on the right side and 1 out of 10 on the left), limiting daily activities and causing insomnia. After 2 years of outpatient follow-up, we discussed endovascular approach with the patient, which was accepted.

Aspirin dose was increased from 100 to 300 mg, and clopidogrel was started 7 days before the procedure. Local anesthesia was used. After a right femoral puncture with a 6F introducer sheath, 7,500 IU of heparin was administered intravenously. A 6F Mach 1 guide catheter was positioned in the right common carotid artery and a 0.014 Whisper guide wire (Abbott Vascular, Abbott Park, IL, USA) was positioned at the petrous carotid artery. A Casper™ 8 mm × 40 mm stent (MicroVention, Inc., Tustin, CA, USA) was placed, covering the entire length of the dysplasia. Balloon angioplasty was not performed, and a cerebral protection system was not used. A three-dimensional angiography was performed before and after the procedure [Figure 1]. The technique and the mechanical behavior of the Casper stent have been described elsewhere.^[7,8] The patient reported immediate symptom relief after stenting and was discharged within 24 h without complications. We prescribed clopidogrel 75 mg daily for 3 months and aspirin 300 mg for 12 months.

After 12-month follow-up, the patient reported that her tinnitus rated 0 out of 10 on the right side and 1 out of 10 on the left side. No carotid murmur could be heard on the treated side. A control CT angiography was performed at 12 months, and showed excellent results [Figure 2].

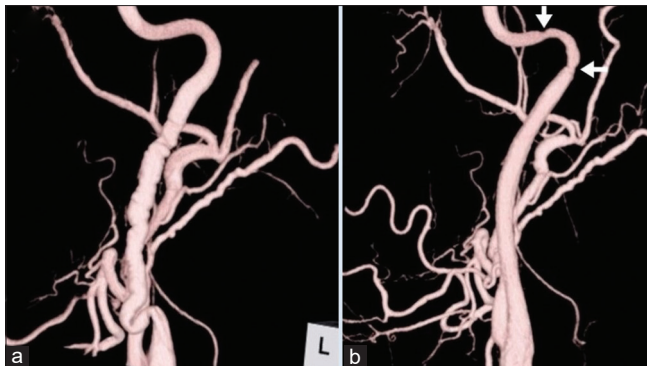


Figure 1: (a) Work incidence of pretreatment three-dimensional angiography showing the characteristic string of bead appearance of fibromuscular dysplasia in the right cervical internal carotid artery. (a) Work incidence of posttreatment three-dimensional angiography showing the right cervical internal carotid artery. The white arrows showing mechanical spasm

Discussion

Pulsatile tinnitus is a common symptom in cerebrovascular FMD, found in up to 33.4% of patients,^[6,9] although it is generally of low intensity. However, a small number of patients have debilitating symptoms that disrupt activities of daily living. In addition to clinical symptoms, FMD may lead to a series of complications, such as transient ischemic attack, stroke, spontaneous dissection, and brain aneurysm.^[10-14] Although the number of patients who experience these complications is significant, most occur before diagnosis. After diagnosis, the number of adverse events is low, suggesting that FMD progresses slowly.^[10] It should be pointed out that although there are some clues about the natural history and prevalence of FMD, they are not fully known.

There is no consensus on the “ideal” treatment for FMD. Oral anticoagulants or antiplatelet agents to prevent thromboembolism have shown considerable benefits; aspirin in doses higher than 81 mg is the recommended treatment.^[15] Beta-blockers and clonazepam have been associated with symptom relief.^[16]

Several surgical techniques have been described, whose morbidity rates range from 2.3% to 50%.^[17-29] Treatment options are varied and include arterial reconstruction, rigid dilation with or without endarterectomy, transluminal dilation through direct balloon, and percutaneous transluminal angioplasty with or without stenting. In general, these procedures prevent symptom recurrence, but no formal recommendations have been made for any one technique over the others.

Table 1 shows the historical evolution of carotid FMD treatment and its modalities, excluding case reports. Although the table shows a wide range of techniques over the years, large series were seen only for the rigid dilation technique.

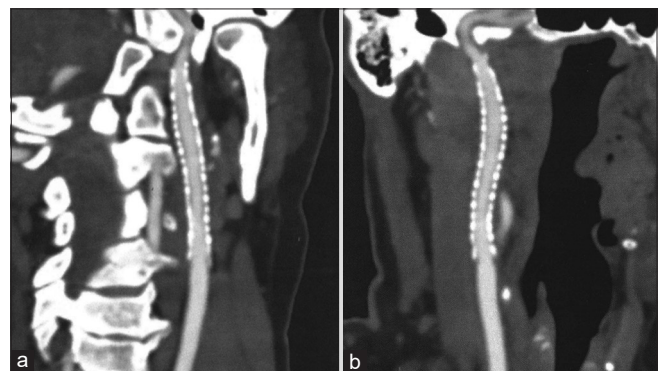


Figure 2: (a) Follow-up computed tomography angiogram, 12 months after stenting. The image showing the right cervical internal carotid artery in the sagittal plane. (b) Follow-up computed tomography angiogram, 12 months after stenting. The image showing the right cervical internal carotid artery in the coronal plane

Table 1: Evolution of surgical and endovascular treatment of carotid fibromuscular dysplasia

| Author, year | Patients/ procedures | Technique | | | | | Embolic protection | Complications, any neurological symptoms/ mortality (%) | References |
|-----------------------------------|-------------------------|-----------------|---------------|--|----------------|-----|------------------------------------|--|------------|
| | | Open balloon | Open stent | Open intraluminal dilation endarterectomy* | Balloon PTA | CAS | | | |
| Morris <i>et al.</i> , 1968 | 12 (8) | No | No | 8 (5*) | No | No | Clamping | 0/0 | [21] |
| Effeney <i>et al.</i> , 1980 | 86 (130) | No | No | 130 (20*) | No | No | Clamping | 3.8/0 | [17] |
| Starr <i>et al.</i> , 1981 | 25 (34) | No | 1 | 31 (3*) | No | No | Clamping and retrograde flusher | 2.7/0 | [22] |
| | | | PTFE | | | | | | |
| Hasso <i>et al.</i> , 1981 | 3 | No | No | No | 3 | No | No | 0/0 | [23] |
| Collins <i>et al.</i> , 1981 | 13 (19) | No | No | 18 (7*) | No | No | Clamping | 5.3/0 | [24] |
| Wesen and Elliott, 1983 | 8 (10) | No | No | 10 | No | No | Clamping | 0/0 | [25] |
| Smith <i>et al.</i> , 1985 | 5 (6) | 6 | No | No | No | No | Retrograde flusher | 0/0 | [26] |
| Smith <i>et al.</i> , 1987 | 7 (8) | 8 | No | No | No | No | Retrograde flusher | 0/0 | [27] |
| Moreau <i>et al.</i> , 1993 | 58 (72) | No | - | 72 (43*) | No | No | Clamping | 2.3/0 | [19] |
| Schneider <i>et al.</i> , 1994 | 115 (168) | No | No | 168 | No | No | Clamping | 2.3/0 | [20] |
| Assadian <i>et al.</i> , 2005 | 6 (9) | No | 9 | No | Yes | No | Retrograde flusher | 11.1/0 | [28] |
| | | | PTFE | | | | | | |
| Tekieli <i>et al.</i> , 2015 | 7 (7) | No | No | No | 3 | 4 | Distal and proximal | 0/0 | [29] |
| Present case | 1 (1) | No | No | No | No | 1 | No | 0/0 | - |

*Patients treated with endarterectomy reconstruction instead of bile duct dilatator. PTA: Percutaneous transluminal angioplasty, CAS: Carotid artery stenting, PTFE: Polytetrafluoroethylene

Stenting has shown good results, rapid symptom relief, and a low complication rate.^[30,27] It is worth noting that atheromatous carotid artery disease may be associated with FMD in older adults with comorbidities, and that endovascular intervention is recommended only for symptomatic cases.^[15]

We decided against balloon angioplasty before or after stent placement due to the absence of associated atheromatous plaque and the risk of artery dissection. A cerebral protection system was not used because the literature reports low embolic risk during carotid FMD treatment,^[27] and because this device itself can cause embolism.^[31] It seems that a cerebral protection system can be dispensed when there is no evidence of associated plaque, as long as the patient receives adequate antiaggregation and anticoagulation.

The double-layer Casper stent has shown excellent results in nonatheromatous diseases of the cervical carotid artery.^[32] In addition to preventing elastic recoil of the artery, it redirects blood flow similar to the intracranial flow diverters used to treat brain aneurysms. This effect occurs because its mesh consists of a free cell area of 0.38 mm² that replaces polytetrafluoroethylene-covered stents, which pose a greater risk of thromboembolic events. Arterial remodeling has also been observed due to the stent's double layer. The amount of metal in contact with the artery causes an inflammatory reaction (intimal hyperplasia), which is beneficial in cervical FMD.^[33] The stent is essential for removing

the swirling effect of carotid blood flow, responsible for tinnitus. To our knowledge, this is the first case of carotid FMD treated with a Casper stent in a patient with disabling tinnitus.

Conclusion

A lack of specific guidelines with high evidence levels hinders management of cervical FMD. Pulsatile tinnitus is a frequent pathology, although in rare cases, it may become disabling. However, a Casper stent resulted in rapid symptom relief, in addition to excellent arterial remodeling at 12 months of follow-up, proving the effectiveness of this method. More research is necessary to determine the best treatment approach for symptomatic FMD patients.

Declaration of patient consent

The authors certify that they have obtained all appropriate patient consent forms. In the form, the legal guardian has given his consent for images and other clinical information to be reported in the journal. The guardian understands that names and initials will not be published and due efforts will be made to conceal identity, but anonymity cannot be guaranteed.

Financial support and sponsorship

Nil.

Conflicts of interest

There are no conflicts of interest.

References

- Sismanis A. Pulsatile tinnitus: Contemporary assessment and management. *Curr Opin Otolaryngol Head Neck Surg* 2011;19:348-57.
- Sanchez TG, Murao M, de Medeiros IR, Kii M, Bento RF, Caldas JG, *et al.* A new therapeutic procedure for treatment of objective venous pulsatile tinnitus. *Int Tinnitus J* 2002;8:54-7.
- Wanke I, Forsting M, Rufenacht DA. Pulsatile tinnitus: radiologic diagnostic and therapeutic options. *Neuroradiologie Scan* 2014;2:149-66.
- Kadian-Dodov D, Goldfinger JZ, Gustavson S, Olin JW. Natural history of cervical artery fibromuscular dysplasia and associated neurovascular events. *Cerebrovasc Dis* 2018;46:33-9.
- Osborn AG, Anderson RE. Angiographic spectrum of cervical and intracranial fibromuscular dysplasia. *Stroke* 1977;8:617-26.
- Kim ES, Olin JW, Froehlich JB, Gu X, Bacharach JM, Gray BH, *et al.* Clinical manifestations of fibromuscular dysplasia vary by patient sex: A report of the United States registry for fibromuscular dysplasia. *J Am Coll Cardiol* 2013;62:2026-8.
- Hopf-Jensen S, Marques L, Preiß M, Müller-Hülsbeck S. Initial clinical experience with the micromesh Roadsaver carotid artery stent for the treatment of patients with symptomatic carotid artery disease. *J Endovasc Ther* 2015;22:220-5.
- Wissgott C, Schmidt W, Brandt C, Behrens P, Andresen R. Preliminary clinical results and mechanical behavior of a new double-layer carotid stent. *J Endovasc Ther* 2015;22:634-9.
- Olin JW, Froehlich J, Gu X, Bacharach JM, Eagle K, Gray BH, *et al.* The United States Registry for Fibromuscular Dysplasia: Results in the first 447 patients. *Circulation* 2012;125:3182-90.
- Shivapour DM, Erwin P, Kim ES. Epidemiology of fibromuscular dysplasia: A review of the literature. *Vasc Med* 2016;21:376-81.
- Harriott AM, Zimmerman E, Singhal AB, Jaff MR, Lindsay ME, Rordorf GA. Cerebrovascular fibromuscular dysplasia: The MGH cohort and literature review. *Neurol Clin Pract* 2017;7:225-36.
- Silhol F, Sarlon-Bartoli G, Daniel L, Bartoli JM, Cohen S, Lepidi H, *et al.* Intranuclear expression of progesterone receptors in smooth muscle cells of renovascular fibromuscular dysplasia: A pilot study. *Ann Vasc Surg* 2015;29:830-5.
- Savard S, Azarine A, Jeunemaitre X, Azizi M, Plouin PF, Steichen O. Association of smoking with phenotype at diagnosis and vascular interventions in patients with renal artery fibromuscular dysplasia. *Hypertension* 2013;61:1227-32.
- Narula N, Kadian-Dodov D, Olin JW. Fibromuscular dysplasia: Contemporary concepts and future directions. *Elsevier* 2018;60:580-5.
- Brott TG, Halperin JL, Abbara S, Bacharach JM, Barr JD, Bush RL, *et al.* 2011 ASA/ACCF/AHA/AANN/AANS/ACR/ASNR/CNS/SAIP/SCAI/SIR/SNIS/SVM/SVS guideline on the management of patients with extracranial carotid and vertebral artery disease: Executive summary. A report of the American College of Cardiology Foundation/American Heart Association Task Force on Practice Guidelines, and the American Stroke Association, American Association of Neuroscience Nurses, American Association of Neurological Surgeons, American College of Radiology, American Society of Neuroradiology, Congress of Neurological Surgeons, Society of Atherosclerosis Imaging and Prevention, Society for Cardiovascular Angiography and Interventions, Society of Interventional Radiology, Society of NeuroInterventional Surgery, Society for Vascular Medicine, and Society for Vascular Surgery. *Circulation* 2011;124:489-532.
- Albertino S, Assunção AR, Souza JA. Pulsatile tinnitus: Treatment with clonazepam and propranolol. *Braz J Otorhinolaryngol* 2005;71:111-3.
- Effeney DJ, Ehrenfeld WK, Stoney RJ, Wylie EJ. Why operate on carotid fibromuscular dysplasia? *Arch Surg* 1980;115:1261-5.
- Finsterer J, Strassegger J, Haymerle A, Hagmüller G. Bilateral stenting of symptomatic and asymptomatic internal carotid artery stenosis due to fibromuscular dysplasia. *J Neurol Neurosurg Psychiatry* 2000;69:683-6.
- Moreau P, Albat B, Thevenet A. Fibromuscular dysplasia of the internal carotid artery: Long-term surgical results. *J Cardiovasc Surg (Torino)* 1993;34:465-72.
- Schneider PA, Cunningham CG, Ehrenfeld WK, Veith FJ, Hobson RW, Williams RA, *et al.* Fibromuscular dysplasia of the carotid artery. *Vascular Surgery: Principles and Practice*. New York, NY: McGraw-Hill; 1994. p. 711-7.
- Morris GC Jr., Lechter A, DeBakey ME. Surgical treatment of fibromuscular disease of the carotid arteries. *Arch Surg* 1968;96:636-43.
- Starr DS, Lawrie GM, Morris GC Jr. Fibromuscular disease of carotid arteries: Long term results of graduated internal dilatation. *Stroke* 1981;12:196-9.
- Hasso AN, Bird CR, Zinke DE, Thompson JR. Fibromuscular dysplasia of the internal carotid artery: Percutaneous transluminal angioplasty. *AJR Am J Roentgenol* 1981;136:955-60.
- Collins GJ Jr., Rich NM, Clagett GP, Spebar MJ, Salander JM. Fibromuscular dysplasia of the internal carotid arteries. Clinical experience and follow-up. *Ann Surg* 1981;194:89-96.
- Wesen CA, Elliott BM. Fibromuscular dysplasia of the carotid arteries. *Am J Surg* 1986;151:448-51.
- Smith DC, Smith LL, Hasso AN. Fibromuscular dysplasia of the internal carotid artery treated by operative transluminal balloon angioplasty. *Radiology* 1985;155:645-8.
- Smith LL, Smith DC, Killeen JD, Hasso AN. Operative balloon angioplasty in the treatment of internal carotid artery fibromuscular dysplasia. *J Vasc Surg* 1987;6:482-7.
- Assadian A, Senekowitsch C, Assadian O, Schuster H, Ptakovsky H, Hagmüller GW. Combined open endovascular stent grafting of internal carotid artery fibromuscular dysplasia: Long term results. *Eur J Vasc Endovasc Surg* 2005;29:345-9.
- Tekieli ŁM, Maciejewski DR, Dzierwa K, Kablak-Ziembicka A, Michalski M, Wójcik-Pędziwiatr M, *et al.* Invasive treatment for carotid fibromuscular dysplasia. *Postepy Kardiol Interwencyjnej* 2015;11:119-25.
- Belán A, Veselá M, Vaněk I, Weiss K, Peregrin JH. Percutaneous transluminal angioplasty of fibromuscular dysplasia of the internal carotid artery. *Cardiovasc Interv Radiol* 2014;5:79-81.
- Almekhlafi MA, Demchuk AM, Mishra S, Bal S, Menon BK, Wiebe S, *et al.* Malignant emboli on transcranial Doppler during carotid stenting predict postprocedure diffusion-weighted imaging lesions. *Stroke* 2013;44:1317-22.
- Kabbasch C, Bangard C, Liebig T, Majd P, Mpotsaris A, Faymonville A. The dual layer Casper micromesh stent: Taking advantage of flow-diverting capabilities for the treatment of extracranial aneurysms and pseudoaneurysms. *Cardiovasc Intervent Radiol* 2016;39:472-6.
- Ierardi AM, Angileri SA, Brambillasca PM, Jannone ML, Biondetti P, Petrillo M, *et al.* In-stent restenosis associated with dual-layer Roadsaver carotid artery stent: A retrospective single-center study. *Radiol Med* 2019;124:704-9.