

ORIGINAL RESEARCH

Escalation of Antithrombotic Therapy Should Be Considered in the Presence of Intraluminal Prosthetic Graft Thrombus Following Endovascular Aneurysm Repair

Terri-Ann Russell ^{a,*}, Sivaram Premnath ^a, Meera Mogan ^a, Grace Langford ^a, Bronte Paice ^a, James Kirk ^b, Timothy Rowlands ^a, Ganesh Kuhan ^a

^a Department of Vascular Surgery, University Hospitals of Derby and Burton NHS Foundation Trust, Uttoxeter Road, Derby, DE22 3NE, UK

^b Department of Radiology, University Hospitals of Derby and Burton NHS Foundation Trust, Uttoxeter Road, Derby, DE22 3NE, UK

WHAT THIS PAPER ADDS

For the first time in the published literature, a pre-operative diagnosis of peripheral arterial disease was found to be associated with the development of Intraluminal prosthetic graft thrombus (IPT) following endovascular abdominal aortic aneurysm repair (EVAR). The escalation of antithrombotic therapy in patients with IPT seemed to correlate with partial or complete thrombus resolution. Therefore, adding a further antiplatelet or anticoagulant in the presence of IPT is recommend for consideration.

Objectives: Intraluminal prosthetic graft thrombus (IPT) following Endovascular Aneurysm Repair (EVAR) can have serious consequences. The aim of this study was to assess the prevalence of IPT and to identify the risk factors for its formation and progression.

Methods: This was a retrospective study of 258 patients who had EVAR between 2015 and 2018. Demographic data, comorbidities, operative data, antithrombotic therapy, CT anatomical data, IPT characteristics (site, regression, and progression), and re-interventions were collected. Univariable analysis followed by multivariable logistic regression and Cox regression were used for data analysis.

Results: The mean age of patients was 76 years (range 55–95) and 27 (10.5 %) were females. IPT was present in 26 patients (10.1%) with a median time to occurrence of six (range 1–24) months. Of the group that developed IPT, six (23.1 %) developed symptoms and two (7.7%) had re-interventions. Multivariable logistic regression analysis revealed peripheral arterial disease to be associated with the formation of IPT (OR 7.4, 95% CI 1.6–35.3, $p = 0.02$) and escalation of antithrombotic therapy was associated with regression or prevention of progression of IPT (OR 0.1, 95% CI 0.0–0.6, $p = 0.01$).

Conclusion: PAD is associated with the formation of IPT after EVAR and warrants consideration of escalation of antithrombotic therapy to prevent further progression and complications.

© 2022 The Author(s). Published by Elsevier Ltd on behalf of European Society for Vascular Surgery. This is an open access article under the CC BY-NC-ND license (<http://creativecommons.org/licenses/by-nc-nd/4.0/>).

Article history: Received 23 July 2021, Revised 19 February 2022, Accepted 9 March 2022,

Keywords: Abdominal aortic aneurysm, Endovascular techniques, Thrombus, Peripheral arterial diseases, Anticoagulant, Antiplatelet agents

INTRODUCTION

Endovascular aneurysm repair (EVAR) is an established treatment option for patients with abdominal aortic aneurysm (AAA). Four randomised controlled trials have shown

early mortality benefit for EVAR.^{1–4} The development of thrombus within the stent graft (Intraprosthetic thrombus [IPT]) has been reported in 10.7¹³ to 33% of patients following EVAR.⁵ The presentation of IPT varies from just an incidental finding on surveillance scan, to more severe symptoms including new onset claudication or thromboembolic events.^{6–8}

Despite the common occurrence, the management of IPT is variable and depends predominantly on surgeon preference.⁵ Management strategies broadly include close surveillance, anticoagulation or addition of antiplatelet agents and surgery.⁹ Surgical options include relining the stent

* Corresponding author. Department of Vascular Surgery, University Hospitals of Derby and Burton NHS Foundation Trust, Uttoxeter Road, Derby, DE22 3NE, UK.

E-mail address: russellterriann@yahoo.com (Terri-Ann Russell).

2666-688X/© 2022 The Author(s). Published by Elsevier Ltd on behalf of European Society for Vascular Surgery. This is an open access article under the CC BY-NC-ND license (<http://creativecommons.org/licenses/by-nc-nd/4.0/>).

<https://doi.org/10.1016/j.ejvsf.2022.03.003>

graft, thrombolysis, or extra-anatomic bypass. European society for vascular surgery guidelines recommends EVAR patients to be on a single antiplatelet agent.¹⁰ Despite single antiplatelet agent therapy, IPT seems to occur frequently after EVAR. The vascular community is currently rethinking its policy of antithrombotic therapy to a dual pathway approach for patients who have had interventions for peripheral arterial disease (PAD).¹¹ The aim of this study was to identify potential risk factors for the formation and progression of IPT and to evaluate which strategy is more appropriate once IPT is identified.

MATERIALS & METHODS

This was a retrospective study of all patients who had EVAR between December 2015 and December 2018 at a tertiary vascular unit. Data were collected from the national vascular registry (NVR) database. Demographic data, comorbidities, operative data, antithrombotic therapy, and computed tomography anatomical data were collected. Follow up data on the morphology of IPT (site, regression, and progression) and re-interventions were obtained from the hospital's radiology database. Data on the use of antiplatelets and anticoagulants were collected from the patient electronic health record and primary care health records. Morbidity and mortality data were also obtained from the NVR and patient electronic health records respectively. Patients who were not enrolled in CT surveillance were excluded from the study as well as patients who missed follow up scans or had an incomplete dataset.

The indication for EVAR was as per the European Society for Vascular Surgery guidelines.¹⁰ EVARs performed outside the Instructions for Use (IFU) of the stent graft system were excluded from the study. The institutional surveillance protocol after EVAR was that of aortic CT angiogram at one, six and 12 months and annually thereafter. All the surveillance CTs were reported by vascular radiologists. CT images of all cases with IPT were re-reviewed by a single senior vascular radiologist, J.K., who was blinded to the use of anticoagulation drug use, to increase the validity of the study. The site, size, density, grade of stenosis, time to occurrence and progression or regression of IPT were evaluated. Also, as an institutional protocol, new thrombus on CT was a trigger for multidisciplinary team discussion, review of antithrombotic medication, assessment for risk of bleeding and escalation of antithrombotic medication.

All the pre-operative and operative variables were defined as per the UK National Vascular Registry Data Dictionary.¹² Intraluminal prosthetic graft thrombus (IPT) was defined as endograft thrombus with a minimum thickness of 2 mm and extending longitudinally for a minimum of 4 mm on post-operative CTA.¹³ Progression or regression of IPT was based on the degree of stenosis which was measured at the point of maximum amount of thrombus. Peripheral arterial disease was defined as symptoms of intermittent claudication, chronic limb threatening ischaemia or previous lower limb arterial interventions for chronic limb ischaemia. Chronic limb threatening ischaemia was defined as objectively

Table 1. Patient characteristics and univariable analysis for intraluminal prosthetic graft thrombus formation.

Variable	No Thrombus (n = 232)	Thrombus (n = 26)	p value
Age < 70	39 (16.8%)	9 (34.6%)	0.03
Male gender	206 (88.8%)	25 (96.2%)	0.49
BMI ≥ 30	71 (33.8%)	11 (47.8%)	0.18
Diabetes mellitus	47 (20.3%)	3 (11.5%)	0.29
Hypertension	150 (64.7%)	16 (61.5%)	0.75
COPD	74 (31.9%)	4 (15.4%)	0.08
Ischaemic heart disease	82 (35.3%)	10 (38.5%)	0.75
Congestive heart failure	11 (4.7%)	0 (0%)	0.61
Chronic Kidney Disease	55 (23.7%)	3 (11.5%)	0.16
Stroke	27 (11.6%)	4 (15.4%)	0.53
Malignancy	7 (3.0%)	1 (3.8%)	0.58
Peripheral Arterial Disease	4 (1.7%)	3 (11.5%)	0.02
<i>ASA Score</i>			
2	61 (26.3%)	12 (46.2%)	0.17
3	127 (54.7%)	11 (42.3%)	
4	36 (15.5%)	3 (11.5%)	
5	8 (3.4%)	0 (0%)	
<i>Smoking</i>			
Current	47 (20.3%)	6 (23.1%)	0.92
Ex-smoker	169 (72.8%)	18 (69.2%)	
Non-smoker	16 (6.9%)	2 (7.7%)	
<i>Pre-operative Medications</i>			
Statins	160 (69.0%)	18 (69.2%)	0.98
Anticoagulants	4 (1.7%)	1 (3.8%)	0.41
Single Antiplatelet	123 (53.0%)	14 (53.8%)	0.93
Dual Antiplatelets	2 (0.9%)	0 (0%)	1.00
Mean Haemoglobin (g/dL)	14.0 ± 3.0	14.9 ± 1.6	0.19
Mean Serum Creatinine (µmol/L)	96.7 ± 31.7	107.3 ± 88.8	0.03

documented atherosclerotic arterial disease in association with ischaemic rest pain or tissue loss (ulceration or gangrene).¹⁴ Lower limb arterial interventions included both endovascular and open lower limb peripheral arterial interventions. Acute AAA symptoms referred to the presentation with symptoms such as abdominal pain and limb ischaemia which were attributable to the aneurysm.

All statistical analysis was done using SPSS for Windows, Version 16.0. Chicago, SPSS Inc. The student's t test was used for continuous variables. For analysis, all patients who had IPT were compared with the patients who did not have IPT (control group). Univariable analysis was performed by Chi squared or Fisher's exact tests for tables where all or some cells had counts of more or less than five respectively. Multivariable logistic regression was performed to identify significant risk factors for the development of IPT. Kaplan-Meier survival analysis was performed for thrombus free survival. Log rank test followed by Cox regression analysis was performed to identify significant factors associated with thrombus free survival. Further subgroup analysis was performed in patients who had IPT to identify the factors associated with progression of IPT. T test was performed to compare means between variables. A p value of < .05 was considered statistically significant.

RESULTS

A total of 308 patients had EVAR during this period. Of the 308 patients only 258 fitted the inclusion criteria for the study. The median follow up of the study population was 48 months (range 30–66). The mean age of patients was 76 years (range 55–95) and 89.5% (231/258) were male. The incidence of IPT was 10.1% (26/258) with a median time to occurrence of six months (range 1–24) from stent graft implantation.

Majority of the procedures were performed electively (84.5%, 218/258). Most of the procedures were performed for asymptomatic aneurysms (83.3%, 215/258) while 23 (8.9%) were done for rupture and 20 (7.8%) for acute symptoms, respectively. Standard EVAR was performed for 205 patients (79.5 %), fenestrated EVAR (FEVAR) for 39 patients (15.1%), and 14 (5.4%) patients had revision EVAR.

Age less than 70 years was found to be significantly associated with the development of IPT (OR = 0.4, 95% CI 0.2–0.9, $p = .03$) (Table 1). Analysis of comorbidities identified peripheral arterial disease to be associated with the formation of IPT (OR = 7.4, 95% CI 1.6–35.3, $p = .02$). The mean serum creatinine was also significantly elevated in patients who had IPT (OR = 0.4, 95% CI 0.2–0.9, $p = .03$) (Table 1). None of the other patient characteristic variables was significant

Table 1 describes the univariable analysis of patient characteristics that are associated with the development of IPT. Univariable analysis of factors related to intervention and CT morphology characteristics did not reveal any significant association with the formation of IPT.

Most of the patients (96.2%, 25/26) with IPT had either unilateral or bilateral EVAR limb thrombus and half of the patients had thrombus in the main body (50.0%, 13/26). Only 23.1% (6/26) of the patients with IPT presented with symptoms of whom four patients presented with lower limb claudication, one with rest pain and one patient developed acute limb ischaemia secondary to an occluded iliac limb. The patient with acute limb ischaemia had a femorofemoral crossover graft while the patient with claudication had relining of the occluded limb of the EVAR stent graft with another EVAR limb. The patient with rest pain suffered a myocardial infarction and subsequently had no intervention. A review of surveillance CT images of the 26 patients who had IPT, and serial comparison of the site of the maximum body and limb thrombus related stenosis revealed a progression of thrombus in 12 cases (46.1%, 12/26). The median follow up of patients with IPT was 11 months (range 4–26 months). No patient characteristic was found to be a risk factor for thrombus progression (Table 2).

Following the initial detection of IPT, antithrombotic therapy was escalated by the addition of an antiplatelet (APT), novel anticoagulant (NOAC) or warfarin in 61.5% (16/26) of patients. The different escalation regimens were as follows; eight (50%) patients were escalated from single to dual antiplatelet (DAPT), three (19%) from warfarin to

Table 2. Patient characteristics and univariable analysis for intraluminal prosthetic graft thrombus progression.

Variable	No Progression (n = 14)	Progression (n = 12)	p value
Age < 70	4 (28.6%)	5 (41.7%)	0.48
Male gender	14 (100.0%)	11 (91.7%)	0.46
Diabetes mellitus	2 (14.3%)	1 (8.3 %)	1.00
Hypertension	9 (64.3%)	7 (58.3%)	1.00
COPD	1 (7.1 %)	3 (25.0%)	0.30
Ischaemic heart disease	3 (21.4%)	7 (58.3%)	0.10
Chronic Kidney Disease	1 (7.1%)	2 (16.7%)	0.58
Stroke	1 (7.1%)	3 (25.0%)	0.31
Malignancy	0 (0%)	1 (8.3%)	0.46
Peripheral Arterial Disease	0 (0 %)	3 (25.0%)	0.08
ASA Score			
2	9 (64.3%)	3 (25.0%)	0.13
3	4 (28.6%)	7 (58.3%)	
4	1 (7.1%)	2 (16.7%)	
Smoking			
Current	2 (14.3%)	4 (33.3%)	0.25
Ex-smoker	10 (71.4%)	8 (66.7%)	
Non-smoker	2 (14.3 %)	0 (0%)	
Pre-operative Medications			
Statins	10 (71.4%)	8 (66.7%)	1.00
Anticoagulants	1 (7.1%)	0 (0%)	1.00
Single Antiplatelet	7 (50.0%)	7 (58.3%)	0.71
Escalation of Anti-thrombotics	12 (85.7 %)	4 (33.3 %)	0.01
Mean Haemoglobin (g/dL)	15.2	14.4	0.32
Mean Serum Creatinine (µmol/L)	97.4	118.8	0.07

warfarin and an antiplatelet medication, two (13%) from single antiplatelet to warfarin, one (6%) from DAPT to warfarin, one (6%) NOAC to NOAC and APT and one (6%) patient from single antiplatelet therapy to a NOAC and an antiplatelet medication. Of the group that had escalation of their anti-thrombotic therapy four had thrombus progression. Of this group, two were escalated from single antiplatelet therapy to warfarin, one from DAPT to warfarin and one from single to dual antiplatelet medication.

All 12 patients who had thrombus progression were on an antiplatelet medication prior to discharge. Five patients were on dual antiplatelet and 7 on single antiplatelet. Multivariable logistic regression analysis revealed peripheral arterial disease to be associated with the formation of IPT (OR 7.4, 95% CI 1.6–35.3, $p = .01$) and escalation of antithrombotic therapy appeared to be a protective factor for the prevention of progression of IPT (OR 0.1, 95% CI 0.0–0.6, $p = .01$) (Table 2).

On Kaplan–Meier analysis, mean intraluminal thrombus free survival was estimated to be 50.0 months (95% CI 48.1–51.8). Peripheral arterial disease was found to be associated with reduced thrombus free survival in log rank test ($p = .002$) and cox regression analysis (HR 6.43, 95% CI 1.88–22.06, $p = .003$) (Fig. 1).

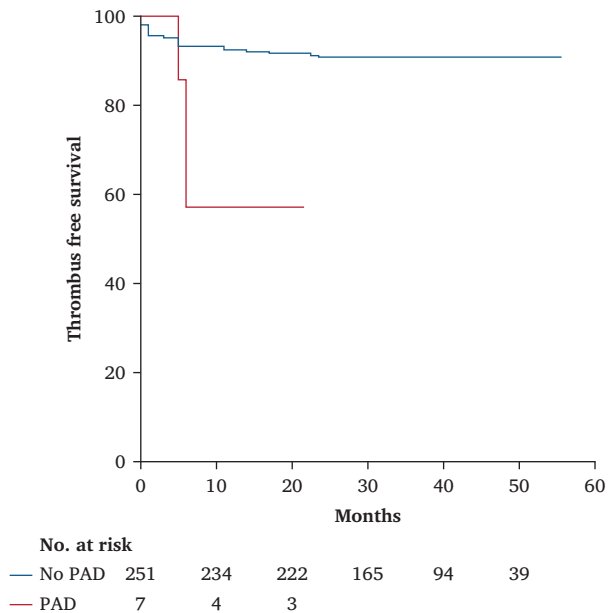


Figure 1. Kaplan—Meier survival estimates.

DISCUSSION

The current study has shown that peripheral arterial disease (PAD) was associated with the risk of development of IPT following EVAR. Previous studies have shown that factors affecting haemodynamic changes within the endograft contribute to IPT formation. These factors included aorto-uni-iliac stent graft configuration, larger neck diameter and higher ratio between cross sectional areas of the main body and limbs.^{5,15–20} Polyester graft fabric, neck thrombus, aneurysmal sac thrombus and age less than 70 years have also been shown to be significant risk factors in previous studies.¹⁷ In the current study PAD was the only risk factor, identified on multivariable analysis, to be associated with the formation of IPT. The exact mechanism for this is unknown, however it is proposed that the presence of PAD might induce haemodynamic changes proximal to the level of arterial obstruction or stenoses resulting in the formation of IPT. Previous studies have also shown that patients with PAD are at a higher risk of thrombus formation compared with patients who do not have PAD.^{21,22} Patients with PAD are also likely to be smokers which is a known risk factor for enhanced procoagulant state.²³

Progression or resolution of IPT is poorly studied in the literature. A recent study by Massoni et al. identified 80 patients with IPT of whom 14 had complete resolution.²⁰ In the present study, 26 patients had IPT, and thrombus progression was seen in 46.1% (12/26). In the group with thrombus progression four patients had claudication, one rest pain, and one had acute limb ischaemia. Of this group only two patients had an intervention for symptomatic relief.

This is the first study to suggest that escalation of anti-thrombotic therapy is associated with lack of IPT progression. Of the 16 patients who had escalation of anti-

thrombotic medication, 75.0% (12/16) did not have IPT progression. Anti-thrombotic combinations varied from the escalation of single antiplatelet to dual antiplatelet therapy or the addition of an antiplatelet to warfarin or novel oral anticoagulant. Due to the different variations and small number of patients with IPT it was not possible to carry out detailed analysis of the different treatment strategies. However, despite the small number of patients in this study, none of the patients who had dual pathway anti-thrombotic medication had progression of their thrombus.

The vascular community is currently rethinking anti-thrombotic therapy for PAD. Recent trials show low dose Rivaroxaban and Aspirin (dual pathway) to be superior to Aspirin alone for patients with PAD and patients who undergo PAD intervention.^{11,24} Considering the evidence from the recent trials, dual pathway might be beneficial in patients with PAD or those at high risk of developing IPT undergoing EVAR. However, larger scale studies are needed to evaluate the effect of dual pathway or dual antiplatelet prophylaxis and treatment in this group of patients prior to concluding. There is an increased risk of an endoleaks in patients on anticoagulants who had EVAR, hence close surveillance is recommended.²⁵ The 2019 ESVS guideline recommends antiplatelet therapy in all patients post aortic aneurysm repair for risk factor management but has not addressed the management of IPT if found on surveillance scans.¹⁰

The current study has multiple limitations. These include the fact that the intra-prosthetic thrombus was measured in two dimensions only. Thrombus volume measurement would have provided a more accurate assessment of thrombus progression or regression. Non-availability of imaging software for volume measurement of the thrombus is one of the limitations of this study. The presence of IPT in follow up images was selected based on the report by Vascular Radiologists. It is possible that IPT which was not significant might not have been reported and hence the lower prevalence of IPT compared with other studies. The current study used the National Vascular Registry (NVR) dataset for AAA. The dataset does not include extent, severity, and anatomy of PAD for AAA patients. The number of cases with PAD in this study was very small 2.7% (7/258). The small prevalence of PAD could result in the significant findings between PAD and IPT being due to chance variation. The uncontrolled nature of the study could also introduce bias. The study included a heterogeneous group of patients. Standard and complex EVAR, and asymptomatic and symptomatic cases were grouped and analysed together. Despite the limitations the study addresses an important complication after EVAR and has highlighted the need for further studies and evidence to support the management of these patients.

In conclusion, this study has demonstrated that IPT is a common finding after EVAR, and PAD appears to be associated with its formation. Escalation of anti-thrombotic therapy on initial identification may offer protection from further IPT progression. Based on the findings in this study, escalation of antithrombotic therapy and strict surveillance

after EVAR in patients with IPT is recommended. Further controlled research to explore the role of anticoagulation in the prevention and treatment of IPT particularly in patients with high thrombotic risk after EVAR is recommended.

ACKNOWLEDGEMENTS

We thank Mr David Pintar for the data collection and entry into the National Vascular Registry.

CONFLICT OF INTEREST

Nil

FUNDING

This research did not receive any specific grant from funding agencies in the public, commercial, or not-for-profit sectors.

REFERENCES

- Lederle FA, Freischlag JA, Kyriakides TC, Matsumura JS, Padberg Jr FT, Kohler TR, et al, OVER Veterans Affairs Cooperative Study Group. Long-term comparison of endovascular and open repair of abdominal aortic aneurysm. *N Engl J Med* 2012;**367**:1988–97.
- Greenhalgh RM, Brown LC, Kwong GP, Powell JT, Thompson SG, EVAR Trial Participants. Comparison of endovascular aneurysm repair with open repair in patients with abdominal aortic aneurysm (EVAR trial 1), 30-day operative mortality results: randomised controlled trial. *Lancet* 2004;**364**:843–8.
- Blankensteijn JD, de Jong SE, Prinssen M, van der Ham AC, Buth J, van Sterkenburg SM, et al, Dutch Randomized Endovascular Aneurysm Management (DREAM) Trial Group. Two-year outcomes after conventional or endovascular repair of abdominal aortic aneurysms. *N Engl J Med* 2005;**352**:2398–405.
- Becquemin JP, Pillet JC, Lescalie F, Sapoval M, Goueffic Y, Lermusiaux P, et al, ACE trialists. A randomized controlled trial of endovascular aneurysm repair versus open surgery for abdominal aortic aneurysms in low-to-moderate-risk patients. *J Vasc Surg* 2011;**53**:1167–73.
- Maleux G, Koolen M, Heye S, Heremans B, Nevelsteen A. Mural thrombotic deposits in abdominal aortic endografts are common and do not require additional treatment at short-term and midterm follow-up. *J Vasc Interv Radiol* 2008;**19**(11):1558–62.
- Carpenter JP, Neschis DG, Fairman RM, Barker CF, Golden MA, Velazquez OC, et al. Failure of endovascular abdominal aortic aneurysm graft limbs. *J Vasc Surg* 2001;**33**(2):296–303.
- Dorffner R, Thurnher S, Youssefzadeh S, Winkelbauer F, Hölzenbein T, Polterauer P, et al. Spiral CT angiography in the assessment of abdominal aortic aneurysms after stent grafting: value of maximum intensity projections. *J Comput Assist Tomogr* 1997;**21**(3):472–7.
- Schunn CD, Krauss M, Heilberger P, Ritter W, Raithel D. Aortic aneurysm size and graft behavior after endovascular stent-grafting: clinical experiences and observations over 3 years. *J Endovasc Ther* 2000;**7**(3):167–76.
- Polat A, Mert B, Gumus F, Farsak B, Erentug V. Rare complication of EVAR: thrombus in endograft. *Eur J Vasc Endovasc Surg* 2011;**42**(3):408.
- Wanhainen A, Verzini F, van Herzele I, Allaire E, Bown M, Cohnert T, et al. Editor's Choice — European Society for Vascular Surgery (ESVS) 2019 clinical practice guidelines on the management of abdominal aorto-iliac artery aneurysms. *Eur J Vasc Endovasc Surg* 2019;**57**(1):8–93.
- Bonaca MP, Bauersachs RM, Anand SS, Debus ES, Nehler MR, Patel MR, et al. Rivaroxaban in peripheral artery disease after revascularization. *N Engl J Med* 2020;**382**(21):1994–2004.
- NVR data dictionary | VSQIP. <https://www.vsqip.org.uk/resources/guides/nvr-data-dictionary/>. 12/02/2020.
- Bianchini Massoni C, Ucci A, Perini P, Azzarone M, Mariani E, Bramucci A, et al. Prevalence, risk factors and clinical impact of intraprosthetic thrombus deposits after EVAR. *J Cardiovasc Surg (Torino)* 2020 Dec;**61**(6):729–37.
- Conte MS, Bradbury AW, Kolh P, White JV, Dick F, Fitridge R, et al. Global vascular guidelines on the management of chronic limb-threatening ischemia. *Eur J Vasc Endovasc Surg* 2019;**58**(1):S1–109.e33.
- Wegener M, Görich J, Krämer S, Fleiter T, Tomczak R, Scharrer-Pamler R, et al. Thrombus formation in aortic endografts. *J Endovasc Ther* 2001;**8**(4):372–9.
- Oliveira NFG, Bastos Gonçalves FM, Hoeks SE, ten Raa S, Ultee KHJ, Rouwet E, et al. Clinical outcome and morphologic determinants of mural thrombus in abdominal aortic endografts. *J Vasc Surg* 2015;**61**:1391–8.
- Perini P, Bianchini Massoni C, Azzarone M, Ucci A, Rossi G, Gallitto E, et al. Significance and risk factors for intraprosthetic mural thrombus in abdominal aortic endografts: a systematic review and meta-analysis. *Ann Vasc Surg* 2018:234–42.
- Mestres G, Maeso J, Fernandez V, Allegue N, Constenla I, Matas M. Incidence and evolution of mural thrombus in abdominal aortic endografts. *Ann Vasc Surg* 2009;**23**(5):627–33.
- Wu IH, Liang PC, Huang SC, Chi NS, Lin FY, Wang SS. The significance of endograft geometry on the incidence of intraprosthetic thrombus deposits after abdominal endovascular grafting. *Eur J Vasc Endovasc Surg* 2009;**38**(6):741–7.
- Bianchini Massoni C, Ucci A, Perini P, Azzarone M, Mariani E, Bramucci A, et al. Prevalence, risk factors and clinical impact of intraprosthetic thrombus deposits after EVAR. *J Cardiovasc Surg (Torino)* 2020;**61**:729–37.
- Cortellaro M, Cofrancesco E, Boschetti C, Mussoni L, Donati MB, Catalano M, et al. Association of increased fibrin turnover and defective fibrinolytic capacity with leg atherosclerosis. *Thromb Haemost* 1994;**72**(2):292–6.
- Kleinegris M-CF, Konings J, Daemen JW, Henskens Y, de Laat B, Spronk HMH, et al. Increased clot formation in the absence of increased thrombin generation in patients with peripheral arterial disease: a case–control study. *Front Cardiovasc Med* 2017;**4**:23.
- Barua RS, Sy F, Srikanth S, Huang G, Javed U, Buhari C, et al. Effects of cigarette smoke exposure on clot dynamics and fibrin structure: an ex vivo investigation. *Arteriosclerosis, Thromb Vasc Biol* 2010;**30**(1):75–9.
- Eikelboom JW, Connolly SJ, Bosch J, Dagenais GR, Hart RG, Shestakovska O, et al. Rivaroxaban with or without aspirin in stable cardiovascular disease. *N Engl J Med* 2017;**377**(14):1319–30.
- Lazarides MK, Georgiadis GS, Charalampidis DG, Antoniou GA, Georgakarakos EI, Trellopoulos G. Impact of long-term warfarin treatment on EVAR durability: a meta-analysis. *J Endovasc Ther* 2014;**21**(1):148–53.