

Single Case

Acoustic Wave Therapy for the Treatment of Extensive Scar Fields: A Case Report

C. Bettina Rümmelein Ikonija Koceva

Rümmelein AG – House of Skin and Laser Medicine, Zürich, Switzerland

Keywords

Scalding trauma · Hypertrophic scars · Itching · Acoustic wave therapy

Abstract

We report a severe scalding case with an affected skin area of 30–40% of the body surface. The patient suffered from severe itching and pain in the hypertrophic scar parts even 1.5 years after the accident. Treatment with acoustic wave therapy almost daily during the first treatment cycle was able to significantly reduce the discomfort. On representation after 1 year, the skin condition showed significant improvement. The second treatment cycle brought further improvement. At the last check-up 2 years later, the patient was free of complaints.

© 2022 The Author(s).

Published by S. Karger AG, Basel

Introduction

A 63-year-old woman from Bahrain presented to us in June 2013. She suffered a serious accident in January 2012 due to scalding with hot water. Due to the severity of the burns, which were not only large-scale but also deep, the patient was in an intensive care unit for 2 months in a medically induced coma. In addition, an MRSA infection occurred during this time. After an initial improvement, the patient was transferred to a special clinic in Great Britain, where further surgical procedures were carried out. Relatively large areas had to be covered with mesh graft transplants. Since September 2012, she had been feeling better, but her general condition was still limited due to chronic pain with high-dose, partly sedating pain medication and restricted movement due to scar-related contractures.

Correspondence to:

C. Bettina Rümmelein, b.ruemmelein@dr-ruemmelein.ch

Case Presentation

When she presented to us in 2013, the patient showed a limited general condition and a reduced ability to move. A cardinal symptom of the patient was severe itching in the scalded body parts, which sometimes increased the pain. Therefore, medication with analgesics (pregabalin), antihistamines (cetirizine), and antidepressants (zopiclon) was still administered. The burn sites covered 40–50% of the body's surface area, which was predominantly on the right, and were irregular, partly severely reddened, and significantly hardened. Strand formation and contractures were observed over the joints, resulting in restricted movement (shown in Fig. 1), especially in the shoulder, knee, elbow, and hip area. The patient was not able to walk or stand upright properly.

The patient was found to have large hypertrophic scarring fields on the entire body, which were caused by second- and third-degree burns. Parts of the necrotized skin were covered with well-healed mesh grafts.

A number of options are available for the treatment of hypertrophic scars (HTSs) and keloids, such as intralesional injections with triamcinolone 10 mg/40 mg, surgical procedures, or ablative and non-ablative laser treatments [1]. The choice of the optimal treatment depends on the shape, acuteness, and extent of the spread of the scars. Since the patient did not want painful treatment, we decided to use acoustic wave treatment (AWT), which is a rarely considered method for scar treatment.

During a 17-day stay in Zurich (June 10, 2013 to June 27, 2013), the patient was treated 14 times with AWT with the Cellactor SC1 (Storz Medical). Due to the astonishing subjective and objective improvement of the findings, she returned to Zurich the following year and received eight more rounds of treatment with the AWT over a period of 13 days (August 13, 2014 to August 26, 2014) (shown in Fig. 2).

The treatment was initially performed with the V-Actor (3,000 pulses per area of approx. two palms at 8.0 Hz). The same area was then treated with the C-Actor at 0.45 mJ/mm², 1,000

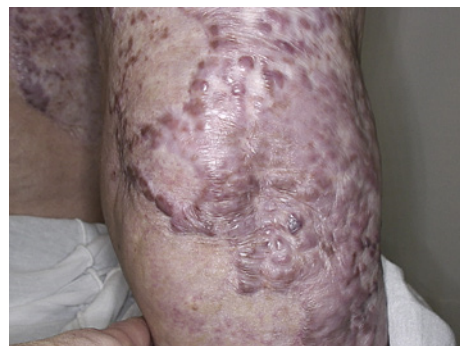

Fig. 1. Elbow right before treatment on June 10, 2013.

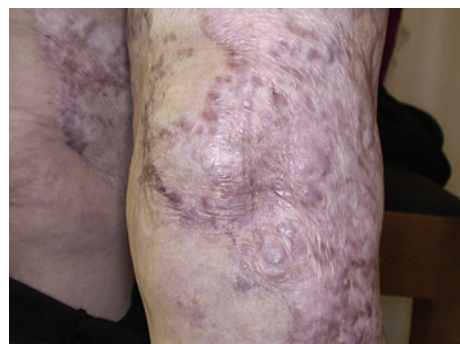

Fig. 2. Elbow right on representation on August 13, 2014.

pulses, 2.0 Hz. Despite the patient's high level of pain, the treatment was tolerated without any problems.

On the one hand, the patient should be able to feel the treatment well, but on the other hand, it should not be perceived as painful. Only low energies can be used over bony structures as well as over the entire chest, which is why the energy with the C-Actor was reduced there to 0.33 mJ/mm². Six defined areas were treated: shoulder, flank, hip, elbow, upper arm with elbow and knee, each on the right side. The total treatment time was approximately 2 h and was completed by applying a moisture lotion without specific ingredients.

Discussion

HTSs are one of the most common complications of burns. They result from excessive scarring during prolonged abnormal wound healing and are characterized by hyalinized collagen bundles.

The formation of HTS is a dynamic and complex process that involves interactions between several factors such as inflammatory cells, cytokines, growth factors, and chemokines. Important factors in patients with severe burns are chronic or prolonged inflammation and infection due to the severity of the injury. A HTS is characterized by hypervascularisation and an increased number of fibroblasts with excessive collagen production [2].

HTSs occur in up to 91% of burns, depending on the depth of the wound. While superficial abrasions, cuts, or cracks usually heal without scars, scars occur when the deep dermis is injured. The pathophysiology of HTS formation includes a hyperactive phase of proliferation in wound healing. A large number of cells (macrophages, fibroblasts, keratinocytes), cytokines, and growth factors participate in this process [3].

The shock waves of the AWT loosen the hardened fibre bundles by means of mechanical energy and lead to physical as well as biological effects. Various biological effects on different cell and tissue types have been demonstrated. In addition to stimulation of microcirculation with angiogenesis and a lymphatic drainage effect, stimulation of growth factors and stem cells has been demonstrated, such as endothelial nitric oxide synthase (eNOS), vascular endothelial growth factors (VEGF), and proliferating cell nuclear antigen (PCNA). These lead to improved blood supply and tendon regeneration [4]. The cells dynamically adapt to the force by modifying their behaviour and reshaping their microenvironment. The release of growth factors after mechanical stimulation can be considered to be the first step in the regeneration of new supportive connective tissue [5]. Since the treatment is not reserved exclusively for qualified physicians, it can be delegated to trained medical staff.

Two handpieces were used. The V-actor directs pneumatically generated vibration pulses to the treatment area. By changing from compression to decompression, microcirculation is improved and by stretching the fibres and muscle fibres, the muscle tension is improved by treating shortening and hardening. The C-Actor produces focused shock waves that are effective at the depth of the focus area. They mechanically stimulate the cells and the cell matrix. A chain of biological reactions is triggered: increased cell metabolism, release of eNOS, which has an anti-inflammatory effect, and numerous growth factors such as VEGF and TGF.

Our 63-year-old patient from Bahrain was in our outpatient care in 2013, 2014, and 2016. In 2016, no further scar treatment was performed, as the patient was very satisfied with the result. On another visit in 2018, the patient was prepared to take photos again (shown in Fig. 3). The medical history did not reveal any additional treatment of scars in the home country, either between the first and second stays or between the second and third stays. The normal skin care was continued.

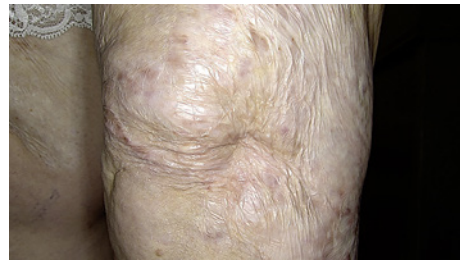


Fig. 3. Elbow right on representation on October 24, 2018.

The patient's general condition improved clinically during the first stay in 2013, although the appearance of the scars did not improve much. The patient admitted the scars were softer and she had fewer complaints. It was possible to reduce painkillers and sedatives by the second stay. Upon admission for the second stay, the skin condition improved significantly, and the patient was feeling considerably better. On the third visit, the patient stated that she was no longer taking oral medication. Pain and itching, the primary guiding symptoms, were no longer mentioned, and the skin condition had improved significantly. In 2018, we were able to take photos again, which showed a further improvement.

Objectively, the skin elasticity, measured with the Cutometer based on the suction method (Multiskincenter by Courage & Khasaka), was improved. Clinically, the scars became flatter and less noticeable and the mobility of the affected large joints (shoulder, elbow, and knee) improved, making the patient more mobile and able to walk and stand up again.

Conclusion for Practice Application

- AWT is a noninvasive treatment. The time required depends on the skin area affected.
- No relevant side effects are expected. Haematomas are possible; the dose must be adjusted over bony structures.
- The application range of AWT is very wide.
- The treatment of hypertrophic and contracted burn scars as a further indication should be investigated in systematic studies.

Statement of Ethics

Ethical approval is not required for this study in accordance with local or national guidelines. Written informed consent was obtained from the patient for the publication of this case report and any accompanying images.

Conflict of Interest Statement

Dr. C. Bettina Rümmelein and Dr. Ikonija Koceva state that there is no conflict of interest.

Funding Sources

This study did not receive any funding.

Author Contributions

Dr. C. Bettina Rümmelein examined the patient and took the pictures. Both Dr. C. Bettina Rümmelein and Dr. Ikonija Koceva reviewed this case and wrote the manuscript.

Data Availability Statement

All data generated in this study are included in the article. Further enquiries can be directed to the corresponding authors.

References

- 1 Finnerty CC, Jeschke MG, Branski LK, Barret JP, Dziewulski P, Herndon DN. Hypertrophic scarring: the greatest unmet challenge after burn injury. *Lancet*. 2016 Oct;388(10052):1427–36.
- 2 Gauglitz GG. Management of keloids and hypertrophic scars: current and emerging options. *Clin Cosmet Investig Dermatol*. 2013 Apr;6:103–14.
- 3 Cui HS, Hong AR, Kim JB, Yu JH, Cho YS, Joo SY, et al. Extracorporeal shock wave therapy alters the expression of fibrosis-related molecules in fibroblast derived from human hypertrophic scar. *Int J Mol Sci*. 2018 Jan;19(1):124.
- 4 Arnó A, García O, Hernán I, Sancho J, Acosta A, Barret JP. Extracorporeal shock waves, a new non-surgical method to treat severe burns. *Burns*. 2010 Sep;36(6):844–9.
- 5 Frairia R, Berta L. Biological effects of extracorporeal shock waves on fibroblasts. A review. *Muscles Ligaments Tendons J*. 2011 Oct;1(4):138–47.