

Antibiotic-induced black hairy tongue: two case reports and a review of the literature

Journal of International Medical Research

48(10) 1–11

© The Author(s) 2020

Article reuse guidelines:

sagepub.com/journals-permissions

DOI: 10.1177/0300060520961279

journals.sagepub.com/home/imr

Jing Ren^{1,#}, Yao Zheng^{1,#}, Hui Du^{2,#},
Shan Wang³, Linna Liu¹, Wanshi Duan⁴,
Zeping Zhang⁵, Lijun Heng⁶ and Qi Yang¹ 

Abstract

Black hairy tongue (BHT) is characterized by a discolored, hairy tongue. We herein report two cases of BHT associated with antibacterial agents and review previous cases. In Case 1, a 17-year-old girl with a central neurocytoma was administered intravenous piperacillin–tazobactam for postoperative infection, and BHT developed 12 days later. Her symptoms resolved 8 days after she discontinued the piperacillin–tazobactam and brushed her tongue three times daily. In Case 2, a 65-year-old man was administered intravenous piperacillin–tazobactam and levofloxacin to treat multidrug-resistant *Pseudomonas aeruginosa*, and BHT developed 15 days later. The piperacillin–tazobactam was discontinued and the patient brushed his tongue, and the discoloration gradually subsided thereafter. However, the BHT reappeared after linezolid treatment. The patient had adverse drug reactions to both the piperacillin–tazobactam and linezolid treatments. The BHT might have been related to antibiotic use in both cases. We identified 19 cases of antibiotic-related BHT in a literature search, but none were related to piperacillin–tazobactam use. In all cases, symptoms resolved after discontinuation of the drug and brushing of the tongue. BHT may be a rare adverse effect of antibiotics. Treatment strategies include removal of the causative agents, mechanical debridement, and good oral hygiene.

¹Department of Pharmacy, The Second Affiliated Hospital of Air Force Medical University, Xi'an, Shaanxi, China

²Xi'an Institute for Food and Drug Control, Xi'an, Shaanxi, China

³Department of Pharmacy, NYU Winthrop Hospital, Mineola, NY, USA

⁴Department of Thoracic surgery, The Second Affiliated Hospital of Air Force Medical University, Xi'an, Shaanxi, China

⁵Department of Neurosurgery, Baoji Traditional Chinese Medicine Hospital, Baoji, Shaanxi, China

⁶Department of Neurosurgery, The Second Affiliated Hospital of Air Force Medical University, Xi'an, Shaanxi, China

#These authors contributed equally to this work.

Corresponding author:

Qi Yang, Department of Pharmacy, The Second Affiliated Hospital of Air Force Medical University, 1 Xinsi Road, Xi'an, Shaanxi Province 710038, People's Republic of China.

Email: yangqi1262@126.com



Creative Commons Non Commercial CC BY-NC: This article is distributed under the terms of the Creative

Commons Attribution-NonCommercial 4.0 License (<https://creativecommons.org/licenses/by-nc/4.0/>) which permits non-commercial use, reproduction and distribution of the work without further permission provided the original work is attributed as specified on the SAGE and Open Access pages (<https://us.sagepub.com/en-us/nam/open-access-at-sage>).

Keywords

Black hairy tongue, piperacillin–tazobactam, adverse drug reaction, case report, literature review, Naranjo algorithm

Date received: 21 February 2020; accepted: 2 September 2020

Introduction

Black hairy tongue (BHT) is an unusual condition characterized by discoloration, elongation, and hypertrophied filiform papillae on the dorsal surface of the tongue.¹ Hairy tongue commonly appears black or brown; however, yellow, green, and blue appearances have also been reported.² BHT is usually asymptomatic, but some patients experience halitosis, tickling, or burning of the tongue.³ Antipsychotics, methyldopa, lansoprazole, interferon, antidepressants, antineoplastics, and antibiotics (e.g., cephalosporins, penicillins, tetracyclines, clarithromycin, and linezolid) have been reported to cause BHT.^{3,4} We herein report two cases of BHT after treatment with anti-infective agents. Using the Naranjo adverse drug reaction causality scale,⁵ we evaluated the association between BHT and antibiotics. To the best of our knowledge, these are the first two cases of BHT associated with piperacillin–tazobactam.

Case reports

Case 1

A 17-year-old girl presented with decreased vision in both eyes. She was diagnosed with a central neurocytoma. She had been healthy in the past and had no inherited diseases. The patient underwent excision of the intracranial space-occupying lesion and lumbar cistern catheterization. She was given ceftriaxone, omeprazole,

dexmedetomidine, and potassium chloride for a couple of days perioperatively. Eleven days after the operation, the patient presented with remittent fever. A cerebrospinal fluid (CSF) analysis revealed a white blood cell (WBC) count of $12 \times 10^6/L$ and a protein levels of 1330.85 mg/L. The CSF sample was cultured on Columbia agar with 5% sheep blood at 35°C. Intravenous (IV) vancomycin (1 g, every 8 hours) and meropenem (1 g, every 8 hours) were administered as empirical antibiotics on 23 November. Fifteen days after the operation, a CSF culture showed *Staphylococcus capitis*. Meropenem was stopped and sulfamethoxazole–trimethoprim was added according to the antimicrobial susceptibility results on 27 November. Two days later, the patient was febrile again (maximum body temperature of 39°C) with an elevated WBC count ($12.82 \times 10^9/L$). Piperacillin–tazobactam (4.5 g, every 6 hours, IV) was introduced on 29 November. The patient's temperature dropped and her WBC count returned to normal 1 day after initiation of the new therapy. Twelve days after initiation of the new antimicrobial therapy, the patient's mother reported blackish pigmentation on the surface of the patient's tongue (Figure 1(a)). Examination of her oral cavity revealed brown-to-black discoloration with a hairy coating on the posterior aspect of the dorsal surface of the tongue. The patient was diagnosed with BHT. *Bifidobacterium* was prescribed as a probiotic to regulate the flora based on suspicion of a secondary infection caused by

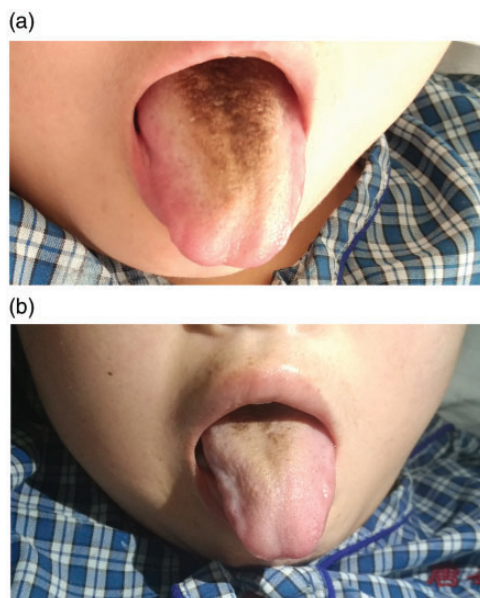


Figure 1. Case 1. (a) Black hairy tongue in a 17-year-old girl receiving piperacillin–tazobactam. (b) Image of the patient's tongue 2 days after stopping piperacillin–tazobactam and brushing the tongue.

piperacillin–tazobactam treatment. No culture of the BHT was performed. The piperacillin–tazobactam was discontinued, and the patient was asked to clean her tongue with a soft-bristle toothbrush three times a day. The patient also gargled after eating. Most of the hairy coating subsided after 2 days (Figure 1(b)). Total disappearance of the lesion was observed 8 days later. Using the Naranjo adverse drug reaction causality scale to evaluate the association between the drugs and BHT, the score for piperacillin–tazobactam was 5, which was higher than that for other drugs used by the patient.

Case 2

A 65-year-old man presented with a 24-year history of hypertension. His blood pressure was well controlled with enalapril. He had undergone surgical treatment of lung cancer

3 months prior. After 5 days of chemotherapy, he developed a fever. A peripheral blood test revealed a very low WBC count ($0.62 \times 10^9/L$) and platelet count ($63 \times 10^9/L$), indicating myelosuppression. To avoid gingival bleeding, the patient was asked not to brush his teeth. He was prescribed mouthwash containing silver ions, which he used three times a day to maintain oral hygiene. He had a 47-year smoking history and had not used cigarettes for about 2 years. He had 17 artificial teeth, which were removed and cleaned every night before sleep. He was administered tropisetron, granulocyte colony-stimulating factor, compound vitamins, and compound amino acids within the first week after admission. Fourteen days after admission, a sputum culture revealed multidrug-resistant *Pseudomonas aeruginosa*. Piperacillin–tazobactam (4.5 g, every 6 hours, IV) and levofloxacin (750 mg, once daily, IV) were started on 26 November. The patient became afebrile after 6 days, and repeated sputum cultures turned negative. The levofloxacin was discontinued on 7 December. After 5 days, the patient reported a brown-to-black discoloration of the tongue (Figure 2(a)). The patient was diagnosed with BHT. A scraping of the tongue was cultured, and no bacteria or yeast were found. The BHT was suspected to be secondary to treatment with piperacillin–tazobactam. The piperacillin–tazobactam and mouthwash were discontinued. The patient was advised to brush his tongue three times a day. The discoloration of his tongue gradually subsided. The Naranjo score for piperacillin–tazobactam was 3, which was higher than that for other drugs taken by the patient.

Outcome and follow-up

On 19 December, the patient in Case 2 developed a fever again. Piperacillin–tazobactam (4.5 g, every 6 hours, IV) and

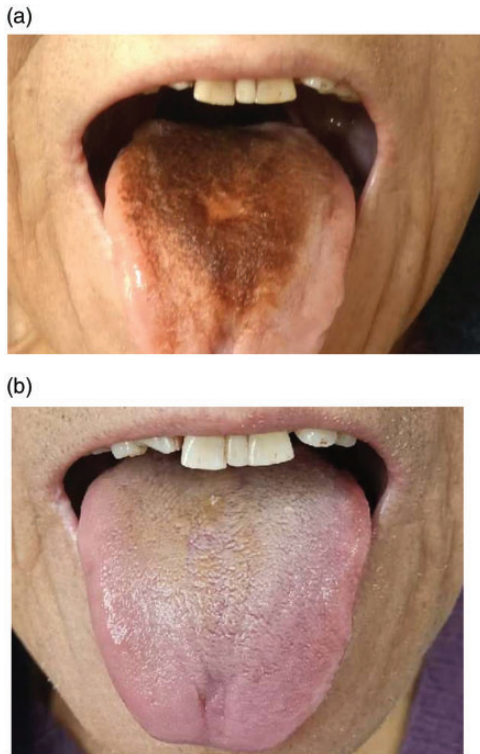


Figure 2. Case 2. (a) Black hairy tongue in a 65-year-old man receiving piperacillin–tazobactam. (b) Image of the patient's tongue 13 days after discontinuing treatment on 25 December.

linezolid (600 mg, every 12 hours, IV) were started again. Six days later, the piperacillin–tazobactam was discontinued. The tongue still exhibited brown discoloration (Figure 2(b)). Intravenous linezolid was administered for another 10 days. The BHT had not completely resolved when the patient was discharged from the hospital on 7 January.

The patient was prescribed linezolid tablets (600 mg, every 12 hours) for 1 month after leaving the hospital. The BHT recurred after he had been taking linezolid for about 7 days; however, he completed the 1-month course of linezolid. During this month, the tongue discoloration persisted despite brushing his tongue and

teeth three times a day. BHT associated with linezolid was suspected, and the Naranjo score was 7 (Table 1). The BHT eventually resolved nearly 10 days after discontinuation of linezolid.

The patient had an adverse drug reaction to both the piperacillin–tazobactam and linezolid treatments; the Naranjo scores were 3 and 7, respectively.

Patients' perspectives

In Case 1, the patient's mother felt that the treatment was very effective with low cost. In Case 2, the patient and his companion were confused about why the abnormal appearance of the tongue persisted, and they sought other solutions. They felt anxious until they were informed that BHT is a benign condition with a good prognosis. Both patients considered the treatment to be simple, practicable, and painless.

Literature review

A search of the online databases PubMed, Embase, and Web of Science as well as the reference lists of all retrieved articles was performed for articles published from 2000 to 2019. The search terms were “black hairy tongue,” “lingua villosa nigra,” “hairy tongue,” “antibiotic,” “side effect,” and “adverse drug reaction.” Reports in which BHT was associated with antimicrobials were collected. The full-text articles, if available, were retrieved. Non-English articles for which we could not acquire a translation were excluded from the literature review. In total, 16 articles describing 19 cases of antibiotic-induced BHT were found during the literature search. The clinical characteristics of all patients are listed in Table 2. The related antimicrobial agents were linezolid (n = 10), amoxicillin–clavulanate (n = 4), erythromycin (n = 1), doxycycline (n = 1), minocycline (n = 2), and metronidazole (n = 1). Of the 19 patients,

Table 1. Naranjo adverse drug reaction causality scale scores.

Question	Score		
	Case 1	Case 2 (P)	Case 2 (L)
1. Are there previous conclusive reports on this reaction?	0	0	+1
2. Did the adverse event appear after the suspected drug was administered?	+2	+2	+2
3. Did the adverse event improve when the drug was discontinued or a specific antagonist was administered?	+1	+1	+1
4. Did the adverse event reappear when the drug was readministered?	0	0	0
5. Are there alternative causes that could have caused the reaction on their own?	+2	-1	+2
6. Did the reaction reappear when a placebo was given?	0	+1	0
7. Was the drug detected in blood or other fluids in concentrations known to be toxic?	0	0	0
8. Was the reaction more severe when the dose was increased or less severe when the dose was decreased?	0	0	0
9. Did the patient have a similar reaction to the same or similar drugs in any previous exposure?	0	0	+1
10. Was the adverse event confirmed by any objective evidence?	0	0	0
Total score	5	3	7
Score	Probability of ADR		
≥9	Definite		
5–8	Probable		
1–4	Possible		
≤0	Doubtful		

P, piperacillin–tazobactam; L, linezolid; ADR, adverse drug reaction.

Source: Reference 5.

13 (68.4%) were male and 6 (31.6%) were female. The patients' ages ranged from 7 to 80 years. Six patients had other possible risk factors for BHT, such as smoking, edentulism, and poor oral hygiene. The Naranjo probability scale was applied in 13 reports. Microbiologic culture of the tongue or a throat swab revealed fungi in three patients, two of

whom were prescribed antifungal agents. In one case, the Naranjo score was 10, indicating a definite drug association. The mean time to the occurrence of linezolid-associated BHT was about 2 weeks. Most patients discontinued the suspected drug, and the BHT resolved in all of them with cleaning of the tongue and application of good oral hygiene.

Table 2. Summary of cases of antibiotic-associated black hairy tongue from the literature and two cases at our institution

Authors/year (reference)	Age/Sex	Suspected antibiotics	Symptoms	Microbiologic findings	Treatment	Duration	Recovery time	Possible risk factors	Naranjo score
Kim et al. 2002 (6)	55/M	Minocycline	Black hairy tongue	None	Discontinued minocycline	7 weeks	NR	Smoking and drinking	NR
Ramsakal and Mangat 2007 (7)	24/M	Doxycycline	Black discoloration and hairy appearance of the tongue	Throat culture was positive <i>Candida albicans</i>	Discontinued doxycycline and underwent treatment with a short course of fluconazole	1 week	3 days	NR	NR
Pigatto et al. 2008 (8)	40/M	Erythromycin	Black-brownish hairy tongue with nail discoloration	Culture of tongue swab specimen was positive for <i>Saccharomyces cerevisiae</i>	Discontinued oral erythromycin	5 months	Gradually improved	Smoking and drinking alcohol and coffee	NR
Refaat et al. 2008 (9)	74/M	Linezolid	Black coating on the surface of the tongue with hairy elevations	None	Discontinued linezolid	2 days	3 days	NR	6
Sheikh et al. 2011 (10)	53/F	Amoxicillin, clavulanate, and metronidazole	Black discoloration of the tongue	Tongue scrapings confirmed <i>Candida</i> infection	Short course of fluconazole	1 week	Within 7 days	High intake of caffeine drinks	NR
Bozkurt et al. 2012 (11)	40/F	Linezolid	Black hairy discoloration on the tongue, especially on the right side	NR	Brushed and practiced good oral hygiene	10 days	Nearly 1 week	NR	6
Khasawneh et al. 2013 (12)	56/M	Linezolid	Blackish discoloration of the tongue and dysgeusia	ND	Finished the antibiotic course and cleaned the tongue with a soft toothbrush and baking soda-containing toothpaste twice daily	4 days	4 weeks later	Edentulous with poor oral hygiene	6
Ajazi and Abdulla 2014 (13)	62/F	Linezolid	Black hairy discoloration of the tongue	NR	Discontinued the antibiotic and improved oral dental hygiene	2 weeks	3 weeks	Very poor oral hygiene	NR
Balaji et al. 2014 (14)	10/M	Linezolid	Black to brown hairy tongue	ND	Stopped the use of oral linezolid and cleaned the tongue with normal saline twice daily	14 days	11 days	NR	5
Jain et al. 2017 (15)	25/M	Linezolid	Black colored/hairy tongue	NR	Withdrew linezolid and cleaned tongue	10–15 days	15 days	NR	6
	30/F	Linezolid	Black hairy tongue	NR	Withdrew linezolid and cleaned the tongue with a soft brush	15 days	10 days	NR	6
Raj et al. 2016 (16)	26/M	Linezolid	Yellow to brown hairy tongue	ND	Withdrew linezolid	10 days	7 days	None	10

(continued)

Table 2. Continued.

Authors/year (reference)	Age/Sex	Suspected antibiotics	Symptoms	Microbiologic findings	Treatment	Duration	Recovery time	Possible risk factors	Naranjo score
Braga-Simoes and Santos 2016 (17)	52/M	Linezolid	Hairy tongue sensation, dark discoloration, xerostomia, and dysgeusia	NR	Withdrew linezolid	Unknown	3 weeks	None	7
Kuo and Fazel 2017 (18)	65/M	Metronidazole	Brown plaque on the dorsal tongue	NR	Used nystatin oral suspension for 4 days with minimal improvement, then applied topical tretinoin 0.1% cream to the tongue nightly and brushed the tongue with a hard-bristle toothbrush daily	2 weeks	1 month	NR	NR
Braggio et al. 2018 (19)	80/M	Linezolid	Swelling and discoloration of the tongue	NR	Withdrew drug	2 weeks	2 weeks	NR	NR
Hamad and Warren (20)	55/F	Minocycline	Black discoloration of the tongue	NR	Withdrew drug and practiced good hygiene	1 week	Within 4 weeks	NR	NR
Negri et al. 2018 (21)	59/F	Amoxicillin + clavulanate	Hypertrophic and hyperpigmented tongue	NR	NR	3 days	5 days	NR	4
	7/F	Amoxicillin + clavulanate	Black hairy tongue	NR	Withdrew drug	12 days	NR	NR	8
	38/M	Amoxicillin + clavulanate	Black hairy tongue	NR	Withdrew drug	1 day	NR	NR	4
Present cases 2020-2021	17/F	Piperacillin-tazobactam and SMZ-TMP	Brown to black discoloration with hairy coating	ND	Withdrew drug and cleaned tongue with soft-bristle toothbrush three times a day	12 days	10 days	None	5
	65/M	Piperacillin-tazobactam	Brown to black discoloration with hairy coating	None	Withdrew drug and cleaned tongue with soft-bristle toothbrush three times a day	15 days	13 days	Recent use of mouthwash	3
		Linezolid	Brown to black discoloration with a hairy coating	ND	Completed a 1-month course and brushed the tongue	2-3 weeks	10 days after discontinuation of linezolid	None	7

M, male; F, female; NR, not reported; ND, not detected; SMZ-TMP, sulfamethoxazole-trimethoprim

Discussion

The first case of BHT was documented in 1557 by Dr. Amatus Lusitanus, who described the condition as self-renewing of the tongue.¹ Since then, several cases have been described in the literature.

We have herein presented two cases of BHT in Chinese patients. In Case 1, recovery was observed 8 days after treatment. In Case 2, the brown discoloration persisted throughout the hospitalization period. Persistent discoloration may be related to the reuse of piperacillin–tazobactam before the problem is completely resolved. Notably, the linezolid-associated BHT recurred after the patient had been discharged from the hospital for about 1 week. The presence of linezolid-induced BHT was supported by the Naranjo score of 7. The duration of linezolid-related BHT was about 3 weeks, which was slightly longer than the durations in previous reports.

Limitations

Our study had two main limitations. First, because patients may not closely monitor their appearance while hospitalized, the reported onset of symptoms may be inaccurate. Second, the inpatient in Case 2 was in a fragile state, and a large amount of information was reported by his companion. Some details may have been omitted, affecting our assessment.

Etiology

Many substances and conditions aggravate, precipitate, and even cause BHT. First, several medications are associated with the development of BHT. The association of BHT with antibiotics such as erythromycin, doxycycline, linezolid, penicillin, minocycline, and metronidazole is well documented in the literature.³ Antipsychotic medications capable of causing xerostomia and

some chemotherapeutic agents are linked to BHT.¹ Second, various behavioral factors, such as smoking or chewing tobacco, excessive coffee consumption, alcohol consumption, heavy black tea consumption, and poor oral hygiene, increase the risk of BHT.³ Third, immunocompromised states, human immunodeficiency virus infection, advanced cancer, and recent radiation therapy to the head and neck region are also associated with an increased rate of BHT.¹ Fourth, certain conditions are thought to limit the normal desquamation of the keratinized filiform papillae, leading to hyperkeratosis. For example, patients with trigeminal neuralgia may experience pain during mastication.²² Pureed or soft diets with less roughage, such as those ingested by edentulous patients, are less likely to desquamate the dorsal tongue and may therefore lead to keratin retention.²³ Fifth, xerostomia alone is probably capable of causing BHT when combined with other predisposing factors.²⁴ Finally, there is evidence for a relationship between excessive use of oxidizing mouthwashes and BHT.²⁵

Clinical diagnosis

No objective diagnostic criteria have yet been established for BHT. The diagnosis of BHT depends on visual inspection of discolored, elongated, and hypertrophied filiform papillae. BHT should be differentiated from black tongue without elongated filiform papillae. A detailed history may be necessary to determine the contribution of a drug or other substance. Dermoscopy can be used as a diagnostic tool in BHT by enabling the precise detection of changes in the shape and color of filiform papillae.²⁶ Biopsy is not necessary unless the lesion is atypical, symptomatic, or suspected to be a malignancy or systemic disease. The patients described in this article were diagnosed with BHT without a dermoscopic examination or biopsy.

Pathophysiology

BHT may result from both environmental and intrinsic factors. BHT consists of two components: discoloration of the tongue and elongated filiform papillae. The elongated papillae can reach 12 to 18 mm in length and 2 mm in width.⁸ The most common coloration of the tongue is black or brown, but the tongue can also be green, yellow or blue. Based on the current study and case reports of antibiotic-induced BHT, four hypotheses for the pathogenesis of BHT can be considered. First, hair-like projections are thought to develop from delayed, inadequate desquamation of keratin over the filiform papillae. This may be caused by a lack of tongue movement and friction. Antimicrobial use may alter the usual flora of the mouth, and chromogenic bacterial growth may discolor the tongue. *Porphyromonas gingivalis*, a gram-negative anaerobic rod bacteria, produces porphyrin, which can discolor the tongue.²⁷ Second, antimicrobials can discolor the tongue, and inadequate desquamation can lead to a hairy appearance. Linezolid reportedly has an adverse effect of tooth discoloration.²⁶ Minocycline can also discolor the tongue or the thyroid.^{29,30} Third, long-term antimicrobial use may lead to a secondary fungal infection of the tongue. In our review, a fungal culture was performed for seven patients. *Candida* species or *Saccharomyces cerevisiae* was found in throat or tongue swab cultures of three patients. No culture was performed for the patient in Case 1 of our study. In Case 2, a culture was performed but no bacteria or yeast were found. Fourth, the urinary nicotinamide output decreases substantially during oral penicillin therapy,³¹ suggesting that penicillin inhibits the growth of intestinal organisms involved in the synthesis of nicotinamide.

Management

BHT is a benign, asymptomatic, and self-limiting disease with a good prognosis. Identifying the at-risk population and performing appropriate interventions can reduce the development of BHT. Patients receiving medications associated with BHT should be educated on preventive techniques. The risk of BHT may be reduced by practicing good oral hygiene. After diagnosis, a thorough medical and medication history is needed to establish the causative relationship. In our review, most patients discontinued use of the suspected drug, and the BHT was resolved in all patients by cleaning the tongue and applying good oral hygiene. Accordingly, first-line treatments include discontinuation of the offending drug and modification of predisposing habits, such as the cessation of oxidizing mouthwashes and smoking, good oral hygiene, and gentle debridement with a soft toothbrush.

Because antibiotic-related BHT is rare, clinicians who encounter it for the first time may attribute the abnormality of the tongue to a secondary infection after a period of antibiotic use. Antifungal agents and/or probiotics may be prescribed as empirical therapies. However, in our review of 19 cases, only Ramsakal and Mangat⁷ and Sheikh et al.¹⁰ confirmed the presence of *Candida* species. Whether the microbiological finding of fungi represents an infection or colonization remains unclear. Therefore, antifungal treatment as first-line therapy is not recommended. There are also many anecdotal reports demonstrating the use of other products to treat BHT, such as topical 50% trichloroacetic acid, topical 40% urea solution, vitamin B complex, gentian violet, and thymol.²⁴ Our review and two newly reported cases clearly indicate that BHT is reversible and unlikely to be harmful; accordingly, the causative drug can be reintroduced if necessary.

Conclusion

BHT is a benign, self-limiting disease with a good prognosis. Current treatment is focused on mechanical debridement, good oral hygiene, and the removal of potential causative agents. Antifungal treatment is usually unnecessary.

Declaration of conflicting interest

The authors declare that there is no conflict of interest.


Ethics approval and consent to participate

This study was approved by the Ethics Committee of The Second Affiliated Hospital of Air Force Medical University, Shaanxi, China. Written informed consent was obtained from the next-of-kin of both patients for the publication of the case reports and accompanying images.

Funding

This work was supported by the Shaanxi Province Youth Science and Technology New Star Plan (2018KJXX-089).

ORCID iD

Qi Yang  <https://orcid.org/0000-0001-8243-2699>

References

- Schlager E, St Claire C, Ashack K, et al. Black hairy tongue: predisposing factors, diagnosis, and treatment. *Am J Clin Dermatol* 2017; 18: 563–569.
- Nisa L and Giger R. Black hairy tongue. *Am J Med* 2011; 124: 816–817.
- Gurvits GE and Tan A. Black hairy tongue syndrome. *World J Gastroenterol* 2014; 20: 10845–10850
- Jhag R, Gour PR and Asati DP. Black hairy tongue with a fixed dose combination of olanzapine and fluoxetine. *Indian J Pharmacol* 2016; 48: 318–320.
- Naranjo CA, Busto U, Sellers EM, et al. A method for estimating the probability of adverse drug reactions. *Clin Pharmacol Ther* 1981; 30: 239–245.
- Kim SB, Kim GA, Kim IH, et al. A case of black hairy tongue associated with minocycline. *Korean J Dermatol* 2002; 40: 319–321.
- Ramsakal A and Mangat L. Lingua villosa nigra. *N Engl J Med* 2007; 357: 2388.
- Pigatto PD, Spadari F, Meroni L, et al. Black hairy tongue associated with long-term oral erythromycin use. *J Eur Acad Dermatol Venereol* 2008; 22: 1269–1270.
- Refaat M, Hyle E, Malhotra R, et al. Linezolid-induced lingua villosa nigra. *Am J Med* 2008; 121: e1.
- Sheikh Z, Khan AS and Khan S. Lingua villosa nigra. *Lancet* 2011; 377: 1183.
- Bozkurt I, Yontar E and Doganay M. Black hairy tongue: a rare side effect of linezolid. *Our Dermatol Online* 2012; 3: 136–137.
- Khasawneh FA, Moti DF and Zorek JA. Linezolid-induced black hairy tongue: a case report. *J Med Case Rep* 2013; 7: 46.
- Aijazi I and Abdulla FM. Linezolid induced black hairy tongue: a rare side effect. *J Ayub Med Coll Abbottabad* 2014; 26: 401–403.
- Balaji G, Maharani B, Ravichandran V, et al. Linezolid induced black hairy tongue. *Indian J Pharmacol* 2014; 46: 653–654.
- Jain AK, Puri MM and Sarin R. Black brown discoloration and hairy tongue - a rare linezolid side effect. *Indian J Tuberc* 2017; 64: 44–46.
- Raj RT, Raj R, Nagpal J, et al. Linezolid induced black hairy tongue an uncommon phenomenon: a case report with update of review of literature. *Am J Med Sci Med* 2016; 4: 71–76.
- Braga-Simões J and Santos LA. Linezolid-induced hairy tongue. *Oxf Med Case Reports* 2016; 12: 295–296.
- Kuo S and Fazel N. Black hairy tongue due to metronidazole. *J Am Acad Dermatol* 2017; 76: AB56.
- Braggio C, Bocchialini G, Ventura L, et al. Linezolid-induced black hairy tongue. *Acta Biomed* 2018; 89: 408–410.
- Hamad Y and Warren DK. Black hairy tongue. *N Engl J Med* 2018; 379: e16.

21. Negri A, Morina M, Celentano A, et al. Black hairy tongue (BHT) associated with use of amoxicillin: three case reports. *Clin Toxicol* 2018; 56: 116.
22. Cheshire WP. Unilateral black hairy tongue in trigeminal neuralgia. *Headache* 2004; 44: 908–910.
23. Kannan S, Muthusamy S, Chandrasekaran B, et al. Black hairy tongue in older edentulous individuals. *J Am Geriatr Soc* 2014; 62: 992–994.
24. Thompson DF and Kessler TL. Drug-induced black hairy tongue. *Pharmacotherapy* 2010; 30: 585–593.
25. Sarti GM, Haddy RI, Schaffer D, et al. Black hairy tongue. *Am Fam Physician* 1990; 41: 1751–1755.
26. Kobayashi K, Takei Y, Sawada M, et al. Dermoscopic features of a black hairy tongue in 2 Japanese patients. *Dermatol Res Pract* 2010; 2010: 145878. doi:10.1155/2010/145878.
27. Dashper SG, Cross KJ, Slakeski N, et al. Hemoglobin hydrolysis and heme acquisition by *Porphyromonas gingivalis*. *Oral Microbiol Immunol* 2004; 19: 50–56.
28. Santos JA, Varandas L and Gouveia C. Reversible teeth discoloration in children: a linezolid therapy side effect. *Clin Pediatr* 2015; 54: 809.
29. Tanzi EL and Hecker MS. Minocycline-induced hyperpigmentation of the tongue. *Arch Dermatol* 2000; 136: 427–428.
30. Nishimoto K, Kumai Y, Murakami D, et al. A case of minocycline-induced black thyroid associated with papillary carcinoma. *Ear Nose Throat J* 2016; 95: E28–E31.
31. Wolfson SA. Black hairy tongue associated with penicillin therapy. *J Am Med Assoc* 1949; 140: 1206–1208.