

Evaluation of ocular surface and tear function - A review of current approaches for dry eye

Shizuka Koh, Srinivas K Rao¹, Sanjeev P Srinivas¹, Louis Tong², Alvin L Young³

An increasing prevalence of dry eye disease in the past decade has resulted in a greater focus on diagnostic methods for this condition. There has been a proliferation of technologies that attempt to quantify various aspects of tear function and ocular surface health. However, a cost-effective, simple, and efficient method remains elusive. In the Indian context, the majority of these patients present to the general ophthalmologist, and a clinical approach that is quick and easy to perform would allow widespread usage for accurate diagnosis. This article reviews currently available methods and their relevance to the general ophthalmologist.

Key words: Dry eye disease, ocular surface, tear film

Access this article online

Website:

www.ijo.in

DOI:

10.4103/ijo.IJO_1804_21

Quick Response Code:



The precorneal tear film was first described by Wolff in 1946 as a three-layered structure composed of a superficial lipid layer, a middle aqueous layer, and a deeper mucin layer.^[1] A more recently proposed model suggests a two-layered structure for the tear film with the superficial lipid layer protecting a hydrated mucogel. Membrane-associated mucins (MUC1, 4, 16) on the epithelial cell microvilli constitute the glycocalyx, while gel-forming soluble mucins (MUC5AC) are dispersed throughout the aqueous layer.^[2] The volume of the tear film is 6–10 μL with a turnover of approximately 16% per minute, and a thickness of 3–5 μm .^[3] This small volume of tears is constantly regulated by a complex system involving neural, humoral, endocrine, immune, and tactile feedback mechanisms to ensure the stability of the tear film between blinks. A stable precorneal tear film is essential for comfort and clear vision. A variety of insults can affect the homeostasis of the tear film, resulting in changes in volume, composition, and turnover, causing discomfort and dysfunction of the ocular surface.

All epithelia on the ocular surface are continuous, although the type of epithelium can vary in the lid margins, the palpebral, forniceal and bulbar conjunctiva, the limbus, and the cornea. This epithelial lining is also in continuity with the glandular epithelia of the lacrimal gland, accessory lacrimal glands, and

the meibomian glands. While this structure represents the anatomical ocular surface, it is functionally integrated with the tear film, the lids and lashes, and the nasolacrimal duct, and together with the neural and immune system represent the ocular surface system, also termed the lacrimal functional unit.^[4] These components work together in synergy to provide, protect, and maintain a smooth corneal refractive surface, and disturbance in any one of these components can result in the deranged function of the other linked elements as well. Thus, to evaluate the ocular surface and tear film in health and disease, it may be necessary to consider the ocular surface system as a whole. However, each component is distinct in anatomy and function, and a thorough understanding of their roles is necessary to help plan the evaluation.

The tear film lipid layer is derived from meibomian gland secretions, which are expressed from the lid margins and spread across the tear film during each blink. It is approximately 100-nm thick and is composed of phospholipids, free fatty acids, and cholesterol.^[5] The surfactant action helps lower the surface tension at the air–surface interface of the precorneal tear film, thereby retarding tear evaporation and maintaining stability between blinks. Excess lipid contaminates the glycocalyx, rendering it hydrophobic, while too little lipid promotes rapid evaporation and both conditions result in tear film instability.

Departments of Innovative Visual Science and Ophthalmology, Osaka University Graduate School of Medicine, Osaka, Japan, ¹Department of Ophthalmology, Darshan Eye Care and Surgical Centre, Chennai, India, ²Department of Ophthalmology, Yong Loo Lin School of Medicine, NUS, Singapore, ³Department of Ophthalmology and Visual Sciences, The Chinese University of Hong Kong, Hong Kong, PRC

Correspondence to: Dr. Srinivas K Rao, Darshan Eye Care and Surgical Centre, T 80, Fifth Main Road, Anna Nagar, Chennai - 600 040, Tamil Nadu, India. E-mail: srinikrao@gmail.com

Received: 05-Jul-2021
Accepted: 10-Jan-2022

Revision: 22-Aug-2021
Published: 31-May-2022

This is an open access journal, and articles are distributed under the terms of the Creative Commons Attribution-NonCommercial-ShareAlike 4.0 License, which allows others to remix, tweak, and build upon the work non-commercially, as long as appropriate credit is given and the new creations are licensed under the identical terms.

For reprints contact: WKHLRPMedknow_reprints@wolterskluwer.com

Cite this article as: Koh S, Rao SK, Srinivas SP, Tong L, Young AL. Evaluation of ocular surface and tear function - A review of current approaches for dry eye. Indian J Ophthalmol 2022;70:1883-91.

The aqueous layer is a mucogel that constitutes more than 90% of the tear film and is primarily composed of water (98%), with salts, proteins, and growth factors. It is secreted by the lacrimal and accessory lacrimal glands and subserves the functions of hydration, lubrication, refraction, and protection from infection. Tear turnover and drainage during blinks serve to flush the ocular surface and remove debris and other noxious substances. Thus, while a lack of tears can cause hyperosmolarity and interfere with its various functions, an excess of tears due to impaired drainage can promote inflammation of the surface due to the retention of noxious substances on the surface.^[6]

The membrane-associated mucins are responsible for maintaining the wettability of the ocular surface by constituting the glycocalyx. Their attachment to the microplicae of the corneal epithelial cells increases the adhesion tension for water, facilitating the spread of tears across the ocular surface. They also offer a physical barrier for epithelial cells against injury and infection. The thickness of the mucin layer varies between 0.02 and 0.05 μm .^[3] Soluble mucins are secreted by the conjunctival goblet cells and are dispersed throughout the tear film, and help in hydration and lubrication.^[7]

It is widely accepted that the bulk of the tear fluid comprising the aqueous portion of tears is supplied by the lacrimal gland. It is secreted into the superior fornix, and under normal circumstances, reaches the exposed surface of the eye by entering the tear meniscus. The tear meniscus is the distance the tear film extends along the ocular surface perpendicular to the lid margin. The normal tear meniscus height ranges between 250 and 600 μm .^[8] Eyelid movement during blinking spreads the tear film uniformly across the ocular surface. Negative pressure flow then causes the tear fluid to move toward the nasal puncta, where it is drained into the nasolacrimal system, aided by the contraction of the orbicularis muscle. This maintains a balance between tear secretion and removal and is important for an uninflamed ocular surface. The tears also protect against infection and help maintain the ocular microbiome.

Many intrinsic and extrinsic factors can affect the stability of the tear film. As mentioned earlier, the ocular surface system comprises other components as well; thus, apart from measures of tear function such as volume, quality, and turnover, changes in the anatomy and function (blink reflex) of the other adnexal structures must also be looked for. These changes result in inflammation, which is responsible for much of the damage that is seen clinically, and the evaluation process must detect the presence and extent of ocular surface inflammation. Thus, an understanding of the healthy tear film and its relationship with the ocular surface system is important to facilitate a thorough evaluation, which allows better treatment.

The Dry Eye Patient

Symptoms of dry eye disease (DED) include constant ocular irritation, foreign body sensation, and blurred vision, which lead to a negative impact on the patients' daily life and social functioning, making DED an important public health problem.^[9,10] However, there is a discrepancy between the ocular signs and symptoms of DED,^[11] and the symptoms are often more aligned to non-ocular conditions than to the tear film parameters.^[12] DED has recently been associated with other

chronic pain conditions and may share genetic susceptibility with depression.^[13-16] Depression and anxiety are more prevalent in DED patients than in controls. Among patients with DED, those suffering from primary Sjögren's syndrome have a higher prevalence and severity of depression.^[17]

Patients who complain of symptoms yet have minimal clinical signs encompass two subcategories: those in a preclinical dry eye state and those with neuropathic pain. Preclinical dry eye patients have intermittent symptoms and can be managed by education, monitoring, and prevention. Patients with neuropathic pain may have a lesion in the somatosensory system, where the ocular pain symptoms disproportionately outweigh the clinical signs. Such patients require management by a pain specialist. Conversely, there are patients with signs of DED on testing but who are asymptomatic. These can either be patients with a predisposition to DED who are found to have ocular surface changes without symptoms, for example, during a preoperative examination, or those with reduced corneal sensitivity. In the latter, they may have a concomitant corneal disease with reduced corneal sensation or corneal damage secondary to long-standing DED which can mask any discomfort.

Patients with aqueous deficiency dry eye (ADDE) may complain of grittiness, discomfort, stinging, burning, tired eyes, photophobia, visual fluctuations, and paradoxical tearing in the early stages. ADDE patients may have worse symptoms in the morning, postulated to be because of tear hyposecretion during sleep, which improves when the patient is awakened, and the blink reflex stimulates tear secretion and amelioration of symptoms. A high index of suspicion for an underlying autoimmune disease should be present when a young patient presents with severe ADDE. Patients with evaporative dry eye typically complain of a burning sensation that is poorly relieved by tear substitutes. This may be related to evaporation causing a concentration of salts and proteins as well as inflammation from meibomian gland dysfunction (MGD). Patients with severe disease have worse symptoms in the morning, whereas those with mild disease have increased symptoms in the evening due to meibum contamination of the tear film. Patients who have mucus deficiency may present with an increased blink rate to maintain visual clarity as the impaired tear film breakup (TBUT) time can lead to fluctuations in vision.

To aid in the diagnosis of the symptoms and measure the impact of DED on quality of life, multiple questionnaires have been created and tested. Two of the commonly used indices are the Ocular Surface Disease Index and the Dry Eye Questionnaire-5. These are used to quantify the extent of patient discomfort and complaints.

Various factors can impact the production, flow, and removal of tears resulting in DED, and MGD is known to impact tear function. However, many other related conditions can also adversely influence the homeostasis of the tear film and ocular surface. These include contact lens wear, allergies and infections of the ocular surface, the use of topical and systemic medications, hormonal imbalances, ocular surgery, neurotrophs, underlying primary and secondary immune disorders, conjunctivochalasis, superior limbic keratoconjunctivitis, conditions that impair a normal lid blink reflex such as Parkinson's disease, thyroid eye disease and facial nerve palsy, incomplete blink secondary to structural changes in the lid, increased friction-related damage

due to changes in the lid wiper, conditions promoting tear stasis, and extreme environmental conditions affecting temperature, humidity, and airflow. These must also be considered in the evaluation of such patients.

Assessing the tear film and ocular surface

A proper assessment of the ocular surface, tear film, and patient symptom questionnaire is essential and should be conducted based on the protocols suggested by both the Dry Eye Workshop (DEWS) II report and the Asia Dry Eye Society (ADES) consensus report.^[18,19] According to DEWS II, dry eye is characterized by multiple potential pathogeneses, whereas ADES relies on tear film instability based on defects in one or more components of the tear film or epithelial surface abnormalities. The postulated mechanism of the vicious cycle DED is different in DEWS II and ADES. While the DEWS II report implicates inflammation and hyperosmolarity as key triggers, in ADES, more attention is paid to tear film instability or tear film breakup. Therefore, current methods used to assess tear film anatomy and function should focus on these key factors. Ideally, these methods should be simple and easy to use in every ophthalmic clinic.

The recommended criteria for dry eye diagnosis by DEWS II are the presence of symptoms and at least one positive result for homeostasis markers (decreased non-invasive tear breakup time (NIBUT), increased osmolarity, or a certain amount of ocular surface damage).^[18] In ADES, however, dry eye can be diagnosed by a combination of symptoms and an unstable tear film (decreased TBUT), with greater dependence on tear film stability^[19] [Fig. 1].

For reliable TBUT measurement, observation of the entire cornea to detect the breakup area should be performed. The time to appearance of the first random black spot, indicating an absence of the fluorescein-stained tear film, is noted. The spot must not involve an area of altered corneal surface, and three readings are averaged. It is ideal to use a metronome to measure time. The suggested cut-off value is 5 s, and eyes with deficient tear function have a value less than the cut-off. Detecting the time to distortion of a grid reflected from the tear film requires an instrument is considered non-invasive and more physiological and is termed NIBUT.

The tear volume is measured by estimating the tear meniscus heights or by performing a Schirmer test by measuring wetting at 5 min. In the clinic, tear meniscus assessment at the slit-lamp is subjectively assessed as normal, reduced, or excessive. Automated instruments measure height by using a photograph or the volume by using meniscometry.^[20] The Schirmer test in its various iterations provides useful information if performed in a consistent manner. The original Schirmer test (Schirmer I) is performed without anesthetic, and the Jones test is performed with anesthetic to minimize reflex tearing. The Schirmer II test is performed with conjunctival anesthesia and nasal stimulation when fatigue of the ocular surface receptors is suspected. Normal values for the first two are >15 mm and >10 mm, and ADDE is confirmed if the last test value is <5 mm.

Measuring the lipid layer requires an instrument and uses tear film interferometry. The meibomian glands are assessed clinically by lid eversion or the use of infrared meibographs. The secretions can be expressed using a spring-loaded

device (Korb evaluator) or by using the thumb to exert firm pressure on the middle third of the lower lid. The number of glands expressing secretions and the quantum and the quality of the secretions are assessed subjectively.^[21]

Hyperosmolarity of the tear film is considered an important trigger for inflammation and can be measured using a point-of-care device such as TearLab®, with a normal value of 302 ± 6 mOsmol/kg.^[22] Some of the other aspects of tear function include tear evaporation, turnover, viscosity, surface tension, pH, ferning as a measure of tear quality, and estimation of the type and amount of proteins and electrolytes in the tears. These are generally reserved for research settings. Although it is clinically useful to assess delays in tear clearance from the surface, by estimating the retention time of fluorescein in the tear meniscus, this is more subjective than the tear clearance tests. Prolonged retention of fluorescein in the meniscus indicates a pro-inflammatory state.

Although detailed quantitative assessments of these metrics require advanced devices, a practical diagnosis of dry eye is also possible with the use of only fluorescein, which is routinely used in combination with slit-lamp biomicroscopy in every ophthalmology clinic. Fluorescein staining is a basic technique in clinical practice, which assesses the integrity of the corneal and conjunctival epithelium, aids in visualizing the volume of the tear film in the meniscus, and estimates stability by measuring the TBUT. The use of fluorescein involves three steps, which are best performed using a standardized, repeatable technique. Step 1: Apply a minimal amount of fluorescein with saline. The use of dry eye drops should be avoided because it may affect the results owing to the demulcent in these drops. Ideally, normal saline should be used to wet the strip. Step 2: Shake the strip vigorously to remove excess diluent from the strip. Step 3: The fluorescein strip is gently applied to the inferior palpebral conjunctiva, with the patient looking up [Fig. 2].

Epithelial damage in the cornea and conjunctiva can be observed with fluorescein. Generally, epithelial damage is greater in the conjunctiva than in the cornea. In dry eyes, corneal staining is usually observed in the inferior or central part of the cornea as the upper 2 mm is usually covered by the upper lid and is protected from desiccation, except in extreme dry eye states and accompanying associated conditions such as superior limbic keratoconjunctivitis, trichiasis, and eyelid wiper variants. Using a cobalt blue filter (transmission spectrum: 410–500 nm) allows better excitation of the fluorescein in the tear film over the cornea but interferes with the visualization of conjunctival staining due to the intense reflection of the blue light from the underlying sclera. The use of a blue-free, yellow barrier filter (transmission >510 nm) can enhance the visibility of fluorescein staining in the conjunctiva by blocking the blue light^[23] [Fig. 3]. Thus, using a yellow barrier filter facilitates the assessment of both corneal and conjunctival staining with fluorescein, obviating the need for rose bengal or lissamine green, which are not commonly available in general clinics.

The ADES classification scheme, which uses only fluorescein staining, is valuable as it also suggests the optimal management of the dry eye state, and this is termed tear film-oriented therapy (TFOT).^[24] Depending on the component of the tear film that is defective, selective topical therapy is suggested to stabilize the tear film. For optimal TFOT, a diagnostic method

is needed to suggest the insufficient component(s) of the tear film. This is called tear film-oriented diagnosis (TFOD). A practical diagnosis based on the fluorescein breakup pattern is recommended.^[25] ADES categorizes dry eye into three types: aqueous deficient dry eye (ADDE), increased evaporation dry eye, and decreased wettability dry eye, based on tear film abnormalities or epithelial surface abnormalities. The classification of dry eye based on the tear film break-up pattern is shown in Fig. 4.^[26]

ADDE is the classical type of dry eye, including Sjögren’s syndrome, which is associated with an unstable tear film due to aqueous tear deficiency, and is diagnosed by noting an area or line pattern. Area break is diagnosed when the upward movement of fluorescein is not observed or is limited to the lower part of the cornea. Line break is diagnosed as a vertical line-like shape during the upward movement of

fluorescein in the lower part of the cornea, within which fluorescein intensity decreases with time until the cessation of the upward movement of fluorescein. The deficiency of membrane-associated mucin decreases the wettability of the cornea and conjunctiva, contributes to instability of the tear film, shortens the tear film breakup time, and is diagnosed by noting a spot or dimple pattern. Spot break is diagnosed as a spot-like shape immediately after eye opening, and at least one spot break is required for diagnosis. Dimple break is diagnosed as an irregular but vertical line-like shape during the upward movement of fluorescein within the zone closer to the central part of the cornea. Abnormal lipid components are thought to accelerate tear evaporation, resulting in an unstable tear film, and is diagnosed by noting a random pattern. Random break is diagnosed as an irregular and indefinite shape whose typical location differs between cases and with each blink.

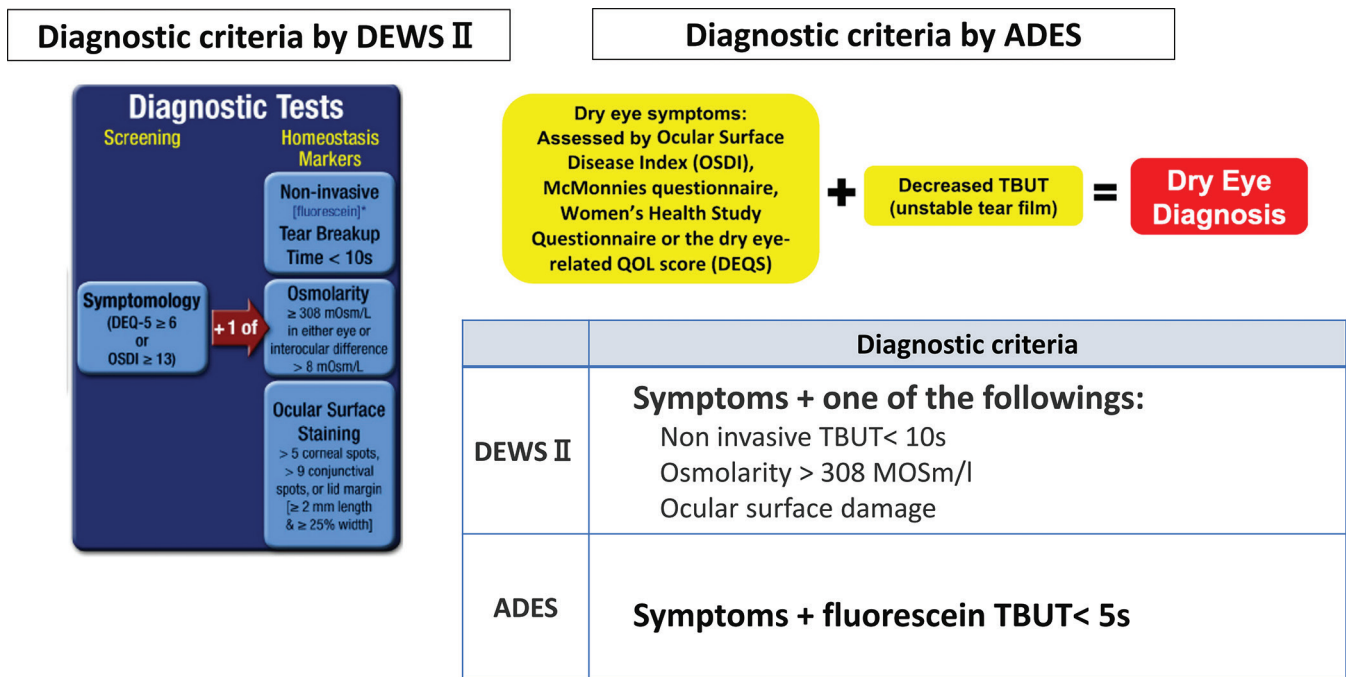
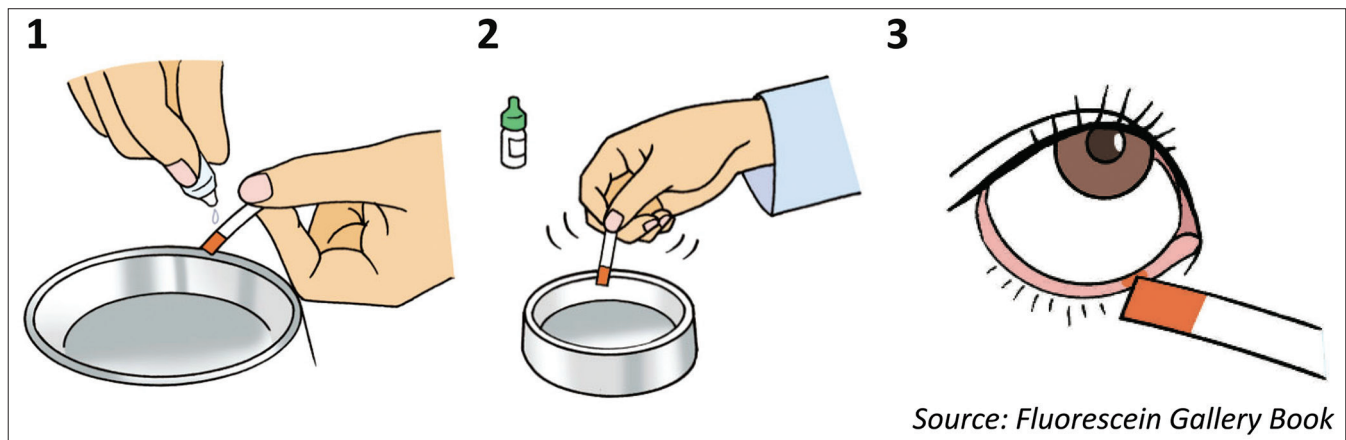


Figure 1: The criteria used by the Dry Eye Workshop II (DEWS II) and Asia Dry Eye Society (ADES) to diagnose dry eye disease. (Reprinted with permission from references 18 and 19)



Source: Fluorescein Gallery Book

Figure 2: Fluorescein staining of the ocular surface – the three steps (Images from “Fluorescein Gallery Book” with permission)

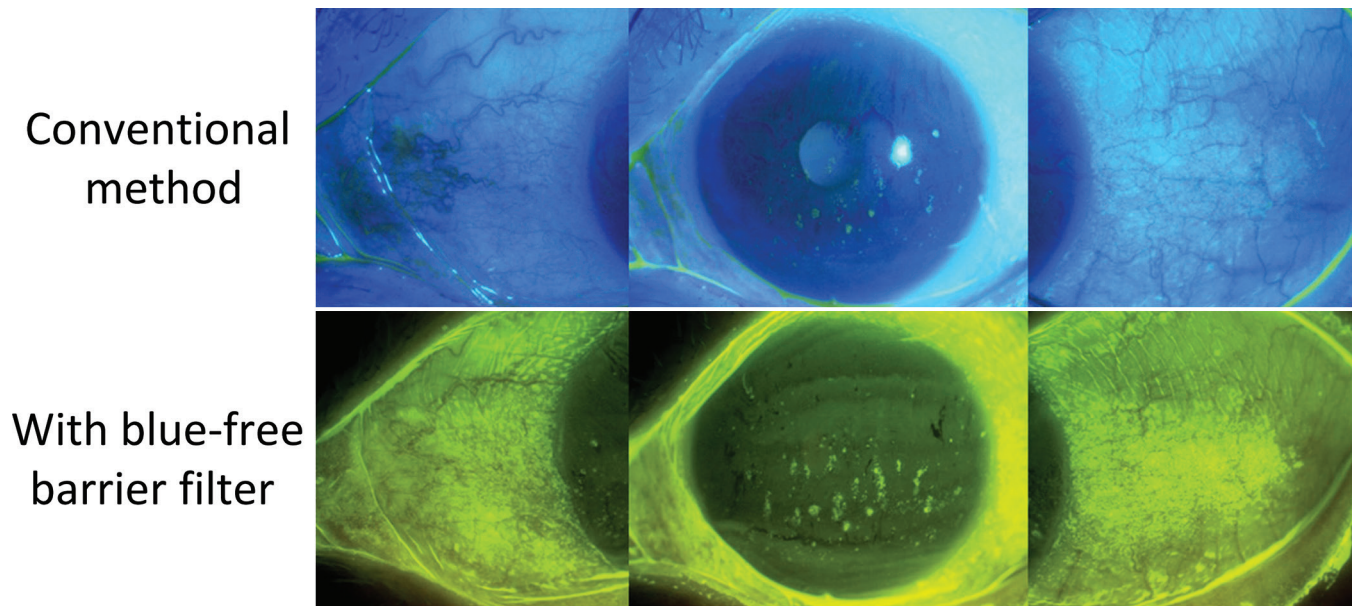


Figure 3: The use of a yellow filter allows assessment of conjunctival staining with fluorescein

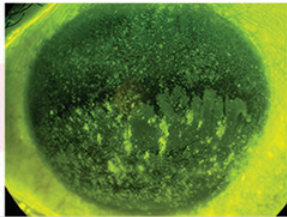
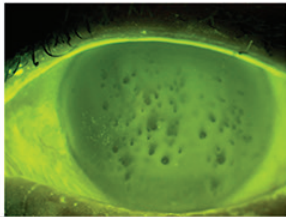
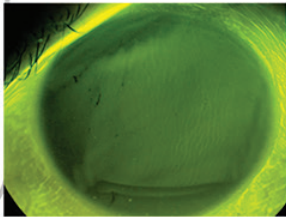
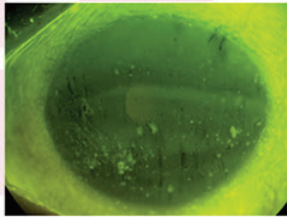
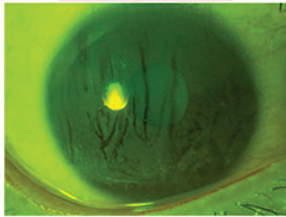
Dry eye type	Aqueous deficient dry eye	Decreased wettability dry eye	Increased evaporation dry eye
Insufficient component	Aqueous tears	Membrane associated mucin	Lipids/ Secretory mucin
Severe	(Severe) Area break	(Severe) Spot break	Random break
Right after the blink			
Mild to moderate	(Mild to moderate) Line break	(Mild to moderate) Dimple break	After FL spreading upward
During FL spreading upward			

Figure 4: Tear Film Oriented Diagnosis (TFOD) – the fluorescein breakup patterns and their significance in diagnosing different types of dry eye. (FL - fluorescein). (Reprinted with permission from reference 26 with modification)

Although TFOD is attractive as it uses a simple clinical method, it requires practice to recognize the various patterns described, which can be challenging, at least in the beginning. The DEWS II guidelines include the use of non-invasive tear breakup time, tear osmolarity measurement, and ocular

surface staining to confirm the presence of a tear deficiency state. Of these, only the last can be performed in a general eye clinic in the absence of specific instrumentation. To determine the contribution of aqueous deficiency and evaporative pathologies, the DEWS II guidelines recommend the use of tear

meniscus height measurement, lipid layer measurement, and visualization of the meibomian gland anatomy,^[27] all of which require instrumentation usually not available in a general eye clinic. Conventional methods such as Schirmer test, fluorescein tear breakup time, and assessment of the quantum and quality of the meibum secretions by pressure on the lower lid can also be used to determine the extent and type of tear deficit.

Assessing ocular surface inflammation

Apart from the changes described in the previous section, the DEWS II report also implicates inflammation and neurosensory abnormalities as key etiological components of DED.^[27] Inflammation is intended to protect an injured ocular surface by activation of the innate immune system. However, in conditions such as DED, the persisting stimuli of hyperosmolarity and friction-induced surface damage during blinking result in activation of the adaptive immune system, resulting in chronic inflammation.^[28] The inflammation further potentiates the dry eye state by damaging the tear secreting elements in the conjunctiva, and the stressed epithelial cells produce corneal envelope precursors, which induce keratinization in the secretory ducts of the meibomian glands. This results in less lipid secretion onto the ocular surface, further worsening DED, and the backpressure in the glands due to the blocked ducts produces gland atrophy and dropout. Thus, over time, the vicious cycles of DED, MGD, and inflammation coexist on the ocular surface and are interrelated and self-propagating. Knowledge of these changes is helpful as immune pathways and molecular triggers can be targeted with specific therapy^[29] [Fig. 5].

The most clinically evaluated inflammatory biomarker at present is matrix metalloproteinase-9 (MMP-9), although this marker is not specific for DED. It is also possible that inflammation on the ocular surface can be mediated by other molecules and enzymes. Thus, while the ability to detect the presence of MMP-9 on the ocular surface by using the point-of-care InflammDry® test is useful, it has its limitations. It is a semi-quantitative test that is positive when more than 40 ng/mL of MMP-9 is detected. However, it is associated with a high cost per test and is unavailable in a general eye clinic at present. Because inflammation is considered an important part of the ocular surface system dysfunction, detecting it by other clinical tests becomes necessary.

Clinically, conjunctival hyperemia is a simple but effective sign of ocular surface inflammation. The location and extent of the redness, associated with the presence of edema, provide clues regarding the cause and severity of the inflammation. In ocular surface inflammation related to DED, the redness is diffuse, and the extent can either be graded semi-quantitatively or by using photographic standards such as the Efron scale. The quantification can also be done with the help of an automated measurement and digital image analysis. If the inflammation is intraocular as in uveitis, the redness is often more in the circumcorneal region, while in scleritis and episcleritis, it is more often localized to the inflamed area. In conjunctivitis, the redness in the palpebral conjunctiva often exceeds that in the bulbar conjunctiva, and there is associated watering or discharge depending on the cause of the infection. Redness limited to the superior limbal and bulbar conjunctiva suggests limbic keratoconjunctivitis, while that limited to the inferior bulbar conjunctiva associated with conjunctival staining suggests medication toxicity.

A study by Yang *et al.*^[30] noted that the extent of conjunctival staining with lissamine green correlated with the levels of markers of inflammation such as interferon- γ , IL-6, IL-17, and MMP-9 in two groups of patients with non-Sjögren's syndrome DE and Sjögren's syndrome DED. Although corneal staining scores with fluorescein showed positive correlations with interferon- γ , IL-17, and MMP-9, the correlation coefficients were lower than those seen with conjunctival staining.

Another sign that has been described is the presence of lid parallel conjunctival folds (LIPCOF), and their number and height can vary depending on the severity and duration of the chronic inflammatory DED. They are most often seen in the temporal corner of the lower lid and may explain the irritation that often occurs in this area. They are postulated to occur due to the effect of the increased amounts of MMP-9 present in this condition, which dissolve the extracellular matrix of the conjunctiva to facilitate migration and recruitment of leukocytes to the inflamed ocular surface. The increased friction during blinking in eyes with less tears causes the loosened conjunctiva to form folds along the lid margin.^[31]

Apart from these easily performed clinical tests, confocal microscopy can be used to look for the presence of inflammatory cells, epithelial changes, and the nerve plexus in such eyes. Use of conjunctival HLA-DR expression obtained from conjunctival impression cytology has been reported, though the normal range varies widely between studies.^[32] Another advantage of impression cytology is the ability to analyze immune cells with flow cytometry.^[33] Flow cytometry on tear fluid washings detects neutrophils and natural killer cells, and a study reported a higher proportion of the former and a lower proportion of the latter in ADDE with corneal staining compared to those without staining and to controls.^[34] Similarly, the quantification of tear inflammatory cytokines may have interesting applications in DED, but one of the practical issues to overcome is the wide range of tear cytokine levels in the general population and the effect of increasing age on the normal range.^[35] These are presently used in studies.

Diagnosing disorders of the tear film and ocular surface

Tear dysfunction, an increasingly prevalent condition, causes epithelial stress, inflammation, MGD, and ocular surface damage.^[28] The ocular surface and tear function are evaluated to detect the presence of such alterations in a symptomatic patient, use the changes to diagnose specific disease entities, document the extent and grade severity of the condition, prognosticate outcomes, and monitor progress and treatment efficacy. The testing process is also performed in an asymptomatic patient if there is an underlying condition such as mixed connective disease. This is necessary as the presence of significant ocular surface changes and even paracentral corneal melting has been described in such eyes in the absence of patient symptoms.^[36] Subjective patient-reported symptoms are also assessed although they sometimes do not correlate closely with the results of the objective tests.^[37]

The test result values are used to understand the changes in the ocular surface and tear film. Stability of the tear film is indicated by the ocular protection index, defined as the ratio of the BUT to the duration of the inter-blink interval. Fluorescein staining is used to detect damage, and the location and extent

THE VICIOUS CYCLES - INTERRELATIONSHIPS

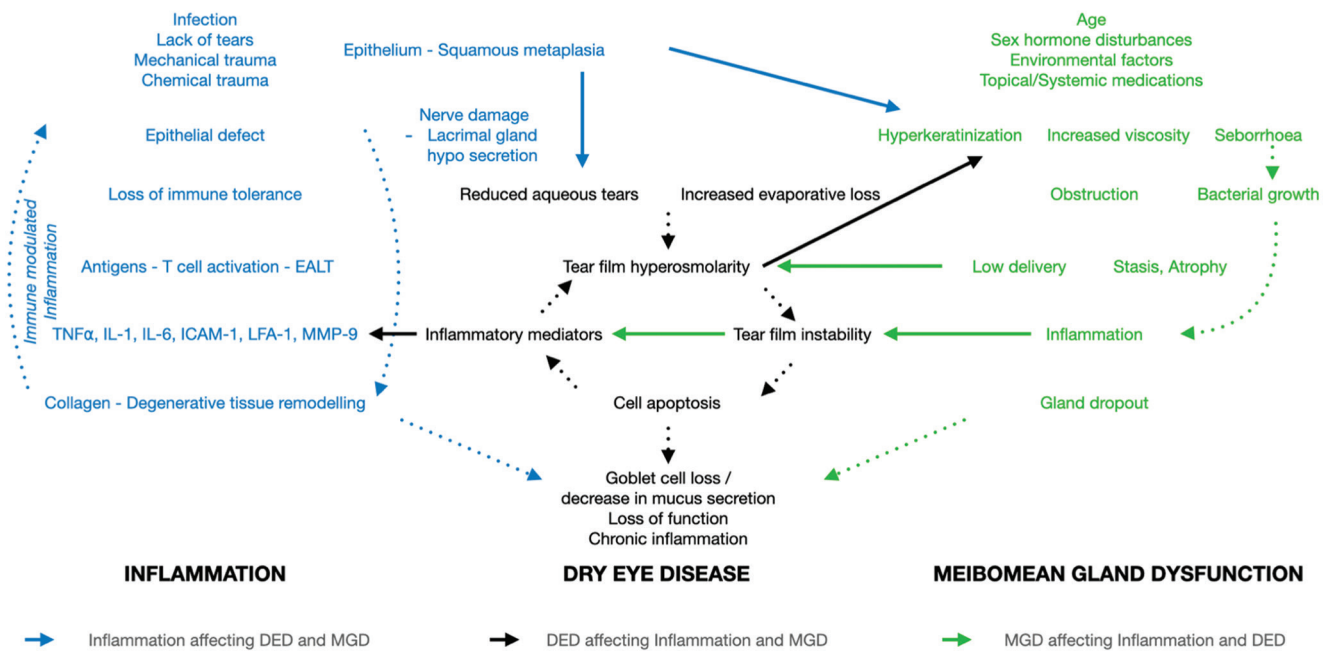


Figure 5: The inter-relationships between the vicious cycles of dry eye disease, meibomian gland dysfunction, and inflammation. All three coexist in eyes with chronic dry eye disease and tend to be self-propagating, resulting in loss of ocular surface homeostasis and damage

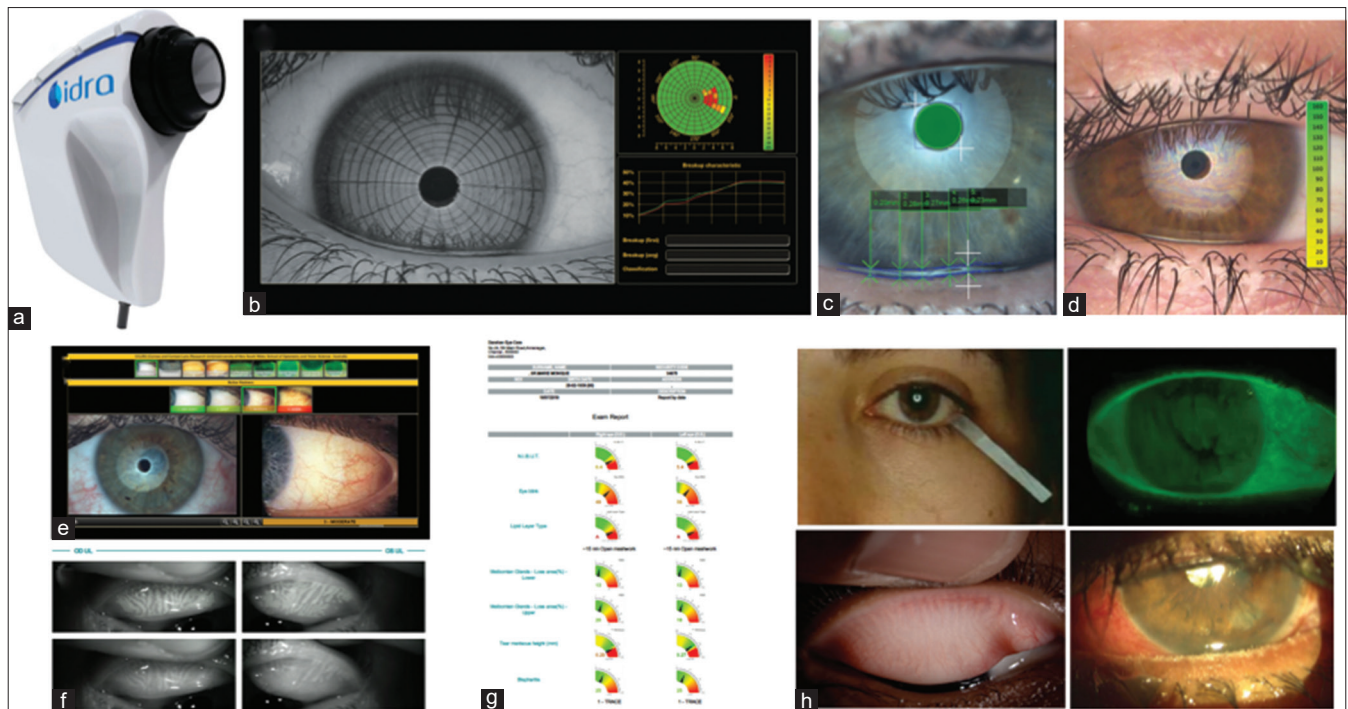


Figure 6: An example of an automated device (a) that provides measurements of non-invasive breakup time - NIBUT (b), tear meniscus height (c), lipid layer assessment (d), scales to grade ocular redness score (e), and meibography (f). These results are presented in a composite report that also includes an assessment of the extent of meibomian gland dropout (g). Clinical assessment of the same parameters is performed by using the Schirmer test, fluorescein tear breakup time (FIBUT), and slit-lamp assessment of meibomian gland architecture, secretions, and inflammation (h)

of the stain can provide clues to different disease processes. Staining of the lower third of the cornea is indicative of lid margin disease, while that in the upper third suggests upper lid changes, often allergic. Interpalpebral corneal staining sparing

the uppermost 2 mm suggests a moderate amount of dry eye, while staining of the entire corneal surface indicates very severe dry eye (with equivalent conjunctival staining) or medicamentosa (with relatively less conjunctiva staining). Staining of the superior

Table 1: Assessment of the tear breakup time, Schirmer test, and lipid layer allows detection of the type of tear film deficit. Evaluating the presence of ocular surface inflammation, extent and location of staining, and other adnexal conditions allows holistic assessment of the loss of ocular surface homeostasis, aids in proper diagnosis, and helps plan treatment

BUT	Schirmer	Lipid	Diagnosis
Normal	Normal	Normal	NORMAL
Normal	Decreased	Normal	ADDE - PRECLINICAL
Normal	Normal	Decreased	EDE - PRECLINICAL
Normal	Decreased	Decreased	ADDE + EDE - PRECLINICAL
Decreased	Decreased	Normal	ADDE
Decreased	Normal	Decreased	EDE
Decreased	Normal	Normal	SHORT BUT DE
Decreased	Decreased	Decreased	SEVERE DRY EYE – ADDE + EDE

bulbar conjunctiva in superior limbic keratoconjunctivitis, the inferior in conjunctivochalasis, medial in mucus fishing syndrome, and the temporal area in angular conjunctivitis can be noted. The upper palpebral conjunctiva can show staining in lid wiper epitheliopathy. The Marx line on the lower lid margin indicated by spotty rose bengal or fluorescein stain is located at the orifices of the meibomian glands and indicates the mucocutaneous junction. With aging and in conditions causing scarring and MGD, this line migrates anteriorly, moving closer to the outer border of the lid margin, especially along the lower temporal eyelid.^[38] Staining preferentially in the lower bulbar conjunctiva is suggestive of medication toxicity, while significant redness of the conjunctiva without concurrent staining suggests inflammation of the ocular surface.

A preferred order of manual testing would be fluorescein use for BUT, corneal staining, lissamine green for lid wiper epitheliopathy and conjunctival staining, Schirmer test, and expression tests for meibomian gland secretions. If there is an obvious lack of tears noted during slit-lamp evaluation, then topical anesthetic use is deferred, while it may be helpful to use it at the start of the evaluation process if the deficit is less obvious. Once measures of dysfunction have been obtained, then these have to be interpreted and a suggested table for the same is provided [Table 1]. Using the metrics for aqueous tear volume, mucin-related tear film stability, and lipid function, an assessment of the type of DED can be obtained. To this is added the presence and extent of inflammation and the occurrence of other disorders of the ocular surface and adnexa to allow a holistic determination of the condition of the ocular surface and tear film, which then allows the formulation of a rational strategy for management. Serial monitoring of these changes also allows determination of the success of treatment over time.

The clinical methods take more time, need a reproducible standardized technique, often involve contact tests, and are possibly less quantitative. However, they are simpler to do, cost less, and do not require the need for specialized equipment. The automated methods, although costly, are generally more time-efficient as one instrument can perform multiple evaluations, are non-contact, and provide a summary printout

of the results, which helps in documentation and discussions with the patient. The endpoints of many of the parameters that reflect a loss of ocular surface homeostasis often show a significant overlap between normal and affected eyes, and there is usually a range of values that detect dysfunction. Thus, a precise endpoint is often not the goal, for instance, in measuring the axial length of the eye, and clinical methods generally serve the purpose if access to an automated device is not available. Given the disconnect between signs and symptoms in this condition and the lack of precise endpoints, it has been suggested that a panel of tests is better for an accurate diagnosis rather than relying on one “gold standard” test [Fig. 6].

Conclusion

A thorough assessment of the ocular surface system anatomy and function can be performed using history of illness, patient symptoms, traditional clinical tests, the newly described TFOD, or by using instruments to obtain quantitative measurements. While there is currently very little data about the comparative efficiency of each of these approaches, they do provide the ophthalmologist with a choice of options. With time and experience, using these approaches concurrently can help the clinician decide about their relative importance in a clinical setting and patient population and aid in the evolution of the testing process to achieve greater efficiency and efficacy. In conclusion, this paper provides an overview of currently available techniques and their interpretation and suggests an approach that would allow general ophthalmologists to detect and grade dysfunction of the ocular surface and tear film in their clinics by using easily available tools.

Financial support and sponsorship

Nil.

Conflicts of interest

There are no conflicts of interest.

References

1. Wolff E. The muco-cutaneous junction of the lid margin and the distribution of the tear fluid. *Trans Ophthalmol Soc UK* 1946;66:291-308.
2. Yokoi N, Bron AJ, Georgiev GA. The precorneal tear film as a fluid shell: The effect of blinking and saccades on tear film distribution and dynamics. *Ocul Surf* 2014;12:252-6.
3. Tiffany JM. The normal tear film. *Dev Ophthalmol* 2008;41:1-20.
4. Research in dry eye: Report of the research Subcommittee of the International Dry Eye Workshop in: Report of the International Dry Eye Workshop (DEWS). *Ocul Surf* 2007;5:179-93.
5. Report of the International Dry Eye Workshop (DEWS). *Ocul Surf* 2007;5:67-202.
6. Braun RJ. Dynamics of the tear film. *Annu Rev Fluid Mech* 2012;44:267-7.
7. Mantelli F, Mauris J, Argüeso P. The ocular surface epithelial barrier and other mechanisms of mucosal protection. *Curr Opin Allergy Clin Immunol* 2013;13:563-8.
8. Wang J, Aquavella J, Palakru J, Chung S, Feng C. Relationships between central tear film thickness and tear menisci of the upper and lower eyelids. *Invest Ophthalmol Vis Sci* 2006;47:4349-55.
9. Mertzanis P, Abetz L, Rajagopalan K, Espindle D, Chalmers R, Snyder C, *et al.* The relative burden of dry eye in patients' lives: Comparisons to a U.S. normative sample. *Invest Ophthalmol Vis Sci* 2005;46:46-50.

10. Clayton JA. Dry eye. *N Engl J Med* 2018;378:2212-3.
11. Nichols KK, Nichols JJ, Mitchell GL. The lack of association between signs and symptoms in patients with dry eye disease. *Cornea* 2004;23:762-70.
12. Schein OD, Tielsch JM, Munõz B, Bandeen-Roche K, West S. Relation between signs and symptoms of dry eye in the elderly. A population-based perspective. *Ophthalmology* 1997;104:1395-401.
13. Galor A, Felix ER, Feuer W, Shalabi N, Martin ER, Margolis TP, *et al.* Dry eye symptoms align more closely to non-ocular conditions than to tear film parameters. *Br J Ophthalmol* 2015;99:1126-9.
14. Vehof J, Sillevius Smitt-Kamminga N, Kozareva D, Nibourg SA, Hammond CJ. Clinical characteristics of dry eye patients with chronic pain syndromes. *Am J Ophthalmol* 2016;162:59-65.
15. Vehof J, Zavos HMS, Lachance G, Hammond CJ, Williams FMK. Shared genetic factors underlie chronic pain syndromes. *Pain* 2014;155:1562-8.
16. Vehof J, Wang B, Kozareva D, Hysi PG, Snieder H, Hammond CJ. The heritability of dry eye disease in a female twin cohort. *Invest Ophthalmol Vis Sci* 2014;55:7278-83.
17. Wan KH, Chen LJ, Young AL. Depression and anxiety in dry eye disease: A systematic review and meta-analysis. *Eye (Lond)* 2016;30:1558-67.
18. Wolffsohn JS, Arita R, Chalmers R, Djalilian A, Dogru M, Dumbleton K, *et al.* TFOS DEWS II Diagnostic Methodology report. *Ocul Surf* 2017;15:539-74.
19. Tsubota K, Yokoi N, Shimazaki J, Watanabe H, Dogru M, Yamamda M, *et al.* New perspectives on dry eye definition and diagnosis: A consensus report by the Asia Dry Eye Society. *Ocul Surf* 2017;15:65-76.
20. Yokoi N, Bron A, Tiffany J, Brown N, Hsuan J, Fowler C. Reflective meniscometry: A non-invasive method to measure tear meniscus curvature. *Br J Ophthalmol* 1999;83:92-7.
21. Korb DR, Blackie CA. Meibomian gland diagnostic expressibility: Correlation with dry eye symptoms and gland location. *Cornea* 2008;27:1142-7.
22. Szalai E, Berta A, Szekanez Z, Szucs G, Modis L Jr. Evaluation of tear osmolarity in non-Sjogren and Sjogren syndrome dry eye patients with the TearLab system. *Cornea* 2012;31:867-71.
23. Koh S, Watanabe H, Hosohata J, Hori Y, Hibino S, Nishida K, *et al.* Diagnosing dry eye using a blue-free barrier filter. *Am J Ophthalmol* 2003;136:513-9.
24. Yokoi N, Georgiev GA. Tear film-oriented diagnosis and tear film-oriented therapy for dry eye based on tear film dynamics. *Invest Ophthalmol Vis Sci* 2018;59:DES13-22.
25. Yokoi N, Georgiev GA, Kato H, Komuro A, Sonomura Y, Sotozono C, *et al.* Classification of fluorescein breakup patterns: A Novel method of differential diagnosis for dry eye. *Am J Ophthalmol* 2017;180:72-85.
26. Koh S, Tung CI, Inoue Y, Jhanji V. Effects of tear film dynamics on quality of vision. *Br J Ophthalmol* 2018;102:1615-20.
27. Craig JP, Nichols KK, Akpek EK, Caffery B, Dua HS, Joo CK, *et al.* TFOS DEWS II Definition and classification report. *Ocul Surf* 2017;15:276-83.
28. Baudouin C, Messmer EM, Aragona P, Geerling G, Akova YA, Benitez-del-Castillo J, *et al.* Revisiting the vicious circle of dry eye disease: A focus on the pathophysiology of meibomian gland dysfunction. *Br J Ophthalmol* 2016;100:300-6.
29. Aragona P, Giannaccare G, Mencucci R, Rubino P, Cantera E, Rolando M. Modern approach to the treatment of dry eye, a complex multifactorial disease: A P.I.C.A.S.S.O. board review. *Br J Ophthalmol* 2021;105:446-53.
30. Yang S, Lee HJ, Kim D, Shin S, Barabino S, Chung SH. The use of conjunctival staining to measure ocular surface inflammation in patients with dry eye. *Cornea* 2019;38:698-705.
31. Meller D, Li DQ, Tseng SC. Regulation of collagenase, stromelysin and gelatinase B in human conjunctival and conjunctivochalasis fibroblasts by interleukin-1beta and tumour necrosis factor-alpha. *Invest Ophthalmol Vis Sci* 2000;41:2922-9.
32. Epstein SP, Galaria-Rathod N, Wei Y, Maguire MG, Asbell PA. HLA-DR expression as a biomarker of inflammation for multicenter clinical trials of ocular surface disease. *Exp Eye Res* 2013;111:95-104.
33. Bose T, Hou A, Lee R, Tong L, Chandy KG. A non-invasive way to isolate and phenotype cells from the conjunctiva. *J Vis Exp* 2017;5:55591.
34. Nair AP, D'Souza S, Shetty R, Ahuja P, Kundu G, Khamar P, *et al.* Altered ocular surface immune cell profile in patients with dry eye disease. *Ocul Surf* 2021;21:96-106.
35. Tong L, Wong TY, Cheng Y. Level of tear cytokines in population-level participants and correlation with clinical features. *Cytokine* 2018;110:452-8.
36. Kervick GN, Pflugfelder SC, Haimovici R, Brown H, Tozman E, Yee R. Paracentral rheumatoid corneal ulceration. Clinical features and cyclosporine therapy. *Ophthalmology* 1992;99:80-8.
37. Smith J, Nichols KK, Baldwin EK. Current patterns in the use of diagnostic tests in dry eye evaluation. *Cornea* 2008;27:656-62.
38. Yamaguchi M, Kutsuna M, Uno T, Zheng X, Kodama T, Ohashi Y. Marx Line: Fluorescein staining line on the inner lid as indicator of meibomian gland dysfunction. *Am J Ophthalmol* 2006;141:669-75.