

# Vastus lateralis flap for trochanteric sarcoma reconstruction following prior main pedicle dissection: A case report

ZAHIR T. FADEL<sup>1</sup>, AMANI J. BASAEED<sup>1</sup>, MOHAMMED B. ASHI<sup>2</sup> and HATTAN A. ALJAALY<sup>1</sup>

<sup>1</sup>Division of Plastic Surgery, Department of Surgery, Faculty of Medicine, King Abdulaziz University, Jeddah 21589, Kingdom of Saudi Arabia; <sup>2</sup>Department of Plastic and Reconstructive Surgery, National Guard Hospital, Jeddah 21423, Kingdom of Saudi Arabia

Received November 23, 2023; Accepted March 27, 2024

DOI: 10.3892/etm.2024.12537

**Abstract.** The reconstruction of trochanteric defects presents a challenge to the reconstructive surgeon. There have been a number of locoregional reconstructive options described in the literature. These include flaps based on the lateral circumflex femoral artery and its branches, such as the tensor fascia lata, vastus lateralis (VL), anterolateral thigh (ALT) flaps. The present case further complicated this challenge as the patient had multiple recurrences of a sarcoma overlying the trochanteric region, with previous surgical resections, reconstruction and radiotherapy. The present case study describes an approach to harvesting the VL flap in a patient with previously harvested ALT.

## Introduction

Reconstruction of soft tissue defects in the trochanteric area can be complex and difficult. Defects resulting from sarcoma resections in patients exposed to radiation therapy further complicate the reconstructive procedure (1). Radiotherapy suppresses wound healing by altering collagen production, rendering the microvasculature of an irradiated area weaker, fragile and compromised (2). Therefore, careful handling and meticulous care must be considered with irradiated vessels, as they are more friable and prone to damage (3). Despite the beneficial effects of radiotherapy in the management of soft tissue sarcoma, 10-25% of sarcomas recur locally (4). Treatment of the recurrence mandates additional tumor resection, radiotherapy and reconstruction.

Reconstructive options for such large three-dimensional defects include locoregional muscle, myocutaneous, or fasciot-cutaneous flaps and free flaps. Examples of locoregional options are the gluteus maximus (GM) flap, posterior gluteal

thigh flap, tensor fascia lata (TFL) flap and anterolateral thigh (ALT) flap. The vastus lateralis (VL) muscle flap is a good choice to fill the dead space with a success rate equal to that of the well-known ALT flap. It was first utilized in 1977 by Minami *et al* (5) for reconstruction of trochanteric pressure ulcers. In 1982, Bovet *et al* (6) described the VL myocutaneous flap, concluding that it has favorable results in trochanteric reconstructions. The purpose of the present report is to share our experience in harvesting the VL flap after prior harvest of the neighboring ALT flap for reconstruction of a recurrent trochanteric sarcoma. All procedures followed were in accordance with the ethical standards of the responsible committee on human experimentation (institutional and national) and with the Helsinki Declaration of 1975, as revised in 2008. Informed consent was obtained from the patient included in the study.

## Case report

**Patient.** A 54-year-old man presented with a recurrent myxofibrosarcoma involving the right greater trochanter region to King Abdulaziz University Hospital in Jeddah, Saudi Arabia. The patient had undergone multiple attempts to achieve a curative resection and reconstruction, in addition to multiple sessions of radiotherapy. The first excision was performed at another hospital in January 2012.

The patient presented to King Abdulaziz University Hospital with recurrence 10 months after that operation, in November 2012, and was admitted for work-up and multidisciplinary team (MDT) discussion. The work-up consisted of routine laboratory work, computed tomography (CT) scans, magnetic resonance imaging (MRI), bone scan and histopathological review of the tissue samples from the first excision (Figs. 1-4). The diagnosis was confirmed to be malignant fibrosarcoma. MDT consensus was to start with neo-adjuvant chemotherapy followed by surgical resection. After receiving two cycles of chemotherapy a repeated MRI revealed poor response to chemotherapy and increase in tumor size. Therefore, surgical resection was performed in February 2013. Tumor negative margin was achieved and primary closure of the wound was done followed by adjuvant radiotherapy.

In September 2016, the patient presented with cellulitis in the same area with a suspicious mass. An MRI revealed a suspicious lesion and an incisional biopsy confirmed the

---

*Correspondence to:* Dr Zahir T. Fadel, Division of Plastic Surgery, Department of Surgery, Faculty of Medicine, King Abdulaziz University, P.O. Box 80215, Jeddah 21589, Kingdom of Saudi Arabia  
E-mail: zfadel@kau.edu.sa

**Key words:** vastus lateralis, anterolateral thigh flap, reconstruction, recurrent sarcoma, trochanteric defect

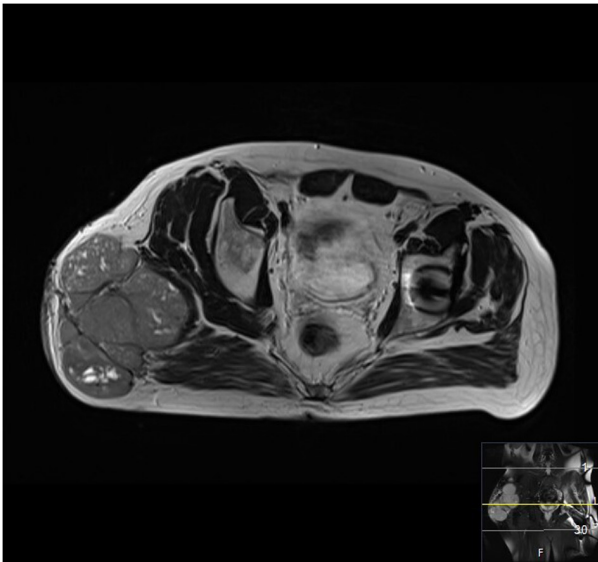


Figure 1. MRI axial view of the tumor (2012). MRI, magnetic resonance imaging.

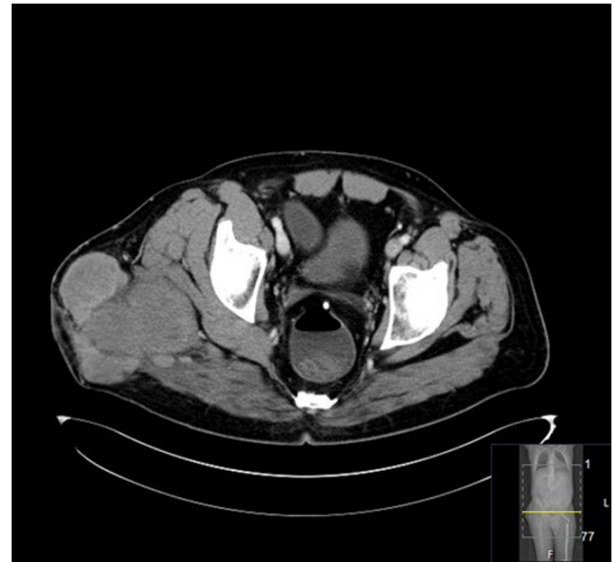

Figure 3. CT axial view of the tumor (2012). CT, computed tomography.

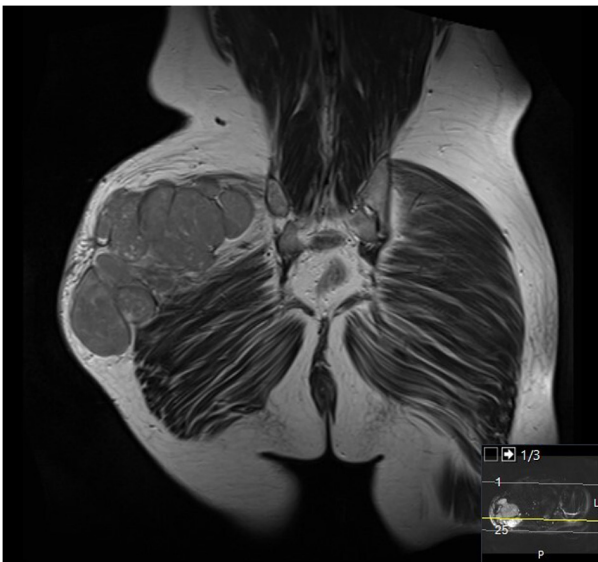

Figure 2. MRI coronal view of the tumor (2012). MRI, magnetic resonance imaging.

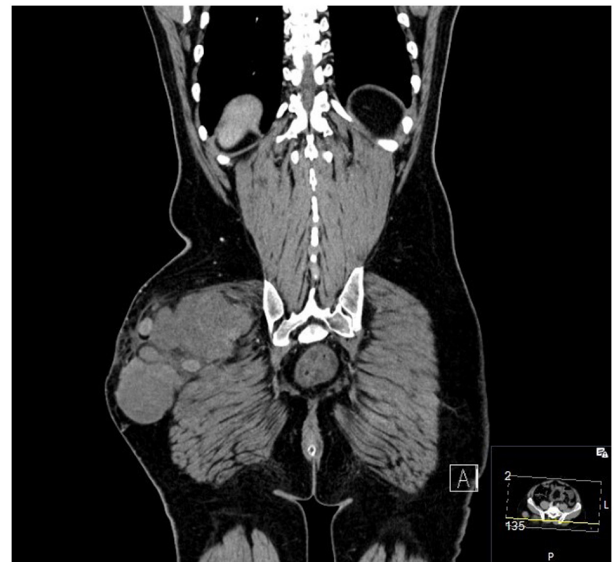

Figure 4. CT coronal view of the tumor (2012). CT, computed tomography.

second recurrence. Metastatic work-up was negative for distant metastasis. In October 2016, the patient underwent resection and reconstruction with a pedicled ALT flap. Following the excision, the patient was reviewed by medical and radiation oncology and it was determined that there was no need for adjuvant therapy at this stage.

In April 2018, a follow-up MRI revealed a new lesion in the same area. The third recurrence was confirmed with an ultrasound-guided biopsy. A MDT meeting concluded that there would be no benefit from chemotherapy as the tumor was chemo-resistant. Therefore, the surgical team proceeded with the resection in July 2018. The excision included removal of the previous ALT flap and final pathology revealed negative margins. This resection was complicated by an injury to the sciatic nerve, which required surgical repair and prolonged

post-operative rehabilitation. The wound was initially managed by negative pressure wound therapy (NPWT) dressings followed by skin grafting.

At two years later, a fourth recurrence was identified on follow-up assessment. An MRI and CT scan performed in September 2020 showed a mass measuring 8.5x4x5 cm over the greater trochanter extending to the fascia, with no abnormal signal in the muscle or bone and no regional lymphadenopathy (Figs. 5-7). Metastatic work-up remained negative. Following the MDT recommendation, the patient received 25 sessions of neo adjuvant radiotherapy. The fifth excision was performed in April 2021. This resulted in a large trochanteric defect of 15x10 cm surrounded by poor quality irradiated skin (Fig. 8). The final pathology confirmed complete resection of a high-grade myxofibrosarcoma with negative margins. The wound was initially managed by

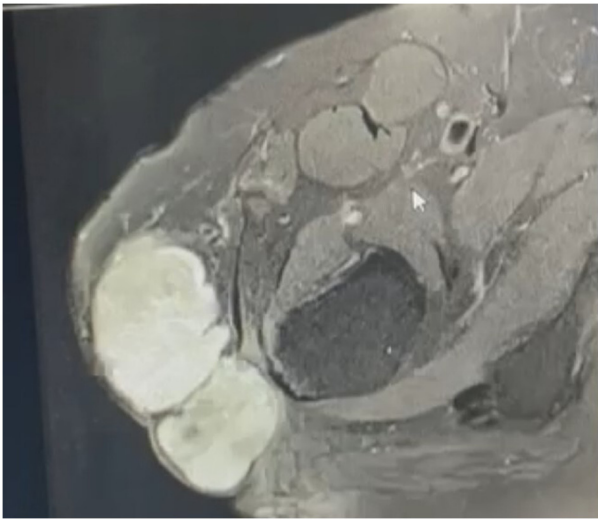


Figure 5. MRI axial view of the tumor (2020). MRI, magnetic resonance imaging.

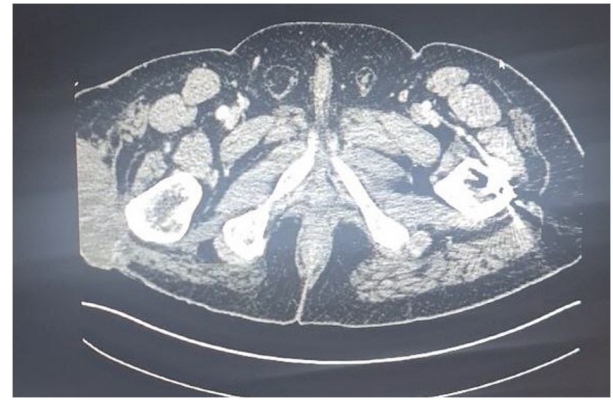

Figure 7. CT axial view of the tumor (2020). CT, computed tomography.

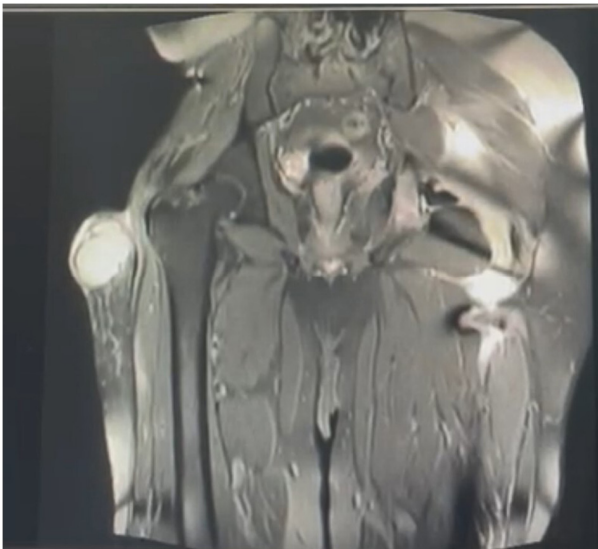


Figure 6. MRI coronal view of the tumor (2020). MRI, magnetic resonance imaging.

NPWT and reconstruction with the VL muscle flap was planned for coverage of the defect.

**Flap harvest.** Following a complete resection with clear margins, the VL muscle was partially exposed within the floor of the defect. The incision was extended distally to assess the quality and perfusion of the muscle. Multiple patent muscular branches were identified in the medial and deep parts of the muscle. The VL muscle flap was carefully divided from the tendonous insertion distally, 10 cm proximal to the patella. The quadriceps tendon was preserved to reduce the risk of patellar instability. The minor pedicle originating from the lateral superior genicular artery was ligated distally. The flap was elevated distal to proximal (Fig. 9). The vascularity to the VL was well maintained, despite the need to sacrifice a few branches entering the distal half of the muscle. The VL flap was turned over into the defect, while preserving the proximal

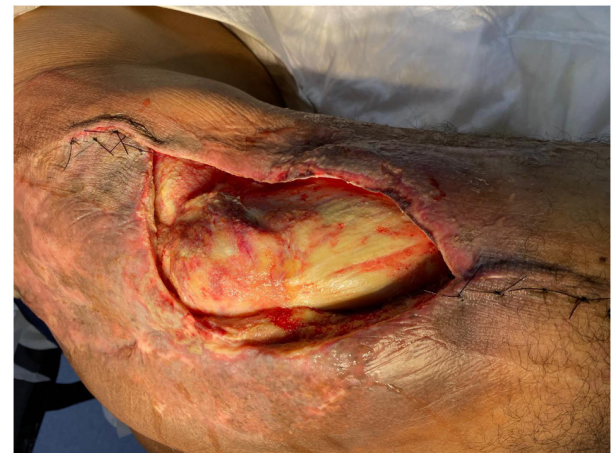

Figure 8. Preoperative picture of the defect in the trochanter area.

vascular supply. The flap rested easily with no tension over the defect and covered the exposed trochanteric bone (Fig. 10). The donor site was closed primarily. A meshed partial thickness skin graft was placed over the flap (Fig. 11) and NPWT dressing was applied.

Successful flap survival was achieved with favorable skin graft take (Fig. 12). The wound progressed towards complete healing. The patient recovered and was discharged from the hospital in June 2021. The patient required physiotherapy and eventually returned to their baseline health status. Follow-up MRI scan revealing no signs of tumor recurrence (July 2021). At the last reported follow-up, three years post-procedure, the patient remained disease-free (Fig. 13).

**Anatomy.** The VL muscle flap is classified as type I Mathes and Nahai based on its vascular supply (7). It can be utilized as a muscle or musculocutaneous flap and it has a skin paddle similar to that of the ALT flap. The main pedicle of the VL arises from the lateral circumflex femoral artery (LCFA), a large branch of the deep femoral artery. It trifurcates to the ascending, transverse and descending branches. The main pedicle of the VL is the descending branch of the lateral circumflex femoral artery (d-LCFA) and vein. The ALT flap similarly depends on the d-LCFA as its main vascular supply, mainly through its perforators (8). Anatomical variations

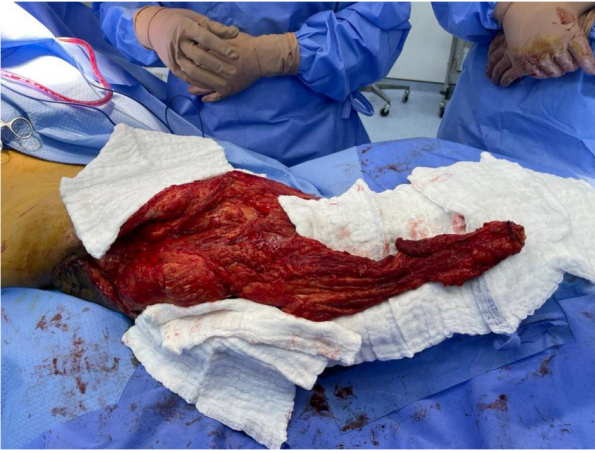

Figure 9. Dissected vastus lateralis flap.

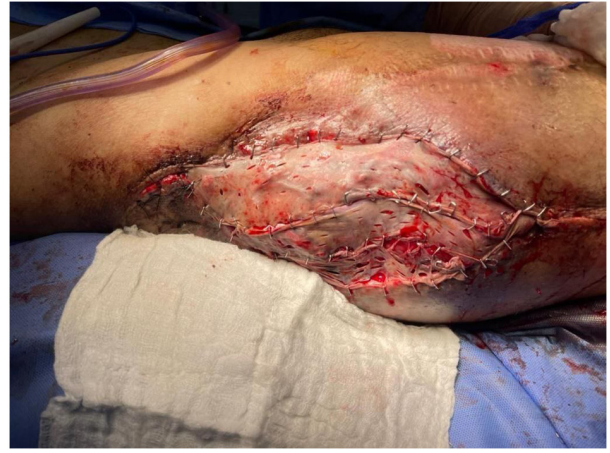

Figure 11. Coverage of the defect with the vastus lateralis flap and skin graft.

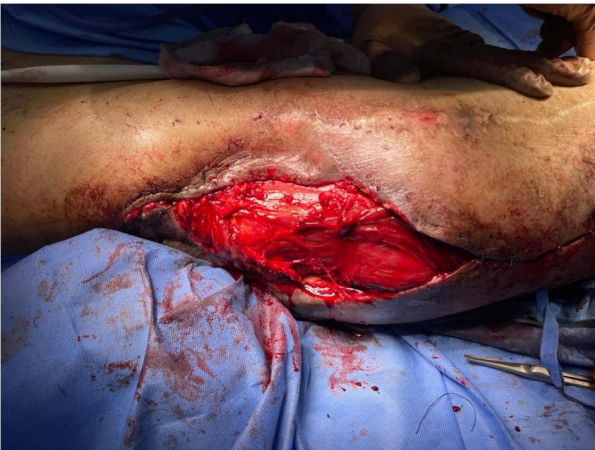

Figure 10. Vastus lateralis flap inset into the defect.

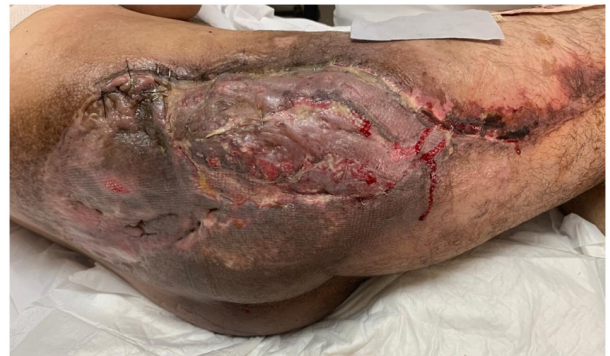

Figure 12. Affected area at the 2-week follow-up illustrating vastus lateralis flap and skin graft covering the trochanteric defect.

are not rare in this sequence; in up to 44% of anatomical cases, there is an oblique branch arising commonly from the d-LCFA, which serves as the dominant perforator of the ALT flap when present (9). The d-LCFA runs in the intermuscular septum between the rectus femoris and the VL for a variable distance before entering the substance of the VL (10). The vessel diameter is >2 mm, with a pedicle length ranging between 8-16 cm (10). Proximally, the d-LCFA gives off a large branch to the rectus femoris muscle, known as the rectus femoris branch (8,11). The VL muscle is innervated through segmental muscular branches of the femoral nerve (12).

## Discussion

Myxofibrosarcomas are among the most common soft tissue sarcomas (STS) presenting in extremities. It has a predilection towards the lower extremity with usual presentation in males between 60-80 years of age. Management of such tumors always involves a multidisciplinary team and treatment options include surgical resection, radiation and chemotherapy (13). Localized lesions are best managed by wide surgical resection with a goal of free margins. Radiotherapy and chemotherapy have limited roles and their benefit has been debated. Some

have even labeled such tumors as radioresistant; however, this has been argued as the indication for radiotherapy is more advanced cases and not due to the modality itself. Chemotherapy mainly plays a role in metastatic disease and has poor outcomes. They demonstrate high recurrence rates compared to other STS, ranging from 20-60% (13). The best form of surveillance is by clinical examination and MRI. To this day local control, which was the main oncologic treatment goal of the present case, is mainly achieved by adequate surgical resection in both margin width and anatomic barrier with adjuvant radiotherapy (13).

Reconstruction of soft tissue defects over the greater trochanter is challenging, as this is a known pressure point and an area of bony projection. The present case was further complicated by multiple resections, radiotherapy, previous dissection of the main vascular pedicle in the region and limitations in recipient vessels for free tissue transfer. All these factors adversely affected the local microvascular network and limited the locoregional reconstructive options. Upon completion of resection with clear margins, VL was adjacent to the defect and appeared to be the only available regional option to attempt reconstruction. The VL is an optimal muscle flap with a reliable vascular pedicle and a wide arc of rotation with minimal donor site morbidity (14). The present case was a case of VL harvest following previous pedicled ALT flap reconstruction in the same area, both of which share a common vascular pedicle.

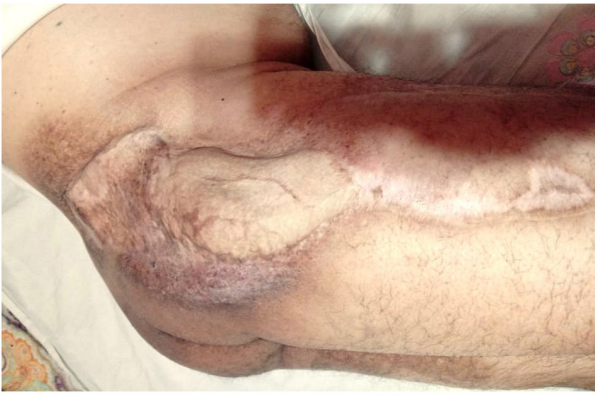

Figure 13. Affected area at the 3-year follow-up showing complete healing of the trochanteric defect with the vastus lateralis flap and no signs of local tumor recurrence.

Harvesting the VL flap for reconstruction of this trochanteric defect allows for immediate reconstruction with a locoregional option. This minimizes recovery time and number of operations needed to resume function. Flap reconstruction of resected soft tissue sarcoma allows for complete recovery with superior functional outcomes compared to amputation (15). Moreover, immediate reconstruction has resulted in decreased wound complications compared to delayed or interval reconstruction (15).

Theoretically, harvesting the VL for reconstruction is challenging due to prior utilization of the ALT flap and dissection of the main shared pedicle, especially in an irradiated bed. These alterations affect the muscle volume and the vasculature, rendering it unpredictable and threatening the success of the reconstruction plan. Intraoperatively, the VL segment was well perfused and deemed viable to be utilized as a pedicled flap. The minor perforators were pulsating and adequately perfusing the flap. A restrictive approach to elevate the minimal required length of the muscle was considered to preserve deep proximal vascular branches as much as possible. Following the inset of the flap over the defect, adequate muscle perfusion was examined by color and healthy bleeding, with no signs of venous congestion. If the VL muscle did not appear well vascularized on exploration, the backup options were either to perform a delayed extended groin flap or to create an arteriovenous (AV) loop in preparation for free tissue transfer.

The VL flap is conventionally classified as Mathes and Nahai type I. However, Toia *et al* (12) have delineated three distinct partitions within the VL muscle, each with its unique blood supply: The superficial partition is supplied by the d-LCFA, the intermediate partition by the transverse branch of the same artery and the deep partition by perforating branches of the deep femoral artery and the deep branch of the superior lateral genicular artery (12). In the present case, multiple perforating branches were observed from both the middle and deep partitions that were adequate and sufficient to supply the flap.

Reconstructive procedures, especially in such situations, require careful planning. Larger defects also limit the choices of the surgeons; either to utilize regional flaps or free flaps. In one case dealing with a large trochanteric and gluteal

defect (25x15 cm) as a result of sarcoma resection, the ALT was utilized as a pedicled local flap and a recipient as a flow through donor vessel, via the d-LCFA, for a free flap from the contralateral ALT (1). In comparison, the present defect was much smaller and the neighboring ALT along with its pedicle had already been harvested and subsequently excised due to tumor recurrence; therefore, such an option was not available. However, combining flaps is a useful technique for providing coverage of large defects.

Latissimus dorsi (LD) myocutaneous flap is a viable alternative in the management of recurrent soft tissue sarcoma (1,2). The LD flap offers coverage for large defects and aids in restoring function to the affected limb. It serves as a workhorse free flap option, offering adequate volume to eliminate dead space and provides healthy well-vascularized tissue from areas unaffected by radiation. However, due to the complexity of the present case, a staged procedure would have been necessary, involving the formation of an AV-loop followed by free tissue transfer. Therefore, the drawbacks of pursuing such an option include the necessity for a staged procedure, the need for microsurgical expertise, a remote donor site, repositioning during surgery and potential morbidity associated with LD harvest (16,17). Whereas a number of these drawbacks are not encountered with a locoregional option such as the VL flap, it has also been reported to have minimal donor site morbidity (14).

The superior posterior femoral fasciocutaneous flap has been described in the reconstruction of greater trochanter defects post resection of a recurrent malignant fibrous histiocytoma involving soft tissue of the hip (18). In that case, the tumor extended into the lateral GM and the TFL muscle. To achieve a free margin part of the VL and Sartorius were resected, resulting in a large defect. Similar to the present case, this defect underwent excessive dissection, alongside complete resection of the TFL.

The GM flap has been reported in reconstruction of trochanteric pressure sores as an advancement flap, with the advantage of providing adequate muscle bulk and neighboring the defect, allowing for a smaller donor site that can be closed primarily with minor tension when an oblique design is used (19). However, GM is unfavorable in mobile patients. Due to the major functional deficit at the donor site, this flap is usually preserved for paraplegic subjects (19). In the present case, the patient was mobile; therefore, the GM flap was not a preferred option.

The most common defects in the trochanteric region are due to pressure sores. As in the case of the defect described in the present report they are large and often extensive. Classically the TFL flap has been utilized in reconstruction of trochanteric pressure ulcers. However, larger and more complex defects carry a high risk of complications, donor site morbidity and flap failure. The VL is an alternative option with good outcomes.

This case study is subject to inherent limitations, notably its nature as a single-case study, which may not fully capture the diversity of outcomes in similar clinical scenarios. Additionally, the retrospective review of data encountered challenges at the time of reporting due to missing information. Despite these obstacles, the application of the VL flap in such a complex case highlights its significant potential.

Demonstrating both robustness and adaptability, the VL flap proves to be a reliable option, emphasizing its utility in the reconstruction of trochanteric defects.

The VL is recognized for its versatility as a muscle flap across a range of applications. Its reliability is evident even in challenging situations in which the area has been subjected to multiple surgical interventions, radiation and a prior ALT flap harvest. With its rich vascularity and multifaceted utility, the VL is an indispensable tool in the armamentarium of every reconstructive surgeon.

### Acknowledgements

Not applicable.

### Funding

No funding was received.

### Availability of data and materials

The data generated in the present study are included in the figures and/or tables of this article.

### Authors' contributions

ZF was the main surgeon performing the reconstructive procedure in this report, as well as the senior author responsible for writing the paper and reviewing it for oversights; ZF also provided a comprehensive revision of the manuscript. AB contributed to the literature review, manuscript development, format, review, drafting, data collection and design of the manuscript. MA was a co-author who provided a comprehensive revision of the manuscript structure, format and content. MA participated in the design of the study, data collection and interpretation and discussion. HA was a senior co-author who provided the details of the case management course and helped in manuscript development. ZF and MA confirm the authenticity of all the raw data. All authors read and approved the final manuscript.

### Ethics approval and consent to participate

All procedures followed were in accordance with the ethical standards of the responsible committee on human experimentation (institutional and national) and with the Helsinki Declaration of 1975, as revised in 2008. Informed written consent was obtained from the patient included in the present study.

### Patient consent for publication

Informed written consent for publication was obtained from the patient included in the present study.

### Competing interests

The authors declare that they have no competing interests.

### References

1. Haque SA, Georgiou A and Woollard A: Pedicled ipsilateral anterolateral thigh (ALT) with flow-through to a secondary contralateral-free ALT flap for coverage of large thigh, trochanteric and gluteal area defects: A case report. *Microsurgery* 41: 276-279, 2021.
2. Hohenberger P and Schwarzbach MH: Management of locally recurrent soft tissue sarcoma after prior surgery and radiation therapy. *Recent Results Cancer Res* 179: 271-283, 2009.
3. Mulholland S, Boyd JB, McCabe S, Gullane P, Rotstein L, Brown D and Yoo J: Recipient vessels in head and neck microsurgery: Radiation effect and vessel access. *Plast Reconstr Surg* 92: 628-632, 1993.
4. Ballo MT, Zagars GK, Pollock RE, Benjamin RS, Feig BW, Cormier JN, Hunt KK, Patel SR, Trent JC, Beddar S and Pisters PW: Retroperitoneal soft tissue sarcoma: An analysis of radiation and surgical treatment. *Int J Radiat Oncol Biol Phys* 67: 158-163, 2007.
5. Minami RT, Hentz VR and Vistnes LM: Use of vastus lateralis muscle flap for repair of trochanteric pressure sores. *Plast Reconstr Surg* 60: 364-368, 1977.
6. Bovet JL, Nassif TM, Guimberteau JC and Baudet J: The vastus lateralis musculocutaneous flap in the repair of trochanteric pressure sores: Technique and indications. *Plast Reconstr Surg* 69: 830-834, 1982.
7. Mathes SJ and Nahai F: Classification of the vascular anatomy of muscles: Experimental and clinical correlation. *Plast Reconstr Surg* 67: 177-187, 1981.
8. Wong CH and Wei FC: Anterolateral thigh flap. *Head Neck* 32: 529-540, 2010.
9. Wong CH, Ong YS and Wei FC: Revisiting vascular supply of the rectus femoris and its relevance in the harvest of the anterolateral thigh flap. *Ann Plast Surg* 71: 586-590, 2013.
10. Wei FC, Jain V, Celik N, Chen HC, Chuang DC and Lin CH: Have we found an ideal soft-tissue flap? An experience with 672 anterolateral thigh flaps. *Plast Reconstr Surg* 109: 2219-2226; discussion 2227-30, 2002.
11. Mathes SJ and Nahai F: *Reconstructive surgery: Principles, Anatomy and Technique 2-Volume Set. Vol 2. 1st edition.* Churchill Livingstone, London. pp1233-1246, 1997.
12. Toia F, D'Arpa S, Brenner E, Melloni C, Moschella F and Cordova A: Segmental anatomy of the vastus lateralis: Guidelines for muscle-sparing flap harvest. *Plast Reconstr Surg* 135: 185e-98e, 2015.
13. Vanni S, De Vita A, Gurrieri L, Fausti V, Miserocchi G, Spadazzi C, Liverani C, Cocchi C, Calabrese C, Bongiovanni A, *et al*: Myxofibrosarcoma landscape: Diagnostic pitfalls, clinical management and future perspectives. *Ther Adv Med Oncol* 14: 17588359221093973, 2022.
14. Rodaix C, Auregan JC, Lhuaiere M, Feydy A, Soubeyrand M and Biau D: The proximal vastus lateralis flap: An anatomical and radiological study. *Morphologie* 106: 75-79, 2022.
15. Stranix JT, Lee ZH, Lam G, Mirror J, Rapp T and Saadeh PB: Limb-sparing sarcoma reconstruction with functional composite thigh flaps. *Microsurgery* 38: 466-472, 2018.
16. Kim J, Lee H, Pyon JK, Mun GH, Bang SI, Jeon BJ and Lee KT: Association of unilateral latissimus dorsi muscle harvest for breast reconstruction with postoperative spinal posture. *Plast Reconstr Surg* 150: 644e-654e, 2022.
17. Oberhofer HM, Samant SS, Swan CC, Wolfe EM, Satteson ES, Leyngold MM and Chim H: Objective comparison of donor-site morbidity following full and thoracodorsal nerve-preserving split latissimus dorsi flaps. *Plast Reconstr Surg* 149: 966e-971e, 2022.
18. Zhang R, Sun J, Wei X, Zhang H, Liu Y, Shi M and Shi Y: Reconstruction of defects with the posterior femoral fasciocutaneous flap after resection of malignant tumours of the femoral greater trochanter, sacrococcygeal region and knee. *J Plast Reconstr Aesthet Surg* 62: 221-229, 2009.
19. Nisanci M, Sahin I, Eski M and Alhan D: A new flap alternative for trochanteric pressure sore coverage: Distal gluteus maximus musculocutaneous advancement flap. *Ann Plast Surg* 74: 214-219, 2015.



Copyright © 2024 Fadel et al. This work is licensed under a Creative Commons Attribution-NonCommercial-NoDerivatives 4.0 International (CC BY-NC-ND 4.0) License.