

Colovaginal fistula closure using a cardiac septal defect occluder

Omar Sadiq, MD,¹ Stephen Simmer, MD,¹ Andrew Watson, MD,¹ Marvin Eng, MD,² Tiberio Frisoli, MD,² Tobias Zuchelli, MD¹



INTRODUCTION

Gastrointestinal fistulas can be challenging to manage endoscopically. Fistulas can occur as a result of malignancy, inflammatory conditions, postoperative states, endoscopic interventions, or radiation therapy.¹ Various endoscopic techniques have been used because of high rates of morbidity and mortality associated with fistula formation. However, these endoscopic therapies offer varying ranges of clinical success.

The endoscopic therapy used for fistula closure generally depends on the size, shape, and location of the defect and the health of surrounding tissue. Fully covered self-expanding metal stents can result in high rates of clinical success²; however, treatment can require multiple procedures, be complicated by stent migration, and is used primarily in the esophagus. Endoscopic clipping and suturing can yield excellent initial results; however, successful closure rates can vary, especially when treating chronic fistulas. Endoscopic vacuum therapy offers promising results in certain cases, but it requires multiple procedures to achieve clinical success. New modalities continue to develop because of the wide range of successful fistula closure seen with standard endoscopic approaches. The use of cardiac septal defect occluders (CSDOs) to close GI fistulas has recently been explored with clinical success. These devices are available in various sizes (Fig. 1). The devices are made of material that is self-expanding and, when activated, result in tissue ingrowth and device occlusion.³

CASE REPORT

We present the case of a 70-year-old woman who developed a colovaginal fistula after debulking surgery for stage 3 ovarian carcinoma. The patient wanted to avoid further surgeries, and initial endoscopic management with stent placement was unsuccessful because of stent migration. Closure with an over-the-scope clip was initially successful but it subsequently became dislodged, and endoscopic suturing could not be performed due to an angulation in the colon at the site of the fistula. After a multidisciplinary discussion, the patient decided to pursue off-label fistula




Figure 1. Cardiac septal defect occluder device under manual traction. The device is an asymmetrical double-disk device with a short waist. The elastic properties of the device can be appreciated under traction.

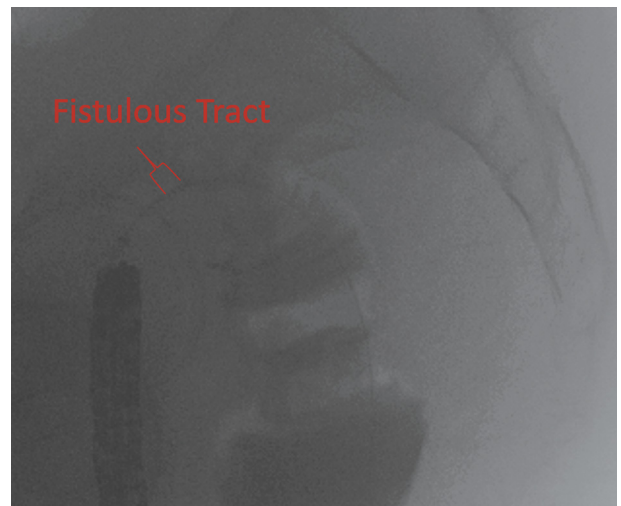


Figure 2. Fluoroscopic imaging demonstrating guidewire crossing the fistulous tract.

closure with a CSDO. We describe the successful placement of a CSDO across a colovaginal fistula with resultant symptom alleviation (Video 1, available online at www.VideoGIE.org).

The fistula was found in the colonic and vaginal lumens using a standard gastroscope, and a wire was advanced

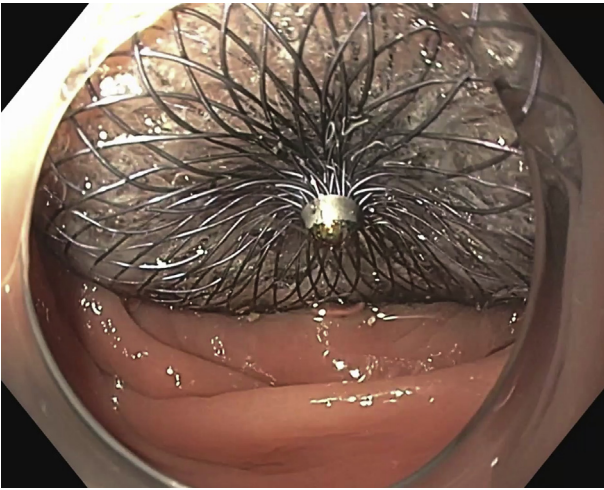


Figure 3. Distal aspect of the cardiac septal defect occluder during deployment in the colon. Minor dimpling is present in the disk to maintain positioning while the proximal aspect is deployed within the vagina.

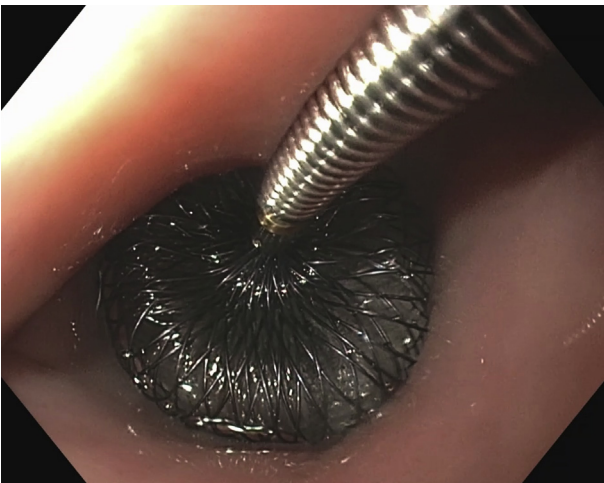


Figure 4. Proximal view of the cardiac septal defect occluder during deployment within the vagina. The deployment cable is disconnected from the device using a counterclockwise rotation after positioning is confirmed endoscopically and fluoroscopically.

through the vaginal opening into the colon under endoscopic and fluoroscopic guidance (Fig. 2). Contrast was injected to map the fistula and to aid in selecting the appropriately sized CSDO. The fistulous tract was found to be <1 cm in length. The dilator and delivery sheath was then advanced over the guidewire through the vagina and across the fistulous tract into the colon under endoscopic visualization. The dilator and guidewire were removed, and the loading device was advanced into the delivery sheath. The distal aspect of the CSDO was deployed into the colon by using the delivery cable (Fig. 3), and then under endoscopic visualization the vaginal aspect was deployed (Fig. 4). After placement was complete (Fig. 5), the

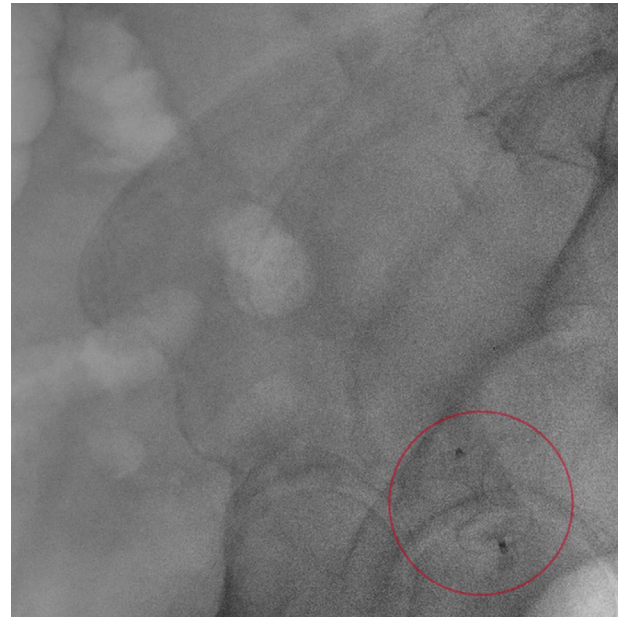

Figure 5. Fluoroscopic confirmation of the cardiac septal defect occluder's positioning across the colovaginal fistula.

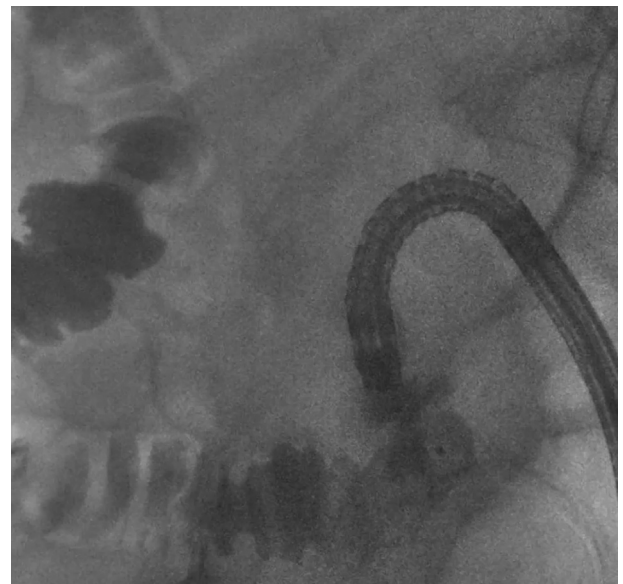

Figure 6. Dilute contrast is used to confirm no further leakage and adequate sizing of the cardiac septal defect occluder.

patient's blood was used to activate the CSDO to induce thrombosis and epithelialization, and contrast was injected in the colon without evidence of a leak into the vagina (Fig. 6). A few weeks after placement, the CSDO became dislodged and a larger CSDO (Amplatzer 24×34×38; AGA Medical Corporation, Golden Valley, Minn, USA) was placed. Direct endoscopic visualization, from the colonic and vaginal lumens, confirmed that the CSDO was

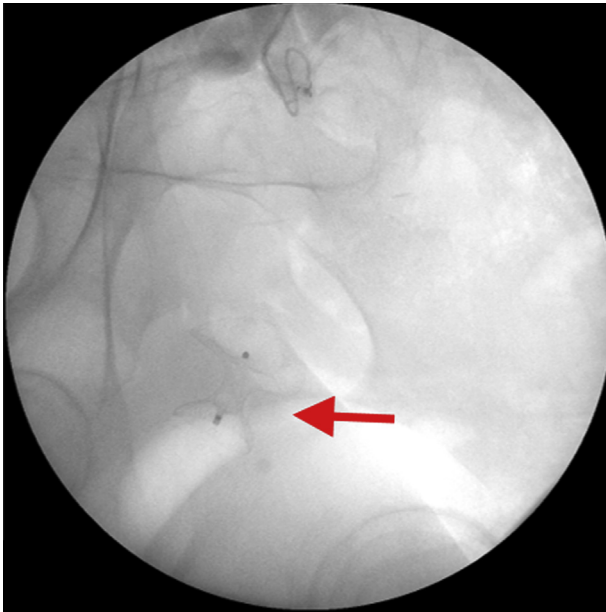


Figure 7. Final fluoroscopic image highlighting the positioning of the cardiac septal defect occluder across the fistulous tract.

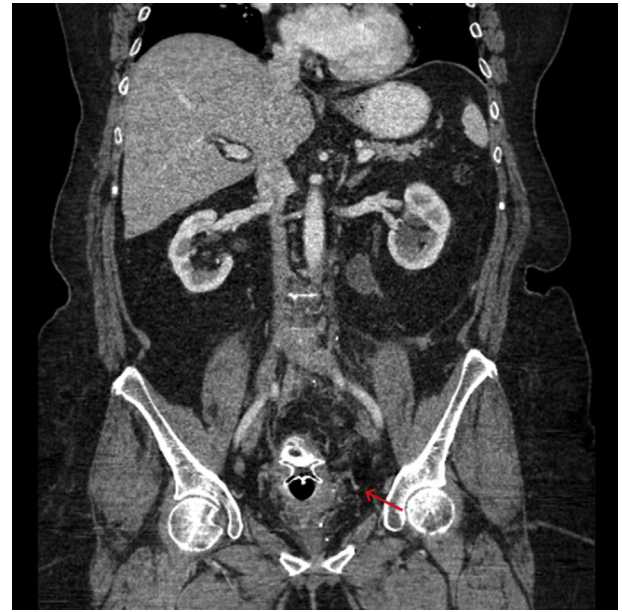


Figure 8. Follow-up CT image demonstrating the positioning of the cardiac septal defect occluder.

traversing the fistula with 1 wing fully deployed in the colon and the other in the vagina. Figures 7 and 8 highlight the positioning of the CSDO traversing the fistula on subsequent evaluation. The patient was symptom free at the 6-month follow-up.

CONCLUSION

This case demonstrates the first successful use of a CSDO for the treatment of a colovaginal fistula. This technique can be considered for refractory, chronic fistulae in patients for whom surgical management is either not possible or preferred, and when traditional endoscopic techniques have failed. Placement appears to be safe and efficacious; however, further investigation is needed to delineate its place within the current endoscopic armamentarium.

DISCLOSURE

Dr Zuchelli is a consultant for Boston Scientific. Dr Eng is a clinical proctor for Boston Scientific, Medtronic, and Edwards Lifesciences. Dr Frisoli is a clinical proctor for Abbott,

Edwards Lifesciences, Boston Scientific, and Medtronic. All other authors disclosed no financial relationships.

Abbreviation: CSDO, cardiac septal defect occluder.

REFERENCES

1. Cho J, Sahakian AB. Endoscopic closure of gastrointestinal fistulae and leaks. *Gastrointest Endosc Clin N Am* 2018;28:233-49.
2. El Hajj II, Imperiale TF, Rex DK, et al. Treatment of esophageal leaks, fistulae, and perforations with temporary stents: evaluation of efficacy, adverse events, and factors associated with successful outcomes. *Gastrointest Endosc* 2014;79:589-98.
3. De Moura DTH, Baptista A, Jirapinyo P, et al. Role of cardiac septal occluders in the treatment of gastrointestinal fistulas: a systematic review. *Clin Endosc* 2020;53:37-48.

Division of Gastroenterology, Henry Ford Hospital, Detroit, Michigan (1), Division of Cardiology, Henry Ford Hospital, Detroit, Michigan (2).

If you would like to chat with an author of this article, you may contact Dr Sadiq at osadiq1@hfhs.org or Dr Zuchelli at tzuchel1@hfhs.org.

Copyright © 2020 American Society for Gastrointestinal Endoscopy. Published by Elsevier Inc. This is an open access article under the CC BY-NC-ND license (<http://creativecommons.org/licenses/by-nc-nd/4.0/>).

<https://doi.org/10.1016/j.vgje.2020.09.001>