

# Combined Gluteus and Pudendal Thigh Flap Reconstruction of Vaginal Defects following Robotic Abdominoperineal Resection

Kassandra R. Dassoulas, MD\*  
Traci L. Hedrick, MD, FACS†  
Chris A. Campbell, MD, FACS\*

**Summary:** Low-lying rectal cancers are being treated more frequently with robotic-assisted abdominoperineal resection, obviating the need for laparotomy and the ability to raise vertical rectus abdominis musculocutaneous flaps. For female patients, posterior vaginectomy often accompanies the resection. Combined pudendal thigh flaps as an extension of bilateral gluteus advancement flaps allow for posterior vaginal resurfacing with thin pliable fasciocutaneous flaps, which rest on the gluteal flap soft-tissue bulk that obliterates the pelvic dead space. For patients with advanced cancers who have had neoadjuvant chemoradiation, the pudendal skin paddle can be planned more laterally to bring in healthier medial thigh skin. The donor incisions lie within the gluteal cleft and crease and groin creases recapitulating normal perineal anatomy and aesthetics. (*Plast Reconstr Surg Glob Open* 2017;5:e1500; doi: 10.1097/GOX.0000000000001500; Published online 19 September 2017.)

## INTRODUCTION

Standard treatment for low-lying rectal adenocarcinoma is proctectomy, which is preceded by chemoradiation in more advanced cases.<sup>1,2</sup> Patients with tumors extending beyond the dentate line involving the sphincter complex require abdominoperineal resection (APR). It is not uncommon for rectal cancers to extend beyond the confines of the rectum to the vagina or prostate, requiring multivisceral resection for cure.<sup>3,4</sup> This leaves a wide defect in the levator complex and a large perineal defect. This procedure is associated with significant morbidity related to complications of the perineal wound.<sup>5</sup>

Musculocutaneous flap reconstruction of the perineum has been shown to decrease wound healing complications in this setting where significant pelvic dead space must be obliterated and perineal resurfacing performed simultaneously.<sup>6</sup> The vertical rectus abdominis musculocutaneous (VRAM) flap is the workhorse flap for reconstruction of these complex pelvic defects by providing the necessary bulk for dead space obliteration, skin, and soft tissue for

pelvic and vaginal resurfacing and is harvested through a standard laparotomy performed for open APR. Additionally, the VRAM has been shown to have fewer wound healing complications when compared with thigh-based flaps and other alternatives requiring a second donor-site incision.<sup>7</sup>

Minimally invasive methods of APR including laparoscopic and robotic techniques are gaining popularity. Although the minimally invasive approach spares patients from large abdominal incisions, the patients still have the same perineal defects and intraabdominal dead space as with the standard open approach without the ability to harvest the abdominally based VRAM through the extirpative incision.

Pelvic dead space management after robotic APR has been described with simultaneous robotic harvest of a rectus abdominis muscle flap.<sup>8</sup> Resurfacing of the perineum has been described with bilateral gluteal advancement flaps without requiring a midline laparotomy for harvest.<sup>9,10</sup> However, neither option provides additional skin to resurface the vagina when partial or total vaginectomy is combined with robotic APR.

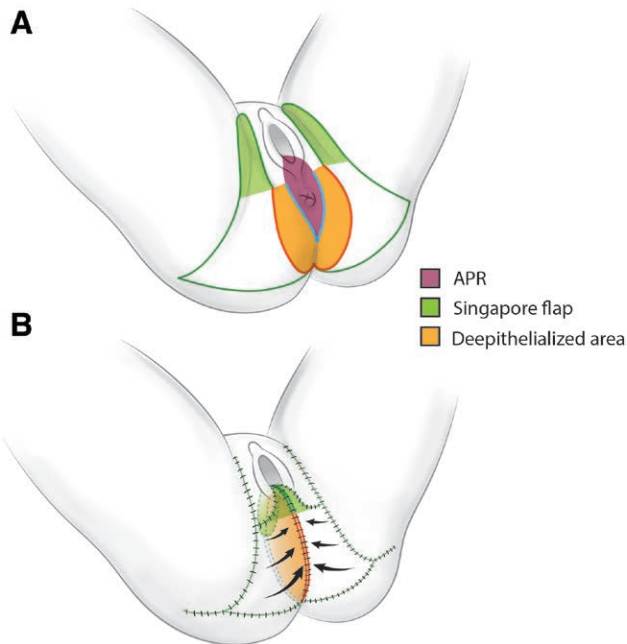
The addition of thin pliable fasciocutaneous pudendal thigh flaps provides posterior vaginal resurfacing<sup>11</sup> and can be harvested in conjunction with gluteus advancement. The elevation of the pudendal flap with the skin paddle of the gluteus flap changes the pudendal flap from an interposition flap to an advancement flap that is inset onto the deepithelialized bulk of the medial gluteus flap (Fig. 1). The medial portion of the gluteus flaps are deepithelialized and folded onto themselves to obliterate the

From the \*Department of Plastic and Reconstructive Surgery, University of Virginia Health System, Charlottesville, Va.; and †Division of Surgical Oncology, Department of General Surgery, University of Virginia Health System, Charlottesville, Va.

Received for publication July 11, 2017; accepted July 26, 2017.

Copyright © 2017 The Authors. Published by Wolters Kluwer Health, Inc. on behalf of The American Society of Plastic Surgeons. This is an open-access article distributed under the terms of the Creative Commons Attribution-Non Commercial-No Derivatives License 4.0 (CCBY-NC-ND), where it is permissible to download and share the work provided it is properly cited. The work cannot be changed in any way or used commercially without permission from the journal. DOI: 10.1097/GOX.0000000000001500

**Disclosure:** The authors have no financial interest to declare in relation to the content of this article. The Article Processing Charge was paid for by the authors.



**Fig. 1.** Combined bilateral pudendal thigh and gluteal advancement flaps (A). Planned APR and posterior vaginectomy defect depicted in purple. Pudendal thigh flap skin paddles marked in light green lying along the groin crease. Medial aspect of bilateral gluteus advancement flaps pictured in orange will be deepithelialized and used to obliterate dead space (B). Deepithelialized skin paddles are sutured to one another to obliterate dead space with pudendal thigh flaps resting on top of them to resurface posterior vaginectomy. Skin closure rests in borders between esthetic subunits of the perineum.

pelvic dead space while also buttressing the pudendal flap inset with soft tissue.

### OPERATIVE TECHNIQUE

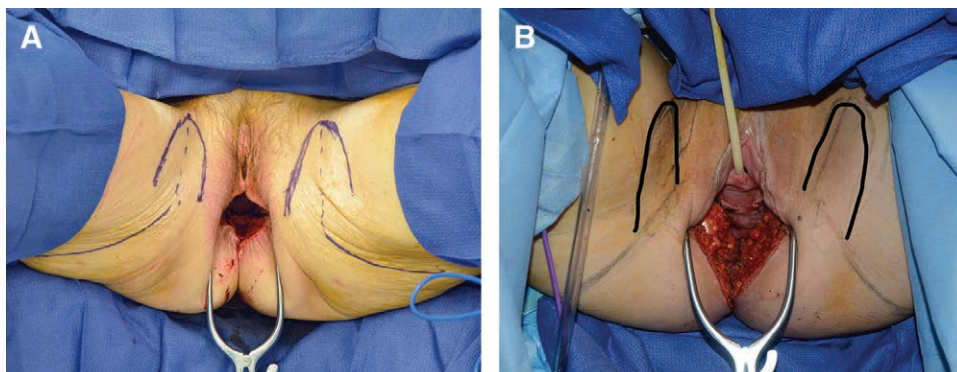
The robotic-assisted APR begins with the perineal dissection in the prone position followed by lithotomy

for the robotic abdominal resection. Depending upon the tumor size and location, an elliptical perineal skin incision of varying dimensions is made to include the anus encompassing the external anal sphincter and posterior vaginal wall. The diameter of skin resection dictates the amount of gluteal advancement that will be required for perineal closure. Up to 10 cm of advancement can be performed per gluteal flap with a tension-free perineal closure.<sup>10</sup> Dissection proceeds proximally through the levator complex. The posterior vaginal wall is divided 2 cm above the tumor creating the posterior vaginal wall defect to be resurfaced by the pudendal thigh flap, which will sit atop the portions of the advanced gluteal flaps used to obliterate the dead space. Dissection continues in the rectovaginal septum proximal to the point of transection.

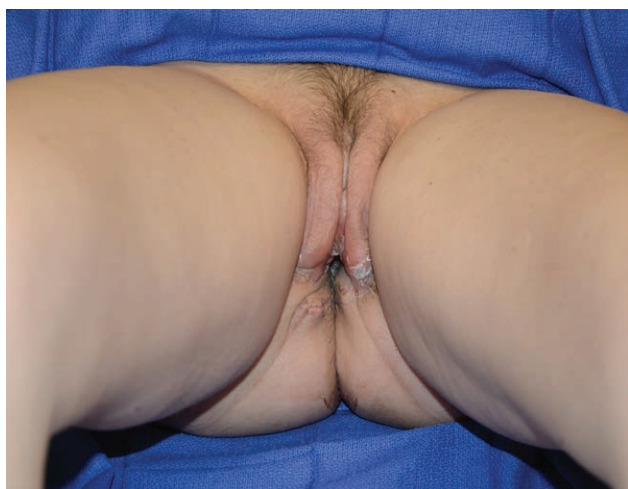The patient is then repositioned to lithotomy where a total mesorectal excision is completed with the DaVinci Si system using 3 robotic arms and a 5 mm assistant port. A left lower quadrant sigmoid colostomy is created. After the APR is complete, the patient remains in the lithotomy position to facilitate reconstruction.

Bilateral pudendal thigh flaps are elevated first in a subfascial plane with the skin paddle designed over the groin crease with a width up to 6 cm and length up to 15 cm.<sup>11</sup> Although classically described as being patterned directly over the groin crease, the skin paddles may be oriented more laterally onto the medial thigh to recruit tissue from outside the area grossly affected by radiation (Fig. 2). The posterior incision at the base of the pudendal thigh flap is not made, but the pudendal skin paddle is elevated with the gluteal flap as an advancement flap. When combined with gluteal advancement, even the more laterally positioned pudendal skin paddles easily reach the introitus for vaginal resurfacing.

Bilateral V-Y gluteal advancement fasciocutaneous flaps are elevated by incising skin, subcutaneous fat and fascia beveling away from the skin paddle. Then the glu-



**Fig. 2.** Design of combined bilateral gluteus advancement and pudendal thigh flaps. A, A 60-year-old female after robotic-assisted APR for rectal cancer with posterior and lateral vaginectomy without radiation. Pudendal thigh flaps centered over groin crease. B, A 35-year old female after robotic-assisted APR and posterior vaginectomy for advanced rectal cancer after neoadjuvant chemoradiation (50.4 Gy in 28 fractions). Redrawn pudendal flap design lateral to groin crease to avoid radiation field. The anterior border of bilateral gluteus V-Y advancements is marked in the gluteal creases in both images. The posterior border is not visualized.



**Fig. 3.** APR with en bloc resection of the posterior wall of the vagina. A 35-year-old patient is pictured in 2B 6 months after combined bilateral pudendal and gluteal flap pelvic reconstruction. Healed incisions lie within gluteal cleft and crease and groin creases. The patient is able to sit, has full pelvic range of motion, and sexual intercourse.

teal fascia is incised circumferentially, allowing the soft tissue to glide medially over the intact gluteus muscle as previously described.<sup>10</sup> The medial aspect of each flap is deepithelialized providing 8 cm length of each flap to be sewn to one another and used to obliterate pelvic dead space while serving as a support for the pudendal thigh flaps (Fig. 1). The medial aspects of the pudendal thigh flaps are sewn to one another to create the posterior wall of the vagina, and this construct can be sutured to the coccyx and surrounding vaginal mucosa and placed on top of the supporting deepithelialized aspect of the gluteal flaps.

Patients are discharged from the hospital on postoperative day 3 with restrictions against abducting the legs past shoulder's width for 2 weeks and against sitting with head of bed greater than 30 degrees for 4 weeks. Rapid return of ambulation is encouraged beginning on postoperative day 1 with showering beginning on day 2. Buttock contour and perineal relationships appear normal with incisions

hidden between esthetic units and an appropriate introital appearance is preserved (Fig. 3).

Our review of 8 consecutive pelvic reconstructions with at least 6 months follow-up show that minor skin dehiscence defined as incisional opening less than 5 cm in length was the most common complication (Table 1). Minor dehiscence was successfully treated in all cases with moist-to-dry dressings and daily showering with soap and water.

Gynecologic involvement during recovery is critical to functional pelvic rehabilitation. Topical estrogen replacement is recommended for premenopausal patients who have completed chemotherapy to prevent dehiscence of the pudendal skin paddles from the vagina due to mucosal atrophy. Preventative dilatation can be performed to maintain appropriate vaginal dimensions.

## CONCLUSIONS

The combination of gluteal advancement flaps to provide pelvic soft-tissue bulk and tension-free closure with pudendal thigh flaps to resurface the posterior vagina provides a powerful tool for female pelvic reconstruction after robotic-assisted APR. For advanced cancers where neoadjuvant chemoradiation is required, radiation exposure will need to be considered for pudendal thigh flap design. However, this combination of flaps offers an excellent tool to reconstruct combined perineal and vaginal defects when abdominally based flaps are not available.

*Chris A. Campbell, MD, FACS*

Department of Plastic and Reconstructive Surgery  
University of Virginia Health System  
P.O. Box 800376  
Charlottesville  
VA 22908  
E-mail: Cac5rb@hscmail.mcc.virginia.edu

## ACKNOWLEDGMENTS

*The authors thank Drs. Charles Friel and Kristin Turza for the inclusion of their patients in this article.*

**Table 1. Female Patients with Rectal Adenocarcinoma Undergoing Combined Bilateral Pudendal Gluteal Advancement Flap Reconstruction with Follow-Up Greater Than 6 Months**

Patient	Age (y)	Stage	BMI	Smoker	Chemotherapy	Radiation	Complication
1	47	T3N0	25.3	N	Y	N	
2	35	T3N0	21.3	N	Y	Y	Vaginal dilatation required
3	37	T3N1	22.9	Y	Y	Y	
4	46	T3N3	23.5	Y	Y	Y	Minor dehiscence
5	60	T3N1	24.1	N	Y	Y	Minor dehiscence
6	48	T4N2	24.3	N	N	Y	
7	49	T4N0	26.8	N	Y	Y	
8	58	T3N0	27.0	Y	Y	Y	Minor dehiscence

BMI, Body Mass Index

## REFERENCES

1. Akbari RP, Paty PB, Guillem JG, et al. Oncologic outcomes of salvage surgery for epidermoid carcinoma of the anus initially managed with combined modality therapy. *Dis Colon Rectum*. 2004;47:1136–1144.
2. Mullen JT, Rodriguez-Bigas MA, Chang GJ, et al. Results of surgical salvage after failed chemoradiation therapy for epidermoid carcinoma of the anal canal. *Ann Surg Oncol*. 2007;14:478–483.
3. Goldberg GL, Sukumvanich P, Einstein MH, et al. Total pelvic exenteration: the Albert Einstein College of Medicine/Montefiore Medical Center Experience (1987 to 2003). *Gynecol Oncol*. 2006;101:261–268.
4. Touran T, Frost DB, O'Connell TX. Sacral resection. Operative technique and outcome. *Arch Surg*. 1990;125:911–913.
5. Arnold PG, Lovich SF, Pairolero PC. Muscle flaps in irradiated wounds: an account of 100 consecutive cases. *Plast Reconstr Surg*. 1994;93:324–327; discussion 328.
6. Campbell CA, Butler CE. Use of adjuvant techniques improves surgical outcomes of complex vertical rectus abdominis myocutaneous flap reconstructions of pelvic cancer defects. *Plast Reconstr Surg*. 2011;128:447–458.
7. Nelson RA, Butler CE. Surgical outcomes of VRAM versus thigh flaps for immediate reconstruction of pelvic and perineal cancer resection defects. *Plast Reconstr Surg*. 2009;123:175–183.
8. Singh P, Teng E, Cannon LM, et al. Dynamic article: tandem robotic technique of extralevator abdominoperineal excision and rectus abdominis muscle harvest for immediate closure of the pelvic floor defect. *Dis Colon Rectum*. 2015;58:885–891.
9. Fisher J, Arnold PG, Waldorf J, et al. The gluteus maximus musculocutaneous V-Y advancement flap for large sacral defects. *Ann Plast Surg*. 1983;11:517–522.
10. Arnold PB, Lahr CJ, Mitchell ME, et al. Predictable closure of the abdominoperineal resection defect: a novel two-team approach. *J Am Coll Surg*. 2012;214:726–732; discussion 732.
11. Wee JT, Joseph VT. A new technique of vaginal reconstruction using neurovascular pudendal-thigh flaps: a preliminary report. *Plast Reconstr Surg*. 1989;83:701–709.