






ORIGINAL RESEARCH

Vertebrobasilar Stroke: Association Between Infarction Patterns and Quantitative Magnetic Resonance Angiography Flow State

Ahmad A. Ballout , MD; Richard B. Libman, MD; Julia R. Schneider, DO; Karen Black , MD; Panagiotis Sideras, MD; Jason J. Wang , PhD; Timothy G. White , MD; Amir R. Dehdashti, MD; Henry H. Woo, MD; Jeffrey M. Katz , MD

BACKGROUND: Treatment and prognosis of vertebrobasilar atherosclerotic disease differs depending on stroke mechanism, such as artery-to-artery embolism, branch atheromatous disease, and hemodynamic ischemia. Our aim was to investigate the relationship between infarction pattern and flow status using quantitative magnetic resonance angiography (QMRA), to determine the validity of using infarction patterns to infer stroke mechanism.

METHODS AND RESULTS: This is a retrospective study of patients with ischemic stroke with intra- or extracranial vertebrobasilar atherosclerotic stenosis, who underwent magnetic resonance imaging of the brain, neurovascular imaging, and QMRA, between 2009 and 2021. Patients with cerebral infarction predating or following QMRA by ≥ 1 year, or QMRA studies performed for basilar thrombosis, vertebral dissection, or only postangioplasty/stenting, were excluded. Poststenotic flow (basilar and posterior cerebral arteries) was dichotomized as low-flow or normal-flow based on published criteria. Of 1211 consecutive patients who underwent QMRA noninvasive optimal analysis, 69 met inclusion. Mixed patterns were most common (46.4%), followed by perforator (23.2%), borderzone (14.5%), and territorial (15.9%). Patients with low-flow had a significantly higher rate of borderzone+ patterns (borderzone alone or in mixed pattern) compared with patients with normal-flow (77.4% low-flow versus 39.5% normal-flow, $P=0.002$). Borderzone+ patterns were associated with 61.5% probability of low-flow state, while no borderzone (perforator/territorial) patterns were associated with 76.7% probability of normal-flow state.

CONCLUSIONS: Borderzone infarction pattern (alone or mixed) was associated with low poststenotic posterior circulation flow by QMRA. However, borderzone pattern only moderately predicted low-flow state, and may be an unreliable flow marker. Therefore, infarct topography may complement, but should not replace hemodynamic studies to establish flow status.

Key Words: hemodynamics ■ posterior circulation ■ vertebrobasilar disease

The mechanisms of cerebral infarction associated with symptomatic vertebrobasilar atherosclerotic disease include artery-to-artery embolism, branch atheromatous disease,¹ hemodynamic ischemia, and often a combination of these. The interrelated nature of these mechanisms is debated, with evidence in the anterior circulation that supports a complementary relationship between hypoperfusion and embolism, as

hemodynamic compromise is thought to both promote the formation of thrombi and decrease the “washout” of distal emboli.^{2–4} This relationship is less well established in the posterior circulation.

Determining a specific stroke mechanism is important because treatment and prognosis may differ.^{5,6} Currently, several neurovascular imaging modalities are used to elucidate stroke mechanism,

Correspondence to: Jeffrey M. Katz, MD, Department of Neurology, North Shore University Hospital, 300 Community Dr, Manhasset, NY 11030. E-mail: jkatz2@northwell.edu

For Sources of Funding and Disclosures, see page 7.

© 2022 The Authors. Published on behalf of the American Heart Association, Inc., by Wiley. This is an open access article under the terms of the Creative Commons Attribution-NonCommercial-NoDerivs License, which permits use and distribution in any medium, provided the original work is properly cited, the use is non-commercial and no modifications or adaptations are made.

JAHA is available at: www.ahajournals.org/journal/jaha

CLINICAL PERSPECTIVE

What Is New?

- There is a strong association between posterior circulation borderzone infarction patterns and a low-flow state as measured by quantitative magnetic resonance angiography in patients with atherosclerotic stenosis of the vertebrobasilar system.
- Posterior circulation borderzone infarction patterns, however, are only moderately predictive of a low-flow state.

What Are the Clinical Implications?

- Infarct topography in the posterior circulation may be used as an adjunct to predict hemodynamic flow status in patients with intracranial atherosclerotic stenosis but cannot supplant hemodynamic studies.

Nonstandard Abbreviations and Acronyms

QMRA	quantitative magnetic resonance angiography
VERITAS	Vertebrobasilar Flow Evaluation and Risk of Transient Ischemic Attack and Stroke

including Time-of-Flight Quantitative Magnetic Resonance Angiography (QMRA) Noninvasive Optimal Vessel Analysis (VasSol, Inc., River Forest, IL, USA); Magnetic Resonance Perfusion-Weighted-Imaging; vasomotor reactivity using transcranial Dopplers and breath-holding techniques; and with embolic signal monitoring.⁷ At our institution, we use QMRA to measure intravascular flow, stratify recurrent stroke risk, and determine indications for intervention based on poststenotic flow status. This approach is based on VERITAS (The Vertebrobasilar Flow Evaluation and Risk of Transient Ischemic Attack and Stroke) trial, which showed a 5-times higher risk of subsequent stroke with low-flow compared with normal-flow in patients with symptomatic intracranial or extracranial vertebrobasilar stenosis.⁸

Infarction patterns are often used in conjunction with vessel imaging to infer the underlying stroke mechanism, although the accuracy of this inference is uncertain, since the actual hemodynamic effect of a given degree of stenosis is unclear. This is particularly true in the posterior circulation given the variability in posterior circulation vascular anatomy, collateralization networks, and poorly defined borderzones. QMRA

may be helpful, because it provides a quantitative measure of intravascular blood flow, and thus may assist in elucidating a specific stroke mechanism.⁹ Given the uncertain relationship between hemodynamics and magnetic resonance imaging (MRI)-based infarction patterns in the posterior circulation, we assessed infarction patterns in relation to flow state and hypothesized that borderzone infarction patterns are associated with a low poststenotic flow state.

METHODS

Patient Selection

We performed a retrospective study of consecutive patients with ischemic stroke, who underwent QMRA Noninvasive Optimal Vessel Analysis to evaluate vertebrobasilar atherosclerotic disease, between 2009 and 2021, at 2 comprehensive stroke centers in a single health system. Institutional review board approval was obtained with waiver of consent because of the retrospective nature of this study. The data supporting the findings of this study are available from the corresponding author upon reasonable request. Study inclusion required the following: (1) MRI-confirmed cerebral infarction localized to the posterior circulation; (2) vascular imaging showing intracranial and/or extracranial atherosclerotic stenosis in the posterior circulation; and (3) QMRA performed within ± 1 year of stroke onset to ensure that cerebral infarctions occurred in relative proximity to the hemodynamic study. Patients were excluded from the study if any of the following criteria were met: (1) vascular imaging demonstrated acute basilar thrombosis or embolic occlusion; (2) MRI showed concurrent cerebral infarctions in the anterior circulation; (3) infarctions occurred exclusively following catheter angiography or bypass surgery; (4) QMRA preceded or followed stroke symptom onset by >1 year; (5) cerebral infarction in the setting of a vertebral artery dissection; or (6) intervention for target stenosis performed before QMRA. A flow diagram for study inclusion is shown in Figure 1.

Distal Flow Status

Patients were dichotomized into normal-flow and low-flow groups based on QMRA blood flow measurements in the basilar artery and (nonfetal origin) posterior cerebral arteries, distal to the atherosclerotic steno-occlusive disease, as defined in the VERITAS study.⁸

Stenosis Severity Determination

The severity of vessel stenosis was determined by 2 board-certified neuroradiologists (K.B., P.S.) who were blinded to distal flow status and clinical history. The WASID (Warfarin versus Aspirin for Symptomatic

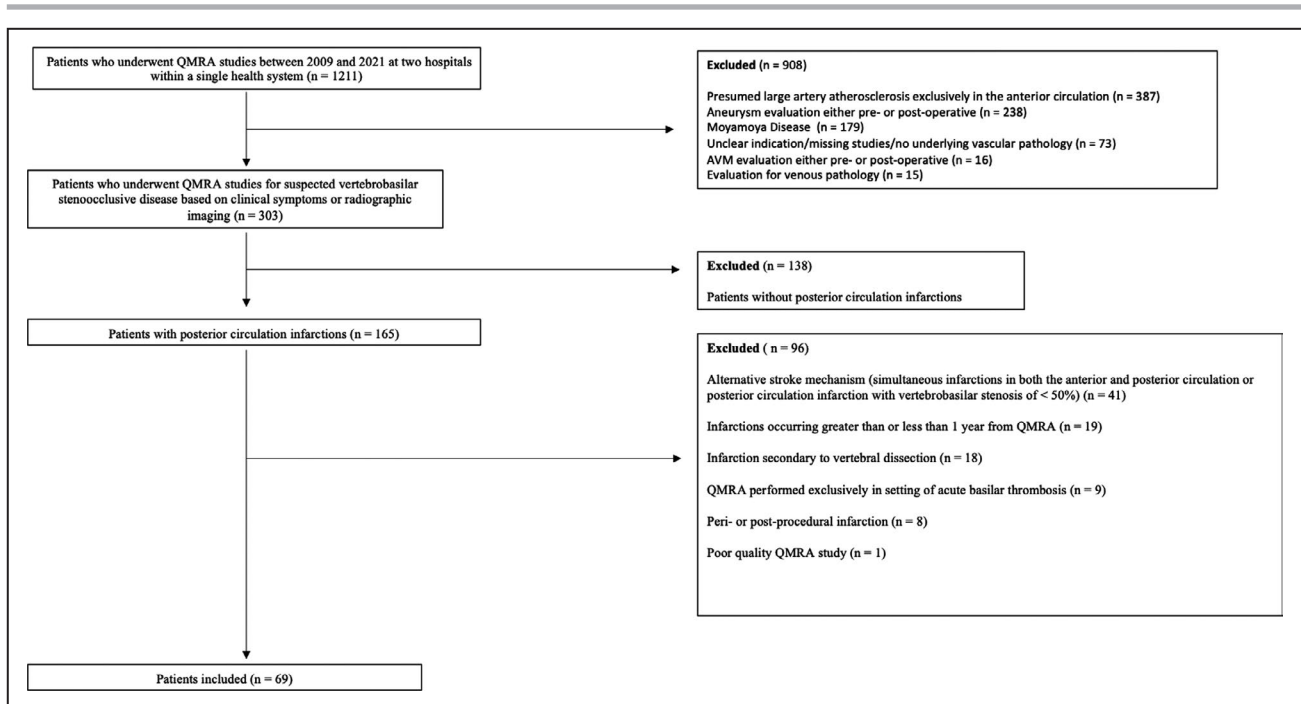


Figure 1. Exclusion criteria.

AVM indicates arteriovenous malformation; and QMRA, quantitative magnetic resonance angiography.

Intracranial Stenosis) method was used to measure intracranial vertebrobasilar stenosis,¹⁰ and the CAVATAS (Carotid and Vertebral Artery Transluminal Angioplasty Study) method was used for the extracranial vertebral arteries.¹¹ Since most of the cohort underwent head and neck computed tomographic angiography (n=57), this was the most common imaging modality used. Computed tomographic angiography has been shown to be superior to time-of-flight MRA in detecting stenosis, with a sensitivity and specificity of 95%.¹² For patients without computed tomographic angiography (n=12), digital subtraction angiography (n=2) or MRA head and neck with contrast (n=10) were used.

Infarction Pattern Determination

MRI diffusion-weighted imaging was reviewed by 2 board-certified neuroradiologists who were blinded to flow status (K.B., P.S.). Consensus was reached between the 2 readers in cases of disagreement. Infarction patterns were adjudicated with reference to published templates¹³ using a modified classification system that was based on those used in previous studies.^{14,15} Mixed infarction patterns were further subclassified by their pattern constituents and later used to dichotomize patients into borderzone+, if a borderzone pattern was a component of the mixed pattern, or nonborderzone, if the mixed pattern was composed solely of territorial and perforator patterns.

Infarction patterns were classified as follows:

1. Territorial pattern: ≥ 1 infarction distal to the stenotic artery restricted to the territory supplied by a single intracranial artery.
2. Perforator pattern: Unilateral infarction in the distribution of a basilar perforating artery.
3. Borderzone pattern: ≥ 1 infarction exclusively in a borderzone between (1) the posterior inferior and anterior inferior cerebellar arteries, (2) the anterior inferior and superior cerebellar arteries, or (3) the posterior and middle cerebral arteries.
4. Mixed pattern: 2 or more of the above patterns.

Statistical Analysis

Interrater reliability for infarction pattern was performed using the kappa statistic, calculated as the proportion of infarction patterns that were similarly classified by both blinded readers (n=45) over the total number of infarctions (n=69). Bivariate analyses were performed to study the association between flow state and infarction patterns using the χ^2 and Fisher exact test. A *P* value of < 0.05 was considered statistically significant. Statistical adjustments were not made because we exclusively performed bivariate analyses. SAS v9.4 (SAS, Cary, NC) was used for all statistical analyses.

RESULTS

Between 2009 and 2021, 1211 consecutive patients underwent QMRA Noninvasive Optimal Vessel Analysis at 2

comprehensive stroke centers in a single health system. Of these, 303/1211 (25.0%) patients underwent QMRA to evaluate vertebrobasilar atherosclerotic disease, of which 69/1211 (5.7%) patients met study inclusion. The mean±SD age of the cohort was 64.6±10.1 years, including 52 (75%) men and 17 (25%) women. Recurrent posterior circulation strokes occurred in 19/69 (27.5%) patients. Brain MRI preceded QMRA in all but 1 stroke, with this stroke occurring 64 days after the QMRA. The median (interquartile range [IQR]) time between brain MRI and QMRA was 6.0 (0–70.5) days. Neurovascular imaging (computed tomographic and/or MR angiography) preceded QMRA in all but 6 studies. The median (IQR) time between neurovascular imaging and QMRA was 3.0 (1–28.7) days.

The vessel involved and the severity of the stenocclusive disease are detailed in Table. Patients with low-flow states were statistically more likely to have a high-grade stenosis of >70% in either vertebral artery or basilar artery compared with patients with normal-flow states (96.7% versus 71.1%, $P=0.005$).

Infarction Patterns

Figure 2 shows examples of each pattern type. The interrater reliability for infarction pattern was moderate ($\kappa=0.65$). The frequency of vertebrobasilar infarction patterns by flow status is shown in Figures 3 and 4. Mixed pattern was the most frequent finding (32/69, 46.4%), followed by perforator (16/69, 23.2%), borderzone (10/69, 14.5%) and territorial (11/69, 15.9%). A borderzone constituent was present in most mixed patterns (29/32, 90.6%). Low flow was seen in 5/10 (50%) patients with borderzone pattern and the majority of patients with mixed (20/32, 62.5%) pattern infarctions, but only a minority of perforator (3/16, 18.8%) and territorial (3/11, 27.3%) patients with infarction pattern (Figure 3). Patients with low-flow states had a significantly higher rate of Borderzone+ patterns compared with patients with normal-flow states (77.4% low-flow versus 39.5% normal-flow, $P=0.002$) (Figure 4). Borderzone+ infarction patterns were only associated with a 61.5% probability of a low-flow state, while no borderzone (perforator/territorial) pattern was associated with a 76.7% probability of a normal-flow state.

DISCUSSION

The aim of our study was to elucidate the relationship between posterior circulation infarction patterns and hemodynamic flow status. We found a strong association between low-flow states and Borderzone+ infarctions (borderzone alone or mixed borderzone plus other patterns), and between normal flow states and non-borderzone infarctions (territorial and perforator patterns). Despite this statistical association, Borderzone+ infarctions were only moderately predictive of low-flow states (61.5%), suggesting that infarction patterns are a suboptimal marker of hemodynamics in the posterior circulation, and cannot be used to reliably predict a low-flow state. Although low-flow states were more frequent with mixed infarctions, and normal-flow states more common with perforator and territorial patterns, both flow states were found in all 4 patterns, suggesting that, to an unequal degree, all 4 infarction patterns are found in both flow states.

The prevalence of the mixed infarction pattern (46.4%) in our study was higher than was reported by the WASID investigators (6.3%).¹⁴ This difference may be in part because of the narrower classification system they used; namely, posterior circulation borderzones limited to the middle cerebral artery/posterior cerebral artery cortical borderzones, excluding cerebellar borderzones, and the possibility of selection bias in our study since our patient population was limited to those who underwent hemodynamic studies. Mixed patterns were not included in the classification system of the VERITAS or SAMMPRIS (Stenting versus Aggressive Medical Management for Preventing Recurrent Stroke in Intracranial Stenosis) subgroup analyses.^{15,16}

In the VERITAS substudy, among patients with a low-flow state (in whom one might expect a large majority of borderzone infarctions), there was a 40% rate of territorial infarctions.¹⁵ In a substudy of the WASID population,¹⁴ hemodynamic insufficiency was defined by collateral status on conventional angiography. For the group of patients with no or poor collaterals, territorial infarctions were more common than borderzone infarctions, and borderzone infarctions were paradoxically more frequent with good collaterals, suggesting

Table 1. Degree and Location of Vertebrobasilar Atherosclerotic Steno-Occlusive Disease

	Low flow (n= 31)	Normal flow (n=38)	Total (n=69)	P value
Stenosis degree				
≥70%/occlusion	30 (96.7%)	27 (71.1%)	57 (82.6%)	0.005
Stenosis location				
Intracranial only	21 (67.7%)	23 (60.5%)	43 (62.3%)	0.53
Basilar involved	11 (35.5%)	17 (44.7%)	28 (40.6%)	0.43
Extracranial only	2 (6.5%)	4 (10.5%)	6 (8.7%)	0.55
Tandem EC+IC	8 (25.8%)	11 (29.0%)	18 (26.1%)	0.77

EC indicates extracranial; and IC, intracranial.

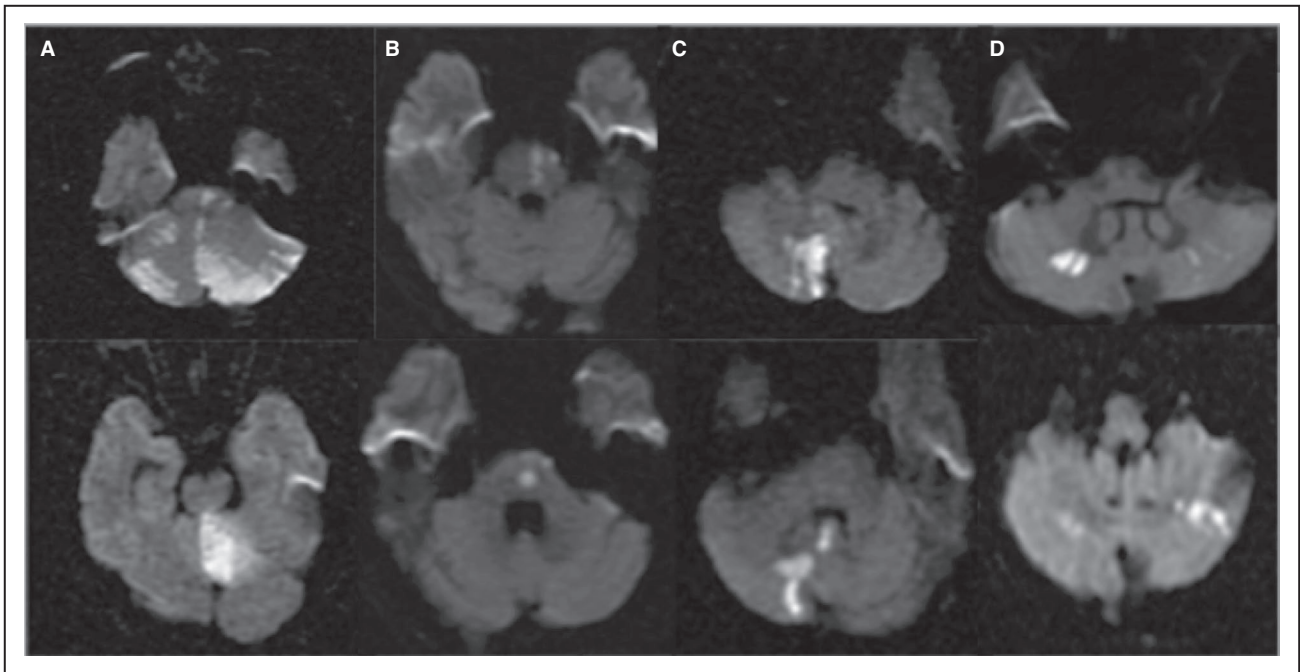


Figure 2. Mixed (A), Perforator (B), Territorial (C), and Borderzone (D) infarction patterns.

an inconsistent relationship between flow status and infarction pattern. This study, however, examined patients with both anterior and posterior circulation ischemia and is, therefore, not strictly comparable to ours.

We found a 27.5% rate of recurrent stroke in our study population. Multiple studies have demonstrated a strong link between imaging markers of hemodynamic status and recurrent cerebrovascular ischemic events.^{8,14,16–21} These, however, have focused primarily on the anterior circulation. Using positron emission topography oxygen extraction fraction (the criterion

standard for hemodynamic imaging), the St. Louis Carotid Occlusion Study demonstrated that patients with hemodynamic impairment are at higher risk of stroke.¹⁹ Other authors have used surrogate markers of hemodynamic status, linking these to risk of further stroke. Using collateral scores as a surrogate for distal flow status, investigators have shown a relationship between collaterals and stroke risk in both WASID and SAMMPRIS subgroups.^{14,16} Unfavorable perfusion profiles have been linked to internal borderzone infarctions,²⁰ and these perfusion profiles have been shown

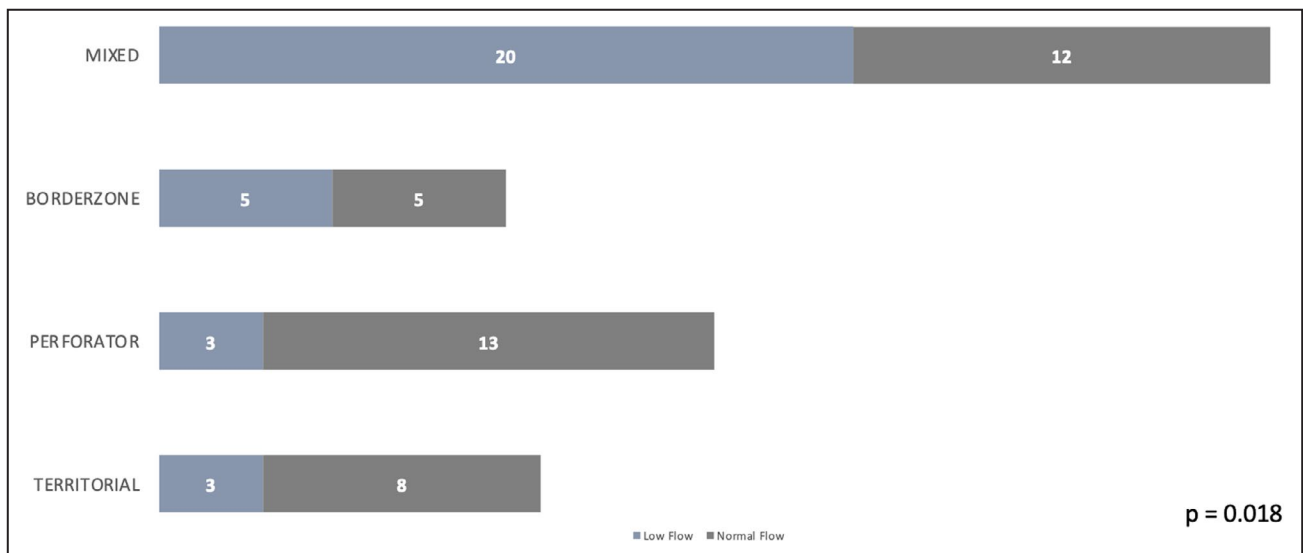


Figure 3. Number of patients with each infarction pattern in relation to flow status.

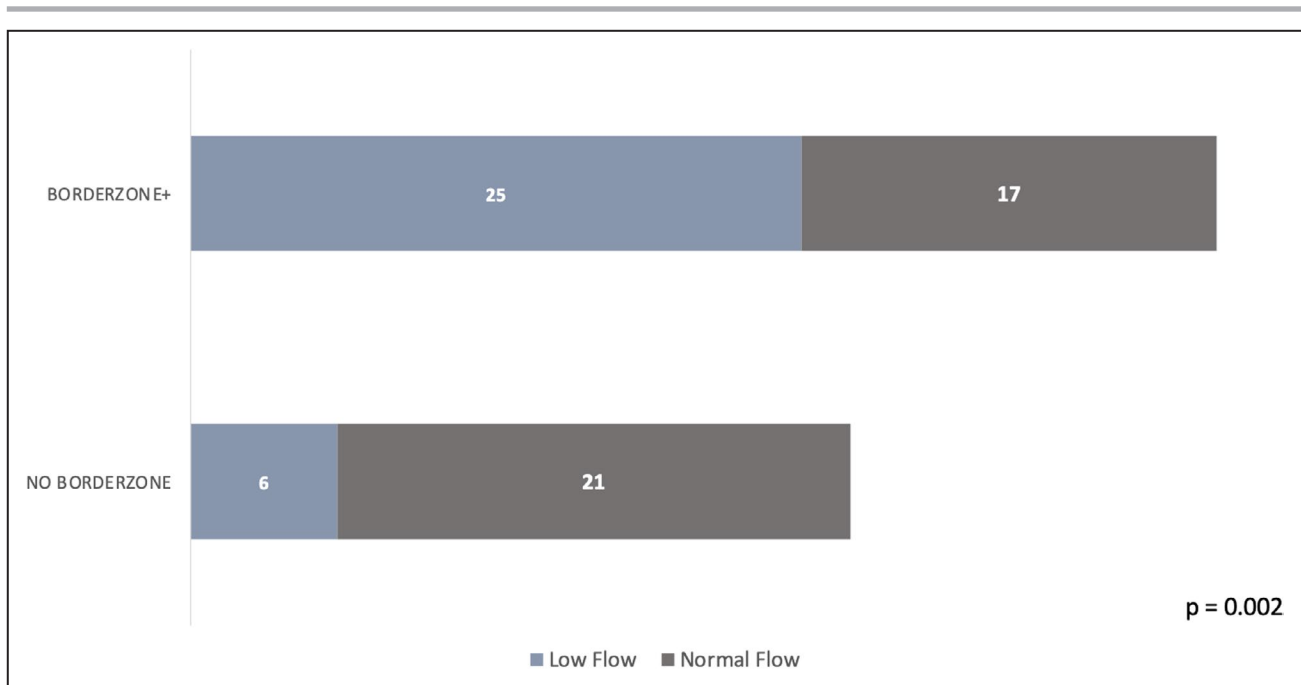


Figure 4. Number of patients with Borderzone+ pattern in relation to flow status (n=69).

to predict recurrent cerebrovascular events and neurological deterioration.^{21,22} Most of these studies were based on the anterior circulation. VERITAS was the first study of its kind to apply hemodynamic imaging principles to the posterior circulation, and risk stratify patients based on flow status. VERITAS showed that patients with low-flow distal to a stenosis, as measured by QMRA, were at significantly increased risk for recurrent stroke compared with those with normal flow.⁸ In contrast, a more recent study examined patients with anterior and posterior circulation intracranial atherosclerotic stenosis, using several measures of hemodynamics, and potential for artery-to-artery embolism and showed that none of the techniques reliably predicted an increased risk of subsequent stroke.²³ This suggests that some of our current techniques for measuring hemodynamics may not be predictive of stroke risk or may have different predictive value depending on the population being studied.

Our study has several strengths and limitations. While our sample size is relatively small, our study included the same number of patients as those in VERITAS who had complete follow-up,⁸ and is sizeable compared with previous studies of posterior circulation stroke in patients with vertebrobasilar atherosclerotic steno-occlusive disease. Our study also has all the limitations of a retrospective design, including confounding, which we could not control for, and selection bias, since QMRA was performed at the discretion of the clinician, and not according to a prespecified protocol. Furthermore, the validity of QMRA Noninvasive Optimal

Vessel Analysis is uncertain since it has never been tested against other hemodynamic testing modalities, including the criterion standard positron-emission tomography. Other strengths of our study include the detailed assessment of infarction patterns performed by neuroradiologists blinded to flow status, and inclusion of cerebellar borderzones, patterns that were not commonly assessed in previous studies.

Our study was not designed to imply a stroke mechanism. For example, a borderzone pattern of infarction associated with low-flow does not distinguish between artery-to-artery embolism and hypoperfusion as a stroke mechanism. In fact, as has previously been proposed, these 2 mechanisms are not mutually exclusive and may coexist.² Our study did not focus on the association between degree of stenosis and flow state. Further studies looking at this association are under way.

CONCLUSIONS

We found a strong statistical association between borderzone infarction patterns (alone or mixed) and low-flow states and between nonborderzone infarctions and normal flow-states in the posterior circulation. Despite this association, borderzone infarction (alone or mixed) patterns were only moderate predictors of low-flow states, and are therefore clinically unreliable markers of hemodynamics. Our findings suggest that infarct topography in the posterior circulation should not be used exclusively to predict hemodynamics but

may be a complementary tool to be used in conjunction with hemodynamic studies. Because flow status defined by QMRA in the posterior circulation may predict stroke risk, investigating angioplasty/stenting versus medical management in patients with symptomatic posterior circulation stenosis may include hemodynamic quantification, but should not depend exclusively on infarction pattern as a marker of hemodynamic compromise.

ARTICLE INFORMATION

Received September 29, 2021; accepted December 6, 2021.

Affiliations

Department of Neurology (A.A.B., R.B.L., J.R.S., J.M.K.), Department of Radiology (K.B., P.S., J.J.W., J.M.K.) and Department of Neurosurgery (T.G.W., A.R.D., H.H.W.), Donald and Barbara Zucker School of Medicine at Hofstra/Northwell, Manhasset, NY.

Sources of Funding

None.

Disclosures

Dr Jeffrey M. Katz has received research funding from Medtronic USA, Inc., and Siemens Healthineers USA that is unrelated to the current research study. The remaining authors have no disclosures to report.

REFERENCES

1. Caplan LR. Intracranial branch atheromatous disease: a neglected, understudied, and underused concept. *Neurology*. 1989;39:1246–1250. doi: 10.1212/WNL.39.9.1246
2. Caplan LR, Hennerici M. Impaired clearance of emboli (washout) is an important link between hypoperfusion, embolism, and ischemic stroke. *Arch Neurol*. 1998;55:1475–1482.
3. Caplan LR, Wong KS, Gao S, Hennerici MG. Is hypoperfusion an important cause of strokes? If so, how? *Cerebrovasc Dis*. 2006;21:145–153.
4. Sedlaczek O, Caplan L, Hennerici M. Impaired washout—embolism and ischemic stroke: further examples and proof of concept. *Cerebrovasc Dis*. 2005;19:396–401.
5. Bang OY, Lee PH, Heo KG, Joo US, Yoon SR, Kim SY. Specific DWI lesion patterns predict prognosis after acute ischaemic stroke within the MCA territory. *J Neurol Neurosurg Psychiatry*. 2005;76:1222–1228.
6. Jung J-M, Kang D-W, Yu K-H, Koo J-S, Lee J-H, Park J-M, Hong K-S, Cho Y-J, Kim JS, Kwon SU, et al. Predictors of recurrent stroke in patients with symptomatic intracranial arterial stenosis. *Stroke*. 2012;43:2785–2787. doi: 10.1161/STROKEAHA.112.659185
7. Liebeskind DS, Prabhakaran S, Azhar N, Feldmann E, Campo-Bustillo I, Sangha R, Koch S, Rundek T, Ostergren L, Chimowitz MI, et al. Mechanisms of early recurrence in intracranial atherosclerotic disease (MyRIAD): rationale and design. *J Stroke Cerebrovasc Dis*. 2020;29:105051.
8. Amin-Hanjani S, Pandey DK, Rose-Finnell L, Du X, Richardson D, Thulborn KR, Elkind MSV, Zipfel GJ, Liebeskind DS, Silver FL, et al. Effect of hemodynamics on stroke risk in symptomatic atherosclerotic vertebrobasilar occlusive disease. *JAMA Neurol*. 2016;73:178–185. doi: 10.1001/jamaneurol.2015.3772
9. Zhao M, Amin-Hanjani S, Ruland S, Curcio AP, Ostergren L, Charbel FT. Regional cerebral blood flow using quantitative MR angiography. *Am J Neuroradiol*. 2007;28:1470–1473. doi: 10.3174/ajnr.A0582
10. Samuels OB, Joseph GJ, Lynn MJ, Smith HA, Chimowitz MI. A standardized method for measuring intracranial arterial stenosis. *Am J Neuroradiol*. 2000;21:643–646.
11. Coward LJ, McCabe DJH, Ederle J, Featherstone RL, Clifton A, Brown MM; CAVATAS Investigators. Long-term outcome after angioplasty and stenting for symptomatic vertebral artery stenosis compared with medical treatment in the Carotid and Vertebral Artery Transluminal Angioplasty Study (CAVATAS): a randomized trial. *Stroke*. 2007;38:1526–1530.
12. Bash S, Villablanca JP, Jahan R, Duckwiler G, Tillis M, Kidwell C, Saver J, Sayre J. Intracranial vascular stenosis and occlusive disease: evaluation with CT angiography, MR angiography, and digital subtraction angiography. *Am J Neuroradiol*. 2005;26:1012–1021.
13. Tatu L, Moulin T, Bogousslavsky J, Duvernoy H. Arterial territories of human brain: brainstem and cerebellum. *Neurology*. 1996;47:1125–1135. doi: 10.1212/WNL.47.5.1125
14. López-Cancio E, Matheus MG, Romano JG, Liebeskind DS, Prabhakaran S, Turan TN, Cotsonis GA, Lynn MJ, Rumboldt Z, Chimowitz MI. Infarct patterns, collaterals and likely causative mechanisms of stroke in symptomatic intracranial atherosclerosis. *Cerebrovasc Dis*. 2014;37:S417–S422. doi: 10.1159/000362922
15. Schaafsma JD, Silver FL, Kasner SE, Caplan LR, Rose-Finnell L, Charbel FT, Pandey DK, Amin-Hanjani S; for the VERITAS Study Group. Infarct patterns in patients with atherosclerotic vertebrobasilar disease in relation to hemodynamics. *Cerebrovasc Dis Extra*. 2019;9:123–128.
16. Wabnitz AM, Derdeyn CP, Fiorella DJ, Lynn MJ, Cotsonis GA, Liebeskind DS, Waters MF, Lutsep H, López-Cancio E, Turan TN, et al. Hemodynamic markers in the anterior circulation as predictors of recurrent stroke in patients with intracranial stenosis. *Stroke*. 2019;50:143–147. doi: 10.1161/STROKEAHA.118.020840
17. Grubb RL Jr, Derdeyn CP, Fritsch SM, Carpenter DA, Yundt KD, Videen TO, Spitznagel EL, Powers WJ. Importance of hemodynamic factors in the prognosis of symptomatic carotid occlusion. *JAMA*. 1998;280:1055–1060. doi: 10.1001/jama.280.12.1055
18. Yaghi S, Grory BM, Prabhakaran S, Yeatts SD, Cutting S, Jayaraman M, Sacchetti D, Furie K, Zaidat OO, Liebeskind DS, et al. Infarct Pattern, Perfusion mismatch thresholds, and recurrent cerebrovascular events in symptomatic intracranial stenosis. *J Neuroimaging*. 2019;29:640–644. doi: 10.1111/jon.12630
19. Sacchetti DC, Cutting SM, McTaggart RA, Chang AD, Hemendinger M, Mac Grory B, Siket MS, Burton T, Thompson B, Rostanski SK, et al. Perfusion imaging and recurrent cerebrovascular events in intracranial atherosclerotic disease or carotid occlusion. *Int J Stroke*. 2018;13:592–599. doi: 10.1177/1747493018764075
20. Kim SJ, Morales JM, Yaghi S, Honda T, Scalzo F, Hinman JD, Raychev R, Sharma LK, Fieldmann E, Ramano JG, et al. Intracranial atherosclerotic disease mechanistic subtypes drive hypoperfusion patterns. *J Neuroimaging*. 2021;31:686–690.
21. Yaghi S, Khatri P, Prabhakaran S, Yeatts SD, Cutting S, Jayaraman M, Chang AD, Sacchetti D, Liebeskind DS, Furie KL. What threshold defines penumbral brain tissue in patients with symptomatic anterior circulation intracranial stenosis: an exploratory analysis. *J Neuroimaging*. 2019;29:203–205. doi: 10.1111/jon.12577
22. Tamura A, Yamamoto Y, Nagakane Y, Takezawa H, Koizumi T, Makita N, Makino M. The relationship between neurological worsening and lesion patterns in patients with acute middle cerebral artery stenosis. *Cerebrovasc Dis*. 2013;35:268–275.
23. Romano JG, Prabhakaran S, Nizam A, Feldmann E, Sangha R, Cotsonis G, Campo-Bustillo I, Koch S, Rundek T, Chimowitz MI, et al. Infarct recurrence in intracranial atherosclerosis: results from the MyRIAD study. *J Stroke Cerebrovasc Dis*. 2021;30:105504.