

Aspiration-related organizing pneumonia complicating laparoscopic adjustable gastric banding: A lung cancer mimicker

Ahmed A. Aljohaney, Amr M. Ajlan¹, Fahad A. Alghamdi²

Departments of Medicine, ¹Radiology and ²Pathology, Faculty of Medicine, King Abdulaziz University, Jeddah, Saudi Arabia

Address for correspondence:

Dr. Ahmed A. Aljohaney,
Department of Medicine,
Faculty of Medicine,
King Abdulaziz University,
P. O. Box 80215, Jeddah
21589, Saudi Arabia.
E-mail: drajohani@yahoo.
com

Submission: 22-02-2016
Accepted: 03-04-2016

Abstract:

There are several described pulmonary complications due to laparoscopic adjustable gastric banding. We report a rare case of a 32-year-old male who presented with pulmonary symptoms and a solitary lung mass 12 years after laparoscopic adjustable gastric banding. A bronchoscopic lung biopsy showed organizing pneumonia that was induced by aspiration pneumonia. The atypical radiological appearance of the aspiration pneumonia may pose a diagnostic challenge, and clinicians' awareness regarding such an entity is needed to avoid unnecessary intervention.

Key words:

Aspiration, gastric banding, lung cancer, organizing pneumonia

Obesity, now a worldwide epidemic, is a risk factor for diabetes mellitus, respiratory conditions, and malignancy.^[1] Gastric bypass, sleeve gastrectomy, and laparoscopic adjustable gastric banding (LAGB) are common bariatric surgeries used to eliminate obesity and reduce related comorbidities.^[2] LAGB involves placing a plastic ring around the gastric fundus, which limits food intake. Such a procedure carries a small overall surgical risk, is reversible, convenient, and can be modified according to the patient's need.^[2,3] However, the application of LAGB has declined, possibly because of a high revision rate and weight recidivism, as well as the overshadowing success of sleeve gastrectomies.^[3] Further, despite the relative safety of LAGB, several reports have documented long-term complications, of which aspiration pneumonia is the most common.^[4,5] In addition, hemoptysis, bronchiectasis, asthma, and lung abscesses have also been reported.^[5]

We report a case of organizing pneumonia due to aspiration, occurring 12 years after LAGB and mimicking lung cancer. We aim to increase physicians' awareness of this rare and late complication of LAGB.

Case Report

A 32-year-old male underwent LAGB for obesity 12 years previously. He presented at the outpatient clinic with a productive cough, small-volume hemoptysis, and fever that had persisted for 7 days. He reported two recent

months of frequent choking while asleep at night. Upper gastrointestinal endoscopy performed 2 weeks ahead of the presentation showed a dilated esophagus containing fluid and food. The patient had a 10-pack year history of smoking and had poor compliance with proton pump inhibitors. At presentation, his temperature was 39.3°C; blood pressure, 100/70 mmHg; pulse, 107 beats/min; respiratory rate, 22 breaths/min; oxygen saturation while breathing room air, 96%; weight, 118 kg; and height, 179 cm (body mass index = 36.9). Chest auscultation indicated diminished breath sounds and few crackles in the right lung. Laboratory tests showed a white blood cell count of $12.8 \times 10^3/\mu\text{L}$; hemoglobin level, 13 g/dL; platelet count, $324 \times 10^3/\mu\text{L}$; and C-reactive protein level, 169 mg/L. The renal profile was normal. Chest X-ray showed relatively well-defined right paramediastinal apical lung opacity [arrow in Figure 1a]. A same-date

This is an open access article distributed under the terms of the Creative Commons Attribution-NonCommercial-ShareAlike 3.0 License, which allows others to remix, tweak, and build upon the work non-commercially, as long as the author is credited and the new creations are licensed under the identical terms.

For reprints contact: reprints@medknow.com

How to cite this article: Aljohaney AA, Ajlan AM, Alghamdi FA. Aspiration-related organizing pneumonia complicating laparoscopic adjustable gastric banding: A lung cancer mimicker. *Ann Thorac Med* 2016;11:294-6.

Access this article online

Quick Response Code:



Website:

www.thoracicmedicine.org

DOI:

10.4103/1817-1737.182902

high-resolution chest computed tomography (CT) confirmed a 5.5 cm right upper lobe apical segmental mass that contacted the mediastinum [arrow in Figure 1b], and esophageal dilation with internal fluid [arrowhead in Figure 1b].

The patient was hospitalized with a presumptive diagnosis of community-acquired pneumonia. He was administered 2 g intravenous ceftriaxone once daily and 600 mg of clindamycin every 8 h. Sputum staining for bacterial or mycobacterial tuberculosis yielded negative results. Since the fever persisted for 3 days, diagnostic bronchoscopy was performed, which revealed signs of gastroesophageal reflux disease (GERD) and a narrowed apical segment of the right upper lobe. Bronchoalveolar lavage of the apical segment of the right upper lobe tested negative for malignancy or infection. Multiple transbronchial lung biopsies from the apical segment of the right upper lobe were pathologically examined and showed an exudate of fibrin and neutrophils and reactive respiratory type of epithelium [Figure 2]. No fibromyxoid masses, histiocytes, or evidence of malignancy was identified. The pathological diagnosis was consistent with organizing pneumonia.

The patient was administered 40 mg of daily prednisone for 1 month, which was afterward tapered over 3 months. He completely recovered 1 month after hospital discharge. A follow-up chest CT, 1 month after hospital discharge, revealed near-complete resolution of the right upper lobe lesion, with minimal residual scarring [arrow in Figure 3]. The gastric band was adjusted to prevent future aspiration incidents, and the patient was counseled to quit smoking.

Discussion

The presented case highlights a few important observations. First, aspiration-related organizing pneumonia is a potential long-term complication of LAGB. Second, organizing pneumonia may radiologically mimic lung cancer, and therefore, presents a diagnostic challenge. Finally, aspiration pneumonia may occur in nondependent lung segments.

Several studies have reported long-term pulmonary complications following LAGB, the most common of which are aspiration pneumonia, lung abscess, and empyema.^[5,6] In most cases, the complications following LABG manifest 6 months to 3 years after gastric banding.^[4,5,7] Interestingly, our patient developed organizing pneumonia 12 years after LAGB, experiencing nocturnal GERD due to a tight gastric band. Previously examined patients with LABG-related aspiration pneumonia also reported GERD symptoms.^[4-7] However, aspiration pneumonia rarely can be diagnosed in the absence of significant symptoms and when it is due to occult aspiration.^[8]

The clinical presentation of the current case was suggestive of acute community-acquired pneumonia. However, the history of LAGB and GERD raised the suspicion of aspiration pneumonia. On CT, aspiration pneumonia manifests as tracheobronchial endoluminal opacities, bronchial wall thickening, centrilobular nodules, tree-in-bud pattern, and peribronchiolar ground-glass or consolidative opacities.^[9] The distribution of lung abnormalities after aspiration is gravity-dependent. The abnormalities are typically located in the lower lobes when occurring in the erect position. In the supine patient, aspiration pneumonitis usually

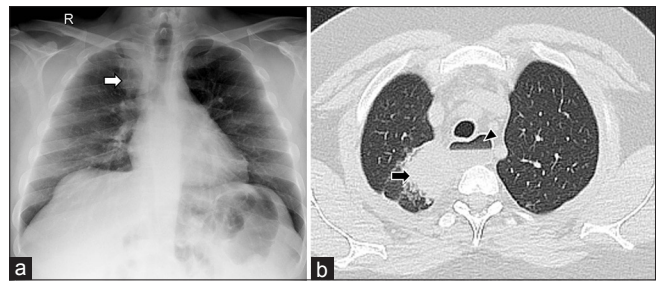


Figure 1: (a) Initial chest X-ray showed right apical lung opacity (arrow). (b) Same-date high-resolution chest computed tomography showing that the lesion is mass like and is located in the apical segment of the right upper lobe (arrow). The computed tomography also showed a dilated esophagus with a luminal fluid level (arrowhead)

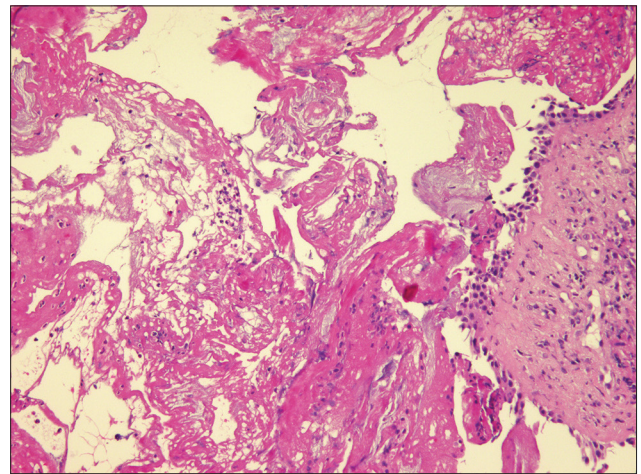


Figure 2: Organizing pneumonia: Fibrin exudate and neutrophils (left) and reactive respiratory type epithelium (right), H and E stain, ×200

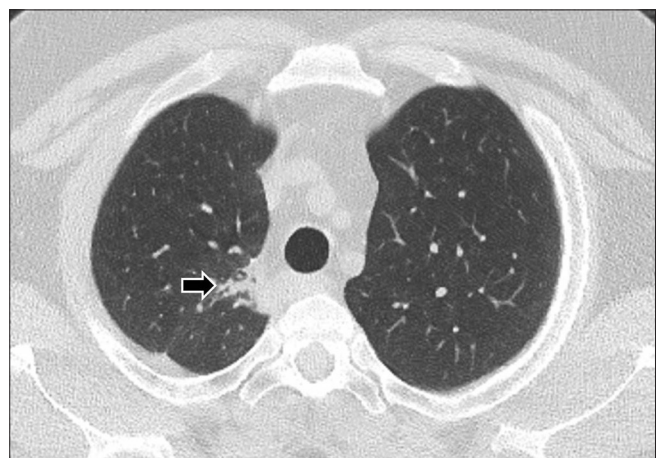


Figure 3: One-month follow-up chest computed tomography showing near-complete resolution of the right upper lobe abnormality and minimal residual scarring (arrow)

involves the superior segments of the lower and posterior segments of the upper lobes.^[9] Chest CT in the present case showed a solitary lung mass, which is atypical of aspiration pneumonitis. Similar to our case, Hu *et al.* described three cases of a solitary lung mass due to aspiration pneumonia that simulated lung cancer.^[8] The patients reported by Hu *et al.* were

of older age, and two had no GERD symptoms. Interestingly, all three patients had masses on imaging examinations, cavitory in two cases and speculated in the third patient. More so, the masses were located in nondependent lung portions.

We performed bronchoscopy because of the worrisome radiological finding, the patient's smoking history, and the lack of clinical improvements despite antibiotic treatment. Histopathological evaluation of the biopsied right upper lobe mass indicated organizing pneumonia, which is a rare and nonspecific inflammatory condition that is idiopathic or occurs secondary to other diseases.^[10] Aspiration pneumonitis is a well-described and less-recognized cause of organizing pneumonia.^[8,10,11] Organizing pneumonia usually has subacute or chronic nonspecific manifestations.^[12] However, in this case, the clinical presentation was relatively acute which may indicate an earlier course.

Pathological confirmation of organizing pneumonia depends on the finding of granulation tissue buds progressing from fibrin exudates to loose collagen with fibroblasts in the distal air spaces.^[13] The lesions occur predominantly within the alveolar spaces and bronchiolar lumen.^[13] Therefore, surgical lung biopsy through video-assisted thoracoscopy or open lung biopsy is recommended to obtain adequate lung tissue for a definitive diagnosis.^[12] However, in some rare cases, bronchoscopic biopsy is sufficient to diagnose patients with typical clinical and radiological features.^[12,14] In the current case, the pathological findings of fibrin exudates within the bronchiolar lumen with neutrophilic infiltrates suggested organizing pneumonia. The absence of the typical granulation tissue buds may be related to the earlier course of presentation or the lack of adequate alveolar material in the biopsy specimen. Our diagnosis of aspiration-related organizing pneumonia was supported by the clinical presentation, absence of alternative diagnoses on histopathological examination, and the patient's dramatic response to corticosteroids. Thus, surgical biopsy was not required despite the unusual radiological findings.

Conclusion

Patients with LAGB should be evaluated and have proper pulmonology assessment if they develop respiratory symptoms. More instances of aspiration-related organizing pneumonia after LAGB may be seen in the future as an increasing number of people undergo bariatric surgery. The atypical radiological appearance of the aspiration pneumonia may pose a diagnostic challenge, and clinicians' awareness regarding such an entity is needed to avoid unnecessary intervention.

Financial support and sponsorship

Nil.

Conflicts of interest

There are no conflicts of interest.

References

1. World Health Organization. Obesity and Overweight; 2015. Available from: <http://www.who.int/mediacentre/factsheets/fs311/en/>. [Last accessed on 2016 Feb 20].
2. Colquitt JL, Pickett K, Loveman E, Frampton GK. Surgery for weight loss in adults. *Cochrane Database Syst Rev* 2014;8:CD003641.
3. Buchwald H, Oien DM. Metabolic/bariatric surgery worldwide 2011. *Obes Surg* 2013;23:427-36.
4. Alamoudi OS. Long-term pulmonary complications after laparoscopic adjustable gastric banding. *Obes Surg* 2006;16:1685-8.
5. Avriel A, Warner E, Avinoach E, Avnon LS, Shteinberg M, Shteinberg D, *et al.* Major respiratory adverse events after laparoscopic gastric banding surgery for morbid obesity. *Respir Med* 2012;106:1192-8.
6. Krassas A, Mallios D, Boulia S, Kakaris S. Thoracic empyema after laparoscopic adjustable gastric banding. A rare complication. *Obes Surg* 2010;20:1459-61.
7. Jalota L, Oluwasanjo A, Alweis R. Recurrent aspiration pneumonia after laparoscopic adjustable gastric banding for obesity surgery. *J Community Hosp Intern Med Perspect* 2014;4:24461 - <http://dx.doi.org/10.3402/jchimp.v4.24461>.
8. Hu X, Yi ES, Ryu JH. Solitary lung masses due to occult aspiration. *Am J Med* 2015;128:655-8.
9. Franquet T, Giménez A, Rosón N, Torrubia S, Sabaté JM, Pérez C. Aspiration diseases: Findings, pitfalls, and differential diagnosis. *Radiographics* 2000;20:673-85.
10. Kligerman SJ, Franks TJ, Galvin JR. From the radiologic pathology archives: Organization and fibrosis as a response to lung injury in diffuse alveolar damage, organizing pneumonia, and acute fibrinous and organizing pneumonia. *Radiographics* 2013;33:1951-75.
11. Prather AD, Smith TR, Poletto DM, Tavora F, Chung JH, Nallamshetty L, *et al.* Aspiration-related lung diseases. *J Thorac Imaging* 2014;29:304-9.
12. Bradley B, Branley HM, Egan JJ, Greaves MS, Hansell DM, Harrison NK, *et al.* Interstitial lung disease guideline: The British Thoracic Society in collaboration with the Thoracic Society of Australia and New Zealand and the Irish Thoracic Society. *Thorax* 2008;63 Suppl 5:v1-58.
13. Cordier JF. Organising pneumonia. *Thorax* 2000;55:318-28.
14. Poletti V, Cazzato S, Minicuci N, Zompatori M, Burzi M, Schiattone ML. The diagnostic value of bronchoalveolar lavage and transbronchial lung biopsy in cryptogenic organizing pneumonia. *Eur Respir J* 1996;9:2513-6.