

# Clinical and Radiographic Evaluation of Four Different Pulpotomy Agents in Primary Molars: A Longitudinal Study

<sup>1</sup>B Sunitha, <sup>2</sup>Ravindar Puppala, <sup>3</sup>Balaji Kethineni, <sup>4</sup>Manoj K Mallela, <sup>5</sup>Ravigna Peddi, <sup>6</sup>P Tarasingh

## ABSTRACT

**Background:** The medicament formocresol (FC) used for pulpotomy in primary teeth has great concerns regarding its toxicity due to one of its constituent formaldehyde which acts by tissue fixation. Therefore, new medicaments were introduced which claimed preservation and regeneration of pulp.

**Aim:** The present study is aimed to compare and evaluate the clinical and radiographic success of FC, pulpotec, mineral trioxide aggregate (MTA), and emdogain (EMD) as pulpotomy medicaments in human primary molars.

**Design:** A sample of 21 patients with 84 teeth were selected. All the patients have at least four teeth eligible for pulpotomy according to selection criteria. In each mouth, the teeth selected were randomly allocated into four groups with 21 each.

**Results:** After 24 months of follow-up, the clinical success rates were FC (94%), pulpotec (94%), MTA (100%), and EMD (83%) and radiographically FC (88%), pulpotec (83%), MTA (94%), and EMD (72%), which were statistically not significant ( $p \geq 0.05$ ).

**Conclusion:** The outcome of this study demonstrates MTA has a high success rate compared with FC, pulpotec, and EMD as pulpotomy agent. In addition, MTA, pulpotec, and EMD can be considered as alternatives to FC as pulpotomy agent.

**Keywords:** Emdogain, Mineral trioxide aggregate, Pulpotec, Pulpotomy.

**How to cite this article:** Sunitha B, Puppala R, Kethineni B, Mallela MK, Peddi R, Tarasingh P. Clinical and Radiographic Evaluation of Four Different Pulpotomy Agents in Primary Molars: A Longitudinal Study. *Int J Clin Pediatr Dent* 2017;10(3):240-244.

**Source of support:** Nil

**Conflict of interest:** None

## INTRODUCTION

Pediatric endodontics, an ever-advancing field, always needs to evaluate the existing and upcoming materials

to find better biologic alternatives. Thus the future clinicians will have at their disposal novel therapeutic approaches for children and adolescents. Vital pulpotomy process using FC has been in practice since decades due to its simplicity and good prognosis.<sup>1</sup> However, many studies showed concern about the use of FC in humans due to its toxicity and the International Agency for Research on Cancer has classified formaldehyde as carcinogenic to human beings.<sup>2</sup> This raised a need for an alternate pulpotomy medicament.<sup>3</sup> Since then, a wide range of materials have been used over the years to replace FC.

Pulpotec is a medicament to perform pulpotomy in deciduous molars which is a radiopaque, nonresorbable paste. Its powder consists of polyoxymethylene, iodoform, and zinc, and liquid consists of dexamethasone, formaldehyde, phenol, guaiacol. Many clinical trials have shown that pulpotec by its antiseptic, hemostatic, anesthetic, antimicrobial, and anti-inflammatory actions and with the advantage of having clinical success even in cases with a little residual blood in the pulp chamber can be used as a pulpotomy medicament.<sup>4-6</sup>

Mineral trioxide aggregate (MTA) was demonstrated as a successful pulpotomy medicament and as an appropriate alternative to FC because it consistently showed better results both clinically and radiographically.<sup>7-10</sup> Recently, EMD has been introduced as a pulpotomy material. Enamel matrix proteins, mainly "amelogenins," are secreted by Hertwig's epithelial root sheath during tooth development and induce a cellular cementum formation, capable of stimulating periodontal ligament cell proliferation sooner than gingival fibroblasts and bone cells.<sup>11</sup> In animal studies EMD has been successfully used as a pulpotomy agent in noninfected teeth.<sup>12</sup> Literature shows comparative studies between the medicaments FC vs EMD, FC vs MTA, MTA vs EMD. But comparative studies using all four medicaments in randomized clinical trial are not available. Therefore, the uniqueness of the present study is FC, pulpotec, MTA, and emdogain, which were used as a pulpotomy medicament in the primary molars and its efficacy was observed both clinically and radiographically over a period of 2 years.

<sup>1,6</sup>Assistant Professor, <sup>2</sup>Professor and Head, <sup>3,4</sup>Professor  
<sup>5</sup>Associate Professor

<sup>1-5</sup>Department of Pedodontics and Preventive Dentistry, Sri Venkata Sai Institute of Dental Sciences, Mahabubnagar Telangana, India

<sup>6</sup>Department of Pedodontics and Preventive Dentistry Government Dental College, Hyderabad, Telangana, India

**Corresponding Author:** B Sunitha, Assistant Professor Department of Pedodontics and Preventive Dentistry, Sri Venkata Sai Institute of Dental Sciences, Mahabubnagar, Telangana, India Phone: +919908806858, e-mail: drsunitha3@yahoo.com

## MATERIALS AND METHODS

A total of 21 children (8 boys and 13 girls) were selected among patients attending the Pedodontics Dental Clinic of Sri Venkat Sai Institute of Dental Sciences, Mahbubnagar in Telangana state of India. Children who are cooperative with good general health and had at least four primary molars requiring pulpotomy were selected. A sample of 84 teeth was randomly allocated into four groups: Group I (FC), Group II (pulpotec), Group III MTA, and Group IV EMD with 21 teeth to each group as shown in Table 1 (sample distribution). Teeth were selected according to the following criteria: Presence of deep carious lesions (radiographically, approximating the pulp); large pulp exposure during caries excavation. The study was conducted from November 2012 to March 2015.

The ethical clearance was obtained from the Institutional Ethical Committee. An informed consent was taken from the parent prior to the procedure. After profound local anesthesia, the tooth was isolated with a rubber dam. Removal of caries was done using sterile spoon excavator and roof of the pulp chamber was removed with a high-speed no. 330 sterile bur. The coronal pulp tissue was amputated by using a sterile sharp spoon excavator. Post amputation bleeding was controlled by placing sterile saline wet cotton pellets over radicular pulp stumps, waited for 5 minutes for hemostasis. If hemorrhage continued, the patient was excluded from the study and treated with appropriate treatment. Pulp dressings were applied as follows:

- *Group I (FC group):* A sterile cotton pellet moistened with FC (diluted at 5:1 ratio) was placed on the amputated pulp for 5 minutes, and pulp stumps were covered with zinc oxide eugenol cement, above which intermediate restorative material (IRM) was placed as temporary restoration.
- *Group II (pulpotec group):* The pulp stumps were covered with pulpotec paste (Products Dentaire – PD, Switzerland) comprised of powder and liquid mixed, above which IRM was placed.
- *Group III (MTA group):* The pulp stumps were covered with an MTA paste comprised of MTA powder (ProRoot MTA; Dentsply Tulsa Dental, Tulsa, OK) mixed at a 3:1 ratio with sterile saline, above which IRM was placed as temporary restoration.
- *Group IV (EMD group):* The canal orifices were dressed with EMD gel (Straumann Basel, Switzerland) above which the IRM was placed as a temporary restoration. Final restorations were performed with stainless steel crowns. The patients were recalled for clinical and radiographic examinations at 6 months interval for a follow-up period of 2 years.<sup>13,14</sup> Teeth were considered to be successful clinically when there is absence of pain, swelling or abscess, sinus tract opening, mobility, pain on percussion and radiographic absence of pathological root resorption, widening of periodontal space, bifurcation radiolucency, and periapical radiolucency.

A sample of 18 children (8 boys and 10 girls) and 72 teeth were available for follow-up evaluations. (Three children did not come for follow-up appointment at 6 months and were excluded from study.) Statistical analysis of the differences in treatment outcomes was performed by using the Chi-square test.

## RESULTS

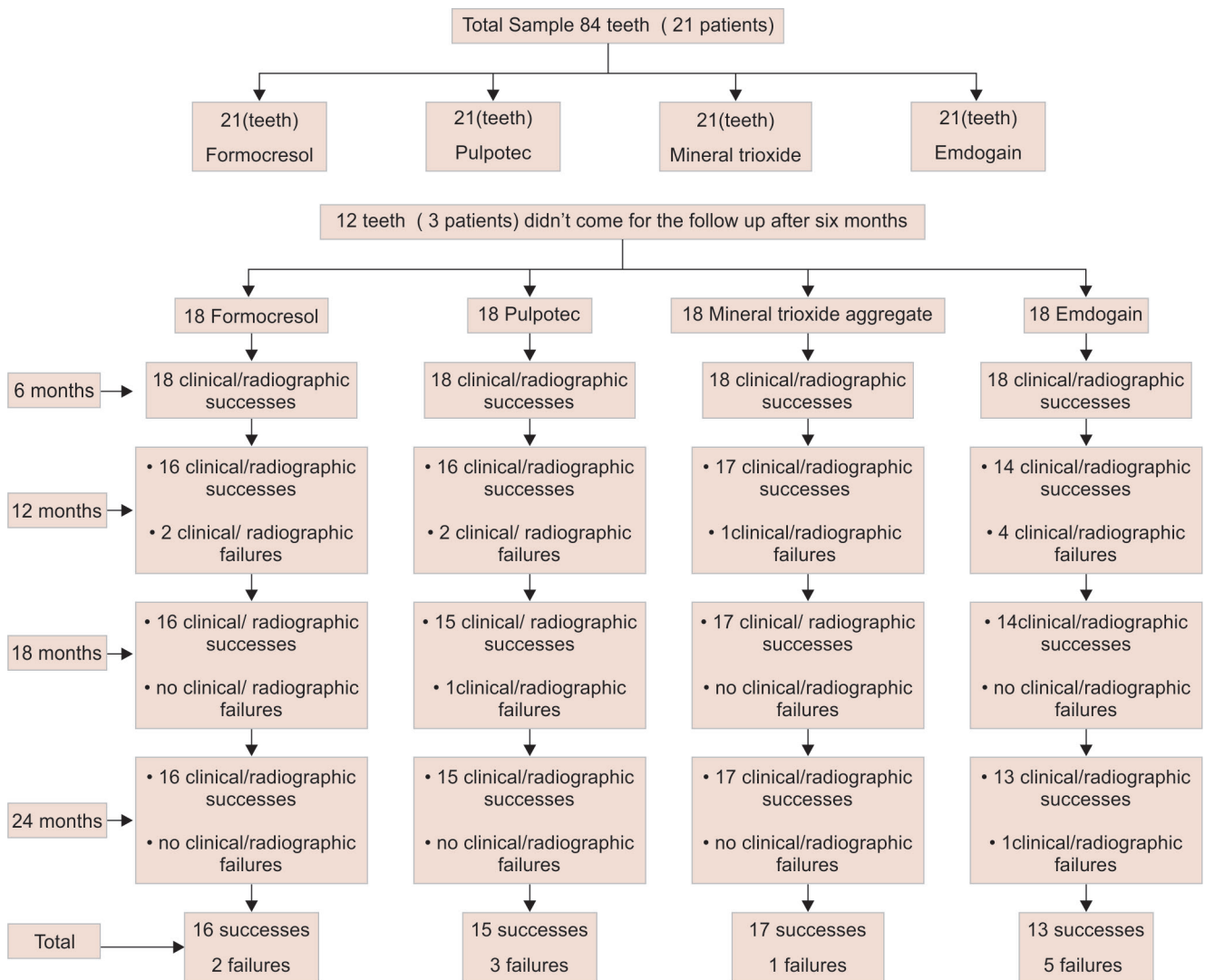
The treatment results for the four groups at each follow-up periods are presented in Flow Chart 1. Radiographic failures were significantly higher than the clinical failures ( $p < 0.05$ ). At the 6th month follow-up examination, all teeth were rated successful both clinically and radiographically. At 12 months follow-up, two failures were observed in FC and pulpotec groups, one in MTA group and four failures in EMD groups. At 18 months follow-up, one failure was observed in pulpotec group and no failures in the other three groups. At 24 months follow-up, one additional failure was seen in EMD group. The overall failures observed were two in FC group, three in pulpotec group, one in MTA group, and five in EMD group.

By the end of 24 months follow-up, the overall failure clinically was five. One in FC group, one in pulpotec group and three in EMD, of which one showed swelling and two showed sinus tract (Table 1). Radiographic appearance of the pulp in the 72 pulpotomized teeth is shown in Table 2. The most frequently observed radiographic finding was external resorption followed by pulp canal obliteration and internal resorption. The clinical success rates of FC and pulpotec were 94.4%, EMD was 83.3%, and MTA was 100% (Table 3). Whereas the overall success rates (as shown in Table 4 and Graph 1) were

**Table 1:** Evaluation of clinical failures

	No pathology	Presence of pain	Swelling	Sinus tract opening	Presence of mobility	Total
Formocresol	17	–	1	–	–	18
Pulpotec	17	–	1	–	–	18
Mineral trioxide aggregate	18	–	–	–	–	18
Emdogain	15	–	1	2	–	18

**Flow Chart 1:** Sample follow-up for 2 years of period



**Table 2:** Evaluation of radiographic failures

	No pathology	Pulp canal obliteration	Internal resorption	External resorption	Total
FC	16	1	–	2	18
Pulpotec	15	3	1	3	18
MTA	17	1	–	1	18
Emdogain	14	4	2	4	18

88.8% for FC, 83.3% for pulpotec, 94.4% for MTA and 72% for EMD, which was statistically not significant ( $p > 0.05$ ).

## DISCUSSION

Pulpotec has an advantage of having clinical success even in cases with a little residual blood in the pulp chamber when used as a pulpotomy medicament.<sup>5,6</sup> The results of pulpotec are in agreement with Donskaya and Dedeyan<sup>5</sup> in their clinical trials using pulpotec as pulpotomy medicament and reported easiness, simplicity in using pulpotec. The paste hardens quickly after mixing of ingredients, providing optimal conditions for final restoration with its

**Table 3:** Clinical evaluation of four pulpotomy groups during follow-up period for 2 years

Groups	6 months	12 months	18 months	24 months	p-value
FC	18 (100)	18 (100)	17 (94)	17 (94)	NS
Pulpotec	18 (100)	18 (100)	17 (94)	17 (94)	NS
MTA	18 (100)	18 (100)	18 (100)	18 (100)	NS
EMD	18 (100)	17 (94)	15 (83)	15 (83)	NS

Values given in parenthesis are success percentage; p value is NS: Not significant

added hemostatic and fixative properties.<sup>4-6</sup> However, in our study, pulpotec application was simple, time-saving, and affordable.

A study conducted by Holan et al<sup>9</sup> comparing the clinical and radiographic success rates between FC and MTA pulpotomy in primary molars showed success rates of 97% for MTA and 83% for FC. Ainehchi et al<sup>7</sup> conducted a randomized control trial of MTA and FC for pulpotomy in primary teeth and found higher success rates of MTA when compared with FC. A similar result was seen in our study with 94% success rate of MTA.

**Table 4:** Radiographic evaluation of four pulpotomy groups during follow-up period for 2 years

Groups	6 months	12 months	18 months	24 months	p-value
FC	18 (100)	16 (88.8)	16 (88.8)	16 (88.8)	NS
Pulpotec	18 (100)	16 (88.8)	15 (83)	15 (83)	NS
MTA	18 (100)	17 (94)	17 (94)	17 (94)	NS
EMD	18 (100)	14 (77.7)	14 (77.7)	13 (72)	NS

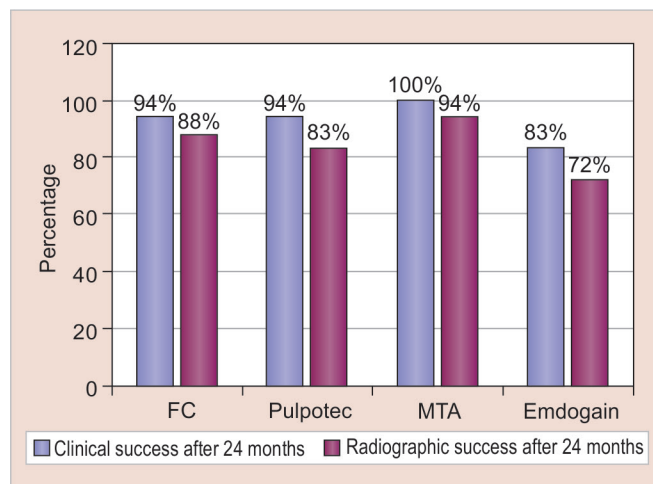
Values given in parenthesis are success percentage; p-value is NS: Not significant

This may be due to its property of becoming hard in the presence of moisture, which in turn evoked a better sealing of pulp chamber. Therefore, MTA can be used in areas in which it is virtually impossible to achieve a totally dry environment, and MTA is a promising material with an expanding foundation of research. It is gaining interest as pulpotomy medicament because of its excellent sealability, biocompatibility, and dentinogenic properties.

The EMD derivative obtained from developing porcine teeth has been approved by the US Food and Drug Administration and marketed under the trade name "EMDOGAIN." It has been successfully used as a pulpotomy agent in noninfected teeth in animal studies. This material is a viscous gel consisting of enamel-derived proteins in a polypropylene liquid and of 90% amelogenins, rest are proline-rich nonamelogenins, tuftelin, tuft protein, serum proteins, ameloblastin, and amelin.<sup>13,14</sup>

The common radiographic failure in the present study (Table 5) was interradiolucency and internal resorption found in 4 out of 21 cases in EMD group during 6 to 12-month interval. In the EMD group, the clinical follow-up at the 6th month revealed no signs of clinical failure. However, at the end of 12th month, one tooth reported with swelling, two teeth showed sinus tract opening, and the same teeth showed furcation radiolucency. These three teeth were treated with pulpectomy. The clinical success with EMD at 24 months was 93.3% and radiographic success rate was 73.3%. The findings were similar to that of Sabbarini et al.<sup>15</sup>

The higher failure rate in EMD might be due to handling properties of the material which is available in a



**Graph 1:** Comparison of overall success rates of four groups both clinically and radiographically after 24 months

gel form and standardization of the quantity, which was difficult during application over the vital pulp tissue. Another disadvantage with EMD material is that care should be taken to prevent the gel to flow away from the amputation site while placing of temporary material (IRM). However, a significant disadvantage was the entire material has to be used up within 2 hours or the material loses its efficacy. Remaining quantity was discarded if not used in the proper time, which greatly reduces the cost-effectiveness of the material. The clinical and radiographic assessment of EMD pulpotomized teeth in this study offers evidence that EMD is a promising material that may be as good as other pulpotomy agents. Further refinement of the delivery system is needed to ensure that EMD can be developed as an agent for predictable and cost-effective in preservation of vitality of radicular pulp.

Failure of pulpotomy in primary molars was attributed to several factors, one of which was erroneous diagnosis of a chronically inflamed pulp as noninflamed and noninfected.<sup>16</sup> Pulpotomy agents that require a healing process may not be applicable to all cariously involved primary teeth. More accurate diagnostic tests may be required to choose those teeth with healthy radicular pulps. Many alternatives have been proposed to maintain the radicular

**Table 5:** Distribution of the sample

Evaluation intervals (months)	Total teeth	Formocresol		Pulpotec			Mineral trioxide aggregate			Emdogain		
		Lower primary first molars	Lower primary second molar	Lower primary first molars	Lower primary second molar	Lower primary first molars	Lower primary second molar	Lower primary first molars	Lower primary second molar	Lower primary first molars	Lower primary second molar	
3	21	10	11	10	11	10	11	10	11	11	10	
6	18	9	9	8	10	8	10	8	10	10	8	
12	18	9	9	8	10	8	10	8	10	10	8	
18	18	9	9	8	10	8	10	8	10	10	8	
24	18	9	9	8	10	8	10	8	10	10	8	

pulp vitality among which MTA and pulpotec are gaining interest in recent years. The regenerative potential of EMD has also proved to be advantageous in vital pulp therapy procedures of primary teeth with encouraging results, although based on the few supporting studies. In the light of present findings of this study as well as documentary evidence, it appears that Pulpotec, MTA, and EMD can be acceptable alternatives to conventional FC pulpotomy procedure. Overall, MTA showed better success rate (94.4%) than pulpotec group (83.3%) and EMD group (72%). However, there is a need for further research to conclude the treatment outcome with histological collaboration, until tooth exfoliation.

## CONCLUSION

In cariously exposed primary molars, MTA could be used as a safe medicament for pulpotomy and could be a substitute for FC. Pulpotec and EMD used for covering the radicular pulp remnant after pulpotomy was proven to be promising alternatives as a pulp medicament. The study highlights on the biological agents like MTA and EMD that were useful for pulpotomy over formaldehyde.

## REFERENCES

1. Patchett CL, Srinivasan V, Waterhouse PJ. Is there life after Buckley's formocresol? Part II – Development of a protocol for the management of extensive caries in the primary molar. *Int J Paediatr Dent* 2006 May;16(3):199-206.
2. Milnes AR. Is formocresol obsolete? A fresh look at the evidence concerning safety issues. *J Endodont* 2008 July;34(7):S40-S46.
3. Saltzman B, Sigal M, Clokie C, Rukavina J, Titley K, Kulkarni GV. Assessment of a novel alternative to conventional formocresol-zinc oxide eugenol pulpotomy for the treatment of pulpally involved human primary teeth: diode laser-mineral trioxide aggregate pulpotomy. *Int J Paediatr Dent* 2005 Nov;15(6):437-447.
4. Melekhov, SV.; Tairov, VV. Results in the treatment of pulpitis in teeth by the pulpotomy method employing pulpotec. *Proceedings of the Moscow meeting of the organisation of dental management, economics and accounting, Krasnodar.* 2005. p. 409-411.
5. Donskaya, IP.; Dedeyan, SA. Treatment of odontitis in pediatric by method of vital amputation with use of 'Pulpotec'. *Transactions of the VIII Congress of the Dentists Association of Russia, Moscow.* 2003. p. 287-288.
6. Melekhov SV, Kapirulina OV. Treatment of pulpitis in multirooted teeth by the pulpotomy method with the use of pulpotec. *Dentistry Today* 2004;1:29.
7. Aeinehchi M, Dadvand S, Fayazi S, Bayat-Movahed S. Randomized controlled trial of mineral trioxide aggregate and formocresol for pulpotomy in primary molar teeth. *Int Endod J* 2007 Apr;40(4):261-267.
8. Jabbarifar SE, Khademi AA, Ghasemi D. Success rate of formocresol pulpotomy versus mineral trioxide aggregate in human primary molar tooth. *J Res Med Sci* 2004;9(6):304-307.
9. Holan G, Eidelman E, Fuks AB. Long-term evaluation of pulpotomy in primary molars using mineral trioxide aggregate or formocresol. *Pediatr Dent* 2005 Mar-Apr;27(2):129-136.
10. Farsi N, Alamoundi N, Balto K, Mushayt A. Success of mineral trioxide aggregate in pulpotomized primary molars. *J Clin Pediatr Dent* 2005 Jul;29(4):307-311.
11. Nakashima M. Dentin induction by implants of autolyzed antigen-extracted allogenic dentin on amputated pulps of dogs. *Endod Dent Traumatol* 1989 Dec;5(6):279-286.
12. Nakamura Y, Hammarström L, Matsumoto K, Lyngstadaas SP. The induction of reparative dentine by enamel proteins. *Int Endod J* 2002 May;35(5):407-417.
13. Hammarström L. Enamel matrix, cementum development and regeneration. *J Clin Periodontol* 1997 Sep;24(9 Pt 2):658-668.
14. Kalaskar RR, Damle SG. Comparative evaluation of lyophilized freeze dried platelet derived preparation with calcium hydroxide as pulpotomy agents in primary molars. *J Indian Soc Pedod Prev Dent* 2004 Mar;22(1):24-29.
15. Sabbarini J, Mohammed A, Wahba N, El-Meligy O, Dean J. Comparison of enamel matrix derivative versus formocresol as pulpotomy agents in the primary dentition. *J Endod* 2008 Mar;34(3):284-287.
16. Mejäre I. Pulpotomy of primary molar with coronal or total pulpitis using formocresol technique. *Scand J Dent Res* 1979 Jun;87(3):208-216.