

Holoprosencephaly with Clefts: Data of 85 Patients, Treatment and Outcome: Part 1: History, Subdivisions, and Data on 85 Holoprosencephalic Cleft Patients

Engela M. Honey^{1,2}, Kurt W. Bütow^{1,3}, Roger Arthur Zwahlen⁴

¹Facial Cleft Deformity Clinic, Department of Maxillo-Facial and Oral Surgery, University of Pretoria, ²Department of Biochemistry, Genetics and Microbiology, Faculty of Natural and Agricultural Science, University of Pretoria, ³Suite A2 Maxillo-Facial Surgery, The Life Wilgers Hospital, Pretoria, South Africa,

⁴Private Practice in Oral and Maxillofacial Surgery, Grand-Places 16, Fribourg, Switzerland

Abstract

Context: Cleft patients with Holoprosencephaly (HPE) constitute a controversy due to a variable facial appearance. HPE appearance varies from only a columella to a prolabium-premaxilla complex agenesis up to a common unilateral or bilateral cleft lip and palate with a single central incisor, various brain deformities, and/or even normal brain development. It is challenging to designate such various appearances, to understand their etiopathogenesis, and to choose the most appropriate management. Literature was reviewed for diagnostic criteria, pregnancy history, clinical findings, brain development, survival rate, initial perioperative management, and postsurgical midfacial growth in cleft patients with HPE. The findings were compared with a clinical database of 85 cleft patients with HPE at the Department of Maxillofacial and Oral Surgery, University of Pretoria. **Aims of Part 1:** The aim of the study is to overcome disparities widely existing among clinicians regarding definitive diagnostic criteria, especially in cases with a common appearance of a uni- or bilateral cleft lip alveolus or cleft lip, alveolus and palate deformity, and cases presenting facial structural agenesis. **Materials and Methods:** A literature search related to diagnostic criteria was compared to results of a cleft HPE database from a single tertiary institution. **Results:** HPE cleft cases can be allocated to one of the following subdivisions: (1) columella complex agenesis (Ag-Colum), (2) prolabium-premaxilla-columella complex agenesis in cleft lip-alveolus deformities (Ag-CLA), (3) prolabium-premaxilla-columella agenesis in cases with complete cleft lip alveolus palate (Ag-CLAP), and (4) standard type (holoprosencephaly in patients with a standard cleft) with uni- or bilateral CLA or CLAP, hard and soft palate cleft (hPsP), and atrophic premaxillae, with or without single central incisor. Further, incidence, variation in brain development, and appearances in HPE cleft patients of different races and gender, epilepsy, and early death are discussed. **Conclusion:** This paper adds new data and facts to the existing literature related to cleft lip and palate patients suffering from HPE.

Keywords: Agnesis of cleft lip-alveolus, agnesis of prolabium-premaxilla, holoprosencephalus, holoprosencephaly, lobar deformities

INTRODUCTION

Cleft patients suffering from holoprosencephalus (HPE) may constitute a controversy with regard to their treatment due to their wide variability in facial appearances and clinical outcomes. Craniofacial as well as neuropathological pictures range from most severe forms as cyclopia with or without proboscis and/or single nostril nose and alobar type HPE, respectively, over milder forms with cleft lip palate deformities, hypotelorism, flat nasal bridge, to microforms such as a single maxillary median incisor, and lacking interhemispheric fusion, respectively.^[1] A correlation between the severity of facial midline and cerebral defects according to the motto: “The face predicts the brain”^[2,3] though underlies a variability of up to 39%.^[4]

The first part of this publication series addresses two aspects. It reviews the neuropathology HPE in general, and based on a large database of cleft lip and palate patients affected by HPE (HPE-clefts) at the Department of Maxillofacial and Oral Surgery of the University of Pretoria and The Life Wilgers Hospital, Pretoria, South Africa, it analyses the designation HPE in cleft lip and palate patients.

Address for correspondence: Dr. Roger Arthur Zwahlen,
Private Practice in Oral and Maxillofacial Surgery, Grand-Places 16,
1700 Fribourg, Switzerland.
E-mail: rozwahlen@gmail.com

This is an open access journal, and articles are distributed under the terms of the Creative Commons Attribution-NonCommercial-ShareAlike 4.0 License, which allows others to remix, tweak, and build upon the work non-commercially, as long as appropriate credit is given and the new creations are licensed under the identical terms.

For reprints contact: reprints@medknow.com

How to cite this article: Honey EM, Bütow KW, Zwahlen RA. Holoprosencephaly with clefts: Data of 85 patients, treatment and outcome: Part 1: History, subdivisions, and data on 85 holoprosencephalic cleft patients. *Ann Maxillofac Surg* 2019;9:140-5.

Access this article online

Quick Response Code:



Website:
www.amsjournal.com

DOI:
10.4103/ams.ams_50_19

MATERIALS AND METHODS

A narrative literature review regarding general aspects of HPE was carried out, covering the period from 1951 to January 2019, reviewing the electronic database PubMed.

The following keywords were used: holoprosencephalus; holoprosencephaly; agenesis of maxillary lip; agenesis of columella; agenesis of premaxilla; and lobular deformities.

- #1 – (Holoprosencephalus) OR (Holoprosencephaly) OR (Agenesis) OR (Maxillary micrognathia) OR (Agenesis of mid-face)
- #2 – (profile) OR (morphology)
- #3 – (#1) and (#2).

Combined free-text terms with Boolean operators and truncation were applied. Restrictions were placed on the English language of publication. A librarian was previously consulted for the search strategy.

The obtained citations from PubMed were exported to the bibliographic management software EndNote® (Thomson Reuters; Carlsbad, CA, USA). After a thorough refinement of titles and abstracts, hard copies of pertinent articles were obtained. Further connate publications could be gained by manual investigation of their references. All data were entered into an Excel spreadsheet for comparison.

In addition, the overall cleft clinic database of the Department of Maxillofacial and Oral Surgery at the University of Pretoria was scoured for cleft palate cases with HPE-clefts. Based on their clinical picture and confirming computed tomography and/or magnetic resonance imaging, 85 HPE-clefts were ascertained, included, and allocated to four different subgroups. One patient with a single maxillary central incisor but without any other additional facial features nor brain involvement was excluded. In addition, clinical retrospective data related to gender and race distribution, epilepsy, and survival rate were compared with findings from literature.

RESULTS

Background

HPE actually is a developmental neuropathology resulting from an incomplete separation of the forebrain during early embryological development. It was first described by Kundrat, in 1882,^[5] who labeled it as arhinencephaly. Only since 1963, it has been referred to as holoprosencephaly by Demyer *et al.*^[6]

Not only its clinical spectrum but also its prevalence varies widely from 1/16,000–1/20,000^[7] to 1/1650–1/100,000^[4] in 24 selected series of live births, up to an estimated high of 1/250 in the first trimester abortions^[2,8,9] and 1/200–1/242 in a Japanese embryo examination.^[4]

HPE underlies a multifactorial etiology. Both environmental, hence epigenetic, and genetic factors have been described. Maternal diabetes, ethanol intake, cigarette smoking, retinoic acid, drugs affecting cholesterol biosynthesis pathways, as well as salicylate consumption have been

considered, although without evidence so far.^[10] Further, in recent years, viral vectors such as cytomegalovirus, toxoplasma, and rubella captured the attention.^[2] Folic acid supplementation, on the other hand, was found to be protective.^[11] Both single gene defects and chromosomal abnormalities have been described as causative genetic factors.^[12] To date, to a great extent, the cause remains unknown, leading to a “multiple-hit hypothesis” considering both epi- and genetic causes.^[13]

Gene mutations in sonic hedgehog: MIM# 600725; *ZIC2*: MIM# 603073; *SIX3*: MIM#603714; and *TGIF1*: MIM#602630 were identified in at least 25% of all cases among all investigated ethnicities.^[14-16] Recently, further gene mutations were discovered: *FGF8*: MIM# 612702 and *FGFR1*: MIM# 615465.^[17] To a minor degree, the following gene mutations are involved: *PTCH1*: MIM# 601309; *TDGF1*: MIM# 187395; *FOXH1*: MIM# 603621; *GLI2*: MIM# 165230; *DISP1* MIM#607502; *GAS1*: MIM#139185; *CDON*: MIM#608707; *NODAL*: MIM# 601265; *DLL*: MIM# 606582; and *STIL*: MIM#181590.^[18-23] Previously considered to be autosomal dominant HPE inheritance patterns with a variable penetrance, they recently have been reconsidered and determined as polygenic with multiple inheritance patterns. Determining a specific genetic etiology is important to provide genetic counseling and to estimate the recurrence risk in close relatives.

Common health issues in patients with HPE surviving infancy are epilepsy, electrolyte imbalances due to hypothalamic dysfunction resulting in diabetes insipidus, neurocognitive delay, and psychiatric disturbances such as anxiety and depression.^[24] Patients’ outcomes vary widely between spontaneous abortion and uncomplicated life due to the severity of involved general diseases.

Analysis of incidence, race, and gender of holoprosencephalus-clefts

The dataset of a cleft lip and palate clinic in Pretoria, Republic of South Africa, has been analyzed regarding the incidences of holoprosencephaly in cleft lip and palate patients (HPE-cleft). This database further has been subdivided according to races [Figure 1] and gender, respectively [Table 1].

Brain involvement in holoprosencephalus-clefts

HPE is classified as (1) alobar, with a complete or near-complete lack of midline separation and a single forebrain ventricle, (2) semilobar, with an incomplete interhemispheric fissure and a partial hemispheric separation, (3) lobar with apart from the frontal neocortex a complete interhemispheric fissure, and (4) middle interhemispheric variant or syntelencephaly, with an interhemispheric fissure but fused central cerebral structures.^[25] The latter is also described as an HPE subtype, somewhat in

Table 1: Gender distribution

Total number of patients (%)	Male	Female
85 (100%)	27 (31.8%)	58 (68.2%)

between the semilobar and lobar types.^[10] Figure 2 highlights the distribution of the various types among the cleft lip and palate database.

Subdivision of holoprosencephalus with clefts

Facial deformities in HPE patients range from (1) aplasia or hypoplasia of the anterior nasal spine, to a (2) reduced or absent nasofrontal angle, a (3) hypoplastic premaxilla, to a (4) hypoplastic nose, and/or flattened alae and nasal tip. Furthermore, a poorly developed philtrum, medial or bilateral cleft lip and palate deformities,^[26] or a median cleft with a premaxilla-prolabium-columella agenesis (Ag-Colum) can occur.^[27]

Due to their clinical features, HPE-Cleft patients can be allocated to four subdivisions: (1) Ag-Colum, (2) columella-lip-alveolus agenesis (Ag-CLA), (3) columella-lip-alveolus-palate, including hard and/or soft palate (Ag-CLAP), and (4) “standard” cleft lip and/or palate deformities (holoprosencephaly in patients with a standard cleft [HPE-Std-Cleft]) [Figure 3].

The three holoprosencephaly subdivisions with facial structural agenesis and clefts (Ag-HPE) may be classified as a specific group due to various agenesis and/or deformities of facial structures.

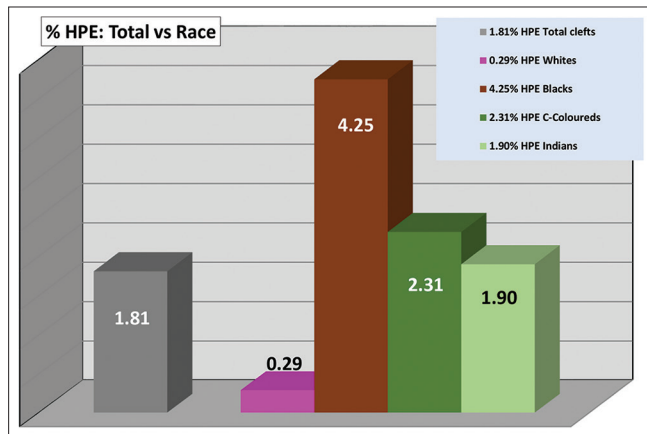


Figure 1: Total number of holoprosencephalus cleft cases and their race

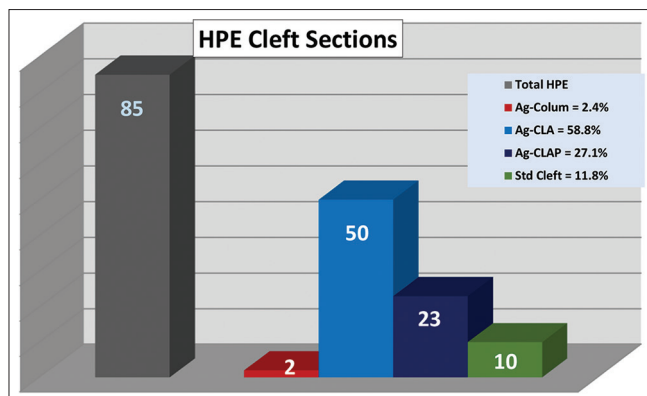


Figure 3: Holoprosencephalus cleft subdivisions

Holoprosencephaly with agenesis and/or deformities of facial structures

The common clinical feature in these three subdivisions is a nondevelopment of the external frontonasal process that occurs mostly together with alobar or semilobar brain deformities, the latter probably influenced by the internal frontonasal process.

Clinical features of the three subdivisions:

- a. Ag-Colum
These cases with only a agenesis of columella represent the mildest form of midfacial deformities [Figure 4].
- b. Agnesis of columella, prolabium, and premaxilla (Ag-CLA)
This subdivision was the largest among this database of cleft lip palate patients with HPE [Figure 5a-d].
- c. Agnesis of columella, prolabium, premaxilla with bilateral cleft palate (Ag-CLAP)
This subdivision represents the second largest group of HPE-cleft patients in this database [Figure 6a-c].

Holoprosencephaly in patients with a standard cleft

This fourth subdivision is considered a separate group. Within this group, four different HPE-Std-Cleft types were recorded [Table 2]. These HPE types show no agenesis of any midfacial structures, however, may show a normal or a wide, unilateral, or bilateral cleft. In this subdivision, a premaxilla always exists, however, with or without a single maxillary central incisor [Figure 7a and b].

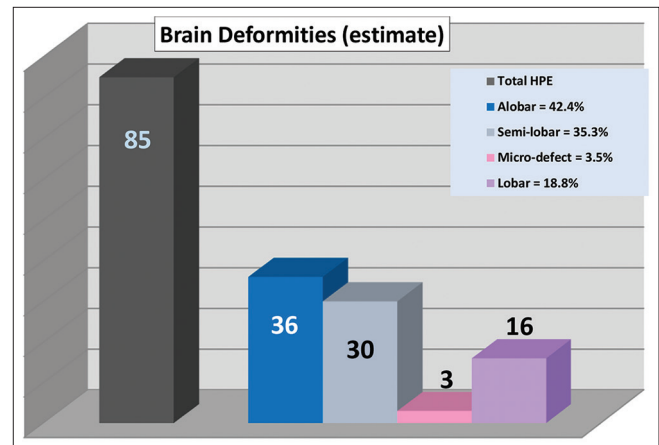


Figure 2: Graphic representation of the various brain deformities among the holoprosencephalus clefts

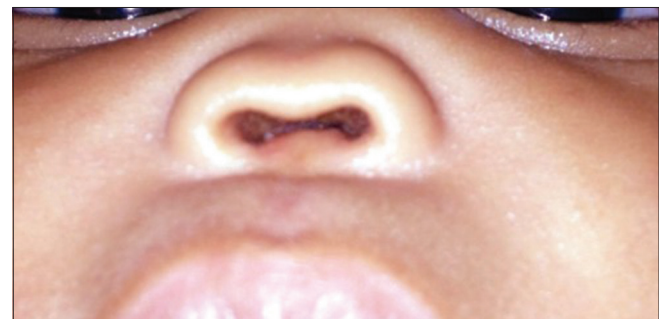


Figure 4: Agnesis of the columella

Epilepsy and death in holoprosencephalus-clefts

All subdivisions of HPE-cleft patients in this database were analyzed for epileptic seizures and deaths. Figure 8 highlights these results.

DISCUSSION

Compared to findings in literature, the overall incidence rate of HPE in this database was 1.81% among 4693 cleft patients, with the lowest of 0.29% among white and the highest of 4.25% among black patients [Figure 1]. This somewhat different incidence rate might arise because the count only started from the 3rd postnatal week onward and hence from the first date of visit in the cleft lip and palate outpatient clinic. In the light of the overall prevalence rate for clefts among the Northern South African population,^[28] the one for HPE-Clefts among the same population is 1:5666 in black South African and 1:250,000 in white South African patients. This discrepancy might be due to a regular attendance of pregnancy examinations or not; in case of an accidental HPE finding, medically approved abortion might occur.

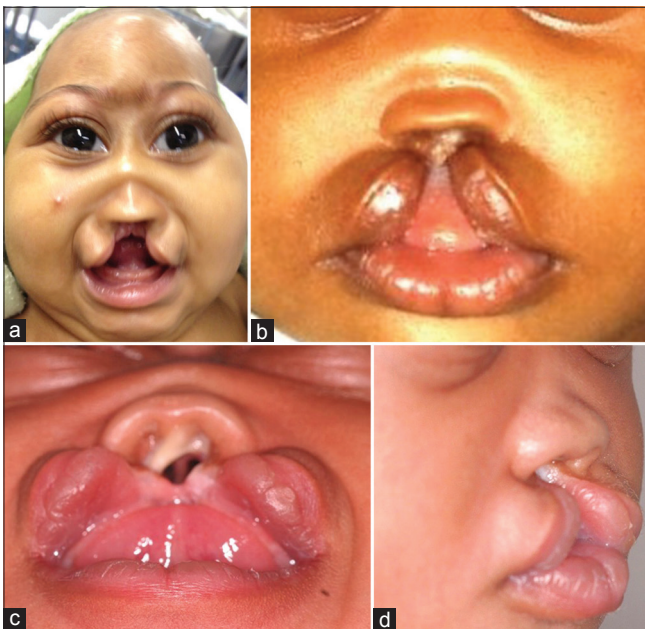

Figure 5: (a) Agnesis of a cleft-lip-alveolus, (b and c) narrow type of an agnesis of cleft-lip-alveolus, (d) oblique view of an agnesis of cleft-lip-alveolus

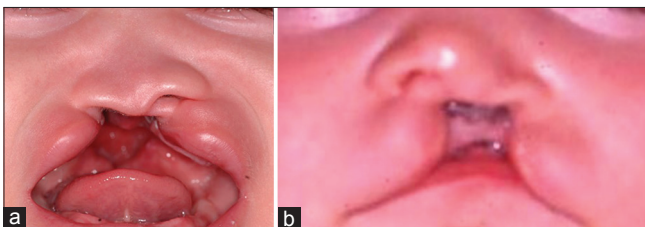


Figure 7: (a) Right unilateral cleft-lip-alveolus-palate in a holoprosencephaly in patients with a standard cleft patient, (b) left unilateral standard cleft in a holoprosencephaly in patients with a standard cleft patient with a feeding plate *in situ*

Related to gender predilection, females in South American countries are more prone to be affected by HPE compared to other studies.^[4] This database [Table 1] showed also a female predilection ratio of 68% compared to 32% of males.

Brain deformities among patients affected by HPE may range from the very frequent alobar to the semilobar and lobar, to the finally least common syntelencephaly type. Previously reported incidence rates of 40% for alobar, 43% for semilobar, and 17% for lobar^[29] have to be considered somewhat carefully, as in some studies, only alobar and lobar types were reported.^[30,31] In this database, the alobar type was most frequent with 42.4%, followed by the semilobar with 35.3% and finally, the lobar with 18.8%. No cases of syntelencephaly were in this database. The microdefect type of brain deformity with only mild or even no cerebral malformations associated with a single maxillary central incisor was only seen in three cases (3.5%).

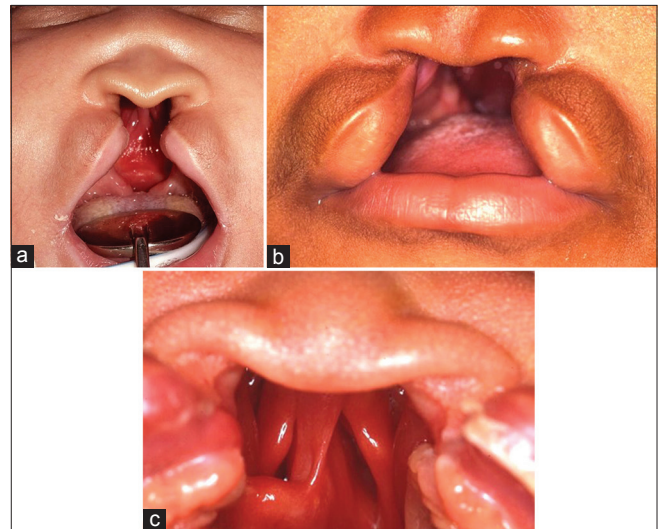


Figure 6: (a) Agnesis of cleft-lip-alveolus + palate, (b) wide variation of an agnesis of cleft-lip-alveolus + palate, (c) intraoral view of a case with agnesis of cleft-lip-alveolus + palate

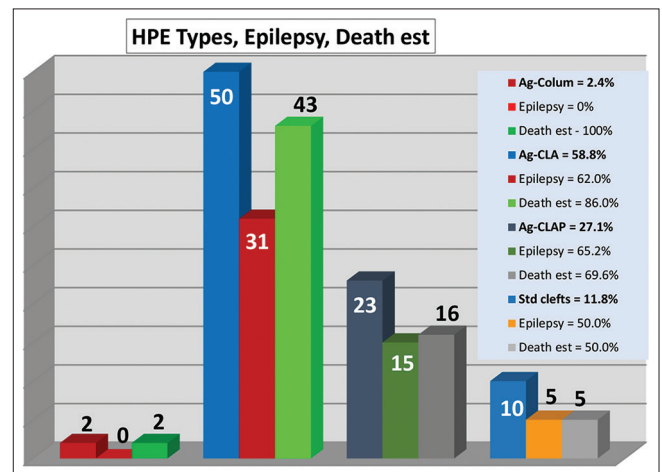


Figure 8: Graphic representation of the occurrence of epilepsy and death among the four subgroups

Table 2: “Standard” cleft types, hard palate soft palate (hPsP)

HPE-Std-Cleft variation	Number of patients
1. CLA unilateral	3
2. CLAP unilateral	4
3. CLAP bilateral	2
4) hPsP	1

Kundrat, in 1882,^[5] provided the first distinction between “arhinencephaly” with a median or lateral cleft lip for this disease pattern. Demyer *et al.*^[6] confirmed the coexistence of HPE and median cleft lip and additionally described a HPE case with bilateral cleft lip. Recently, others distinguished subdivisions of the upper median cleft lip related to cleft size, the philtrum, the columella, the superior labial frenulum, and the premaxilla.^[32] More comprehensively, this disease pattern was described as “median cleft with agenesis of the premaxilla-prolabium-columella complex,”^[27] however, without further subdivisions. The review of this database provided enough material to coin finally four subdivisions of this disease pattern, resulting in an incidence ratio between Ag-HPE (Ag-Colum, Ag-CLA, and Ag-CLAP) and HPE-Std-Cleft of 88% versus 12%.

The phenomenon of the single central upper incisor exists within the disease pattern of HPE,^[33] however, not all patients with a single maxillary central incisor are affected by HPE. HPE patients affected with a single maxillary central incisor are allocated to the fourth of the here presented subdivisions, the HPE-Std-Cleft subdivision. In literature, there is so far only one HPE-Std-Cleft case reported with an isolated hard and soft palate cleft (hPsP), apparently not being considered as part of a HPE with otherwise normally appearing midfacial structures.^[29]

The mortality rate is generally very high. It fluctuates between 33% in the postnatal 24 h, to 58% in the 1st month, to 50% between the fourth and the 5th month, up to 70%–80% in the 1st year of life, with a reported survival rate of only 29% after 1 year of life.^[34] Only a small number of children survived until adulthood.^[35] Survival rate generally correlates with the severity of the brain malformations and its associated diseases. The Carter Centers for Brain Research^[36] performed a population-based study about holoprosencephaly and related malformations. Combining through the New York State Congenital Malformations Registry from 1984 to 1989, they detected that 57% of HPE children with syndromes died within the first 2 days of life and 54% of HPE children, with no severe craniofacial abnormalities survived their 1st year of life.^[35] The earliest date a HPE-cleft patient presented at our cleft lip and palate clinic 3-week postnatal. The mortality rate of 78% in this database was very high. It fluctuated from 50.0% with the HPE-Std-Cleft subdivision up to 100% in those few Ag-Colum cases. The children suffering from an Ag-CLA showed an 86% whereas those with an Ag-CLAP a 70% mortality rate.

Epilepsy with or without seizures is a common complication. A single seizure occurs in around 50% of all HPE children.^[35] In the Carter Centers’ study, only around 40% of children needed antiepileptic treatment.^[36] This database revealed an incidence of epilepsy in 65% of children with an Ag-CLAP (65%), in 62% of those with an Ag-CLA and 50% in those with a HPE-Std-Cleft. No patient of the Ag-Colum subdivision suffered from epilepsy. This is rather unusual as children with Ag-Colum are actually at the milder end of the spectrum but revealed the highest mortality rate in this database. As their number is very small, it only might be speculated that this may be due to a particularly different brain malformation.

A review of the literature and of a database of 85 HPE cleft cases provided the basis to subdivide this complex disease patterns into four subdivisions. Further investigations relating HPE etiology, developmental long-term outcomes and endocrine functions are required.

CONCLUSION

This analysis adds important data to the existing literature related to HPE patients with cleft lip and palate deformities.

- (1) The prevalence found in these HPE-Cleft patients is 1.81%, with a prevalence of 4.25% among black African patients;
- (2) 68% of diagnosed HPE-Cleft patients were females.
- (3) Alobar and semilobar brain malformations count for 78% of brain deformities among these HPE-Cleft patients.
- (4) Four distinct subdivisions could be identified reviewing the facial features of HPE cleft lip and palate patients in this database.
- (5) HPE-Cleft patients presented in 60% with epilepsy and a 78% death rate.

In this database, the three subdivisions containing cases with holoprosencephaly and various agenesis of midfacial structures (Ag-HPE) accounted for 88% of all cases, entailing further most general health-related compromised patients. The fourth subdivision of HPE-“standard-cleft” patients comprises only 12% of all cases, showing less involved midfacial deformities and structural agenesis. They may or may not disclose a single central upper incisor and may further present as “normal” cleft children initially, some of them even with a possibly normal life expectancy.

Acknowledgment

Some of the figures presented are published in the book:^[18] Cleft – Ultimate Treatment, with permission of the authors, who are holding the publishing rights.

RN Hester van der Berg, Facial Cleft Deformity Clinic and RN Daleen du Plessis, research assistant.

Declaration of patient consent

The authors certify that they have obtained all appropriate patient consent forms. In the form, the legal guardian has given his consent for images and other clinical information to be reported in the journal. The guardian understands that names and initials will not be published and due efforts will be made to conceal identity, but anonymity cannot be guaranteed.

Financial support and sponsorship

Dr. EM Honey is supported by the South African Medical Research Council under a Self-Initiated Research Grant. The views and opinions expressed are not those of the SAMRC but of the authors of the material produced or publicized; Nil for database analysis.

Conflict of interest

There are no conflicts of interest.

REFERENCES

- Solomon BD, Kruszka P, Muenke M. Holoprosencephaly flashcards: An updated summary for the clinician. *Am J Med Genet C Semin Med Genet* 2018;178:117-21.
- Duboung C, Bendavid C, Pasquier L, Henry C, Odent S, David V. Holoprosencephaly. *Orphanet J Rare Dis* 2007;28:1-14.
- Demyer W, Zeman W, Palmer CG. The face predicts the brain: Diagnostic significance of median facial anomalies for holoprosencephaly (arhinencephaly). *Pediatrics* 1964;34:256-63.
- Orioli IM, Castilla EE. Epidemiology of holoprosencephaly: Prevalence and risk factors. *Am J Med Genet C Semin Med Genet* 2010;154C:13-21.
- Kundrat H. Arhinecephalie als Typische Art von Missbildung. *Graz: Leuschnert und Lubensky; 1882. p. 33-79.*
- Demyer W, Zeman W. Alobar holoprosencephaly (arhinencephaly) with median cleft lip and palate: Clinical, electroencephalographic and nosologic considerations. *Confin Neurol* 1963;23:1-36.
- Yamada S. Embryonic holoprosencephaly: Pathology and phenotypic variability. *Congenit Anom (Kyoto)* 2006;46:164-71.
- Lacbawan FL, Muenke M. Central nervous system embryogenesis and its failures. *Pediatr Dev Pathol* 2002;5:425-47.
- Ming JE, Muenke M. Multiple hits during early embryonic development: Digenic diseases and holoprosencephaly. *Am J Hum Genet* 2002;71:1017-32.
- Winter TC, Kennedy AM, Woodward PJ. Holoprosencephaly: A survey of the entity, with embryology and fetal imaging. *Radiographics* 2015;35:275-90.
- Miller EA, Rasmussen SA, Siega-Riz AM, Frías JL, Honein MA; National Birth Defects Prevention Study. Risk factors for non-syndromic holoprosencephaly in the National Birth Defects Prevention Study. *Am J Med Genet C Semin Med Genet* 2010;154C:62-72.
- Solomon BD, Gropman A, Muenke M. Holoprosencephaly overview. In: Pagon RA, Adam MP, Ardinger HH, Wallace SE, Amemiya A, Bean LJ, *et al.*, editors. *GeneReviews* (R). University of Washington; 1993. Available from: <http://www.genereviews.org/> ©1993-2019.; <https://www.ncbi.nlm.nih.gov/books/NBK1530>. [Last accessed on 2019 Jan 13].
- Roessler E, Vélez JI, Zhou N, Muenke M. Utilizing prospective sequence analysis of SHH, ZIC2, SIX3 and TGIF in holoprosencephaly probands to describe the parameters limiting the observed frequency of mutant gene × gene interactions. *Mol Genet Metab* 2012;105:658-64.
- Dubourg C, David V, Gropman A, Mercier S, Muenke M, Odent S, *et al.* Clinical utility gene card for: Holoprosencephaly. *Eur J Hum Genet* 2011;19:118-20.
- Kauvar EF, Muenke M. Holoprosencephaly: Recommendations for diagnosis and management. *Curr Opin Pediatr* 2010;22:687-95.
- Pineda-Alvarez DE, Dubourg C, David V, Roessler E, Muenke M. Current recommendations for the molecular evaluation of newly diagnosed holoprosencephaly patients. *Am J Med Genet C Semin Med Genet* 2010;154C:93-101.
- Dubourg C, Carré W, Hamdi-Rozé H, Mouden C, Roume J, Abdelmajid B, *et al.* Mutational spectrum in holoprosencephaly shows that FGF is a new major signaling pathway. *Hum Mutat* 2016;37:1329-39.
- Arauz RF, Solomon BD, Pineda-Alvarez DE, Gropman AL, Parsons JA, Roessler E, *et al.* A hypomorphic allele in the FGF8 gene contributes to holoprosencephaly and is allelic to gonadotropin-releasing hormone deficiency in humans. *Mol Syndromol* 2010;1:59-66.
- Bendavid C, Dupé V, Rochard L, Gicquel I, Dubourg C, David V. Holoprosencephaly: An update on cytogenetic abnormalities. *Am J Med Genet C Semin Med Genet* 2010;154C:86-92.
- Bae GU, Domené S, Roessler E, Schachter K, Kang JS, Muenke M, *et al.* Mutations in CDON, encoding a hedgehog receptor, result in holoprosencephaly and defective interactions with other hedgehog receptors. *Am J Hum Genet* 2011;89:231-40.
- Dupé V, Rochard L, Mercier S, Le Pétillon Y, Gicquel I, Bendavid C, *et al.* NOTCH, a new signaling pathway implicated in holoprosencephaly. *Hum Mol Genet* 2011;20:1122-31.
- Pineda-Alvarez DE, Roessler E, Hu P, Srivastava K, Solomon BD, Siple CE, *et al.* Missense substitutions in the GAS1 protein present in holoprosencephaly patients reduce the affinity for its ligand, SHH. *Hum Genet* 2012;131:301-10.
- Mouden C, de Tayrac M, Dubourg C, Rose S, Carré W, Hamdi-Rozé H, *et al.* Homozygous STIL mutation causes holoprosencephaly and microcephaly in two siblings. *PLoS One* 2015;10:e0117418.
- Weiss K, Kruszka PS, Levey E, Muenke M. Holoprosencephaly from conception to adulthood. *Am J Med Genet C Semin Med Genet* 2018;178:122-7.
- Petryk A, Graf D, Marcucio R. Holoprosencephaly: Signaling interactions between the brain and the face, the environment and the genes, and the phenotypic variability in animal models and humans. *Wiley Interdiscip Rev Dev Biol* 2015;4:17-32.
- Richieri-Costa A, Ribeiro LA. Holoprosencephaly and holoprosencephaly-like phenotypes: Review of facial and molecular findings in patients from a craniofacial hospital in Brazil. *Am J Med Genet C Semin Med Genet* 2010;154C:149-57.
- Bütow KW, Zwahlen RA. Median cleft reconstruction with agenesis of premaxilla-prolabium-columella. In: *Cleft-Ultimate Treatment*. 2nd ed., Ch. 20. Durban: Reach Publisher; 2016. p. 367-74.
- Van Wyk PJ, Bütow KW, Van der Merwe CA, Kleynhans EE. Die insidiese in kliniese voorkoms van gesplete gesigsdeformiteite in Transvaal. *J Dent Assoc Afr* 1987;42:403-6.
- Orioli IM, Castilla EE. Clinical epidemiologic study of holoprosencephaly in South America. *Am J Med Genet A* 2007;143A:3088-99.
- Chen CP, Chern SR, Lin CJ, Lee CC, Wang W, Tzen CY. A comparison of maternal age, sex ratio and associated anomalies among numerically aneuploid, structurally aneuploid and euploid holoprosencephaly. *Genet Couns* 2005;16:49-57.
- Roach E, Demyer W, Conneally PM, Palmer C, Merritt AD. Holoprosencephaly: Birth data, genetic and demographic analyses of 30 families. *Birth Defects Orig Artic Ser* 1975;11:294-313.
- de Boutray M, Beziat JL, Yachouh J, Bigorre M, Gleizal A, Captier G. Median cleft of the upper lip: A new classification to guide treatment decisions. *J Craniomaxillofac Surg* 2016;44:664-71.
- Richieri-Costa A, Ribeiro LA. Single maxillary central incisor, holoprosencephaly, and holoprosencephaly-like phenotype. *Am J Med Genet A* 2006;140:2594-7.
- Levey EB, Stashinko E, Clegg NJ, Delgado MR. Management of children with holoprosencephaly. *Am J Med Genet C Semin Med Genet* 2010;154C:183-90.
- Olsen CL, Hughes JP, Youngblood LG, Sharpe-Stimac M. Epidemiology of holoprosencephaly and phenotypic characteristics of affected children: New York state, 1984-1989. *Am J Med Genet* 1997;73:217-26.
- Carter Centers for Brain Research in Holoprosencephaly and Related Malformations. Available from: <http://www.stanford.edu/group/hpc>. [Last accessed on 2019 Jan 13].