

RESEARCH ARTICLE

Serum Carbohydrate Antigen 19-9 in Differential Diagnosis of Benign and Malignant Pancreatic Cystic Neoplasms: A Meta-Analysis

Shaobo Cao, Ya Hu, Xiang Gao, Quan Liao, Yupei Zhao*

Department of General Surgery, Peking Union Medical College Hospital and Chinese Academy of Medical Science, Beijing, 100730, China

* zhao8028@263.net



click for updates

Abstract

Background

Using serum carbohydrate antigen 19–9 (CA 19–9) in discriminating between benign and malignant pancreatic disease remains controversial. We aim to evaluate the diagnostic value of serum CA 19–9 in predicting malignant pancreatic cystic lesions.

Methods

Eligible studies were identified through searching MEDLINE and EMBASE prior to March 2016. Studies were assessed for quality using the Quality Assessment for Studies of Diagnostic Accuracy, 2nd version (QUADAS-2). Pooled sensitivity and specificity with 95% confidence interval (CI) were calculated using random-effects models. Summary receiver operator characteristic (SROC) curves and the area under curve (AUC) were performed.

Results

A total of thirteen studies including 1437 patients were enrolled in this meta-analysis. The pooled sensitivity and specificity were 0.47(95% CI: 0.35–0.59), and 0.88(95% CI: 0.86–0.91), respectively, and the AUC was 0.87(95% CI, 0.84–0.90). Meta-regression analysis showed that sample size, region and reference standards were not the main sources of heterogeneity.

Conclusions

Serum CA 19–9 has satisfying pooled specificity while poor pooled sensitivity for discriminating benign from malignant PCNs. It deserves to be widely used as complementary to other clinical diagnostic methods.

OPEN ACCESS

Citation: Cao S, Hu Y, Gao X, Liao Q, Zhao Y (2016) Serum Carbohydrate Antigen 19-9 in Differential Diagnosis of Benign and Malignant Pancreatic Cystic Neoplasms: A Meta-Analysis. PLoS ONE 11(11): e0166406. doi:10.1371/journal.pone.0166406

Editor: Rajvir Dahiya, University of California San Francisco, UNITED STATES

Received: July 21, 2016

Accepted: October 30, 2016

Published: November 11, 2016

Copyright: © 2016 Cao et al. This is an open access article distributed under the terms of the [Creative Commons Attribution License](https://creativecommons.org/licenses/by/4.0/), which permits unrestricted use, distribution, and reproduction in any medium, provided the original author and source are credited.

Data Availability Statement: All relevant data are within the paper and its Supporting Information files.

Funding: The authors received no specific funding for this work.

Competing Interests: The authors have declared that no competing interests exist.

Introduction

Pancreatic cystic neoplasms (PCNs) include serous cystic adenomas (SCAs), cystic neuroendocrine tumors, mucinous cystic neoplasms (MCNs) and intraductal papillary mucinous neoplasms (IPMNs). SCAs is a benign type of PCNs that rarely get malignant but MCNs and IPMNs may be premalignant or malignant.[1,2] The differentiation of benign and malignant PCNs can be complex preoperatively, despite the advances in imaging technology. Close follow-up was generally sufficient for some patients with benign PCNs considering the high rate of complications associated with surgical resection and the increased hospital costs.[3] Careful non-operative management seemed to be safe and effective in some asymptomatic patients.[4] Nevertheless, neoplasms with high malignant potential were supposed to be referred for surgical resection and these group of patients may be associated with poor survival even after radical resection in some cases.[5–7] Therefore, accurate and rapid diagnosis of malignant PCNs is crucial for the optimal management.

Traditional cross-sectional imaging examinations have a limited ability to differentiate benign from premalignant or malignant PCNs.[8,9] EUS-guided fine needle aspiration (FNA) is invasive and positron emission tomography (PET) is costly for many people. Laboratory tests such as the assessment of tumor markers are considered as the most frequent, economic, convenient and rapid method. The role of serum CA 19–9 in distinguishing between benign and malignant disease remains controversial. So we conducted this meta-analysis to evaluate the diagnostic precision of serum CA 19–9 in discriminating benign from malignant PCNs.

Methods

Article search strategy

A literature search for relevant articles including MEDLINE and EMBASE was carried out to identify eligible English-language studies published prior to March 2016 by two independent reviewers independently. The following terms were used as keywords: “CA19-9 Antigen”, “pancreas” OR “pancreatic cystic lesion” OR “Pancreatic cystic neoplasms”, “diagnosis”. The references of identified articles and review articles were also reviewed to involve more relevant studies.

Study eligibility and quality assessment

Two reviewers (Shaobo Cao and Ya Hu) independently reviewed the searches and evaluated every article. Titles and abstracts were considered to identify the potentially eligible study. And then full text was obtained for further evaluation. Studies were included if (1) they attempted to determine the benignity or malignancy of PCNs; (2) sufficient information were provided to complete the 2×2 contingency tables; (3) histopathology results and/or clinical follow-up were used as the reference standard; (4) they were published as full-text articles. The exclusion criteria were as follows: (1) studies with insufficient data to construct 2×2 contingency tables; (2) editorial, case reports, letter to editors, comment, brief communication or meeting abstract without publication of full article; (3) included patients less than ten; (4) studies in which the relevant data overlapped with that of other studies due to patient overlap. QUADAS-2 tool was used to assess the quality, applicability, and risk of bias of included studies.[10] All the authors discussed their evaluation and any disagreement was resolved through discussion.

Statistic analysis

Rev Man 5.3 (The Nordic Cochrane Centre, The Cochrane Collaboration, 2014) and STATA version 12.0 (STATA Corporation, College Station, Texas, USA) were used to meta-analyze

the data. Pooled sensitivity, specificity, summary receiver operating characteristic (SROC) curve, diagnostic odds ratio (DOR) and the area under the curve (AUC) were calculated following a bivariate mixed-effects regression model with MIDAS tool.[11] An AUC close to 1 reflected a well-performing diagnostic precision, and a poor performance has an AUC close to 0.5.[12] Forrest plots of each study and pooled estimates for sensitivity and specificity with 95% confidence intervals (95% CI) were presented.

The Cochran's Q and I^2 statistics were used to assess the extent of heterogeneity among the included studies.[13] The studies were considered to be with statistically significant heterogeneity if $P < 0.1$ and $I^2 > 50\%$. Deek funnel plot asymmetry test was used to evaluate the potential publication bias, and $P < 0.1$ was considered to be of a significant publication bias statistically. Subgroup analysis and meta-regression were applied to identify the sources of heterogeneity across studies.[14] $P < 0.05$ was determined to be statistically significant.

Results

Search and selection of the studies

The procedure of studies search and selection was outlined in Fig 1. The systematic database search returned 559 articles. Of these, 481 articles were excluded based on the titles and abstracts. Full manuscripts from the remaining 78 articles were viewed. Finally, a total of 13 studies were eligible for data extraction and analysis.[15–27]

Patient characteristics and quality of studies

A total of 13 studies (1 prospective, 12 retrospective) comprising 1437 patients were incorporated in this analysis, which included 948 benign lesions and 489 malignant lesions. The principal characteristics of these included studies were outlined in Table 1. The cutoff value of serum CA 19–9 used to differentiate benign and malignant cysts ranged from 35 to 45 U/ml in 11 papers, while definite cutoff value was not reported in the rest two studies.[18,19] Most of the patients underwent operations and the pathological results were available, but a part of patients were observed without surgery in two studies.[23,25] Eleven studies reported that elevated serum CA 19–9 was related with malignant PCNs by univariate analysis and the other two researchers reported the opposite results.[24,27] The quality evaluation of the studies was shown in Fig 2. The risks of bias in “patient selection” were generally high in our meta-analysis, this represented the most prominent issue in the methodological quality assessment. Two studies with more than two high ‘risks’ were judged to be of low quality. The applicability was good.

Diagnostic performance

The pooled sensitivity and specificity of serum CA 19–9 levels in predicting malignant PCNs were 0.47 (95% CI: 0.35–0.59) and 0.88 (95% CI: 0.86–0.91), respectively (Fig 3). The positive likelihood ratio was 4.0 (95% CI, 3.2–5.2) and the negative likelihood ratio was 0.6 (95% CI, 0.48–0.75). The AUC was 0.87 (95% CI, 0.84–0.90) (Fig 4). The summary Diagnostic Odds Ratio (DOR) was 7 (95% CI: 4–12).

Publications bias

The publications bias of the studies was assessed by Deek funnel plot. The linear regression of log odds ratios on inverse root of effective sample sizes showed that the Bias value was 0.11 ($P = 0.91$), indicating no evidence of publications bias in these included studies (Fig 5).

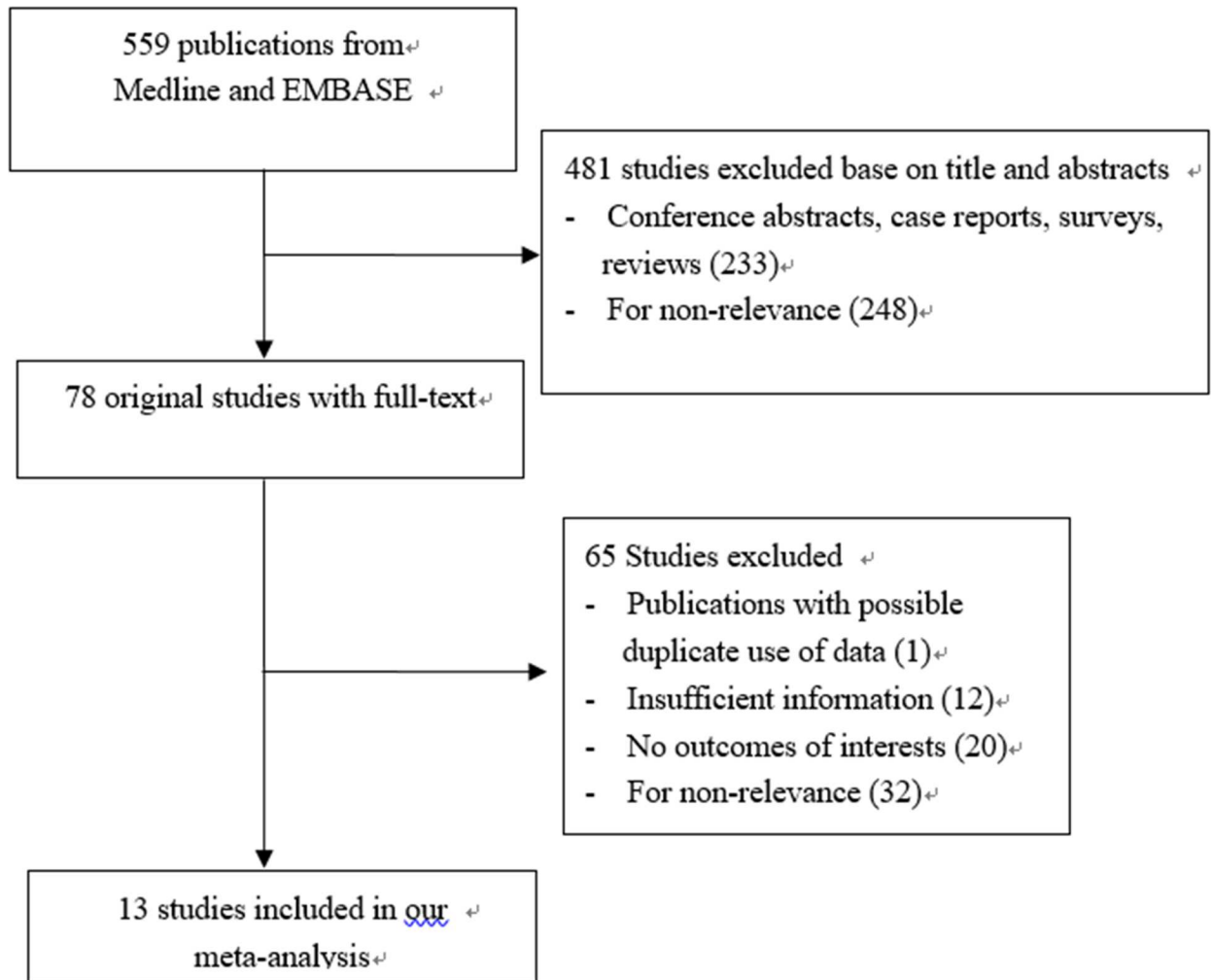


Fig 1. The flow chart of systematic studies search and selection procedure.

doi:10.1371/journal.pone.0166406.g001

Heterogeneity assessing and subgroup analysis

Significant heterogeneity was observed in sensitivity ($P < 0.01$; $I^2 = 81.87\%$), while no heterogeneity was showed in specificity ($P = 0.35$; $I^2 = 9.7\%$) among these 13 studies. Subgroup analysis was performed to identify possible reasons for the heterogeneity. We conducted subgroup analyses based on study sample size, study population and type of PCNs. There were six studies with sample size more than 100, involving 991 patients in total, which revealed a pooled sensitivity of 0.44 (95% CI: 0.32–0.56), specificity of 0.89 (95% CI: 0.86–0.91) and DOR of 6 (95% CI: 4–10), respectively. For studies with samples less than 100, the pooled sensitivity, specificity and DOR were 0.49 (95% CI: 0.28–0.69), 0.87 (95% CI: 0.81–0.91) and 6 (95% CI: 3–14), respectively. Seven studies were conducted in Asian patients, in which the pooled sensitivity, specificity and DOR were 0.37 (95% CI: 0.24–0.52), 0.90 (95% CI: 0.87–0.92) and 5 (95% CI: 3–10), respectively. The remaining 6 studies, conducted in patients from the western countries, showed a pooled sensitivity of 0.59 (95% CI: 0.44–0.72), specificity of 0.86 (95% CI: 0.81–0.89) and DOR of 8 (95% CI: 4–16), respectively. There were 10 studies involving patients with IPMNs only, whose pooled sensitivity and specificity were 0.45 (95% CI: 0.31–0.61), 0.89 (95% CI: 0.86–0.91), respectively. The remaining 3 studies were insufficient for analysis.

Table 1. Characteristics of included studies.

Author, Year	Country	Study design	Mean age, years	Reference standards	No. of patients in studies	Patients included in meta-analysis	Patients with malignant disease	Patients with benign disease	Surgical pathology(n)	Cutoff vaule (u/ml)	Size of lesion
Fritz et al., 2011	Germany	Retrospective	32–87	Pathology	142	142	50	92	142IPMNs: (Benign +HGD92, invasive50)	37	unknown
Goh et al., 2008	Canada	Retrospective	54(14–84)	Pathology	176	137	79	58	176PCNs: (Benign70, potentially malignant51, malignant15)	45	104patients>30mm,72patients<30mm
Grobmyer et al., 2009	USA	Retrospective	63	Pathology	78	40	8	32	78PCNs: (Non-malignant65, malignant13)	37	40mm
Hirono et al., 2012	Japan	Retrospective	68.9(32–84)	Pathology	134	134	78	56	134IPMNs: (Adenomas81, borderline neoplasms5, CIS41, invasive37)	elevated	30.4mm
Hwang et al., 2011	Korea	Retrospective	63(38–83)	Pathology	237	237	39	198	237IPMNs: (Adenomas81, borderline17, CIS13, invasive26)	37	Malignant 36.6mm, unmalignant 25mm,
Ingakul et al., 2010	Japan	Prospective	Malignant70, unmalignant66.4	Pathology, cytology, follow-up	200	146	22	124	200 IPMNs: (invasive ductal carcinoma22, IPMNs alone93)	37	unknown
Jones et al., 2009	USA	Retrospective	62(24–84)	Pathology	114	62	25	37	62PCNs: (Invasive35, IPMN29, MCN17, SMA33)	35	40mm
Kitagawa et al., 2003	USA	Retrospective	64	Pathology	63	42	21	21	63IPMN: (Benign30, invasive28, CIS5)	elevated	unknown
Ohtsuka et al., 2012	Japan	Retrospective	unknown	Pathology	138	99	22	77	99IPMNs: (LGD55, IGD22, HGD9, invasive13)	37	65patients>30mm, 34patients<30mm
Sadakari et al., 2010	Japan	Retrospective	66(46–82)	Pathology	73	53	6	47	73IPMNs: (Adenomas48, borderline19, CIS5, invasive1)	37	47patients>30mm, 26patients<30mm
Shin et al., 2010	Korea	Retrospective	61(35–77)	Pathology	204	195	49	146	204IPMNs: (Adenoma77, borderline77, CIS9, invasive41)	37	85patients>30mm, 119patients<30mm
Sperti et al., 2007	Italy	Retrospective	64(37–84)	Pathology, follow-up	64	64	26	38	64 IPMNs: (Adenomas13, borderline8, CIS5, invasive21)	37	28mm
Xu et al., 2011	China	Retrospective	62(41–76)	Pathology	86	86	64	22	86IPMNs: (Adenomas10, borderline12, CIS3, invasive61)	37	unknown

LGD: Low-grade dysplasia; IGD: Intermediate-grade dysplasia; HGD: High grade-dysplasia; CIS: carcinoma in situ. MCN: mucinous cystic neoplasms; SMA: serous microcystic adenoma.

* 85 patients did not undergo surgery

** 17 patients did not undergo surgery

doi:10.1371/journal.pone.0166406.t001

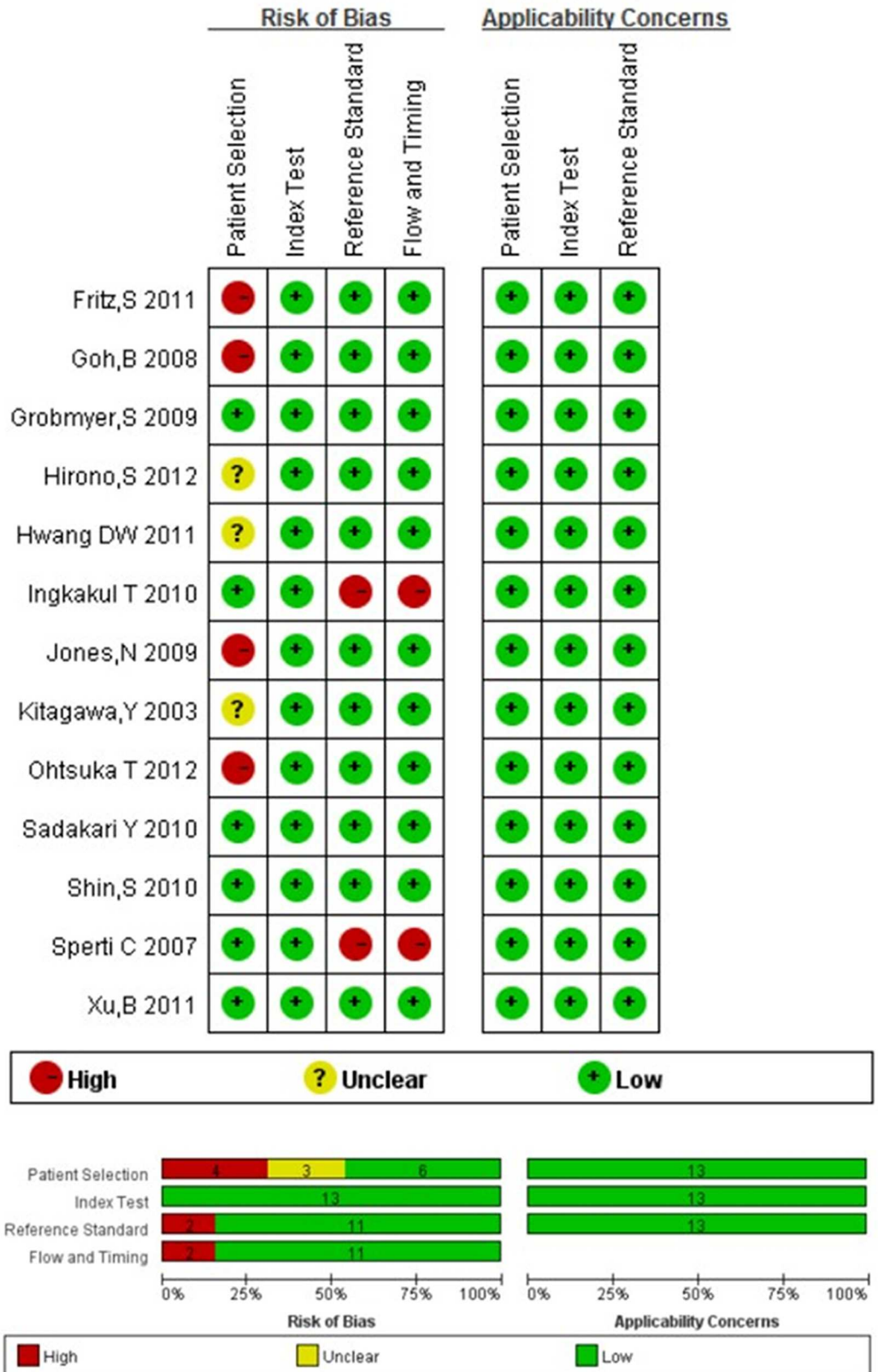


Fig 2. Risk of bias of each included studies with QUADAS-2 quality assessment tools.

doi:10.1371/journal.pone.0166406.g002

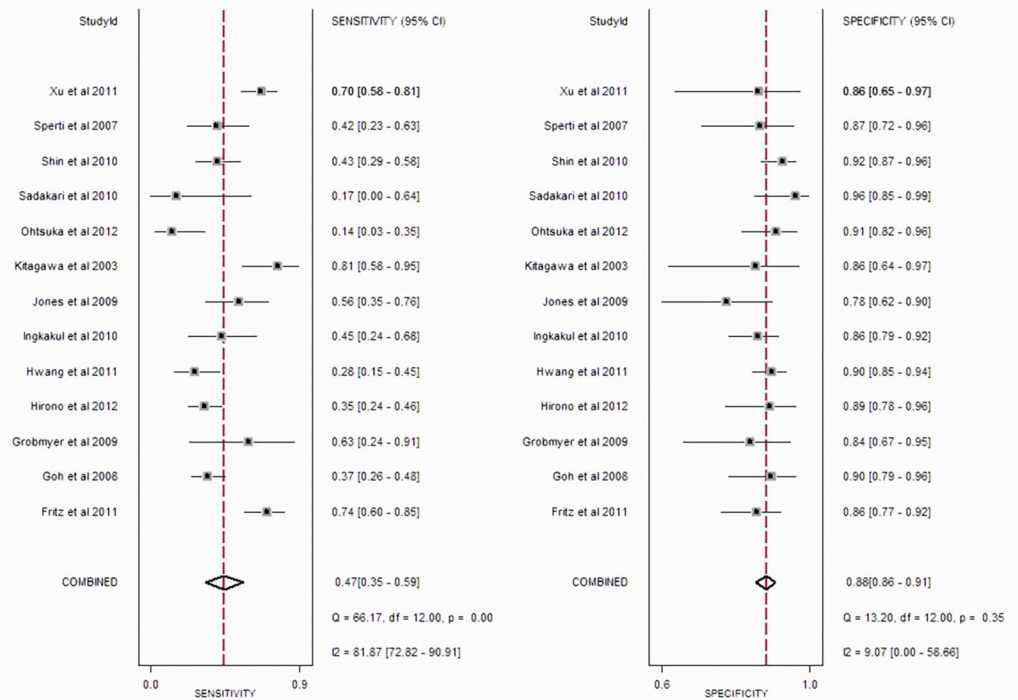


Fig 3. Forest plot of sensitivity and specificity estimates for serum CA 19-9 in predicting malignant PCNs for 13 studies.

doi:10.1371/journal.pone.0166406.g003

For meta-regression analysis, we found that these pre-identified confounding covariates, like sample size, region, reference standards may cause heterogeneity. But these factors were not the main sources of heterogeneity as shown in Fig 6.

Discussion

There are growing number of cystic lesions identified in pancreas due to the increasingly wide use of abdominal imaging.[28] Correct preoperative diagnosis is the pillar of clinical management.[5,29] It has been reported that preoperative factors, such as serum tumor markers, cyst fluid tumor markers, tumor size, diameter of the main pancreatic duct, symptoms, duct type, EUS-FNA-based cytology and cross-sectional imaging features are reasonably accurate in predicting the malignant potential of PCNs.[15,25,30-35] Several articles reported that elevated serum CA 19-9 is a significant high risk factor of malignant PCNs. [15,16,20,25,26]

In our meta-analyses, we summarized 13 studies involving 1437 patients who were diagnosed with PCNs. To predict malignancy of PCNs, the pooled specificity and AUC of serum CA 19-9 were satisfactory, while the pooled sensitivity was limited. This might suggest that serum CA 19-9 would be a useful discriminator between benign and malignant PCNs, but more sensitive biomarkers were needed. A significant number of malignant PCNs might be misdiagnosed as benign disease when only relying on serum CA 19-9. Our viewpoint was also agreed by many other researchers, who reported that serum CA 19-9 was a useful non-invasive tool for distinguishing malignant IPMNs, and should be taken into account in the decision to offer surgery.[15,17,36]

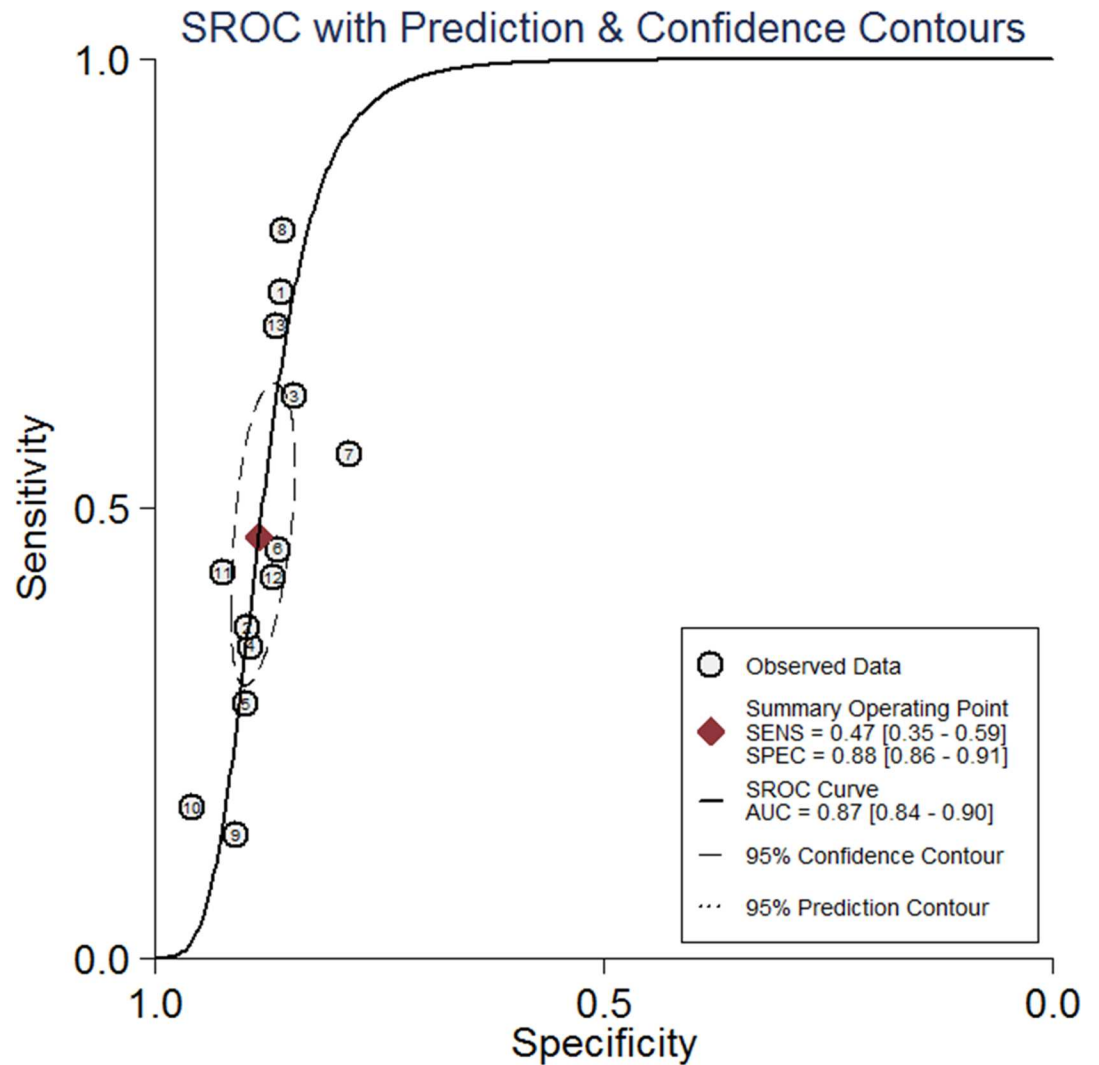


Fig 4. Summary of receiver operator characteristic (SROC) curve for serum CA 19–9 in predicting malignant PCNs. AUC: area under the curve.

doi:10.1371/journal.pone.0166406.g004

Many other diagnostic techniques were also used to distinguish benign and malignant PCNs. It was illuminated that the risk of malignant PCNs associated with cyst size greater than 3cm, presence of a mural nodule, dilatation of the main pancreatic duct, etc.[37] A meta-analysis reported that the level of cyst fluid CEA would not differentiate benign from malignant PCNs well, with a pooled sensitivity (0.63; 95% CI: 0.55–0.69) and specificity (0.63; 95% CI: 0.57–0.68), respectively.[38] The international consensus guidelines 2012 for PCNs identified that elevated CEA of cyst fluid was not an effective biomarker to distinguish benign from malignant cysts. [5] Suzuki analyzed EUS-FNA-based cytology differentiating malignant and benign IPMNs. Similar to our diagnostic test, the pooled sensitivity and specificity were 0.64 (95% CI, 0.44–0.82) and 0.9 (95% CI, 0.81–0.96), respectively.[39] But it is more safe, convenient and economic to detect serum CA 19–9 in clinical practice. Sultana reported that the pooled sensitivity and specificity of CT/MRI in distinguishing malignant IPMNs were 0.89 (95% CI, 0.71–0.88), 0.76 (95% CI, 0.65–0.85), respectively. 18-fluorodeoxyglucose positron emission tomography (18-FDG PET) is believed to be better than other imaging technology in

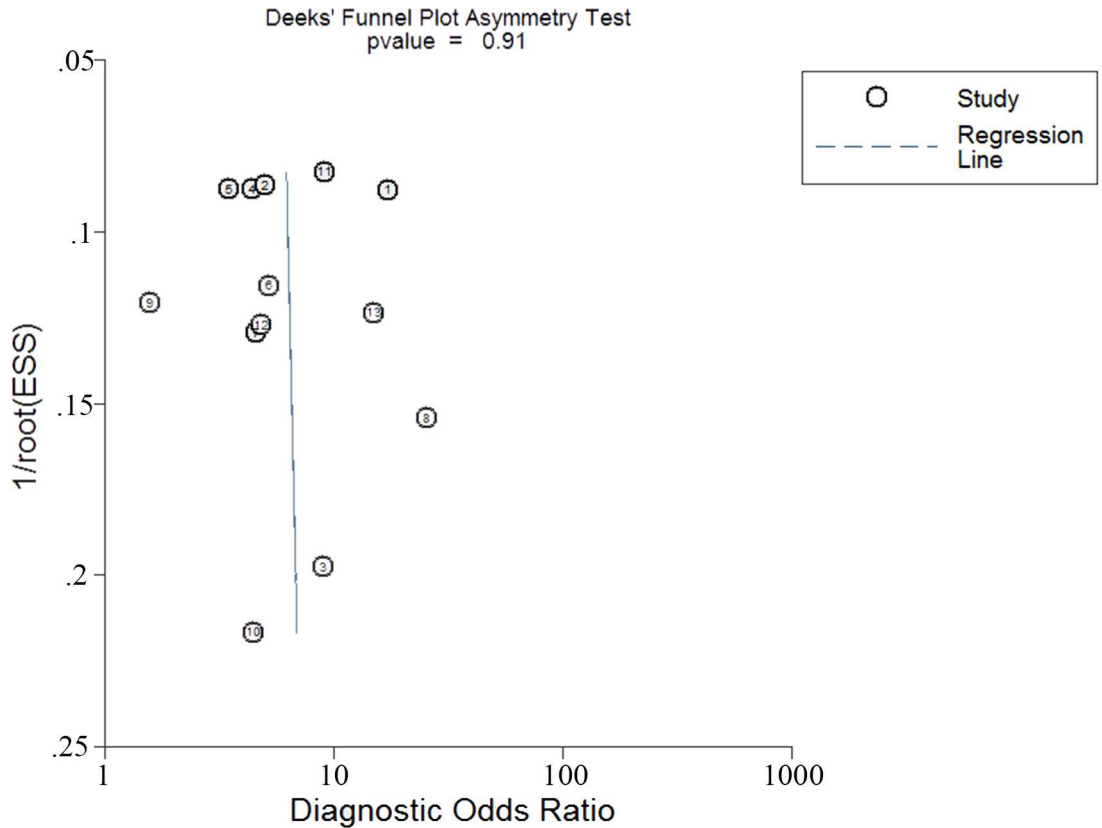


Fig 5. The Deek's funnel asymmetry plot test for evaluation of potential publication bias for serum CA 19-9 in the diagnosis of malignant PCNs.

doi:10.1371/journal.pone.0166406.g005

distinguishing benign from malignant IPMNs.[23,40] The pooled sensitivity and specificity of 18-FDG PET were 0.968 (95% CI: 0.90–0.99) and 0.91(0.81–0.99).[36] As 18-FDG PET is not routinely performed for its high cost and radiation, the decision of whether to do a surgery or not remains challenging.[41] Studies of molecular markers were also reported recently. It is

```

Meta-regression
REML estimate of between-study variance
% residual variation due to heterogeneity
Proportion of between-study variance explained
Joint test for all covariates
With Knapp-Hartung modification
Number of obs = 13
tau2 = .1614
I-squared_res = 71.81%
Adj R-squared = -33.92%
Model F(3, 9) = 0.29
Prob > F = 0.8351
    
```

logor	Coef.	Std. Err.	t	P> t	[95% Conf. Interval]	
Region1	-.2846694	.32758	-0.87	0.407	-1.025707	.4563681
Referencel	.0927115	.4004128	0.23	0.822	-.8130852	.9985082
Size	.0018451	.0029339	0.63	0.545	-.0047918	.0084821
_cons	.8621784	.3589507	2.40	0.040	.0501754	1.674181

Fig 6. The meta-regression analysis for possible resources of heterogeneity among included studies.

doi:10.1371/journal.pone.0166406.g006

reported that the sensitivity and specificity of KRAS mutations analysis in differentiating malignancy from benign PCNs were 0.59 (95% CI: 0.46–0.71) and 0.78(0.71–0.85), respectively. And the pooled sensitivity and specificity of loss of heterozygosity of KRAS gene were 0.89 (95% CI: 0.78–0.96), 0.69 (95% CI: 0.60–0.76), respectively.[42] Compared with these tests, serum CA19-9 can be an initiatory and essential preoperative assessment in routine clinical practice. According to the pooled specificity and AUC in our meta-analysis, it's helpful to preliminarily identify malignant PCNs. As it is impossible to establish a diagnosis of malignant PCNs before surgery with one unique inspection technique, a combined preoperative diagnosis strategy with multi-disciplinary approach may be more promising.

There are several limitations in our meta-analysis. First, high heterogeneity was found in our meta-analysis and the meta-regression analyses failed to explore the main resources of heterogeneity among studies. The possible reason is that studies shared different cutoff values or definitions of malignant PCNs, which might not be taken into account in our statistical model. The various criteria used to evaluate malignant PCNs, such as CIS, HGD, potentially malignant cancer, invasive cancer and malignant cancer among studies, may result in heterogeneity. In addition, the term CIS has been suggested to be abandoned in the international consensus guidelines. [5] Second, most of the included studies didn't provide the information of assays used to detect serum CA 19–9, and such differences in detection may be an important source of heterogeneity. Third, only studies published in English were included in our meta-analysis, which may also result in bias. Finally, we just valued the diagnostic precision of serum CA 19–9 in discriminating benign from malignant PCNs, but failed to deeply discuss what should we manage patients with normal or evaluated CA 19–9.

Conclusions

In conclusion, this meta-analysis indicated that serum CA 19–9 could be a useful tool with high pooled specificity for discriminating benign from malignant PCNs. Considered as the most economic, convenient, safe and rapid method, it deserved to be widely used as complementary to other diagnostic techniques. There is still a need for further studies looking into features associated with malignant PCNs.

Supporting Information

S1 PRISMA Checklist. Prisma Harms checklist items.
(DOCX)

Author Contributions

Conceptualization: YPZ QL.

Data curation: SBC YH XG.

Formal analysis: SBC YH XG.

Methodology: SBC YH XG.

Software: SBC YH XG.

Supervision: SBC YH XG QL YPZ.

Validation: YPZ QL.

Visualization: SBC.

Writing – original draft: SBC.

Writing – review & editing: SBC YH XG QL YPZ.

References

1. Galanis C, Zamani A, Cameron JL, Campbell KA, Lillemoe KD, Caparrelli D, et al. Resected serous cystic neoplasms of the pancreas: a review of 158 patients with recommendations for treatment. *J Gastrointest Surg*. 2007; 11(7):820–26.
2. Sarr MG, Carpenter HA, Prabhakar LP, Orchard TF, Hughes S, van Heerden JA, et al. Clinical and pathologic correlation of 84 mucinous cystic neoplasms of the pancreas: can one reliably differentiate benign from malignant (or premalignant) neoplasms? *Ann Surg*. 2000; 231(2):205–12.
3. Cecka F, Jon B, Cermakova E, Subrt Z, Ferko A. Impact of postoperative complications on clinical and economic consequences in pancreatic surgery. *Ann Surg Treat Res*. 2016; 90(1):21–28.
4. Salvia R, Crippa S, Falconi M, Bassi C, Guarise A, Scarpa A, et al. Branch-duct intraductal papillary mucinous neoplasms of the pancreas: to operate or not to operate? *Gut*. 2007; 56(8):1086–90. doi: [10.1136/gut.2006.100628](https://doi.org/10.1136/gut.2006.100628) PMID: [17127707](https://pubmed.ncbi.nlm.nih.gov/17127707/).
5. Tanaka M, Fernandez-del CC, Adsay V, Chari S, Falconi M, Jang JY, et al. International consensus guidelines 2012 for the management of IPMN and MCN of the pancreas. *Pancreatology*. 2012; 12(3):183–97. doi: [10.1016/j.pan.2012.04.004](https://doi.org/10.1016/j.pan.2012.04.004) PMID: [22687371](https://pubmed.ncbi.nlm.nih.gov/22687371/).
6. Hwang DW, Jang JY, Lee SE, Lim CS, Lee KU, Kim SW. Clinicopathologic analysis of surgically proven intraductal papillary mucinous neoplasms of the pancreas in SNUH: a 15-year experience at a single academic institution. *Langenbecks Arch Surg*. 2012; 397(1):93–102. doi: [10.1007/s00423-010-0674-6](https://doi.org/10.1007/s00423-010-0674-6) PMID: [20640860](https://pubmed.ncbi.nlm.nih.gov/20640860/).
7. Gourgiotis S, Ridolfini MP, Germanos S. Intraductal papillary mucinous neoplasms of the pancreas. *Eur J Surg Oncol*. 2007; 33(6):678–84. doi: [10.1016/j.ejso.2006.11.031](https://doi.org/10.1016/j.ejso.2006.11.031) PMID: [17207960](https://pubmed.ncbi.nlm.nih.gov/17207960/).
8. Zaruba P, Dvorakova T, Zavada F, Belina F, Ryska M. [Is accurate preoperative assessment of pancreatic cystic lesions possible?]. *Rozhl Chir*. 2013; 92(12):708–14. PMID: [24479516](https://pubmed.ncbi.nlm.nih.gov/24479516/).
9. Baba T, Yamaguchi T, Ishihara T, Kobayashi A, Oshima T, Sakaue N, et al. Distinguishing benign from malignant intraductal papillary mucinous tumors of the pancreas by imaging techniques. *Pancreas*. 2004; 29(3):212–17. PMID: [15367887](https://pubmed.ncbi.nlm.nih.gov/15367887/).
10. Whiting PF, Rutjes AW, Westwood ME, Mallett S, Deeks JJ, Reitsma JB, et al. QUADAS-2: a revised tool for the quality assessment of diagnostic accuracy studies. *Ann Intern Med*. 2011; 155(8):529–36. doi: [10.7326/0003-4819-155-8-201110180-00009](https://doi.org/10.7326/0003-4819-155-8-201110180-00009) PMID: [22007046](https://pubmed.ncbi.nlm.nih.gov/22007046/).
11. Walter SD. Properties of the summary receiver operating characteristic (SROC) curve for diagnostic test data. *Stat Med*. 2002; 21(9):1237–56. doi: [10.1002/sim.1099](https://doi.org/10.1002/sim.1099) PMID: [12111876](https://pubmed.ncbi.nlm.nih.gov/12111876/).
12. Rosman AS, Korsten MA. Application of summary receiver operating characteristics (sROC) analysis to diagnostic clinical testing. *Adv Med Sci*. 2007; 52(76–82).
13. Higgins JP, Thompson SG. Quantifying heterogeneity in a meta-analysis. *Stat Med*. 2002; 21(11):1539–58. doi: [10.1002/sim.1186](https://doi.org/10.1002/sim.1186) PMID: [12111919](https://pubmed.ncbi.nlm.nih.gov/12111919/).
14. Deeks JJ, Macaskill P, Irwig L. The performance of tests of publication bias and other sample size effects in systematic reviews of diagnostic test accuracy was assessed. *J Clin Epidemiol*. 2005; 58(9):882–93. doi: [10.1016/j.jclinepi.2005.01.016](https://doi.org/10.1016/j.jclinepi.2005.01.016) PMID: [16085191](https://pubmed.ncbi.nlm.nih.gov/16085191/).
15. Fritz S, Hackert T, Hinz U, Hartwig W, Buchler MW, Werner J. Role of serum carbohydrate antigen 19–9 and carcinoembryonic antigen in distinguishing between benign and invasive intraductal papillary mucinous neoplasm of the pancreas. *Br J Surg*. 2011; 98(1):104–10. doi: [10.1002/bjs.7280](https://doi.org/10.1002/bjs.7280) PMID: [20949535](https://pubmed.ncbi.nlm.nih.gov/20949535/).
16. Goh BKP, Tan Y, Thng C, Cheow P, Chung YA, Chow PKH, et al. How Useful Are Clinical, Biochemical, and Cross-Sectional Imaging Features in Predicting Potentially Malignant or Malignant Cystic Lesions of the Pancreas? Results from a Single Institution Experience with 220 Surgically Treated Patients. *J Am Coll Surgeons*. 2008; 206(1):17–27. doi: [10.1016/j.jamcollsurg.2007.06.312](https://doi.org/10.1016/j.jamcollsurg.2007.06.312) PMID: [18155564](https://pubmed.ncbi.nlm.nih.gov/18155564/).
17. Grobmyer SR, Cance WG, Copeland EM, Vogel SB, Hochwald SN. Is there an indication for initial conservative management of pancreatic cystic lesions? *J Surg Oncol*. 2009; 100(5):372–74. doi: [10.1002/jso.21260](https://doi.org/10.1002/jso.21260) PMID: [19267387](https://pubmed.ncbi.nlm.nih.gov/19267387/).
18. Hirono S, Tani M, Kawai M, Okada K, Miyazawa M, Shimizu A, et al. The Carcinoembryonic Antigen Level in Pancreatic Juice and Mural Nodule Size Are Predictors of Malignancy for Branch Duct Type Intraductal Papillary Mucinous Neoplasms of the Pancreas. *Ann Surg*. 2012; 255(3):517–22. doi: [10.1097/SLA.0b013e3182444231](https://doi.org/10.1097/SLA.0b013e3182444231) PMID: [22301608](https://pubmed.ncbi.nlm.nih.gov/22301608/).

19. Kitagawa Y, Unger TA, Taylor S, Kozarek RA, Traverso LW. Mucus is a predictor of better prognosis and survival in patients with intraductal papillary mucinous tumor of the pancreas. *J Gastrointest Surg.* 2003; 7(1):12–18, 18-19. PMID: [12559180](#).
20. Jones NB, Hatzaras I, George N, Muscarella P, Ellison EC, Melvin WS, et al. Clinical factors predictive of malignant and premalignant cystic neoplasms of the pancreas: a single institution experience. *HPB.* 2009; 11(8):664–70. doi: [10.1111/j.1477-2574.2009.00114.x](#) PMID: [20495634](#).
21. Shin SH, Han DJ, Park KT, Kim YH, Park JB, Kim SC. Validating a Simple Scoring System to Predict Malignancy and Invasiveness of Intraductal Papillary Mucinous Neoplasms of the Pancreas. *World J Surg.* 2010; 34(4):776–83. doi: [10.1007/s00268-010-0416-5](#) PMID: [20127242](#).
22. Xu B, Zheng W, Jin D, Ding W, Lou W, Ramsahok L. Predictive Value of Serum Carbohydrate Antigen 19–9 in Malignant Intraductal Papillary Mucinous Neoplasms. *World J Surg.* 2011; 35(5):1103–09. doi: [10.1007/s00268-011-1003-0](#) PMID: [21416173](#).
23. Sperti C, Bissoli S, Pasquali C, Frison L, Liessi G, Chierichetti F, et al. 18-fluorodeoxyglucose positron emission tomography enhances computed tomography diagnosis of malignant intraductal papillary mucinous neoplasms of the pancreas. *Ann Surg.* 2007; 246(6):932–37, 937-39. doi: [10.1097/SLA.0b013e31815c2a29](#) PMID: [18043094](#).
24. Ohtsuka T, Kono H, Nagayoshi Y, Mori Y, Tsutsumi K, Sadakari Y, et al. An increase in the number of predictive factors augments the likelihood of malignancy in branch duct intraductal papillary mucinous neoplasm of the pancreas. *Surgery.* 2012; 151(1):76–83. doi: [10.1016/j.surg.2011.07.009](#) PMID: [21875733](#).
25. Ingkakul T, Sadakari Y, Ienaga J, Satoh N, Takahata S, Tanaka M. Predictors of the Presence of Concomitant Invasive Ductal Carcinoma in Intraductal Papillary Mucinous Neoplasm of the Pancreas. *Ann Surg.* 2010; 251(1):70–75.
26. Hwang DW, Jang J, Lim C, Lee SE, Yoon Y, Ahn YJ, et al. Determination of Malignant and Invasive Predictors in Branch Duct Type Intraductal Papillary Mucinous Neoplasms of the Pancreas: A Suggested Scoring Formula. *J Korean Med Sci.* 2011; 26(6):740. doi: [10.3346/jkms.2011.26.6.740](#) PMID: [21655058](#).
27. Sadakari Y, Ienaga J, Kobayashi K, Miyasaka Y, Takahata S, Nakamura M, et al. Cyst size indicates malignant transformation in branch duct intraductal papillary mucinous neoplasm of the pancreas without mural nodules. *Pancreas.* 2010; 39(2):232–36. doi: [10.1097/MPA.0b013e3181bab60e](#) PMID: [19752768](#).
28. Edirimanne S, Connor SJ. Incidental pancreatic cystic lesions. *World J Surg.* 2008; 32(9):2028–37. doi: [10.1007/s00268-008-9633-6](#) PMID: [18553049](#).
29. Klibansky DA, Reid-Lombardo KM, Gordon SR, Gardner TB. The clinical relevance of the increasing incidence of intraductal papillary mucinous neoplasm. *Clin Gastroenterol Hepatol.* 2012; 10(5):555–58. doi: [10.1016/j.cgh.2011.12.029](#) PMID: [22210438](#).
30. Al-Haddad M, Gill KR, Raimondo M, Woodward TA, Krishna M, Crook JE, et al. Safety and efficacy of cytology brushings versus standard fine-needle aspiration in evaluating cystic pancreatic lesions: a controlled study. *Endoscopy.* 2010; 42(2):127–32. doi: [10.1055/s-0029-1215351](#) PMID: [19998218](#).
31. Dudeja V, Allen PJ. Premalignant cystic neoplasms of the pancreas. *Semin Oncol.* 2015; 42(1):70–85. doi: [10.1053/j.seminoncol.2014.12.007](#) PMID: [25726053](#).
32. Hong HS, Yun M, Cho A, Choi JY, Kim MJ, Kim KW, et al. The utility of F-18 FDG PET/CT in the evaluation of pancreatic intraductal papillary mucinous neoplasm. *Clin Nucl Med.* 2010; 35(10):776–79. doi: [10.1097/RLU.0b013e3181e4da32](#) PMID: [20838285](#).
33. Tan L, Zhao YE, Wang DB, Wang QB, Hu J, Chen KM, et al. Imaging features of intraductal papillary mucinous neoplasms of the pancreas in multi-detector row computed tomography. *World J Gastroenterol.* 2009; 15(32):4037–43. PMID: [19705500](#). doi: [10.3748/wjg.15.4037](#)
34. Tomimaru Y, Takeda Y, Tatsumi M, Kim T, Kobayashi S, Marubashi S, et al. Utility of 2-[18F] fluoro-2-deoxy-D-glucose positron emission tomography in differential diagnosis of benign and malignant intraductal papillary-mucinous neoplasm of the pancreas. *Oncol Rep.* 2010; 24(3):613–20. PMID: [20664965](#).
35. Cone MM, Rea JD, Diggs BS, Billingsley KG, Sheppard BC. Endoscopic ultrasound may be unnecessary in the preoperative evaluation of intraductal papillary mucinous neoplasm. *HPB (Oxford).* 2011; 13(2):112–16. doi: [10.1111/j.1477-2574.2010.00254.x](#) PMID: [21241428](#).
36. Sultana A, Jackson R, Tim G, Bostock E, Psarelli EE, Cox TF, et al. What Is the Best Way to Identify Malignant Transformation Within Pancreatic IPMN: A Systematic Review and Meta-Analyses. *Clin Transl Gastroenterol.* 2015; 6(e130). doi: [10.1038/ctg.2015.60](#) PMID: [26658837](#).
37. Anand N, Sampath K, Wu BU. Cyst features and risk of malignancy in intraductal papillary mucinous neoplasms of the pancreas: a meta-analysis. *Clin Gastroenterol Hepatol.* 2013; 11(8):913–21, e59-60. doi: [10.1016/j.cgh.2013.02.010](#) PMID: [23416279](#).

38. Ngamruengphong S, Bartel MJ, Raimondo M. Cyst carcinoembryonic antigen in differentiating pancreatic cysts: a meta-analysis. *Dig Liver Dis.* 2013; 45(11):920–26. doi: [10.1016/j.dld.2013.05.002](https://doi.org/10.1016/j.dld.2013.05.002) PMID: [23790480](https://pubmed.ncbi.nlm.nih.gov/23790480/).
39. Suzuki R, Thosani N, Annangi S, Guha S, Bhutani MS. Diagnostic yield of EUS-FNA-based cytology distinguishing malignant and benign IPMNs: a systematic review and meta-analysis. *Pancreatology.* 2014; 14(5):380–84. doi: [10.1016/j.pan.2014.07.006](https://doi.org/10.1016/j.pan.2014.07.006) PMID: [25278308](https://pubmed.ncbi.nlm.nih.gov/25278308/).
40. Kauhanen S, Rinta-Kiikka I, Kemppainen J, Gronroos J, Kajander S, Seppanen M, et al. Accuracy of 18F-FDG PET/CT, Multidetector CT, and MR Imaging in the Diagnosis of Pancreatic Cysts: A Prospective Single-Center Study. *J Nucl Med.* 2015; 56(8):1163–68. doi: [10.2967/jnumed.114.148940](https://doi.org/10.2967/jnumed.114.148940) PMID: [26045314](https://pubmed.ncbi.nlm.nih.gov/26045314/).
41. Grenacher L, Strau A, Bergmann F, Birdsey M, Mayerle J. Cyst Features and Risk of Malignancy in Intraductal Papillary Mucinous Neoplasms of the Pancreas: Imaging and Pathology. *Viszeralmedizin.* 2015; 31(1):31–37. doi: [10.1159/000375254](https://doi.org/10.1159/000375254) PMID: [26288613](https://pubmed.ncbi.nlm.nih.gov/26288613/).
42. Guo X, Zhan X, Li Z. Molecular Analyses of Aspirated Cystic Fluid for the Differential Diagnosis of Cystic Lesions of the Pancreas: A Systematic Review and Meta-Analysis. *Gastroent Res Pract.* 2016; 2016(1–08). doi: [10.1155/2016/3546085](https://doi.org/10.1155/2016/3546085) PMID: [26819604](https://pubmed.ncbi.nlm.nih.gov/26819604/).