

The Utility of ^{99m}Tc -mercaptoacetyltriglycine Renogram in Assessing the Baseline Renal Function of a Rare Incidental Ectopic Thoracic Kidney

Ting-Ting Zhang, Adanna Oparandu, Ziauddin Saad

Department of Nuclear Medicine, Addenbrooke's Hospital, Cambridge University Hospitals NHS Foundation Trust, CB2 0QQ, UK

Abstract

Ectopic thoracic kidney is an extremely rare condition caused by the abnormal location of one or both kidneys in the thoracic cavity. They are usually discovered incidentally on routine imaging. Although commonly asymptomatic, thoracic kidneys are at a risk of malrotation, pelviureteric junction obstruction, and subsequent obstructive nephropathy, by virtue of their long pedicle. We present a case report of an incidental thoracic kidney, for which a ^{99m}Tc -mercaptoacetyltriglycine (^{99m}Tc -MAG3) renogram was performed to assess the baseline renal function. Although few reports are published in the literature using ^{99m}Tc -MAG3 renogram for this indication, we demonstrate a safe and feasible study to establish a baseline assessment of renal function in this group of patients.

Keywords: ^{99m}Tc -mercaptoacetyltriglycine renogram, ectopic kidney, renal ectopia, thoracic kidney

Introduction

Renal ectopia is a developmental anomaly characterized by the abnormal location of one or both kidneys. The rarest of these is a thoracic kidney with an incidence of <1 in 10,000, accounting for <5% of all renal ectopias.^[1] Thoracic kidneys are discovered incidentally on routine imaging such as ultrasound, intravenous pyelography, intravenous urography, and on computed tomography (CT). This case report highlights the utility of ^{99m}Tc -mercaptoacetyltriglycine (^{99m}Tc -MAG3) renogram in the baseline assessment of a rare ectopic kidney, incidentally identified on conventional radiography.

Address for correspondence:

Dr. Ziauddin Saad, Department of Nuclear Medicine, Addenbrooke's Hospital, Cambridge University Hospitals NHS Foundation Trust, CB2 0QQ, UK.
E-mail: ziauddin_z@yahoo.com

Access this article online

Quick Response Code:



Website:
www.wjnm.org

DOI:
10.4103/1450-1147.215488

Case Report

A previously fit and well 6-month-old boy presented with a history of cough for 6 weeks and underwent a chest radiograph [Figure 1]. This revealed a well-defined intrathoracic mass, abutting the left hemidiaphragm. Subsequently, a CT study was arranged to further characterize the finding [Figure 2]. This revealed a kidney within the posterior mediastinum, above a normal left hemidiaphragm. Detailed past medical history revealed normal physiological and age-specific milestones, with no developmental anomalies. Therefore, the patient was referred to our Nuclear Medicine Department for a ^{99m}Tc -MAG3 study to assess the renal function and handling of tracer in the ectopic kidney.

This is an open access article distributed under the terms of the Creative Commons Attribution-NonCommercial-ShareAlike 3.0 License, which allows others to remix, tweak, and build upon the work non-commercially, as long as the author is credited and the new creations are licensed under the identical terms.

For reprints contact: reprints@medknow.com

How to cite this article: Zhang TT, Oparandu A, Saad Z. The utility of ^{99m}Tc -mercaptoacetyltriglycine renogram in assessing the baseline renal function of a rare incidental ectopic thoracic kidney. World J Nucl Med 2017;16:311-3.

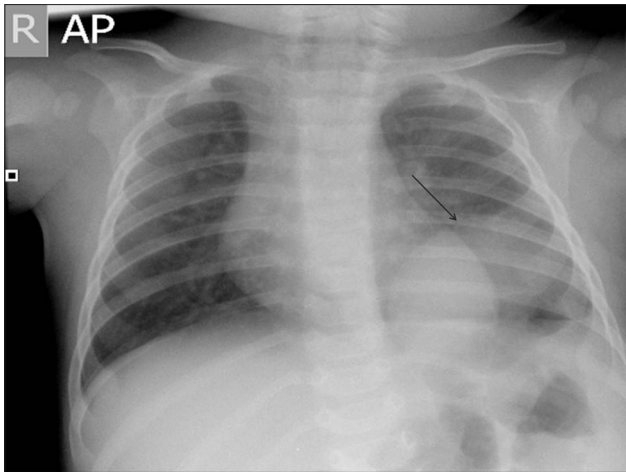


Figure 1: Chest radiograph demonstrating an ovoid mass in the left hemithorax, abutting the left hemidiaphragm

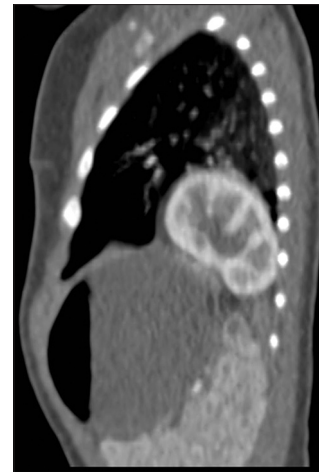

Figure 2: Sagittal reconstruction of computed tomography thorax demonstrates an intrathoracic kidney

After weight measurements, 21MBq of ^{99m}Tc -MAG-3 and 8.2 mg of furosemide were administered through a cannula at the start of dynamic imaging (time-0). Dynamic image acquisition was undertaken at a rate of 20 s per frame for 30 min (90 frames in total). The data were analyzed using the GE Discovery Xeleris view 3 functional imaging workstation software (Medical systems Milwaukee, Wisconsin, 2000).

Results

The ^{99m}Tc -MAG3 study demonstrated an ectopically placed left kidney in the left hemithorax with the right kidney located in the normal anatomical position [Figure 3]. Both kidneys demonstrated good perfusion, adequate tracer uptake, and rapid transit of activity to the pelvicalyceal systems. The excretory pattern (under furosemide flow rates; time-0) was observed to be brisk, with no evidence of hold up or obstruction. The differential function was found to be essentially within the normal range, with the left kidney at 44% and the right kidney at 56%.

Discussion

Renal embryogenesis involves cranial migration of kidneys from the pelvis to its normal retroperitoneal anatomical location. This embryonic process can be arrested at any point along its path resulting in renal ectopia, usually inferior to its normal position. On rare occasion, the kidney can ascend to a higher location, resulting in a thoracic kidney. The exact mechanism of this is still unclear. However, it has been postulated that delayed closure of the pleuroperitoneal membrane may allow excessive renal ascent.^[2] Alternatively, delayed differentiation of the metanephrogenic tissue may cause the renal ascent to be prolonged.^[1]

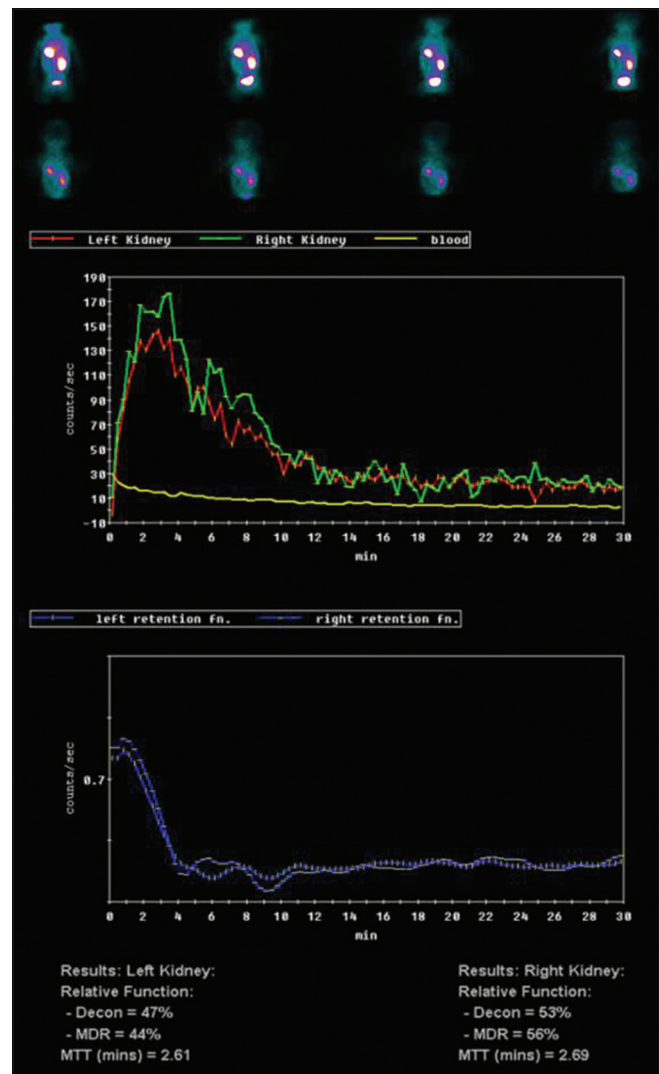


Figure 3: ^{99m}Tc mercaptoacetyltriglycine renogram shows the ectopic intrathoracic location of the left kidney. Both kidneys demonstrate a good tracer uptake, rapid transit of activity to the pelvicalyceal system, and unobstructed clearance of tracer

Most ectopic thoracic kidneys are separated from the pleural cavity by a thin layer of pleura,^[3] with the renal vasculature and ureters forming a long pedicle which exits through the foramen of Bochdalek. This can predispose to malrotation, with subsequent pelviureteric junction obstruction, obstructive nephropathy, and eventual renal scarring. However, the majority of ectopic kidneys remain asymptomatic.

The choice of radiopharmaceuticals used in assessing renal function varies between departments. In the past three decades, there has been a shift in preference toward ^{99m}Tc -MAG3 due to its better target-to-background scintigraphic imaging properties, especially in patients in whom renal failure is anticipated. ^{99m}Tc -diethylenetriaminepentaacetic acid (DTPA), on the other hand, is still the radiopharmaceutical choice for departments utilizing its ability to measure the glomerular filtration rate. ^{99m}Tc -dimercaptosuccinic acid (DMSA) is preferred when the clinical question pertains to renal scarring, absolute divided renal function, or the detection of functioning renal parenchyma at native or ectopic sites. To date, there are few case reports in the literature utilizing ^{99m}Tc -MAG3, ^{99m}Tc -DTPA, and ^{99m}Tc -DMSA^[4,5] in this rare group of patients. We demonstrate that ^{99m}Tc -MAG3 renogram is a safe and

feasible study to establish a baseline functional renal assessment in terms of comprehensive radiotracer handling in ectopic thoracic kidneys and to confirm various potential drainage patterns.^[6]

Financial support and sponsorship

Nil.

Conflicts of interest

There are no conflicts of interest.

References

1. Donat SM, Donat PE. Intrathoracic kidney: A case report with a review of the world literature. *J Urol* 1988;140:131-3.
2. Yalcinbas YK, Sasmaz H, Canbaz S. Thoracic left kidney: A differential diagnosis dilemma for thoracic surgeons. *Ann Thorac Surg* 2001;72:281-3.
3. Panossian DH, Thomas RD, Anholm JD. Asymptomatic mediastinal mass in an elderly man. *Chest* 1995;107:1165-6.
4. Aydin HI, Sarici SU, Alpay F, Gökçay E. Thoracic ectopic kidney in a child: A case report. *Türk J Pediatr* 2000;42:253-5.
5. Padma S, Pande SR, Sundaram PS. (99m) Tc DTPA renogram identifies Bochdalek hernia with an intra thoracic kidney as its content. *World J Nucl Med* 2014;13:193-6.
6. Toba M, Fukuchi K, Hayashida K, Takeda Y, Fukushima K. Intrathoracic mass simulated by ectopic kidney. *Clin Nucl Med* 2000;25:289-90.