CASE REPORT – OPEN ACCESS

International Journal of Surgery Case Reports 28 (2016) 4–8

Contents lists available at ScienceDirect

International Journal of Surgery Case Reports

journal homepage: www.casereports.com

Abdominal tuberculosis that masked under the early postoperative septic complications

Oleksii Lukavetskyy, Nina Boyko, Volodymyr Fedorov, Oleksii Ogurtsov*, Yaroslav Havrysh*

Surgery No. 1 Department, Danylo Halytsky Lviv National Medical University Nekrasova Street 4, Lviv,79010, Ukraine

ARTICLE INFO

Article history:
Received 21 March 2016
Received in revised form 8 May 2016
Accepted 14 May 2016
Available online 19 May 2016

Keywords:
Abdominal tuberculosis
Septic complications
Laparoscopic adrenalectomy
Relaparoscopy

ABSTRACT

INTRODUCTION: At the same time even laparoscopic adrenalectomy can become the source or the causing factor of a number of complications. In the following report we present the clinic case of diagnostic complications during postsurgical period of "rapid" development and signs of tuberculosis after laparoscopic adrenalectomy.

PRESENTATION OF CASE: The patient underwent ultrasonography and CT was found out: the tumor of right adrenal gland. Operational treatment: right laparoscopy adrenalectomy. Pathologistological conclusion: clear cell adenoma. On the fourth day there was a high temperature rise noted 38–39 °C. On the 10th day the CT, where there were no signs of free liquid abscess formation. Relaparoscopic: small amount of serous-hemorrhagic liquid in small pelvis, hyperemated peritoneum, in both – left and right liver lobes tight knots of white color. After, the patient still had hyperthermia 38 °C. Phthisiatrician consulted the patient and diagnosed abdominal tuberculosis. After six-month treatment the patient in satisfactory condition was discharged home.

DISCUSSION: But in case of our patient's case such visual diagnostic methods, such as CT and ultrasonography of abdominal cavity appeared to be non-informative in lymph system diagnostics due to the number of reasons.The described clinical case and literature data prove the fact, that crucial in abdominal tuberculosis form management treatment is a diagnostic laparoscopy with tissue biopsy.

CONCLUSION: Labors, as well as adrenalectomy are possible factors which decrease the immunity and can cause the activation of tuberculosis process. Diagnostic laparoscopy and intraoperative histological tissue study of abdominal cavity are the main points in prescribing diagnosis of abdominal tuberculosis form.

1. Introduction

In the past, adrenal tumors were diagnosed sporadically – no more than 0.6% of all malignant tumors. Today, owing to visual diagnostic methods such as ultrasonic scanning (US), computer tomography (CT) and magnetic resonance tomography (MRT) the diagnostic frequency of retroperitoneal space tumors has increased. According to CT and MRT, the frequency identification of tumor over 0.5sm in an adrenal gland is 1–2%, after autopsy – 6% [21]. Adrenal tumors are more common among younger patients: up to 20 years old (25%); 21–40 years old – (32%); 41–60 years old (28%); older than 60 years old (15%) [22].

Laparoscopic adrenalectomy is generally accepted "golden standard" to treat patients with benign adrenal tumors [2,3,6–9]. The first laparoscopic surgery on adrenal gland was performed in 1992 [1,18,19,20]. According to the literature on the subject the number of postsurgical complications after laparoscopic adrenalectomy is 4.1%, 3% out of which need the second operation for its elimination [23,10]. At the same time even laparoscopic adrenalectomy can become the source or the causing factor of a number of complications. In the following report we present the clinic case of diagnostic complications during postsurgical period of "rapid" development and signs of tuberculosis after laparoscopic adrenalectomy.

2. Presentation of case

A female patient approached a clinic for an additional diagnostics and treatment of adrenal tumor, which had been detected on a regular US a year before. During the following year, patient's general health state was satisfactory, but some episodic blood pressure increases till 150/80 mmHg were observed.

* Corresponding authors.
E-mail addresses: surgery1lnmu@ukr.net (O. Lukavetskyy), boyko.surgery@gmail.com (N. Boyko), surgeon.fedorov@gmail.com (V. Fedorov), o.ogurtsov@gmail.com (O. Ogurtsov), havryshy@yahoo.com (Y. Havrysh).

http://dx.doi.org/10.1016/j.ijscr.2016.05.023

Fig. 1. CT image: (A) transverse (B) sagittal (C) coronal.

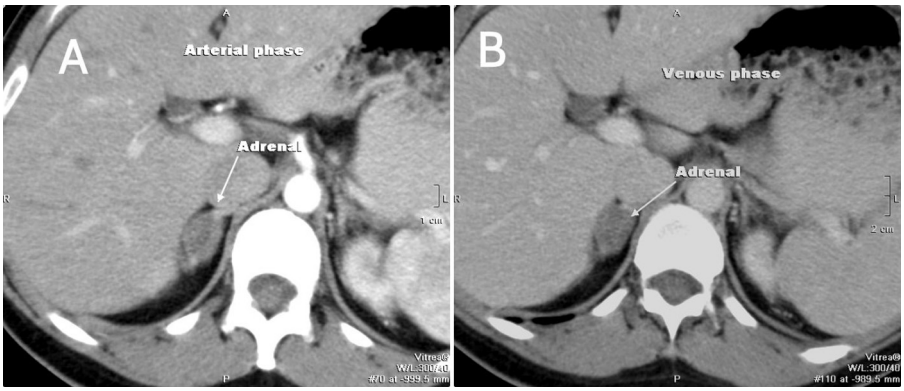

Fig. 2. CT image (A) arterial phase (B) venouse phase.

There were virtually no complaints on admission to hospital. During the check-up, the patient's state was satisfactory, body mass index was 22.2 kg/m2, body constitution – normostenic. The skin was pale pink without any formations or eruption. Hereditary anamnesis was non-aggravated. Biochemical blood analysis, general blood and urine analyses were without any deviations from norms. The level of cortisol hormones in a 24 h urine (115 m kg/24 h) with the normal value 28.5–213.7 m kg/24 h and aldosterone in vein blood (95 pg/ml) with the normal value 10,0–160 pg/ml, as well as adrenaline (18 m kg/24 h) with the normal value 20 m kg/24 h, and metanephrine levels (76 m kg/24 h) with the normal value 6–115 mkg/24 h conformed to the norm.

The patient underwent ultrasonography and multi spiral computed tomography of abdominal cavity organs and extraperitoneal space during which the following was found out: the tumor of right adrenal gland 26 × 16, oval, tissue texture, heterogeneous structure. During the CT procedure the existence of tumor in above-mentioned size was proved, which absorbed the contrast liquid non-linearly: in negative phase – 8(HU), in venous phase – 58 (HU), in acute phase 25 (HU) (Figs. 1 and 2). The above mentioned characteristics and the results of medical examinations were the background for surgical treatment of the adrenal tumor. The patient underwent operational treatment: right laparoscopy adrenalectomy. The bed of adrenal was drained with two polychlor vinyl tubes, which were taken out on the frontal abdominal netting front inguinal line on the right via counteropening. Macro: adrenal gland had a 26 × 16 tumor in a capsule, orange with distinctive borders (Fig. 3).

2.1. Pathologistological conclusion: clear cell adenoma of adrenal cortex

The early postsurgical period passed without any peculiarities. There were secretions of serous hemorrhage nature through drainage: 1 st 24 h (80 ml), 2nd (40 ml), 3d (25 ml). Drainages were taken out on the third day. On the fourth day there was a high temperature rise noted 38–39 °C. During the week infusion and antibiotics therapies (cephalosporins 3d generation – 1 g 2 t.d. intravenously) were applied, but with no results. There were changes to the general blood tests on the 5th day: leukocytes 11.3 10^{9}/L, band neutrophils number rose to 9%, haemoglobin 99 g/l. Biochemical blood and urine analyses were without any pathological changes. In control US of abdominal cavity and abdominal bed there were no signs of liquid accumulation, but thickened hypoechoic adrenal parenchyma caught the attention. Patient's well-being was not improving. After the following US on the 7th day of post-surgical period 30 × 10 × 14 liquid accumulation was noticed, virtually in the placed of abdominal ablation. It was located between a liver and middle third of right kidney, which was eliminated using puncture method controlled by US. The liquid of hemorrhagic nature, homogeneous, without pus admixture and unpleasant smell. Cytologic study of a puncture sample discovered that visual field was covered with erythrocytes, there were no other cells present. The patient continued suffering form high fever. On the 10th day the CT of abdominal cavity and extraperitoneal space was conducted, where there were no signs of free liquid abscess formation in abdominal cavity or retroperitoneal space. The patient was qualified as the one needing second diagnostic laparoscopic reintervention. During the operation there was a small amount of serous-hemorrhagic liquid in small pelvis, hyperemated peritoneum, in both – left and right liver lobes tight knots of white color (diameter – 1.5 mm) (Fig. 5), no liquid accumulation discovered. In the bed area of right epinephros (Fig. 4) there were spotted three tight knots in size 4 mm with non-linear border and thick consistency and afterwards they were taken to biopsy. Cytologic study of intraoperative material showed that a huge amount of neutral fat was identified on the background of non-structural and fibrous substances, just a few connecting tissue cells were without

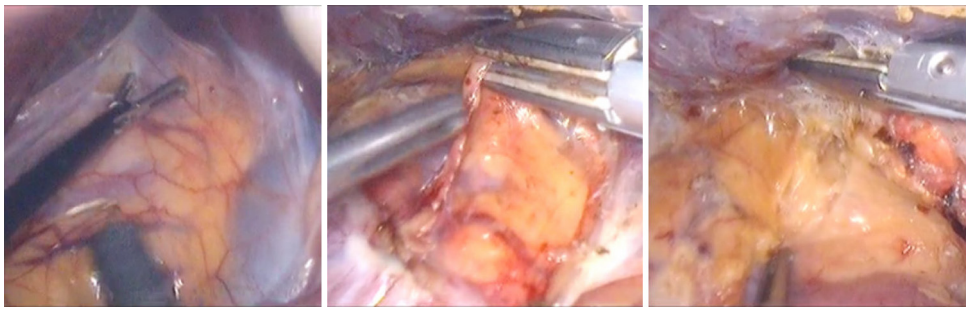

Fig. 3. Right laparoscopy adrenalectomy.

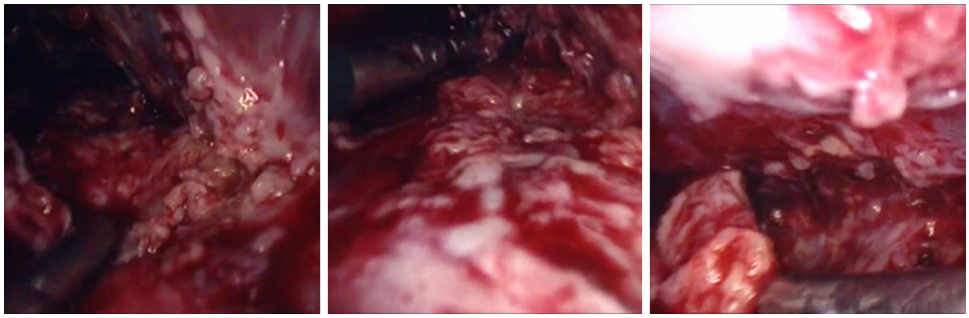

Fig. 4. Relaparoscopy: area of right epinephros.

Fig. 5. Three tight knots.

any changes in cells morphology. Histological conclusion: granulomatous inflammation with morphological signs of mycobacterial infection.

After relaparoscopy procedure, the patient still had hyperthermia 38–39 °C. Phthisiatrician consulted the patient and diagnosed abdominal tuberculosis. While the patient was transferred to inpatient department for extrapulmonary tuberculosis patients, the following changes of laboratory tests were observed: haemoglobin 80 g/l, leukocytes- 10/l, band neutrophils-14%, рівень ESR- 61 mm/h, ALAT-244 IU/L, ALT- 536IU/L. Mantoux test – 2 tuberculin units 10/58, papule – 14 mm, sputum test on APB – negative, AIDs-negative. X-ray radiography did not shown any pathological changes. The following treatment was prescribed to the patient: Isoniazidum (15 mg/kg), Etanbutol (25 mg/kg) for 6 months, anti-inflammatory and disintoxicating therapy. After six-month treatment the patient in satisfactory condition was discharged home.

3. Discussion

Tuberculosis is an infection disease that occurs in Europe. However, there should be stated a steady decrease in sickness rate for an active lung tuberculosis phase due to the early diagnostic and timely treatment. Yet sickness rate of extrapulmonary tuberculosis remains the same, most of all, due to the late diagnostic, when symptoms manifestation mainly consists of non-specific systemic and extrapulmonary appearance [10].

It is known that tuberculosis mycobacteria penetrate into the abdominal cavity in three main ways: peroral – spread on peritoneum from infected neighbouring cores and hematogenic spreading. From hematogenic spread to the progressive abdominal tuberculosis form, several years may pass, as the source of latent infection could be in a state of peace until reactivation [11], as we observed it in our patient's case.

According to the related literature there are three diagnostic phases of abdominal tuberculosis form [13]. First two involve the clinical patient evaluation and X-ray radiography study. The third stage involves invasive methods, which are crucial for the final diagnosis verification. In the above described case, clinical development of abdominal tuberculosis form, were non-specific ones, thus, similar to SIRS symptoms. Those circumstances led to diagnostic delay and nonspecific treatment, as a result of complications development. The most common clinical symptoms and indications for abdominal tuberculosis form patients are abdominal pain, bloating, ascites, fever, icterus and weight loss. According to the relevant literature, in 84.9% extrapulmonary tuberculosis

cases fever is observed [17]. In the described case, the primary symptoms that indicated the development of early pus-septic complication were torpid fever, leucocytosis and a rise in number of stab neutrophils in general blood analysis. It is worth mentioning, that clinical picture was extremely fast, meaning that symptoms developed in 12 h. We are of the mind, that the torpid tuberculosis form or immunodeficiency were the cause of this. In the stated case, the development of secondary immunodeficiency in patient is the consequence of recent labor and surgery interference, which acted as a trigger for the latent tuberculosis bacteria activation. It should be admitted, that particular attention should be paid to the patients with anamnesis of preceding lung tuberculosis and immunodeficiency. According to the literature on a subject, hepatosplenomegaly in abdominal tuberculosis forms is diagnosted in 50–80% cases and occurs as a result of hematogenic spread of extrapulmonary tuberculosis or through the portal-vein system from gastointestinal traumas [4,5,14,15]. It should be stated here, that during activation phase of microbacteria adjacent regional lymph nodes and peritoneum are involved. From paaraortic and portal lymph nodes via the portal vein or hepatic artery system infection can spread on liver or spleen, with a further formation of macronodular tuberculosis hotbed in liver and spleen [12]. As a rule, peritoneum, lymph nodes and parenchymatous organs of abdominal cavity are involved in this process. But in case of our patient's case such visual diagnostic methods, such as CT and ultrasonography of abdominal cavity appeared to be non-informative in lymph system diagnostics due to the number of reasons:

1. The patient undergone CT without contrast that enabled visualization of minor lymph nodes.
2. According to CT results there were no enlarged lymph nodes (> 15 mm) which could have been treated as pathological ones.
3. Constitutional characteristics of the patient, in particular low content of intraperitoneal fat and intimate neighbouring of abdominal cavity wall to the organs.

The described clinical case and literature data [16,18] prove the fact, that crucial in abdominal tuberculosis form management treatment is a diagnostic laparoscopy with tissue biopsy.

4. Conclusions

1. Labors, as well as adrenalectomy are possible factors which decrease the immunity and can cause the activation of tuberculosis process.
2. With the clinical picture of pus-septical complications during the early postsurgical period without the diagnosis of infection source hotbed, it is worth conducting diagnostic laparoscopy with biopsy and the following cytologic study.
3. For correct diagnosis having vague clinical picture of surgical pathology of abdominal cavity organs, CT with contrast is advised to be used.
4. Pretentious presurgical diagnostics is required by patients with anamnesis of preliminary lung tuberculosis and immunodeficiency.
5. Diagnostic laparoscopy and intraoperative histological tissue study of abdominal cavity are the main points in prescribing diagnosis of abdominal tuberculosis form.

Conflicts of interest

None.

Funding

We have not any sources of funding for your research.

Ethical approval

Ethical committee approval Danylo Halytsky Lviv National Medical University.

Consent

Written informed consent was obtained from the patient for publication of this case report and accompanying images. A copy of the written consent is available for review by the Editor-in-Chief of this journal on request

Author contribution

Oleksii Lukavetskyy, Nina Boyko – concept and design.
Oleksii Ogurtsov, Volodymyr Fedorov – data analysis, interpretation, writing the paper.
Yaroslav Havrysh, Oleksii Ogurtsov, – data collection.

Guarantor

Oleksii Lukavetskyy MD, PhD, Professor.
Nina Boyko MD, PhD, Professor.
Volodymyr Fedorov, MD.
Oleksii Ogurtsov, MD.
Yaroslav Havrysh, MD, PhD.

References

[1] M. Gagner, et al., Laparoscopic adrenalectomy in cushing syndrome and pheochromocytoma, NEJM 327 (1992) 1033.
[2] A. Assalia, M. Gagner, Laparoscopic adrenalectomy, BJS 91 (2004) 1259.
[3] M.S. Choh, J.A. Madura, The role of minimally invasive treatments in surgical oncology, Surg. Clin. North Am. 89 (2009) 53.
[4] G. Conzo, M. Musella, F. Corcione, M. De Palma, N. Avenia, M. Milone, Della, C. Pietra, A. Palazzo, D. Parmeggiani, D. Pasquali, A. A.Sinisi, L. Santini, Laparoscopic treatment of pheochromocytomas smaller or larger than 6 cm. A clinical retrospective study on 44 patients. Laparoscopic adrenalectomy for pheochromocytoma, Ann. Ital. Chir. 84 (2016) 417–422.
[5] A. Toniato, I.M. Boschin, G. Opocher, A. Guolo, M. Pelizzo, F. Mantero, Is the laparoscopic adrenalectomy for pheochromocytoma the best treatment? Surgery 141 (2007) 723–727.
[6] W.T. Shen, R. Grogan, M. Vriens, O.H. Clark, Q.Y. Duh, One hundred two patients with pheochromocytoma treated at a single institution since the introduction of laparoscopic adrenalectomy, Arch Surg. 145 (2010) 893–897.
[7] G. Bittner, M. Gershuni, D. Matthews, F. Moley, M. Brunt, Risk factors affecting operative approach, conversion, and morbidity for adrenalectomy: a single-institution series of 402 patients, Surg. Endosc. 277 (2013) 2342–2350.
[8] R. Sharma, A. Ganpule, Veeraman, M. i, Sabni, B. s, Desai, M, Laparoscopic management of adrenal lesions larger than 5 cm in diameter, Urol. J. 6 (2009) 254–259.
[9] Patryk Fiszer, Sadegh Toutounchi, Ryszard Pogorzelski, Ewa Krajewska, Bartosz Sutkowski, Piotr Gierej, Maciej Skórski, Adrenalectomy for pheochromocytoma versus other surgical indications, Videosurgery Other Miniinvasive Tech. 7 (2012) 144–146.
[10] R. Avasthi, D. Mohanty, S.C. Chaudhary, K. Mishra, Disseminated tuberculosis: interesting hematological observations, J. Assoc. Physicians India 58 (2010) 243–244.
[11] C. Hopewell, A clinical view of tuberculosis, Radiol. Clin. North Am. 33 (1995) 641–653.
[12] O. Akhan, J. Pringot, Imaging of abdominal tuberculosis, Eur. Radiol. 12 (2002) 312–323.
[13] O. Uygur-Bayramicli, G. Dabak, A clinical dilemma: abdominal tuberculosis, World J Gastroenterol. 9 (2003) 1098–1101.
[14] Z. Alvarez, R. Carpio, Hepatobiliary tuberculosis, Dig. Dis. Sci. 983 (28) (2016) 193–200.
[15] M. De Schepper, F. Vanhoenacker, A. Drevelengas, The Spleen in Infectious Disorder Medical Imaging of The Spleen, 7, Springer International Publishing AG, 2000, pp. 67–80.

[16] K. Alhajri, N. Alzerwi, K. Alsaleh, H. Yousef, M. Alzaben, Disseminated (miliary) abdominal tuberculosis after laparoscopic gastric bypass surgery, BMJ Case Rep. 12 (2011) 230.
[17] A.R. Miah, Y.R. Sharma, M.T. Rahman, A. Raihan, P.K. Roy, M. Hasan, Clinicopathological profile of patients with abdominal tuberculosis, J. Nepal Health Res. Counc. 9 (2011) 169–175.
[18] H.S. Park, S.A. Roman, J.A. Sosa, Outcomes from 3144 adrenalectomies in the United States: which matters more, surgeon volume or specialty? Arch. Surg. 144 (11) (2009) 1060–1067.
[19] J. Lubikowski, et al., From open to laparoscopic adrenalectomy: thirty years' experience of one medical centre, Endokrynol. Pol. 61 (1) (2010) 94–101.
[20] S. Gaujoux, et al., Risk factors for conversion and complications after unilateral laparoscopic adrenalectomy, Br. J. Surg. Soc. Ltd. 98 (2011) 1392–1399.
[21] Черенько С.М. Артериальная гипертензия и опухоли надпочечников // 100 избранных лекций по эндокринологии. Под ред. Ю.И. Караченцева, А.В. Казакова, Н.А. Кравчун, И.М. Ильиной. – Х., 2009. – С. 925-933.
[22] Кваченюк А.М., Комісаренко І.В., Рибаков С.І., Коваленко К.В. Тактика ведення хворих з пухлинами наднирникових залоз // Матеріали VII з'їзду ендокринологів України. – Київ, 15-18 травня 2007 р. – С. 102.
[23] O.A. Castillo, et al., Complications associated with laparoscopic adrenalectomy: description and standardized assessment, Actas. Urol. Esp. 10 (2014) 1016.