



Update Article

Turco's injury: diagnosis and treatment^{☆,☆☆}

Ana Paula Simões da Silva^{*}, Leandro Girardi Shimba,
Luiz Henrique Boraschi Vieira Ribas, Alexandre Simmonds de Almeida,
Vinicius Naves, Aires Duarte Júnior

Faculdade de Ciências Médicas da Santa Casa de São Paulo, Pavilhão Fernandinho Simonsen, São Paulo, SP, Brazil

ARTICLE INFO

Article history:

Received 2 May 2013

Accepted 16 July 2013

Available online 14 May 2014

Keywords:

Tarsal joints/injuries

Metatarsal bones

Bone fractures

Dislocations

ABSTRACT

The aim of this study was to alert doctors to the existence of Turco's injury and discuss the existing treatments that have been described in the worldwide literature. A bibliographic survey of Lisfranc's injury and Turco's injury covering from 1985 to 2013 was conducted in the SciELO and PubMed databases. Among the 193 articles, those relating to bone-ligament injuries of the Lisfranc joint and high-energy trauma were excluded, as were the case reports. The patients selected were professional or amateur athletes who solely presented a ligament injury to the Lisfranc joint (Turco's injury), which was diagnosed from the history, physical examination, radiographs and magnetic resonance images. Non-athletic patients and those with associated bone injuries were excluded (10). According to the injury classification, the patients were treated by means of either an open or a closed procedure and then a standard rehabilitation protocol. Out of the 10 patients, five underwent conservative treatment and five underwent surgical treatment using different techniques and synthesis materials. We obtained two poor results, one satisfactory, five good and two excellent. We conclude that the correct diagnosis has a direct influence on the treatment and on the final result obtained, and that lack of knowledge of this injury is the main factor responsible for underdiagnosing Turco's injury. There is a need for randomized prospective studies comparing the types of synthesis and evolution of treated cases, in order to define the best treatment for this injury.

© 2014 Sociedade Brasileira de Ortopedia e Traumatologia. Published by Elsevier Editora Ltda. Este é um artigo Open Access sob a licença de [CC BY-NC-ND](http://creativecommons.org/licenses/by-nc-nd/4.0/)

Lesão de Turco: diagnóstico e tratamento

R E S U M O

Este trabalho tem por objetivos alertar os médicos sobre a existência da lesão de Turco e discutir sobre os tratamentos existentes descritos na literatura mundial. Foi feito levantamento bibliográfico da lesão de Lisfranc e da lesão de Turco de 1985 a 2013 nas bases de dados Scielo e Pubmed. Dos 193 artigos, foram excluídos os com lesão osteoligamentar da articulação de Lisfranc, os por traumas de alta energia, os relatos de caso. Foram

Palavras-chave:

Articulações tarsianas/lesões

Ossos do metatarso

Fraturas ósseas

Luxações

[☆] Please cite this article as: da Silva APS, Shimba LG, Ribas LHBV, de Almeida AS, Naves V, Duarte Júnior A. Turco's injury: diagnosis and treatment. Rev Bras Ortop. 2014;49:321-327.

^{☆☆} Work performed in the Sports Traumatology Group, Department of Orthopedics and Traumatology, School of Medical Sciences, Santa Casa de São Paulo, Fernandinho Simonsen Wing.

^{*} Corresponding author.

E-mail: apaulass@gmail.com (A.P.S. da Silva).

2255-4971 © 2014 Sociedade Brasileira de Ortopedia e Traumatologia. Published by Elsevier Editora Ltda.

Este é um artigo Open Access sob a licença de [CC BY-NC-ND](http://creativecommons.org/licenses/by-nc-nd/4.0/) <http://dx.doi.org/10.1016/j.rboe.2014.04.018>

selecionados pacientes atletas profissionais ou amadores, com lesão ligamentar exclusiva da articulação de Lisfranc (lesão de Turco), a qual foi diagnosticada pela história, pelo exame físico, pelas radiografias e pela ressonância magnética. Como fatores de exclusão, pacientes não atletas e com lesões ósseas associadas (10). De acordo com a classificação da lesão, os pacientes foram tratados cruenta ou incruentamente e submetidos a um protocolo-padrão de reabilitação. Dos 10 pacientes, cinco foram submetidos a tratamento conservador e cinco a tratamento cirúrgico, por diferentes técnicas e materiais de síntese. Obtiveram-se dois resultados ruins, um satisfatório, cinco bons e dois excelentes. Concluímos que o diagnóstico correto influencia diretamente no tratamento e no resultado final obtido e que o desconhecimento da lesão é o principal responsável pelo subdiagnóstico da lesão de Turco. Há necessidade de estudos prospectivos randomizados que comparem os tipos de síntese e a evolução dos casos tratados para uma definição do melhor tratamento para tal lesão.

© 2014 Sociedade Brasileira de Ortopedia e Traumatologia. Publicado por Elsevier Editora Ltda. Este é um artigo Open Access sob a licença de [CC BY-NC-ND](#)

Introduction

The Lisfranc or tarsometatarsal joint is thus named in homage to the French physician Jacques Lisfranc, who was the first to describe an amputation through this joint.¹⁻⁴ This complex is formed by bone elements (base of the metatarsals, cuneiforms and cuboid) and ligaments that give structure and support to the transverse arch of the midfoot. Between the medial cuneiform and the second metatarsal, there is a strong oblique ligament called the Lisfranc ligament. This, in association with the effect of the most proximal fitting of the second metatarsal, forms the main stabilizer of this joint.^{1,3,5-8} The complex anatomy of bones and ligaments in this region, in association with the multiple injury patterns and mechanisms, makes radiographic interpretation and diagnosis a challenge, particularly in attending emergency cases.⁹

Dislocated fractures of the Lisfranc joint are unusual injuries of the foot and occur at a rate of 1:55,000 to 60,000 per year, which corresponds to 0.1% to 0.9% of all fractures. Approximately one third of these injuries go undiagnosed, which may lead to chronic pain in the foot affected, osteoarthritis and deformities.^{1,3,10-13} Among the various injury mechanisms that have been described, the commonest is plantar flexion over the metatarsals, in association with rotational stress.⁹ In this manner, it is important for physicians to become familiar with the types of presentation of Lisfranc dislocated fractures, and specifically the one discussed in this study, which bears the name of Turco's injury, given that early diagnosis and intervention are essential for better prognosis.^{14,15} Turco's injury is one in which there is a low-energy trauma mechanism that only causes ligament tears, with or without dislocation of this joint, and it occurs especially among athletes.⁹

This injury is therefore characterized by an opening of up to 5 mm in the intermetatarsal space of the first and second metatarsals, and it may range in severity, according to the classification of Nunley and Vertullo, from stage I to IV.¹⁶

Anatomy and biomechanics

Understanding the anatomy of the tarsometatarsal complex is essential for it to be possible to evaluate, diagnose and treat injuries to this joint. The stability of this complex is

achieved through bone architecture and ligament support. The first, second and third metatarsals articulate with the medial, intermediate and lateral cuneiforms, in this order, and the fourth and fifth metatarsals articulate with the cuboid. The second metatarsal not only lies between the first and third metatarsals, but also has a greater contact surface with the bones that surround it, given that the intermediate cuneiform is located more proximally than the medial and lateral cuneiforms. Thus, it has a lock-and-bolt fit that increases the stability.^{17,18}

In addition to the structured bone framework, there is a ligament support. The bones of the metatarsus are joined together by means of the dorsal and plantar intermetatarsal ligaments, as are also the cuneiforms and the cuboid, but there is no ligament that joins the base of the first metatarsal to the second metatarsal. There is also a variable network of longitudinal and oblique ligaments that secures the last four metatarsals to the cuneiforms and cuboid on the plantar and dorsal sides, along with two longitudinal ligaments that anchor the first metatarsal in the medial cuneiform.^{17,18}

The largest and strongest ligament of the tarsometatarsal complex is the so-called Lisfranc ligament. Its origin is in the lateral surface of the medial cuneiform and it is inserted into the medial face of the base of the second metatarsal^{17,18} (Fig. 1).

Physiopathology

Lisfranc injuries can be caused by direct or indirect mechanisms. Direct trauma to the dorsum of the foot is rare and may be complicated through contamination, vascular impairment and compartmental syndrome. Injuries through indirect mechanisms are responsible for most cases and result both from rotational forces applied to the forefoot with the hindfoot fixed and from axial loads on a fixed foot in plantar flexion.¹⁴

The commonest cause of indirect trauma that has been described in the literature is car accidents, which account for approximately 40% to 45% of the injuries.¹⁷ Other causes that have been described include acts of falling from a height, accidents with horses, motorcycle accidents and injuries in athletes.^{14,17}

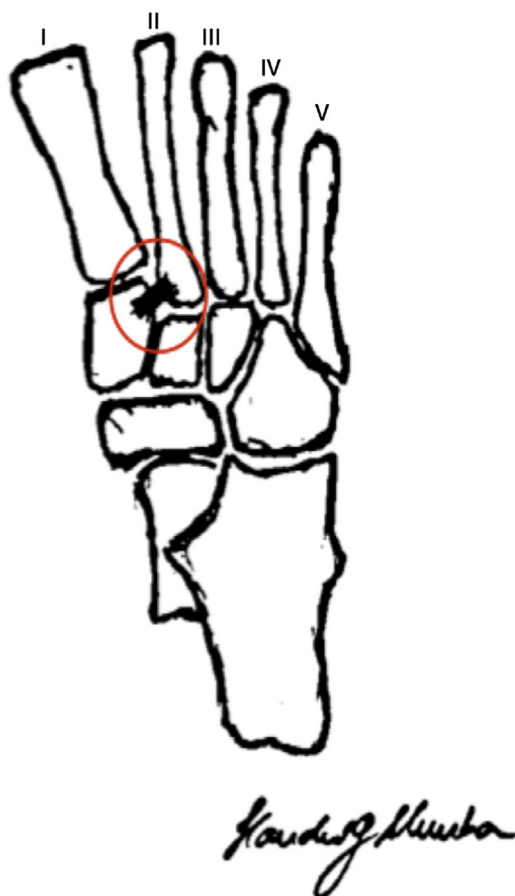


Fig. 1 – Representation of the bone anatomy of the midfoot and hindfoot, in which “lock-and-bolt” fitting of the second metatarsal with the cuneiforms was observed. The Lisfranc ligament is highlighted and the metatarsals (I to V) are identified.

Diagnosis

Well-conducted clinical history-taking and physical examination are fundamental for the diagnosis. Patients generally reveal the trauma mechanism and report having pain in the midfoot, varying greatly in intensity. They are generally asymptomatic when walking, but present pain when running, jumping and making other sports movements. It is important to locate the painful points. Pain on palpation between the base of the first and the second metatarsal is an important finding, even without injuries involving diastasis of the intermetatarsal space.^{12,15-17} Provocative tests may also be very helpful. The two tests most frequently used are lateral compression test and the axial stability test between the first and second metatarsals, which are positive when they reproduce pain in the midfoot. Shapiro et al.¹⁹ concluded that these two tests are positive when there is rupture of the Lisfranc ligament. There is also a specific test for tarsometatarsal injuries, which consists of passive pronation with abduction of the forefoot, with the hindfoot fixed. This maneuver produces pain at the site of the injured ligament.

Well-produced radiographs are also fundamental for the diagnosis. Anteroposterior (AP), lateral (L) and oblique (O) views should be produced, with loading if possible. A comparison with radiographs on the contralateral foot may be useful for detecting subtle injuries. In the AP view, the medial face of the intermediate cuneiform should be aligned with the medial face of the second metatarsal. In the oblique view, the parameter for normality is the medial face of the cuboid, which should be aligned with the medial face of the fourth metatarsal. In profile view, the presence of anterior or posterior dislocation or subluxation of the tarsometatarsal joints can be observed. If there is any doubt, AP and lateral-view radiographs can also be obtained with loading, which may help to show diastasis between the first and second metatarsals in AP view. In lateral view with loading, a dropped plantar arch or dorsal subluxation can be seen.^{11,12,14-17}

Classification

The classification used for Turco's injury is the one proposed by Nunley and Vertullo, which is specific for midfoot injuries in athletes. This classification divides the injuries into three stages. In sprain stage I of the Lisfranc ligament, there is no diastasis or loss of the plantar arch. In sprain stage II, there is a diastasis of 2 mm to 5 mm due to failure of the Lisfranc ligament, but there is no loss of the plantar arch. In stage III, there is a diastasis between the first and second metatarsals and loss of the plantar arch¹⁶ (Fig. 2).

Materials and methods

Scientific articles that specifically discussed Lisfranc's injury and Turco's injury between 1985 and 2012 were surveyed in the Scielo and Pubmed databases, using the following descriptors: “Lisfranc joint”, “tarsometatarsal joint”, “injuries”, “fracture”, “dislocation”, “treatment” and “outcome”. One hundred and ninety-three articles were found, and articles describing the following were excluded: bone and ligament injuries of the Lisfranc joint; injuries due to high-energy trauma; and case reports. The information was compared with cases surveyed in a typical teaching hospital in a large city between 2006 and 2011 regarding the treatment used, follow-up, postoperative evaluation and return to pre-injury activities. The data were organized according to sports activity, age, side affected, classification, treatment and follow-up (Table 1).

The patients selected for inclusion in this study were professional or amateur athletes with ligament injuries solely in the Lisfranc joint (Turco's injury), which were diagnosed from the history, physical examination, radiographs and magnetic resonance imaging. Patients who were not athletes and who presented associated bone lesions were excluded. A group of 10 patients was thus formed: six men (60%) and four women (40%), with a mean age of 35 years (20 to 61). The left side was affected in eight cases (80%) and the right side in two cases (20%). The assessments using the classification of Nunley and Vertullo¹⁶ were: four cases of type I (40%), four of type II (40%) and two of type III (20%). The mean follow-up was 44.9 months (17 to 76).

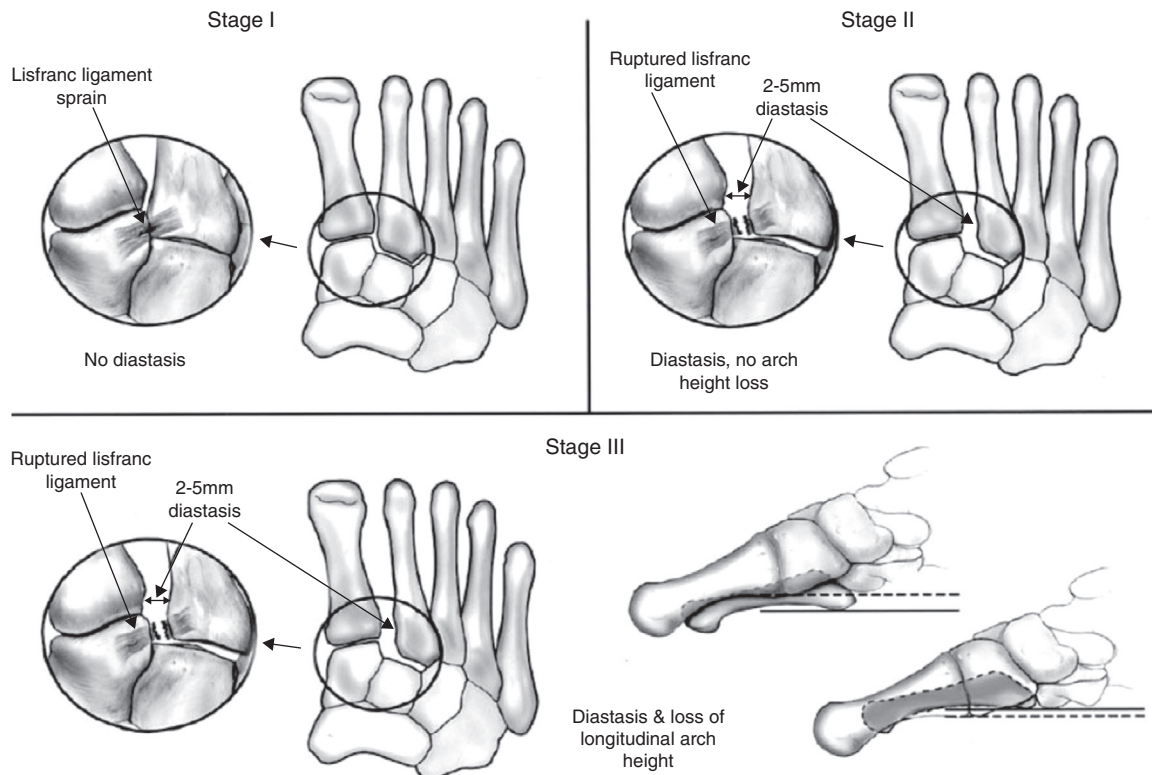


Fig. 2 – Nunley and Vertullo classification.¹⁶

Table 1 – Distribution of 10 patients with Turco's injury, organized according to gender, sports activity, side affected, classification¹⁶ and treatment.

Case	Gender	Age	Date	Sports activity	Side affected	Classification	Treatment
1	Male	20	2007	Baseball	Right	II	Surgical
2	Male	31	2010	Soccer	Left	II	Surgical
3	Male	27	2007	Baseball	Left	III	Surgical
4	Male	24	2011	Recreational soccer	Left	I	Conservative
5	Male	44	2011	Soccer	Left	I	Conservative
6	Male	28	2006	Soccer	Left	III	Surgical
7	Female	61	2009	Walking	Left	I	Conservative
8	Female	31	2009	Walking	Left	II	Conservative
9	Female	61	2007	Golf	Left	II	Surgical
10	Female	23	2008	Artistic gymnastics	Right	I	Conservative

The patients were treated conservatively or surgically, according to the classification of the injury.

All the patients underwent our group's standard rehabilitation protocol, which consisted of four to six weeks of immobilization using a brace, without loading, with analgesic physiotherapy and training of sports movements.

To analyze the results, we used subjective assessment that took into account pain and sports practice performance, which was considered to be poor, satisfactory, good or excellent. The results were considered to be poor if the patient presented pain and did not return to the sport; satisfactory if the patient continued to present pain but returned to sports practice below the pre-injury performance level; good if the patient presented pain but returned to sports practice at a level similar to before the injury; and excellent if the patient did not present pain and returned to the sport at the same level as before the injury.

At the follow-up assessments, radiographs were produced in anteroposterior, lateral and oblique views, with loading, in order to evaluate the evolution.

Result

After careful individualized analysis on each medical file (each patient), the cases were stratified based on the type of treatment, postoperative complications, results, length of follow-up and radiographic signs of arthrosis.

The patients with type I injuries (4, 5, 7 and 10) were treated conservatively in accordance with our standard protocol: patients 5 and 7 evolved with good results and patients 4 and 10 with excellent results.

The patients with type II injuries (1, 2 and 9) underwent surgical treatment: patients 1 and 9 were treated with

Table 2 – Distribution of 10 patients with Turco's injury, according to the type of treatment, rehabilitation, complications presented and return to sports activity.

Case	Type of treatment	Postoperative complications	Result	Follow-up (months)	Arthrosis
1	ORIF with 2 parallel SFS	Superficial skin infection and dehiscence of suture	Good	61 months	No
2	ORIF with 1 oblique SFS	Superficial skin infection and non-anatomical reduction	Poor	34 months	Yes
3	ORIF with 2 divergent SFS and 1 Kirschner wire	Absent	Good	59 months	No
4	Conservative	Absent	Excellent	18 months	No
5	Conservative	Absent	Good	17 months	No
6	ORIF with 2 parallel SFS	Absent	Satisfactory	76 months	Yes
7	Conservative	Absent	Good	36 months	Yes
8	Conservative	Absent	Poor	37 months	No
9	ORIF with 2 parallel SFS	Absent	Good	60 months	Yes
10	Conservative	Absent	Excellent	51 months	No

ORIF, open reduction and internal fixation; SFS, small-fragment screws (3.5 mm).

open reduction and internal fixation (ORIF), using two parallel small-fragment screws (3.5 mm), which in one case went from the medial cuneiform to the base of the second metatarsal and in the other case from the medial cuneiform to the intermediate cuneiform. During the follow-up, both of them presented good results, although patient 1 evolved with dehiscence of the suture and superficial skin infection, without arthrosis, while patient 9 had no complications of the operative wound but showed radiographic signs of arthrosis. Patient 2 was treated with ORIF, using an oblique small-fragment screw going from the medial cuneiform to the base of the second metatarsal. This patient evolved with superficial skin infection during the postoperative period and presented a poor result during the follow-up, which we attributed to the non-anatomical reduction obtained in the surgery. This patient evolved with arthrosis. Patient 8, who also had a type II injury, was treated in a closed manner, because of late diagnosis and radiographic evidence of midfoot ankylosis, and presented a poor result.

The patients with type III injuries (3 and 6) underwent surgical treatment. Patient 3 underwent ORIF using two divergent small-fragment spongy screws with partial threading: one from the medial cuneiform to the base of the second metatarsal and the other from the medial cuneiform to the intermediate cuneiform, in association with a Kirschner wire from the second metatarsal to the intermediate cuneiform. During the evolution, this patient presented a good result, without arthrosis. This patient underwent removal of the Kirschner wire after six weeks. Patient 6 was treated with ORIF using parallel screws, with satisfactory evolution and arthrosis (Table 2).

Discussion

According to the literature, more than 20% of dislocated Lisfranc fractures are not diagnosed in the initial evaluation,^{3,4} which makes suspicion and early diagnosis prerequisites for correct management of this injury. To avoid sequelae over the long term, and functional impotence of this joint, the consensus is that anatomical reduction and joint stabilization should

be performed, so that the follow-up will be satisfactory and the recovery adequate.²⁰⁻²⁴ Lisfranc injuries generally result from high-energy trauma.³ Car accidents are the main cause of these injuries. In our sample, the commonest trauma mechanism was low-energy. The principal during sports practice is plantar flexion over the metatarsals, in association with rotational stress, in accordance with what was described in Turco's original article.¹⁵

The diagnosis is obtained through detailed physical examination, which shows up patients for whom it is difficult or even impossible to bear weight on the affected limb, with pain on palpation in the region of the joint between the first and second metatarsals, and possibly also edema and local sweating. It is very important to perform radiographs with loading on the affected foot, in the frontal, lateral and oblique positions. In cases of doubt, magnetic resonance imaging is indicated for the diagnosis.

The classification described by Nunley and Vertullo¹⁶ was used to interpret and classify the injuries, and this also guided the treatment. There is no consensus in the literature regarding the treatment: open or closed reduction using wires or screws; the positioning of the screws; and whether arthrodesis is indicated. In our sample, none of the patients underwent arthrodesis. Arthrodesis is a predictable consequence of injuries that are not adequately reduced, with or without associated failure of the synthesis, or undiagnosed injuries that evolve with symptomatic arthrosis. However, there was one case (patient 8) for whom the diagnosis was not made at the initial attendance, which was at another service. This patient was admitted to our service with two months of evolution of the injury, and conservative treatment was chosen. The patient evolved with arthrosis and ankylosis, but without symptoms that would justify arthrodesis.

As published in recent studies, anatomical reduction and internal fixation are the essential factors for a good therapeutic results in cases of injuries classified as types II and III by Nunley and Vertullo. This is concordant with our results, as shown in patient 2, in whom anatomical reduction was not achieved, with consequent evolution to a poor result.^{7,25-31} Conservative treatment was only indicated for grade I injuries, given that the initial reduction was lost with improvement

of the soft tissues, and also because of the tendency toward initial displacement.²²

Grade II and III injuries can be dealt with using several techniques and approaches, which vary according to the surgeon's experience and preference. These may include closed reduction and percutaneous fixation using wires or screws,³² open reduction and internal fixation using these same materials^{17,20,24,33} and even primary arthrodesis.³⁰

In 2003, Perugia et al.³⁴ treated this type of injury by means of closed reduction and internal fixation using percutaneous 4 mm spongy screws, in 42 patients: 12 with purely ligament injuries and 30 with bone and ligament injuries, with follow-up of close to 58 months. The results were evaluated using the AOFAS midfoot functional score with a mean of 81 points. In their study, the treatments and results obtained were not differentiated between the patients with solely ligament injuries (Turco's injury) and those with bone-ligament injuries (Lisfranc fracture-dislocation). Furthermore, the authors did not give any information regarding evolution of their cases to arthrosis, the return to work or residual pain.

Perez et al.,²⁴ Rammelt et al.²⁵ and Tan et al.²⁶ used open reduction and internal fixation with Kirschner wires (2.5 to 3.5 mm), through one or two access routes. In their study, among all the complications possible (infection, loss of reduction or skin necrosis), Perez et al.²⁴ presented one case of infection and three with skin necrosis, with a follow-up of 76 months. Rammelt et al.²⁵ showed one case with skin necrosis and one with infection. Over a 36-month follow-up, Tan et al.²⁶ found 10 cases of arthrosis of the tarsometatarsal joint, but all these patients returned to work. Eleven out of their 12 patients presented complete or partial pain relief. None of these authors reported any loss of reduction over the course of their patients' follow-ups, and the synthesis materials were removed eight weeks after the operation. We had one case in which mixed synthesis was used (screw and wire), in which the wire was removed six weeks after the operation. There were no complications and we obtained a good result.

The great majority of the authors^{7,25,27-30,33,34} used open reduction and internal fixation using small-fragment screws. Only Mulier et al.³¹ performed treatments with large-fragment screws (4.5 mm). In their study, conducted on 16 patients with 30 months of follow-up, the synthesis material was removed after 12 weeks, after evidence of bone consolidation and/or ligament healing was seen. The results that they presented included: two patients with sympathetic-reflex dystrophy, 15 with evolution to early arthrosis of this joint and two cases that, because of the severity of the injury, underwent primary arthrodesis. In agreement with the literature, we used ORIF with small-fragment screws.

Among the studies in which the patients with bone-ligament injuries to the Lisfranc joint underwent open reduction and internal fixation using two screws, Arntz et al.⁷ had the following results among 34 patients: 20 evolved with arthrosis, without the need for arthrodesis, 21 returned to work and 29 had complete or partial pain relief. Kuo et al.²⁸ found that 12 of their 48 patients had problems with the fixation, consisting of loosening of the synthesis material and loss of the reduction. These patients evolved with arthrosis, but only six of them required arthrodesis.

Ly and Coetzee²⁹ performed open reduction and internal fixation with two screws on their patients with purely ligament injuries (20 cases). They found synthesis failure in 16 cases and evolution to arthrosis in 15 cases. Of these, five patients underwent reoperation with arthrodesis. Among the 20 patients treated, only six returned to work. Among our 10 cases of purely ligament injury, five were treated surgically and four of them underwent ORIF with two screws. Of these, one evolved with infection and dehiscence of the suture (patient 1), but presented a good result without arthrosis. Two presented good results in which one evolved with asymptomatic arthrosis (patient 9) and the other without arthrosis (patient 3). The last of these cases (patient 6) presented a satisfactory result with asymptomatic arthrosis.

We did not use the AOFAS score in our evaluation because this is not a satisfactory evaluation method among athletes. For this reason, we suggest that there should be an evaluation described in the materials and methods that stratifies the results into poor, satisfactory, good and excellent, with a clinical correlation.

Conclusion

Correct diagnosis directly influences the treatment and the final result obtained. Lack of knowledge of the injury is the main factor responsible for underdiagnosing Turco's injury and its complications. There is a need for randomized prospective studies that compare the types of synthesis material and the evolution of the cases treated with these materials, in order to define the best treatment.

Conflicts of interest

The authors declare no conflicts of interest.

REFERENCES

1. Englanoff G, Anglin D, Hutson HR. Lisfranc fracture-dislocation: a frequently missed diagnosis in the emergency department. *Ann Emerg Med.* 1995;26(2):229-33.
2. Cassebaum WH. Lisfranc fracture-dislocations. *Clin Orthop Relat Res.* 1963;30:116-29.
3. Pereira CJ, Espinosa EG, Miranda I, Pereira MB, Canto RS. Avaliação do tratamento cirúrgico da fratura luxação de Lisfranc. *Acta Ortop Bras.* 2008;16(2):93-7.
4. Myerson MS, Fisher RT, Burgess AR, Kenzora JE. Fracture dislocations of the tarsometatarsal joints: end results correlated with pathology and treatment. *Foot Ankle.* 1986;6(5):225-42.
5. De Palma L, Santucci A, Sabetta SP, Rapali S. Anatomy of the Lisfranc joint complex. *Foot Ankle Int.* 1997;18(6):356-64.
6. Burroughs KE, Reimer CD, Fields KB. Lisfranc injury of the foot: a commonly missed diagnosis. *Am Fam Physician.* 1998;58(1):118-24.
7. Arntz CT, Veith RG, Hansen Jr ST. Fractures and fracture-dislocations of the tarsometatarsal joint. *J Bone Joint Surg Am.* 1988;70(2):173-81.
8. Vuori JP, Aro HT. Lisfranc joint injuries: trauma mechanisms and associated injuries. *J Trauma.* 1993;35(1):40-5.
9. Umans HR. Imaging sports medicine injuries of the foot and toes. *Clin Sports Med.* 2006;25(4):763-80.

10. Van Rijn J, Dorleijn DM, Boetes B, Wiersma-Tuinstra S, Moonen S. Missing the Lisfranc fracture: a case report and review of the literature. *J Foot Ankle Surg.* 2012;51(2):270-4.
11. Faciszewski T, Burks RT, Manaster BJ. Subtle injuries of the Lisfranc joint. *J Bone Joint Surg Am.* 1990;72(10):1519-22.
12. Harwood MI, Raikin SM. A Lisfranc fracture-dislocation in a football player. *J Am Board Fam Pract.* 2003;16(1):69-72.
13. Hardcastle PH, Reschauer R, Kutscha-Lissberg E, Schoffmann W. Injuries to the tarsometatarsal joint. Incidence, classification, and treatment. *J Bone Joint Surg Br.* 1982;64(3):349-56.
14. Perron AD, Brady WJ, Keats TE. Orthopedic pitfalls in the ED: Lisfranc fracture-dislocation. *Am J Emerg Med.* 2001;19(1):71-5.
15. Turco VJ. Diastasis of first and second tarsometatarsal rays: a cause of pain in the foot. *Bull N Y Acad Med.* 1973;49(3):222-5.
16. Nunley JA, Vertullo CJ. Classification, investigation, and management of midfoot sprains: Lisfranc injuries in the athlete. *Am J Sports Med.* 2002;30(6):871-8.
17. Thompson MC, Mormino MA. Injury to the tarsometatarsal joint complex. *J Am Acad Orthop Surg.* 2003;11(4):260-7.
18. Desmond EA, Chou LB. Current concepts review: Lisfranc injuries. *Foot Ankle Int.* 2006;27(8):653-60.
19. Shapiro MS, Wascher DC, Finerman GA. Rupture of Lisfranc's ligament in athletes. *Am J Sports Med.* 1994;22:687-91.
20. Hunt SA, Ropiak C, Tejwani NC. Lisfranc joint injuries: diagnosis and treatment. *Am J Orthop (Belle Mead NJ).* 2006;35(8):376-85.
21. Loveday D, Robinson A. Lisfranc injuries. *Br J Hosp Med (Lond).* 2008;69(7):399-402.
22. Myerson MS. The diagnosis and treatment of injury to the tarsometatarsal joint complex. *J Bone Joint Surg Br.* 1999;81(5):756-63.
23. Myerson MS, Cerrato R. Current management of tarsometatarsal injuries in the athlete. *Instr Course Lect.* 2009;58:583-94.
24. Pérez Blanco R, Rodríguez Merchán C, Canosa Sevillano R, Munuera Martínez L. Tarsometatarsal fractures and dislocations. *J Orthop Trauma.* 1988;2(3):188-94.
25. Rammelt S, Schneiders W, Schikore H, Holch M, Heineck J, Zwipp H. Primary open reduction and fixation compared with delayed corrective arthrodesis in the treatment of tarsometatarsal (Lisfranc) fracture dislocation. *J Bone Joint Surg Br.* 2008;90(11):1499-506.
26. Tan YH, Chin TW, Mitra AK, Tan SK. Tarsometatarsal (Lisfranc's) injuries – results of open reduction and internal fixation. *Ann Acad Med Singapore.* 1995;24(6):816-9.
27. Henning JA, Jones CB, Sietsema DL, Bohay DR, Anderson JG. Open reduction internal fixation versus primary arthrodesis for lisfranc injuries: a prospective randomized study. *Foot Ankle Int.* 2009;30(10):913-22.
28. Kuo RS, Tejwani NC, Digiovanni CW, Holt SK, Benirschke SK, Hansen Jr ST, Sangeorzan BJ. Outcome after open reduction and internal fixation of Lisfranc joint injuries. *J Bone Joint Surg Am.* 2000;82(11):1609-18.
29. Ly TV, Coetzee JC. Treatment of primarily ligamentous Lisfranc joint injuries: primary arthrodesis compared with open reduction and internal fixation. A prospective, randomized study. *J Bone Joint Surg Am.* 2006;88(3):514-20.
30. Rajapakse B, Edwards A, Hong T. A single surgeon's experience of treatment of Lisfranc joint injuries. *Injury.* 2006;37(9):914-21.
31. Mulier T, Reynders P, Dereymaeker G, Broos P. Severe Lisfranc' injuries: primary arthrodesis or ORIF? *Foot Ankle Int.* 2002;23(10):902-5.
32. Coetzee JC. Making sense of Lisfranc' injuries. *Foot Ankle Clin.* 2008;13(4):695-704.
33. Clanton TO, McGarvey W. Athletic injuries to the soft tissues of the foot and ankle. In: Coughlin MJ, Mann RA, Saltzman CL, editors. *Surgery of the foot and ankle.* 8th ed. Philadelphia: Mosby; 2006. p. 1520-7.
34. Perugia D, Basile A, Battaglia A, Stopponi M, De Simeonibus AU. Fracture dislocations of Lisfranc' joint treated with closed reduction and percutaneous fixation. *Int Orthop.* 2003;27(1):30-5.