

# Post Septorhinoplasty Custom-Made Unilateral Nasal Stent for Nasal Cleft Deformity

Manu Rathee, Mohaneesh Bhoria, Priyanka Boora

Department of Prosthodontics, Post Graduate Institute of Dental Sciences, Pandit Bhagwat Dayal Sharma University of Health Sciences, Rohtak, Haryana, India

## Abstract

**Context:** Nasal cleft deformity is a complicated problem. Utilization of nasal stent in post septorhinoplasty aims at establishing and maintaining airway patency, tissue position, and reduces tissue contracture after surgery. **Case Report:** A 16-year-old female patient presented with history of surgical reconstruction of congenital cleft lip and cleft palate with secondary septorhinoplasty of nasal cleft deformity. Patient was referred for nasal stent 1 week after septorhinoplasty. This case report provides a novel technique for fabrication of esthetic nasal stent after postseptorhinoplasty for secondary cleft nose deformity correction. **Conclusion:** This case report presents a simple, convenient technique for nasal stent fabrication for prevention of restenosis for cleft nose deformity post secondary septorhinoplasty. Provision of nasal stent allows breathing, maintains esthetics, comfort, nasal patency, and contour with minimal discomfort.

**Keywords:** Nasal deformity, Nasal stent, Rhinoplasty

**Address for correspondence:** Dr. Manu Rathee, Senior Professor and Head, Department of Prosthodontics, Post Graduate Institute of Dental Sciences, Pandit Bhagwat Dayal Sharma University of Health Sciences, Rohtak, Haryana, India. E-mail: ratheemanu@gmail.com

## Introduction

Nose is the central and prominent structure of the face and the nasal deformity is recognized as cosmetic or functional. Deformities of nose can occur as a result of congenital defect, traumatic injuries, defect associated with cleft lip and cleft palate, surgical excision, or contracture after tumor resection.<sup>[1,2]</sup>

Intranasal prosthesis are used during nasal rehabilitation, aimed at establishing and maintaining airway, maintaining tissue anatomic position, reducing tissue contracture after surgery, and support the mobile tissue. The nasal stent is a removable intranasal prosthesis to support the form of the nose.<sup>[3]</sup> Intranasal splint and stent assist to improve both form and function during surgical and prosthetic rehabilitation.<sup>[4]</sup> This article

provides clinical and lab procedure details for fabrication of simple and esthetic nasal stent postseptorhinoplasty for secondary cleft nose deformity correction.

## Case Presentation

A 16-year-old female patient was referred from the Department of Plastic and Burn Surgery for the fabrication of nasal stent. Patient had a history of congenital cleft lip and cleft palate since birth and had undergone surgical reconstruction for the same at 1.5 years of age. No rhinoplasty was done at that time and the surgical reconstruction of cleft nasal deformity was deferred till the teenage. The patient underwent cleft septorhinoplasty with Potter's V-Y plasty and was referred for nasal stent after 1 week postoperatively [Figure 1].

For intranasal impression, the patient was advised to sit upright in the dental chair. Petroleum jelly was applied to the internal surface of anterior nares to facilitate the comfortable removal of the impression. The nostrils were packed with petroleum jelly coated gauze attached to thread to prevent the impression material from being displaced posteriorly. To confine the impression material in the nasal vestibule, a 19 gauge stainless steel wire was

### Access this article online

Quick Response Code:



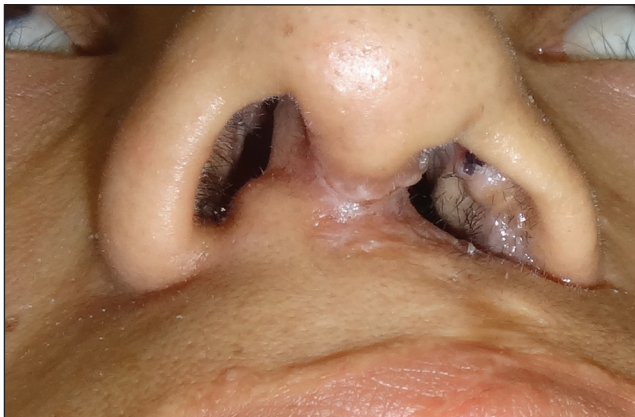Website:  
www.najms.org

DOI:  
10.4103/1947-2714.152083

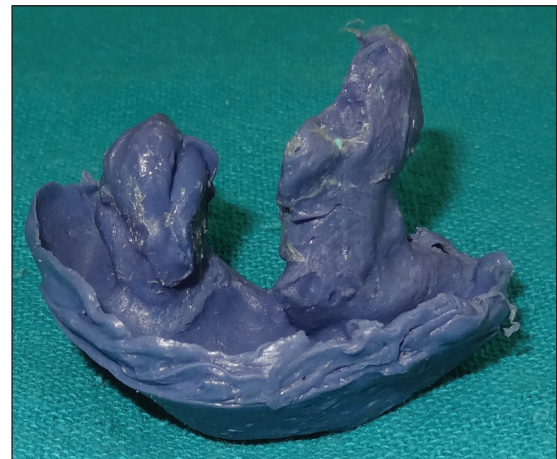
adapted as U-shaped frame across the columella to hold the impression material. Tray adhesive was applied over the wire and elastomeric impression material (Impregum Soft, 3M ESPE AG, Dental Product, Germany) was loaded around the loop. Unset impression material was molded to the desired shape. Additional material was added around the alae of nose for simultaneous nasal impression. The intra- and extranasal combined impression was retrieved [Figure 2]. Impression was inspected for completeness, disinfected, and poured with dental stone.

Master cast was obtained using three-pour technique. The increments were separated from each other using base plate wax. A base plate wax was placed through the center of left nostril impression, separating the impression into one-third and two-third sections. Four linear grooves, two on each side of the wax sheet, were engraved before pouring of the impression and elevations with corresponding depressions were obtained in sections of nasal moulage [Figure 3]. Wax sheet was removed and petroleum jelly was applied over the first segment to act as separating media.


The second and third segments of the split cast were poured with grooves for proper orientation of the sections [Figure 4]. Wax pattern for nasal stent was fabricated. A suction tip segment was used to provide for nasal patency. The rubber suction tip was cut, tried on model, length was adjusted, and positioned centrally in the left nasal cavity on the working cast using modeling wax to make the stent hollow. A stainless wire hook was adapted over the columella and embedded in the stent wax pattern. Split mold was assembled and autopolymerizing acrylic resin was flown in the mold. The prosthesis was retrieved after completion of polymerization. The stent was characterized to match the color with adjoining skin [Figure 5]. All sharp edges and projections were smoothed and the surface was highly polished to prevent injury to the nasal mucosa and the growth of microorganisms. The nasal stent was delivered to the patient and its accuracy was checked by asking the patient to close right nostril and breathe forcibly through the left nostril [Figure 6]. The stent was retained *in situ* and the inhalation and exhalation



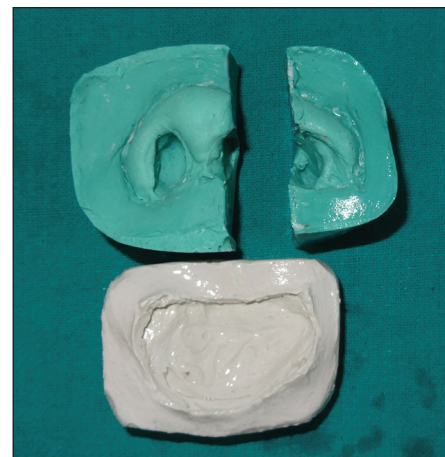**Figure 1:** Post-septorhinoplasty nasal architecture



**Figure 2:** Nasal impression

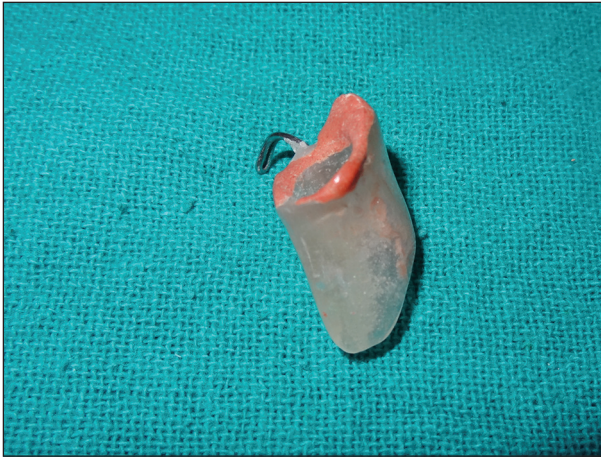

**Figure 3:** Wax sheet with grooves positioned over the nasal impression

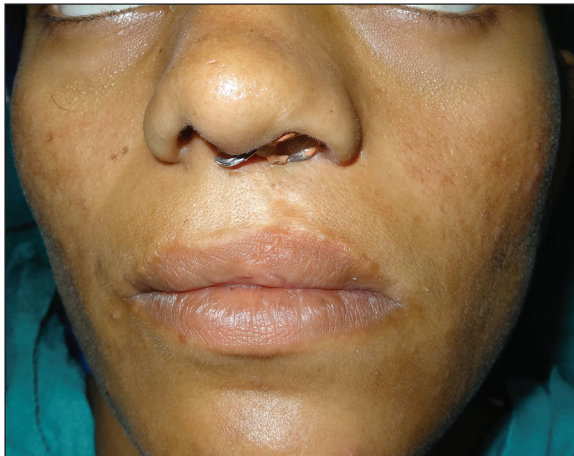

**Figure 4:** Three sections of sectional working cast

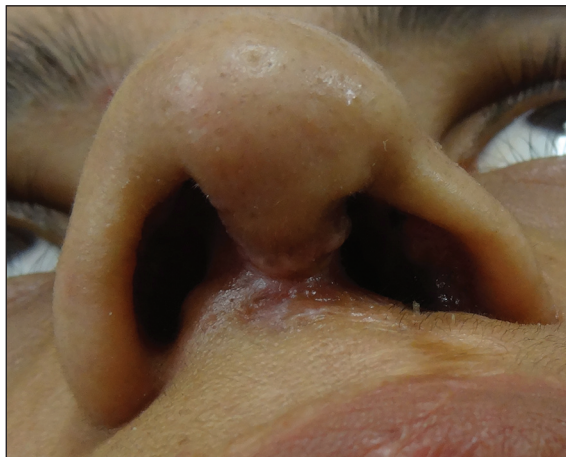process occurred without hindrance. Instructions were given regarding the use and maintenance hygiene of the stent. After insertion, the patient was recalled at 48 h and 1, 3, and 6 months for periodic follow-up [Figure 7].



**Figure 5:** Characterized nasal stent with attached wire hook



**Figure 6:** Nasal stent *in situ*



**Figure 7:** Post septorhinoplasty nasal architecture at 6 months follow-up

## Discussion

The cleft nasal deformity is a common problem presented with deformed soft tissue and skeletal foundation which are further complicated by the long-term effects of anatomic growth and surgical scarring.<sup>[1]</sup> Cleft lip is a malformation and the accompanying nasal deformity is primarily a deformation of normal architectural elements with characteristically short columella. Lip closure alone leaves typical nose deformity with associated esthetic and functional problems. Residual deformity correction of secondary cleft nose deformity depends on severity of deformity. Septorhinoplasty is done using cartilage graft to achieve desired tip projection and shape, to maintain surgically achieved contour, and to avoid postoperative relapse.

Cleft nasal deformity can be addressed during multiple stages of life. The timing of cleft lip nasal surgery can be divided into primary, intermediate, and secondary repair. Primary rhinoplasty, the nasal surgery at the time of primary cleft lip repair, is aimed at achieving restoration of symmetry and repositioning of the nasal structures such that further growth will not exacerbate deformities. However, it is unclear that primary surgical repair prevents the need for future correction. Intermediate rhinoplasty, not always indicated, usually done before school age to achieve symmetry and alleviate future growth deformities. Secondary rhinoplasty is done after facial growth is complete. This is around 14-16 years in female patients and 16-18 years in male patients.<sup>[5-7]</sup> Correction is generally delayed to achieve orthodontic correction of skeletal base, to permit maximal growth of lower lateral cartilage, and to allow bone grafting of hypoplastic maxillary symmetric alar base.

Cartilage graft placement for reinforcement is a major component of the cleft rhinoplasty operation. Use of the cartilage grafts supports the structure of the nose, allowing for improved tip definition and prevents wound contracture and collapse. However, after surgical correction there is a tendency for the lower lateral cartilage to retain its memory and recreate the preoperative nasal deformity. Therefore, nostril retainer or nasal stent is advised postoperatively to maintain the corrected position of the nose.<sup>[8-10]</sup> Multiple techniques have been suggested to prevent subsequent deformation, such as suspending the slumped alar cartilage to a fixed point or using a cartilage stent to stabilize the columella. Wong *et al.*, described implanting a resorbable plate as an internal nasal splint, but had problems with postoperative exposure and extrusion.<sup>[8]</sup> A dynamic nostril splint in surgery of the nasal tip was developed by Cenzi and Guarda in an attempt to keep the nose symmetric as it grows.<sup>[11]</sup>

Secondary surgery for nose to further modify the nasal shape of cleft nose deformity is desired by the patient in

teenage is carried out through septorhinoplasty. A good method for maintaining nasal shape after correction of alar cartilage is to use nasal splint, internal nasal inserts, or nasal packing. Yeow *et al.*, demonstrated in a retrospective analysis of with or without postoperative nasal splint cases that use of splint resulted in better appearance and nasal symmetry.<sup>[12]</sup> The use of nasal stent has been found effective postoperatively after cleft rhinoplasty avoiding relapse of the nasal reconstruction and drop of the nasal ala. Retainers also allow airway patency and avoid relapse, surgical adhesions due to nasal secretions, and scarring. The design of this custom-made nasal stent negates the need to suture the stent to the nasal septum and the hook below the columella avoids the risk of dislocation and aspiration.

### Conclusion

This article describes the clinical and laboratory procedures for the construction of nasal stent for prevention of restenosis for cleft nose deformity in a patient treated with secondary septorhinoplasty. The technique described is simple, noninvasive, cost-effective, and easy to fabricate. The splint fits precisely, allows breathing and it maintains esthetics, comfort, nasal patency, and contour.

### References

1. Parel SM. Intranasal conformers. *J Prosthet Dent* 1980;43:439-44.
2. Beumer J, Curtis TA, Marunick MT. Maxillofacial rehabilitation prosthodontic and surgical considerations. St Louis: Ishiyaku EuroAmerica 1996;3:455-77.
3. The Glossary of Prosthodontic Terms. *J Prosthet Dent* 2005;94:10-92.
4. Seals RR Jr, Bohnenkamp LG, Parel SM. Intranasal prostheses, splints, and stents. *J Prosthet Dent* 1988;60:595-601.
5. Mulliken JB, Burvin R, Farkas LG. Repair of bilateral complete cleft lip: Intraoperative nasolabial anthropometry. *Plast Reconstr Surg* 2001;26:307-14.
6. Young JM. Internal nares prosthesis. *J Prosthet Dent* 1970;24:320-3.
7. Musgrove RH. Surgery of nasal deformities associated with cleft lip. *Plast Reconstr Surg Transplant Bull* 1961;28:261-75.
8. Wong GB, Burvin R, Mulliken JB. Resorbable internal splint: An adjunct to primary correction of unilateral cleft lip-nasal deformity. *Plast Reconstr Surg* 2002;110:385-91.
9. Kim SK, Cha BH, Lee KC, Park JM. Primary correction of unilateral cleft lip nasal deformity in Asian patients: Anthropometric evaluation. *Plast Reconstr Surg* 2004;114: 1373-81.
10. Salyer KE. Early and late treatment of unilateral cleft nasal deformity. *Cleft Palate Craniofac J* 1992;29:556-69.
11. Cenzi R, Guarda L. A dynamic nostril splint in the surgery of the nasal tip: Technical innovation. *J Craniomaxillofac Surg* 1996;24:88-91.
12. Yeow VK, Chen PK, Chen YR, Noordhoff SM. The use of nasal splints in the primary management of unilateral cleft nasal deformity. *Plast Reconstr Surg* 1999;103:1347-54.

**How to cite this article:** Rathee M, Bhorja M, Boora P. Post septorhinoplasty custom-made unilateral nasal stent for nasal cleft deformity. *North Am J Med Sci* 2015;7:73-6.

**Source of Support:** Nil. **Conflict of Interest:** None declared.