

Available online at www.sciencedirect.com

ScienceDirect

journal homepage: <http://Elsevier.com/locate/radcr>

Interventional Radiology

Rigid inflatable gastrostomy tube malposition

Timothy E. Murray MB, MCh, MRCS, FFR^{a,*},
Michael J. Lee MSc, FRCPI, FRCR, FFR, EBIR, FSIR^{a,b}

^a Department of Radiology, Beaumont Hospital, P.O. Box 1297, Beaumont Road, Dublin 9, Ireland^b Royal College of Surgeons in Ireland, St Stephen's Green, Dublin, Ireland

ARTICLE INFO

Article history:

Received 8 June 2017

Received in revised form 26 June 2017

Accepted 3 July 2017

Available online

Keywords:

Gastrostomy

Interventional Radiology

Malposition

ABSTRACT

Rigid inflatable gastrostomy (RIG) tubes are widely used in contemporary clinical practice for a variety of indications. Insertion of RIG tubes is associated with a high technical success rate and low incidence of mortality. In this case report, a procedural pitfall associated with intraperitoneal-extragastric malposition is described. Rigorous assessment of abdominal radiographs, as well as awareness of the expected appearance of the RIG tube and gastrostomy T-fasteners, allows the abdominal radiologist to detect early RIG position in the early postprocedural period. Abdominal radiography is a widely available and inexpensive technique. The high spatial resolution it provides makes it a valuable tool in determining hardware position.

© 2017 the Authors. Published by Elsevier Inc. under copyright license from the University of Washington. This is an open access article under the CC BY-NC-ND license (<http://creativecommons.org/licenses/by-nc-nd/4.0/>).

Clinical case

A rigid inflatable gastrostomy (RIG) tube (14 Fr 2.3 cm MIC-KEY Balloon Button Gastrostomy, Kimberly-Clark Worldwide, Draper, UT) was inserted for nutritional support in a 70-year-old male inpatient undergoing radiotherapy for upper gastrointestinal malignancy. Twenty-four hours after insertion of the RIG tube, a trial of clear fluids through the gastrostomy tube was commenced, which immediately elicited severe abdominal and left shoulder pain. An abdominal radiograph was performed by the clinical team before interventional radiology review (Fig. 1A). Although most RIG

tubes are not intentionally radiopaque, being silicone and without added radiopaque markers, a careful review of the annotated abdominal radiograph demonstrates a discordant position of the visible RIG tube relative to the radiopaque gastrostomy T-fasteners (Fig. 1B). The gastrostomy tube should be positioned centrally within the 4 securing gastrostomy T-fasteners, which are deployed inside the stomach and placed under tension, securing the anterior gastric wall to the anterior abdominal wall to prevent migration or retraction. This relationship is assessable on radiographs.

The final lateral fluoroscopic image from recent gastrostomy insertion was retrospectively reviewed (Fig. 2A). Annotation reveals that although the RIG catheter tip was successfully

Competing Interests: TM and ML have no financial interests to disclose.

Ethical Statement: In accordance with institutional policy, local ethics committee approval was not required for this case study. Informed consent was granted by the patient for submission of the case report and images.

Authorship Statement: The corresponding author (TM) accepts to undertake all the responsibility for authorship during the submission and review stages of the manuscript.

* Corresponding author.

E-mail address: timothymurray@rcsi.ie (T.E. Murray).

<https://doi.org/10.1016/j.radcr.2017.07.009>

1930-0433/© 2017 the Authors. Published by Elsevier Inc. under copyright license from the University of Washington. This is an open access article under the CC BY-NC-ND license (<http://creativecommons.org/licenses/by-nc-nd/4.0/>).

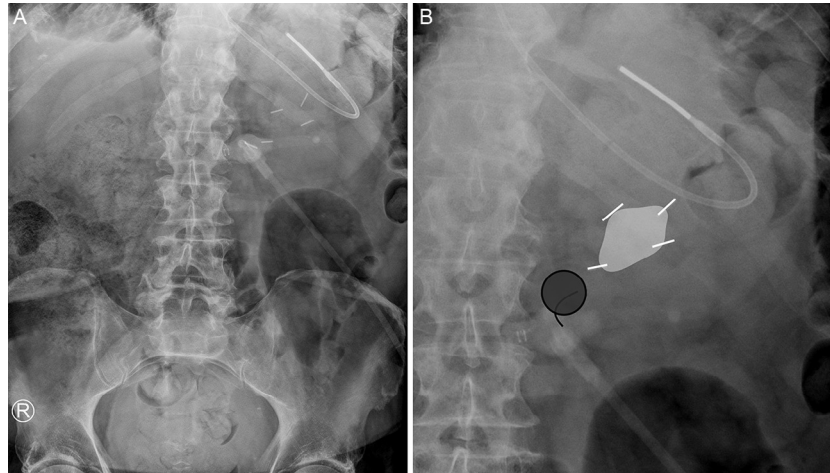


Fig. 1 – Unannotated abdominal radiograph performed for abdominal and shoulder pain after insertion of rigid inflatable gastrostomy (RIG) tube (A). Annotated image demonstrates the gastrostomy T-fastener (white lines), which demarcate the desired position of the initial gastrostomy puncture site (within the white quadrangle). The gastrostomy balloon (gray circle) and gastrostomy tube (black line) are seen inferomedially, indicating the gastrostomy tube has migrated from the initial gastrostomy puncture site (B).

positioned within the gastric lumen, the RIG balloon was inflated outside the stomach wall (Fig. 2B). This position was therefore unsecured and permitted inferomedial migration of the intraperitoneal-extragastric tube. Upon detection of RIG malposition, the intraperitoneal tube was removed, and repeat insertion was promptly performed without incident during the same inpatient admission. There were no additional complications related to the procedure.

Discussion

RIG insertion demonstrates high technical success rates (90%-100%) and a low incidence of procedure-related mortality (1%) [1]. Gastrostomy T-fasteners secure the anterior gastric wall to the anterior peritoneal wall and reduce the risk of intraperi-

toneal tube placement but do not eliminate that risk [2]. Typically, 4 gastrostomy T-fasteners are evenly spaced to form a quadrangle, and the RIG tube is inserted through the center point to ensure maximal fixation. Although the mobile tip may move slightly, the balloon should remain within the geometric center of the gastrostomy T-fasteners.

Cases where the tip of the gastrostomy catheter is within the gastric lumen but the balloon remains intraperitoneal-extragastric can be challenging to recognize during the procedure. The intraluminal tip allows the operator to install iodinated contrast, or insufflate air via the tube into the stomach as expected, thus masking malposition. Balloon inflation with normal saline is difficult to visualize. Dilute iodinated contrast, used to opacify the balloon, is not associated with balloon dysfunction and should be considered in place of water in case of uncertainty [3]. Awareness of inadvertent extragastric balloon inflation is important, and requires close scrutiny of balloon

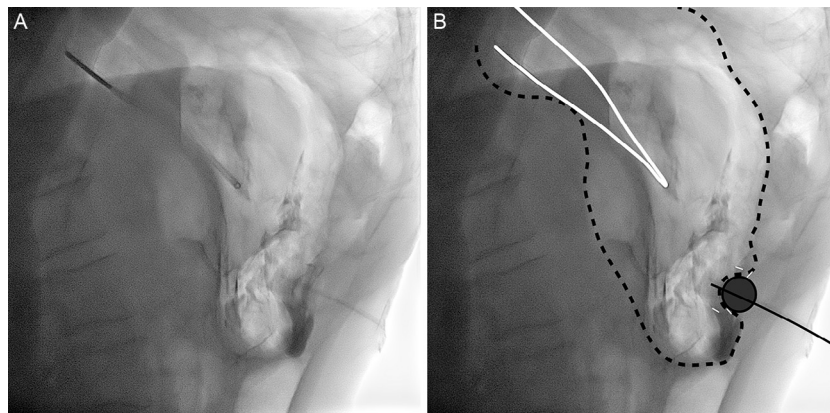


Fig. 2 – Unannotated lateral fluoroscopic image after insertion of rigid inflatable gastrostomy (RIG) tube (A). Annotation and evaluation of each structure demonstrate the nasogastric tube (white line) within a distended stomach (dashed black line). The gastrostomy tube (solid black line) is seen with the catheter tip in the gastric lumen; however, the balloon (gray circle) is inflated in an extramural position. Positions of gastrostomy T-fasteners (white dash) were as expected (B).

position. In this case, a robust protocol of stepwise escalation of RIG usage, commencing with clear fluids, aids in the early clinical detection of malposition and helps prevent the feared complication of chemical or infectious peritonitis.

The risk of malposition and migration of RIG tubes during their lifetime is 7.2%; however unrecognized intraprocedural malposition is rare (the exact incidence is unknown) [4]. Operator satisfaction with the position of RIG tube after insertion is accepted as sufficient proof of satisfactory position, with further imaging not routinely performed. Abdominal radiography, either routinely post-procedure or when malposition is suspected, is not required. Clinical symptoms alone should prompt reassessment in the interventional suite under fluoroscopy and reinsertion, or a limited noncontrast computed tomography [1]. Nonetheless, radiologists' awareness of the expected radiographic appearances of malposition may permit early diagnosis on plain film (be it abdominal, or even chest radiographs where the upper abdomen is included). Because of a high prevalence of comorbidities and cognitive impairment in patients who underwent gastrostomy, this vulnerable cohort may be difficult to clinically assess or may undergo further imaging for unrelated reasons. Early detection before potential intraperitoneal feeding is of clear value. Finally, pain from RIG insertion peaks at 6 hours. Worsening pain

beyond this period, as experienced by our patient, where pain peaked at 24 hours after first use, is abnormal and should prompt further assessment [5].

REFERENCES

- [1] Sutcliffe J, Wigham A, McEniff N, Dvorak P, Crocetti L, Uberoi R. CIRSE standards of practice guidelines on gastrostomy. *Cardiovasc Intervent Radiol* 2016;39:973-87.
- [2] Thornton FJ, Fotheringham T, Haslam PJ, McGrath FP, Keeling F, Lee MJ. Percutaneous radiologic gastrostomy with and without T-fastener gastropexy: a randomized comparison study. *Cardiovasc Intervent Radiol* 2002;25:467-71.
- [3] Lopera JE, Alvarez A, Trimmer C, Josephs S, Anderson M, Dolmatch B. Stability of balloon-retention gastrostomy tubes with different concentrations of contrast material: in vitro study. *Cardiovasc Intervent Radiol* 2008;32:127.
- [4] Power S, Kavanagh LN, Shields MC, Given MF, Keeling AN, McGrath FP, et al. Insertion of balloon retained gastrostomy buttons: a 5-year retrospective review of 260 patients. *Cardiovasc Intervent Radiol* 2013;36:484-91.
- [5] England A, Tam CL, Thacker DE, Walker AL, Parkinson AS, Demello W, et al. Patterns, incidence and predictive factors for pain after interventional radiology. *Clin Radiol* 2005;60:1188-94.