

Noneruption of teeth in amelogenesis imperfecta: A report of two cases and review

Jaygopal G Ray¹, Sayani Dutta¹, Snehanjan Sarangi¹, Priyanka Yadav²

Departments of ¹Oral Pathology and ²Public Health Dentistry, Burdwan Dental College and Hospital, Burdwan, West Bengal, India

Abstract

Amelogenesis imperfecta (AI) comprises a complicated group of conditions, involving a structural defect of the tooth enamel, owing to certain genetic disturbances. It is expressed as an autosomal dominant, autosomal recessive or X-linked recessive trait. The structural pattern and clinical appearances of all the teeth, including those in the deciduous as well as the permanent dentition, are affected. It may be differentiated into three main divisions such as hypoplastic, hypocalcific and hypomaturation patterns. Eruption of tooth refers to a complex coordinated physiological process characterized by the movement of a tooth from its initial developmental position within the jaws to its final functional position in the occlusal plane, dictated crucially by dental follicle, bony remodeling metabolic alteration and molecular determinants. Alteration involving any one of the factors might cause hindrances. Herein, we report two cases with AI associated with noneruption.

Keywords: Amelogenesis imperfecta, noneruption, unerupted and impacted teeth

Address for correspondence: Dr. Snehanjan Sarangi, FD-9, Flat No. 3, Salt Lake, Kolkata - 700 106, West Bengal, India.

E-mail: babi.sarangi@gmail.com

Submitted: 20-Nov-2020, **Revised:** 03-Feb-2021, **Accepted:** 03-Jul-2021, **Published:** 28-Jun-2022

INTRODUCTION

Eruption of tooth is a complicated physiological developmental procedure, connoted by movement of a tooth from its initial site of development within the alveolar process to its functional position in the oral cavity. This orchestrated movement is regulated by dental follicle by means of synchronized resorption and bone deposition following a precise chronology, bilaterally coordinated with facial growth and bone remodeling. The absence of tooth within the oral cavity usually arises as a result of disturbance involving some critical processes of tooth eruption.

Amelogenesis or enamel formation is a two-step process. The first step produces partly mineralized enamel. Once

the full width of the enamel has been laid down, the second step includes significant influx of additional minerals coincident with the removal of organic content and water to obtain a very high (about 96%) mineral constituent.^[1] Hereditary defects of enamel, usually not associated with any other genetic defects or systemic conditions, are known as amelogenesis imperfecta (AI). Hence, AI connotes a group of genetic conditions, involving the structure and phenotype of dental enamel, involving both deciduous and permanent dentition usually in association with other intraoral and/or extraoral tissues.^[2] The clinical appearance and structure of enamel involving the teeth are characterized by discoloration, hypo mineralization and hypoplasia along with fragility and sensitivity.^[3] AI may

This is an open access journal, and articles are distributed under the terms of the Creative Commons Attribution-NonCommercial-ShareAlike 4.0 License, which allows others to remix, tweak, and build upon the work non-commercially, as long as appropriate credit is given and the new creations are licensed under the identical terms.

For reprints contact: WKHLRPMedknow_reprints@wolterskluwer.com

How to cite this article: Ray JG, Dutta S, Sarangi S, Yadav P. Noneruption of teeth in amelogenesis imperfecta: A report of two cases and review. *J Oral Maxillofac Pathol* 2022;26:254-8.

Access this article online

Quick Response Code:



Website:

www.jomfp.in

DOI:

10.4103/jomfp.JOMFP_471_20

exhibit autosomal dominant, autosomal recessive, X-linked dominant or X-linked recessive subtypes; however, the autosomal dominant variant is the most common.^[4]

In this article, we present two cases of multiple unerupted teeth in AI patients. Interestingly, in both cases, siblings are involved which makes our case unique.

CASE REPORTS

Case 1

A female patient, aged about 14 years, hailing from a semi-urban area of Burdwan district of West Bengal, reported to the Department of Oral Pathology and Microbiology, Burdwan Dental College and Hospital, with the chief complaint of multiple missing teeth associated with esthetic concerns. Her general external physical examination revealed that the patient had a normal stature and little stunted growth [Figure 1]. The patient's hair, skin and nail mental status were normal. The extraoral examination revealed nothing significant. Intraoral examination yielded the presence of multiple retained deciduous teeth, noneruption of permanent successors, along with retained root and malocclusion evidenced by anterior deep bite coupled with areas of crossbite [Figure 2]. Specifically 13, 14, 15, 18, 23, 24, 25 and 28 in the maxillary arch and 31, 32, 33, 34, 35, 42, 44 and 45 in the mandibular arch were missing. Areas of attrition, especially in the anterior tooth region of both the jaws along with chalky white hypocalcific (HC) isolated areas in relation to labial aspect of 11, 12, 21 and 22, were evident. Open contact points, especially involving maxillary anterior and mandibular posterior teeth, were noted [Figure 3]. The enamel of the teeth in general had a thin, hard and glossy consistency on probing with a dental explorer, excepting 37 and 47 which possessed a rough, scratchy consistency, and the occlusal areas of 83 and 85 and the mesioproximal aspect of 26 exhibited opaque yellowish white zones of discoloration, where enamel appeared to be worn out. Orthopantomogram (OPG) revealed the presence of impacted and unerupted teeth in both maxillary and mandibular dentition. Taurodontism in 37 and 47, accompanied with failure of completion of root formation, was noted in the impacted teeth [Figure 4].

The younger sister of the patient presented with similar manifestations as found on OPG – multiple retained teeth associated with multiple unerupted permanent teeth [Figure 5].

However, hormonal assays for the growth hormones including the thyroid profiles were not significant.

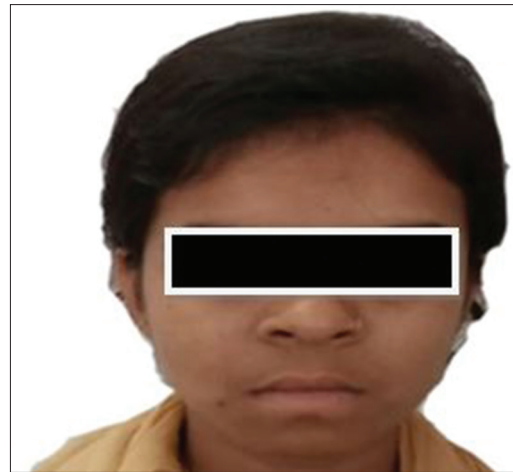

Figure 1: Extraoral view of the patient

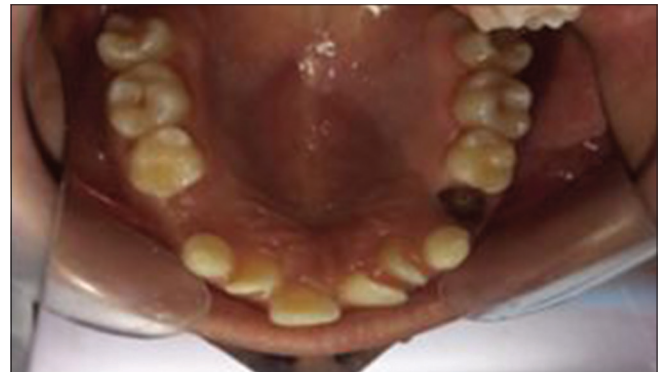

Figure 2: Intraoral view showing the presence of multiple retained deciduous teeth, noneruption of permanent successors, along with retained root

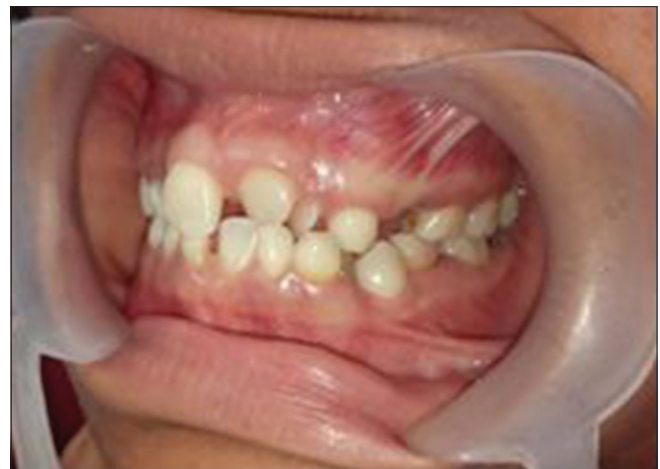

Figure 3: Lower arch view – Malocclusion evidenced by anterior deep bite coupled with areas of crossbite

Case 2

A 17-year-old female patient, hailing from the rural areas of Birbhum district of West Bengal, visited the Department of Oral Pathology and Microbiology, Burdwan Dental College

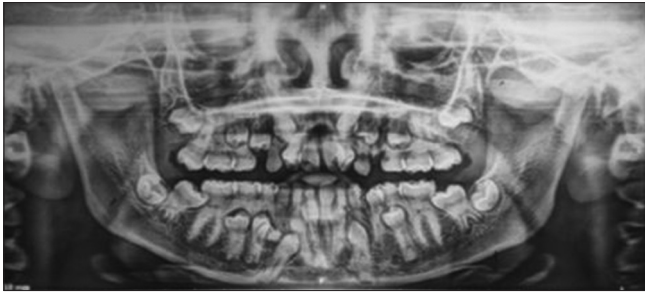

Figure 4: Orthopantomogram of the patient revealed the presence of multiple impacted and unerupted teeth in both maxillary and mandibular dentition along with failure of root completion

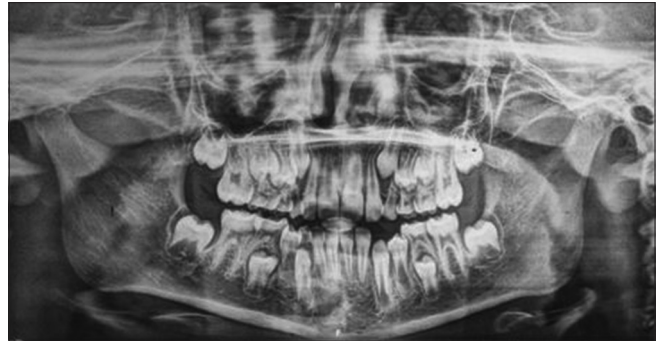

Figure 5: Orthopantomogram of the younger sister of the patient showing unerupted and impacted teeth and teeth with incomplete root formation



Figure 6: Extraoral view

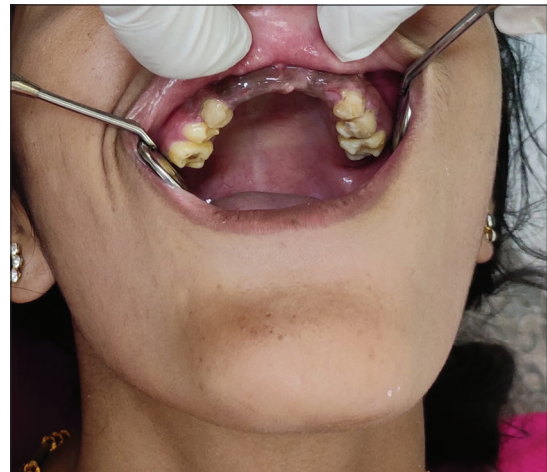

Figure 7: Intraoral view yielded the presence of multiple retained deciduous teeth, multiple missing permanent teeth and malocclusion. The canines and molar teeth pertaining to the upper arches exhibited marked mottling and a rough scratchy surface

and Hospital, with the chief complaint of multiple missing teeth. On extraoral examination, nothing significant was found [Figure 6]. Intraoral examination yielded the presence of multiple retained deciduous teeth, multiple missing permanent teeth and malocclusion. The canines and molar teeth pertaining to the upper arches exhibited marked mottling and a rough scratchy surface [Figure 7], 52 and 65 were retained in the upper arch and 73, 74, 84 and 85 were retained in the mandibular arch. 11, 12, 14, 15, 17, 18 and 21, 22, 24, 25, 27, 28 in the maxillary arch were absent. 32, 33, 42, 43, 34, 44, 37 and 47 in the mandibular arch were absent. Spacing in lower arch and open contact points involving maxillary posterior teeth were noted, especially between 26 and 65 [Figure 8]. OPG revealed the presence of multiple unerupted/retained deciduous and permanent impacted teeth along with teeth where root completions were not evident [Figure 9].

Medical history of the patient revealed the symptoms of hypothyroidism, with the thyroid-stimulating hormone level being 19.36 IU/ml.

The elder sister of the patient also presented with similar features comprising AI along with unerupted teeth. She also had hypothyroidism.

DISCUSSION

AI is a group of heterogeneous disorders that affect the development of enamel. As a result, the amount, composition and/or structure of enamel can be abnormal. These disorders are caused by mutations in a variety of genes that are important for enamel formation. Mutations in several genes, including ENAM, AMEL, DLX3 and P63, are known to cause isolated or syndromic AI.^[5,6]

AI is classified into three basic phenotypes in accordance with the three stages of enamel development:

- Hypoplastic (HP) (localized pitted, generalized pitted, generalized thin) – Characterized by a defective or inadequate deposition of enamel matrix caused by a disturbance in the functioning of the ameloblasts
- Hypocalcification – Characterized by defective mineralization of the enamel matrix during the calcification stage

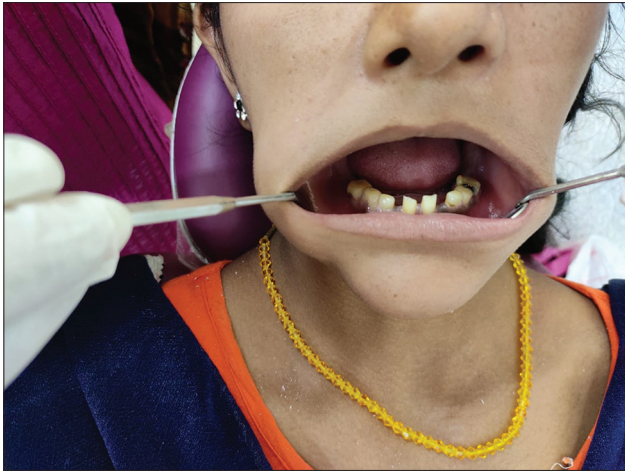

Figure 8: Intraoral view of lower arch showing spacing and open contact points

- Hypomaturation (diffuse pigmented, snowcapped) – Emphasized by lack of enlargement and maturation of the enamel crystallites during maturative stage of amelogenesis.^[7]

Each main clinical group of AI may be further subdivided into subgroups based on the mode of inheritance, as well as the clinical appearance of defective enamel, although in some cases, overlapping clinical features might be evident. HP type AI represents 60%–73% of all the cases, the hypomaturative type 20%–40% followed by the HC type representing about 7% of all cases.^[8]

Interestingly, AI can also be associated with a spectrum of other features such as progressive root and crown resorption, pulpal calcification, taurodontism, malformation of root, impaction of permanent teeth and congenitally missing teeth.^[9]

Multiple unerupted and impacted teeth, crowding, along with incomplete root formation have been observed in our reported cases. However, the most prominent finding in the said case is multiple unerupted or impacted teeth in siblings. A study conducted by W. Kim Scow revealed that dental eruptive problems are more prevalent in AI including dental impaction and follicular cysts and this may actually lead to noneruption. Although reasons for the eruptive pathosis are unclear, numerous etiologies that have so far been suggested are abnormal molecular control of the eruption process, lack of space and concurrent follicular enlargement.^[9] Noneruption of teeth might be associated with several syndromes such as Rutherford syndrome, GAPO syndrome, osteopetrosis and cleidocranial dysplasia.^[10] In a few instances, failure of eruption was associated with the exposure of dentin caused by abnormal enamel leading to resorption of the tooth followed by ankylosis.^[11,12] Finally, we have come across deep bite, crossbite,

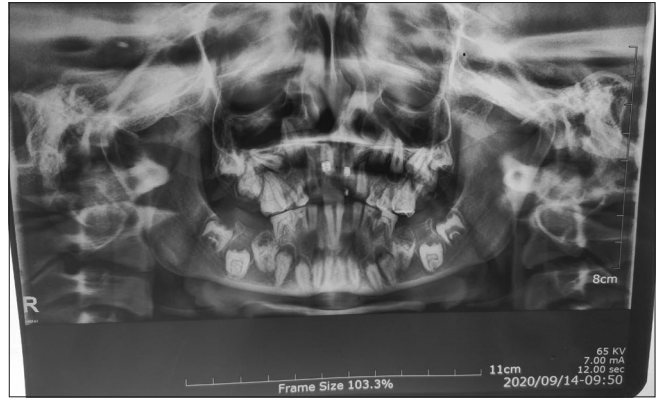


Figure 9: Orthopantomogram of the patient revealed the presence of multiple unerupted/retained deciduous and permanent impacted teeth along with teeth where root completions were not evident

generalized attrition and open contacts as a result of either AI or malocclusion resulting from multiple edentulous spaces due to impacted teeth.

However, noneruption or delayed eruption of teeth is not an exclusive feature of AI but seen in others conditions such as hypophosphatasia, hypothyroidism, hypopituitarism and hypoparathyroidism and drug treatments such as bisphosphonate administration and chemotherapy, premature birth and chronic and prolonged malnutrition during childhood.^[13] Therefore, we assume in our cases both local and systemic factors might have contributed toward noneruption of teeth.

Declaration of patient consent

The authors certify that they have obtained all appropriate patient consent forms. In the form the patient (s) has/have given his/her/their consent for his/her/their images and other clinical information to be reported in the journal. The patients understand that their names and initials will not be published and due efforts will be made to conceal their identity, but anonymity cannot be guaranteed.

Financial support and sponsorship

Nil.

Conflicts of interest

There are no conflicts of interest.

REFERENCES

1. Nancy A. Enamel: Composition, Formation and Structure-Ten Cate's Oral Histology: Development, Structure and Function. 6th ed. St Louis, Missouri: Mosby; 2003. p. 154.
2. Prabhu SR, Wilson DF, Daftary DK. Developmental disorders of the teeth – Oral Diseases in the Tropics. Delhi: Oxford University Press; 1993. p. 548.
3. Gadhia K, McDonald S, Arkutu N, Malik K. Amelogenesis imperfecta: An introduction. Br Dent J 2012;212:377-9.
4. Kida M, Ariga T, Shirakawa T, Oguchi H, Sakiyama Y. Autosomal-dominant

- hypoplastic form of amelogenesis imperfecta caused by an enamelin gene mutation at the exon-intron boundary. *J Dent Res* 2002;81:738-42.
5. Carlson MB. *Human Embryology and Developmental Biology*. 5th ed. Michigan: Elsevier; 2014.
 6. Wright JT, Hart TC, Hart PS, Simmons D, Suggs C, Daley B, *et al.* Human and mouse enamel phenotypes resulting from mutation or altered expression of AMEL, ENAM, MMP20 and KLK4. *Cells Tissues Organs* 2009;189:224-9.
 7. Neville BW, Damm D, Chi AC. *Color Atlas of Oral and Maxillofacial Diseases*. 5th ed. South Carolina: Science Direct; 2019.
 8. Aldred MJ, Savarirayan R, Crawford PJ. Amelogenesis imperfecta: A classification and catalogue for the 21st century. *Oral Dis* 2003;9:19-23.
 9. Reddy SS, Aarthi Nisha V, Harish BN. Hypoplastic amelogenesis imperfecta with multiple impacted teeth-reports of two cases. *J Clin Exp Dent* 2010;2:e207-11.
 10. Hanisch M, Hanisch L, Kleinheinz J, Jung S. Primary failure of eruption (PFE): A systematic review. *Head Face Med* 2018;14:5.
 11. Seow WK. Dental development in amelogenesis imperfecta: A controlled study. *Pediatr Dent* 1995;17:26-30.
 12. Canger EM, Celenk P, Yenisey M, Odyakmaz SZ. Amelogenesis imperfecta, hypoplastic type associated with some dental abnormalities: A case report. *Braz Dent J* 2010;21:170-4.
 13. Dixit UB, Jain MC. Primary failure of eruption, a review. *Indian J Oral Health Res* 2018;4:1.