

# Compound betamethasone in the treatment of pain after supraspinatus tendon repair

Journal of International Medical Research  
2022, Vol. 50(9) 1–9  
© The Author(s) 2022  
Article reuse guidelines:  
[sagepub.com/journals-permissions](https://sagepub.com/journals-permissions)  
DOI: [10.1177/03000605221121962](https://doi.org/10.1177/03000605221121962)  
[journals.sagepub.com/home/imr](https://journals.sagepub.com/home/imr)



Hu Da, Jian-Kuan Song, Li Liu and  
Liang Zhou 

## Abstract

**Objective:** To investigate the effect of compound betamethasone on pain points of the supraspinatus tendon by local blocking therapy after repair surgery.

**Methods:** This non-randomised controlled trial included patients who underwent arthroscopic repair of supraspinatus tendon tears and who had long-term pain. At 3 months following surgery, patients were assigned to an experimental group, whose pain points were treated with compound betamethasone, or a control group who did not receive compound betamethasone. Visual analogue scale (VAS) score, Pittsburgh Sleep Quality Index (PSQI) and Constant shoulder score for pain were determined at 3, 4, 5 and 6 months following surgery and analysed retrospectively.

**Results:** Of 38 included patients, there were no statistically significant between-group differences in VAS score, PSQI or Constant shoulder scores at 3 months following surgery. At 4, 5 and 6 months after surgery, the VAS score and PSQI were significantly lower, and the Constant shoulder score was significantly higher, in the experimental group versus controls.

**Conclusions:** Using compound betamethasone to locally block pain points after supraspinatus tendon repair surgery may significantly alleviate pain, improve sleep quality, facilitate functional shoulder exercise and achieve good shoulder function.

## Keywords

Compound betamethasone, supraspinatus tendon, pain, inflammation, local blocking therapy, shoulder function

Date received: 1 June 2022; accepted: 22 July 2022

## Introduction

Injury to the rotator cuff, an important structure in the shoulder joint, may destroy the stability of the humeral glenoid joint.<sup>1</sup> The most common injury is a tear of the

Department of Orthopaedics, Lianshui County People's Hospital, Lianshui, Jiangsu, China

### Corresponding author:

Liang Zhou, Department of Orthopaedics, Lianshui County People's Hospital, 6 Hongri Road, Lianshui, Jiangsu 223499, China.

Email: [zhouliangmd@sina.com](mailto:zhouliangmd@sina.com)



supraspinatus tendon near the footprint on the humeral head.<sup>2</sup> Shoulder arthroscopy is the main treatment favoured by clinicians for rotator cuff repair, due to the procedure being minimally invasive and associated with few complications.<sup>3</sup> However, many patients experience long-term neck and shoulder pain after surgery, and localized pain points at the site of injury of the supraspinatus tendon can be palpated. Described as a persistent dull pain, its specific clinical manifestation includes relief in the daytime and aggravation at night, which seriously affects sleep.<sup>4</sup> In addition, the pain limits patients' performance of functional exercise, resulting in shoulder stiffness.<sup>5</sup> In the clinic, postoperative pain is reduced by the administration of oral nonsteroidal anti-inflammatory drugs (NSAIDs) and shoulder physiotherapy. However, for some patients, the effect is very poor.<sup>6,7</sup> Thus, complete alleviation of pain in these patients, improvement of quality of life, protection of the shoulder joint function and improvement of patients' satisfaction with surgery, remain difficult problems that orthopaedic doctors need to address.<sup>8</sup>

The purpose of the present study was to investigate the effect of local blocking therapy, with compound betamethasone injections, on pain after supraspinatus tendon repair, by analysis of data from the previous 6 years, with the aim of providing a solid theoretical basis for future clinical work.

## Patients and methods

### Study population

This non-randomised controlled trial was conducted at Lianshui County People's Hospital, Lianshui, Jiangsu, China, between June 2015 and October 2021, and included sequential patients who had undergone supraspinatus tendon repair with arthroscopy for supraspinatus tendon

tears, and who had obvious long-term neck and shoulder pain after the operation. Patients were assigned to the experimental group or the control group according to the order in which they saw a doctor, using a non-random alternating assignment method, and were blinded to the group allocation. All procedures were performed after receiving approval from the Ethics Committee of Lianshui County People's Hospital (permission No. ACEC2014-016), and were conducted according to relevant guidelines and regulations. Written informed consent for study inclusion was obtained from all patients. The authors had access to information that could identify individual participants during data collection. All patient details were de-identified for publication, and the reporting of this study conforms to CONSORT guidelines.<sup>9,10</sup> Fellow researchers may reproduce the methodology from the description given in this methods section.

### Study inclusion and exclusion criteria

The inclusion criteria were as follows: (I) obvious pain still present at 3 months following surgery, with poor effects of oral NSAIDs and analgesic drugs (e.g., ibuprofen or celecoxib), and infrared physiotherapy for the shoulder; (II) palpable localized pain points at the supraspinatus tendon; (III) a visual analogue scale (VAS) score for pain  $\geq 3.0$ ; and (IV) the patient exhibited good postoperative treatment compliance. The exclusion criteria were as follows: (I) poor patient ability to understand instructions and an inability to complete VAS, Pittsburgh Sleep Quality Index (PSQI) and Constant shoulder score evaluation; (II) presence of other diseases or injuries of the shoulder joint; (III) presence of acute or chronic infectious diseases, systemic immune diseases, or obvious abnormalities, including in terms of leukocyte count, erythrocyte sedimentation rate, anti-O test,

C-reactive protein, or rheumatoid factor; or (IV) lack of outpatient follow-up after discharge.

### *Therapeutic method*

Both groups received physical therapy, and oral NSAIDS and analgesics, beyond 3 months following surgery and throughout the study period. The injured upper limb was fixed in an abducted position. At 3 months following surgery, patients allocated to the experimental group received 1 ml of compound betamethasone as a formulation for injection supplied in a sterile 1 ml ampoule (Schering-Plough Labo N.V. Shanghai, China) and 4 ml normal saline by intramuscular injection, to block the pain points in the supraspinatus tendon. In cases of persistent pain, a further betamethasone injection was administered at 4 months. Patients in the control group did not receive any injection, but continued with physical therapy, oral NSAIDS and analgesics.

### *Outcome measures*

All outcome measures were determined by the same joint surgeon (C-MX), who was blinded to the grouping and treatment methods.

#### *Pain score*

Nocturnal pain was evaluated in patients at 3, 4, 5 and 6 months after surgery using the VAS. Total VAS scores range from 0 to 10, where 0 indicates no pain and 10 indicates the most severe pain.

#### *Sleep quality score*

Sleep quality was evaluated with the PSQI in all patients at 3, 4, 5 and 6 months after surgery. Total PSQI scores range from 0 to 21. The higher the score, the worse the sleep

quality,<sup>11</sup> and a total PSQI score >5 indicates poor sleep.<sup>12</sup>

### *Scoring of shoulder function*

Shoulder function was evaluated with the Constant shoulder score in all patients at 3, 4, 5, and 6 months following surgery. The Constant shoulder score includes four parts: a pain score, an activities of daily living score, a shoulder active range of motion score, and a shoulder abductor strength score. The total score ranges from 0 to 100, and the higher the score, the better the shoulder function.<sup>13</sup>

### *Statistical analyses*

All data are presented as mean  $\pm$  SD and were analysed using SPSS software, version 24.0 (IBM, Armonk, NY, USA). Data from the experimental and control groups were analysed statistically. Between-group differences were assessed with Student's *t*-test, and a *P*-value <0.05 was considered statistically significant.

## **Results**

A total of 49 patients were initially enrolled into the study, and 11 patients who met the exclusion criteria were then excluded. The remaining 38 patients were included in this study, including nine male and 29 female patients, aged between 47 and 66 years. The experimental group comprised five male and 14 female patients (mean age,  $54.27 \pm 6.36$  years; age range, 47–66 years) and the control group comprised four male and 15 female patients (mean age,  $56.48 \pm 4.80$  years; age range, 48–65 years). There was no statistically significant difference in sex or age between the two groups ( $P > 0.05$ ), indicating comparability. Overall, VAS scores were >4.3 at 3 months following surgery and prior to betamethasone treatment. Three patients in the experimental group received an additional injection of

betamethasone at 4 months after surgery due to persistent pain.

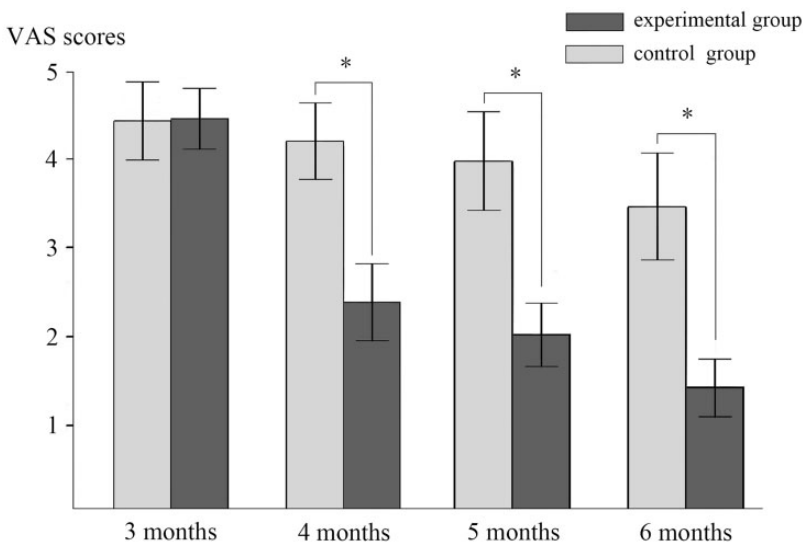
The VAS scores for nocturnal pain, PSQI scores, and Constant scores for shoulder function are shown for the two groups in Figures 1, 2, and 3, respectively. No statistically significant differences were noted between the two groups at 3 months after surgery, before patients in the experimental group received the local blocking treatment with compound betamethasone ( $P > 0.05$ ).

At 3 months following surgery, the experimental group received local blocking treatment. After a few hours of treatment, patients reported that their pain was greatly relieved. At 4, 5 and 6 months following surgery, the VAS and PSQI scores were significantly lower in the experimental group compared with the control group, indicating reduced pain and increased sleep quality versus controls. In addition, the Constant scores for shoulder function were all significantly higher in the experimental group

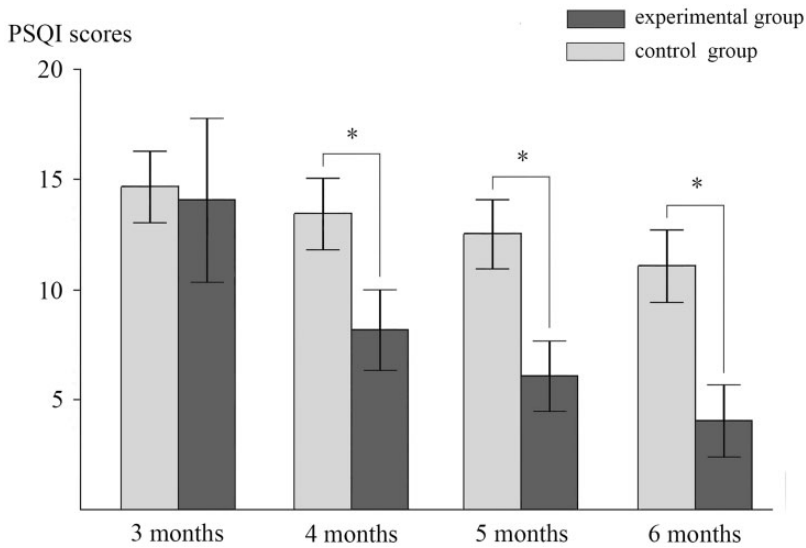
compared with the control group ( $P < 0.05$ ; Figures 1, 2, and 3), indicating improved shoulder function versus controls.

## Discussion

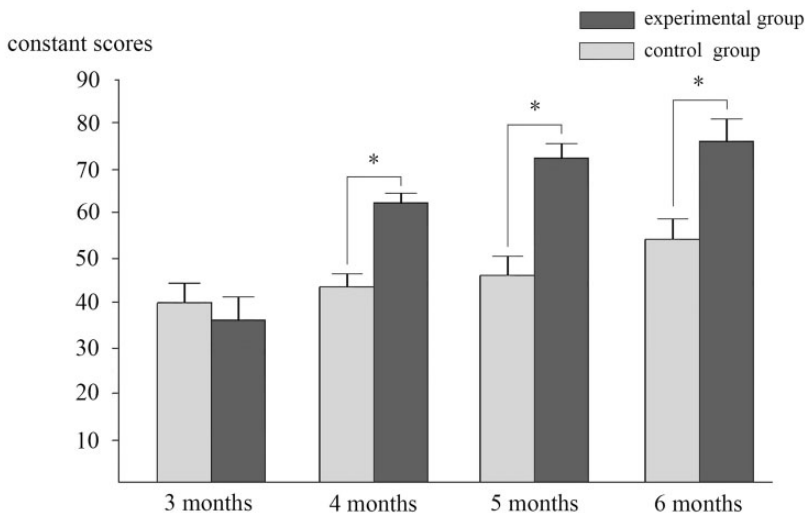
Persistent dull pain, disrupted sleep and shoulder stiffness are common complications after supraspinatus tendon repair. Painful conditions often disrupt sleep and, in advanced stages, may even exert a negative effect on daily activities.<sup>14</sup> Many treatments are ineffective; thus, the complications associated with supraspinatus tendon repair remain a troubling problem for joint surgeons.<sup>8</sup> In the present study, the effect of local blocking therapy with compound betamethasone was investigated on the pain points of the supraspinatus tendon following surgical repair. To the best of our knowledge, this is the first published study to describe this subject. The most important result of the present study was the



**Figure 1.** Visual analogue scale (VAS) scores for nocturnal pain in patients who had undergone arthroscopic repair of supraspinatus tendon tears and had obvious neck and shoulder pain at 3 months following surgery, who either received compound betamethasone by injection at 3 months (experimental group) or did not receive compound betamethasone (control group). \*Statistically significant between-group difference ( $P < 0.05$ , Student's *t*-test).



**Figure 2.** Pittsburgh Sleep Quality Index (PSQI) scores in patients who had undergone arthroscopic repair of supraspinatus tendon tears and had obvious neck and shoulder pain at 3 months following surgery, who either received compound betamethasone by injection at 3 months (experimental group) or did not receive compound betamethasone (control group). \*Statistically significant between-group difference ( $P < 0.05$ , Student's *t*-test).



**Figure 3.** Constant scores for shoulder function in patients who had undergone arthroscopic repair of supraspinatus tendon tears and had obvious neck and shoulder pain at 3 months following surgery, who either received compound betamethasone by injection at 3 months (experimental group) or did not receive compound betamethasone (control group). \*Statistically significant between-group difference ( $P < 0.05$ , Student's *t*-test).

demonstration that persistent dull pain and sleep disturbance was mitigated, and shoulder joint activity function was improved, in patients undergoing the above treatment.

Rotator cuff injury is caused by internal and external factors and involves a process of chronic inflammatory infiltration.<sup>15,16</sup> Synovial inflammation in the subacromial area and glenohumeral joint is a common histological feature of shoulder disorders.<sup>14</sup> Numerous studies have demonstrated that the pain caused by rotator cuff injury is inflammatory pain, which is mainly due to changes in the pain signal channel involving inflammatory mediators. Inflammation is an important cause of pain,<sup>17</sup> and in the current study, all the patients had nocturnal pain after supraspinatus tendon repair that continued into the 3rd postoperative month (VAS scores > 4.3).

Inflammatory reactions have been shown to occur in the bursa tissue of patients with rotator cuff injury.<sup>18</sup> After local injection of dexamethasone and cyclooxygenase inhibitor, the expression of inflammatory mediators decreased significantly.<sup>18</sup> In addition, injection of anaesthetic agents and corticosteroids into the point of tenderness in the acromion and capsule of patients with rotator cuff injury has resulted in significantly alleviated pain.<sup>19,20</sup>

Inspired by the above reports, local blocking therapy with compound betamethasone injections was used in the current study to treat pain points in patients who had undergone supraspinatus tendon surgery, in an attempt to alleviate patient pain. The treatment effect was not sustained in three patients, and their condition was alleviated after reinjection. No significant differences in the VAS score for nocturnal pain, PSQI or Constant score for shoulder function were noted between the two groups at 3 months following surgery. After patients in the experimental group received local blocking therapy, their VAS

and PSQI scores were significantly lower than those of patients in the control group, at 4, 5 and 6 months following surgery, and the Constant score for shoulder function was significantly higher compared with controls. The results suggest that after the pain points in the supraspinatus tendon were locally blocked by compound betamethasone, the pain was significantly relieved, the quality of sleep significantly improved, and the function of the shoulder joint was greatly recovered.

Betamethasone is a type of glucocorticoid.<sup>21</sup> After glucocorticoids bind to the receptors of target cells, they can affect the transcription of some proteins involved in the inflammatory response, and exert anti-inflammatory effects, which is the basic mechanism of the anti-inflammatory effect of glucocorticoids. Glucocorticoids also inhibit some links in the inflammatory process by affecting inflammatory mediators, cytokines and nitric oxide synthase. Glucocorticoids can reduce the expansion of capillaries, exudation, oedema, and infiltration and phagocytosis in inflammatory cells, and alleviate inflammatory manifestations such as redness, swelling, heat and pain.<sup>22</sup> In the current study, all patients had localized pain points at the repair site of the supraspinatus tendon. According to the above mechanism, injection of compound betamethasone was employed to successfully relieve pain by inhibiting the inflammation of pain points.

Compound betamethasone injection is a compound preparation administered at 1 ml per ampoule. The main components include betamethasone sodium phosphate and betamethasone dipropionate. Betamethasone sodium phosphate is a soluble agent that can be quickly absorbed and takes effect after injection. Betamethasone dipropionate is a slightly soluble drug. After local injection, it becomes a repository that slowly provides a supply of drug, and it



continuously exerts its anti-inflammatory effects, with improved conditions being noted over a long time period.<sup>23</sup> A few hours after administration of local blocking therapy, the patients reported feeling that the pain was greatly relieved. The results of this study showed that, after three months of local blocking treatment, there was a greater reduction in pain, and better improvements in sleep quality and shoulder joint function in the experimental group compared with the control group. The good results were attributed to the design of the ingredients included in the betamethasone compound.

Long-term and extensive use of glucocorticoids are associated with many adverse reactions, such as adrenocortical hyper-splenism syndrome, induction or aggravation of infection, osteoporosis, mental disorders, and digestive and cardiovascular complications.<sup>24</sup> Since the therapeutic dose used in the present study was small and only administered once or twice, the above-mentioned adverse reactions should theoretically not occur, and these reactions were not observed in the current study.

The results of the present study may be limited by several factors. First, most of the scores were obtained based on patients' feelings and may have been greatly affected by subjective factors; secondly, although pain was the most important factor affecting patients' sleep quality and shoulder joint activity, multiple other patient-related factors, such as tolerance, patient age, size of the tear, and healing ability, may also have affected the results; thirdly, no magnetic resonance imaging (MRI)-based comparison of results was performed; fourthly, 11 patients were excluded from the study due to their poor understanding and inability to cooperate in completing the survey and physical examination, resulting in a small amount of sampling error; fifthly, the evaluation period of clinical outcomes

was relatively short; and sixthly, the non-randomized, non-blinded study design may have affected the accuracy of the results. Nevertheless, we believe that this study presents meaningful results. Additional comprehensive studies are required that should include comparisons of MRI results, long evaluation periods, and expanded sample sizes.

The results of the present study suggest that the use of compound betamethasone to locally block pain points in the supraspinatus tendon may significantly alleviate postoperative persistent pain, and improve the sleep quality and shoulder function of patients following surgery. The approach recommended in the present study is simple, effective, minimally invasive, relatively inexpensive and easily accepted by patients.

## Conclusion

Chronic neck and shoulder pain, disrupted sleep and shoulder stiffness are common complications after supraspinatus tendon repair. Painful conditions often disrupt sleep and negatively affect the functional exercise of the shoulder. The present results suggest that the use of compound betamethasone to locally block pain points in the supraspinatus tendon may significantly alleviate persistent dull pain after repair surgery and improve patients' sleep quality and shoulder joint activity function.

## Acknowledgement

The authors thank Dr Chang-Ming Xu for his excellent technical assistance.

## Author contributions

LZ and HD conceived the study design. HD, JKS, and LL performed the study, collected the data and contributed to the study design. HD and LZ prepared the manuscript. HD and JKS edited the manuscript. All authors read and approved the final manuscript.

### Data accessibility

All data supporting our findings are contained within the manuscript.

### Declaration of conflicting interest

The Author(s) declare that there is no conflict of interest.

### Funding

This research received no specific grant from any funding agency in the public, commercial, or not-for-profit sectors.

### ORCID iD

Liang Zhou  <https://orcid.org/0000-0001-7225-6775>

### References

- Hovellius L, Augustini BG, Fredin H, et al. Primary anterior dislocation of the shoulder in young patients. A ten-year prospective study. *J Bone Joint Surg Am* 1996; 78: 1677–1684.
- Teunis T, Lubberts B, Reilly BT, et al. A systematic review and pooled analysis of the prevalence of rotator cuff disease with increasing age. *J Shoulder Elbow Surg* 2014; 23: 1913–1921.
- Di Benedetto P, Mancuso F, Tosolini L, et al. Treatment options for massive rotator cuff tears: a narrative review. *Acta Biomed* 2021; 92: e2021026.
- Wilson JM, Boissonneault AR, Schwartz AM, et al. Frailty and malnutrition are associated with inpatient postoperative complications and mortality in hip fracture patients. *J Orthop Trauma* 2019; 33: 143–148.
- Ko JY, Lian WS, Tsai TC, et al. MicroRNA-29a mitigates subacromial bursa fibrosis in rotator cuff lesion with shoulder stiffness. *Int J Mol Sci* 2019; 20: 5742.
- Roberson T and Throckmorton T. Pain after rotator cuff repair. *Curr Orthop Pract* 2016; 27: 156–160.
- Kim JW, Kim YN and Lee DK. The effect of combined exercise with slings and a flexi-bar on muscle activity and pain in rotator cuff repair patients. *J Phys Ther Sci* 2016; 28: 2890–2893.
- Chakravarty K and Webley M. Shoulder joint movement and its relationship to disability in the elderly. *J Rheumatol* 1993; 20: 1359–1361.
- Von Elm E, Altman DG, Egger M, et al. The Strengthening the Reporting of Observational Studies in Epidemiology (STROBE) statement: guidelines for reporting observational studies. *Ann Intern Med* 2007; 147: 573–577.
- Schulz KF, Altman DG and Moher D; CONSORT Group. CONSORT 2010 statement: updated guidelines for reporting parallel group randomized trials. *Ann Intern Med* 2010; 152: 726–732.
- Sateia MJ. International classification of sleep disorders-third edition: highlights and modifications. *Chest* 2014; 146: 1387–1394.
- Şahan MH, Serbest S, Tiftikçi U, et al. Evaluation of arthroscopic rotator cuff repair results in patients with anterior greater tubercle cysts. *J Orthop Surg (Hong Kong)* 2019; 27: 2309499019825602.
- Gilbart MK and Gerber C. Comparison of the subjective shoulder value and the Constant score. *J Shoulder Elbow Surg* 2007; 16: 717–721.
- Serbest S, Tiftikçi U, Askın A, et al. Preoperative and post-operative sleep quality evaluation in rotator cuff tear patients. *Knee Surg Sports Traumatol Arthrosc* 2017; 25: 2109–2113.
- Oliva F, Piccirilli E, Bossa M, et al. I.S.Mu. LT – Rotator cuff tears guidelines. *Muscles Ligaments Tendons J* 2016; 5: 227–263.
- Darrieutort-Laffite C, Blanchard F and Le Goff B. Calcific tendonitis of the rotator cuff: from formation to resorption. *Joint Bone Spine* 2018; 85: 687–692.
- Sakai H, Fujita K, Sakai Y, et al. Immunolocalization of cytokines and growth factors in subacromial bursa of rotator cuff tear patients. *Kobe J Med Sci* 2001; 47: 25–34.
- Kim YS, Bigliani LU, Fujisawa M, et al. Stromal cell-derived factor 1 (SDF-1, CXCL12) is increased in subacromial bursitis and downregulated by steroid and



- nonsteroidal anti-inflammatory agents. *J Orthop Res* 2006; 24: 1756–1764.
19. Çift H, Özkan FÜ, Tolu S, et al. Comparison of subacromial tenoxicam and steroid injections in the treatment of impingement syndrome. *Eklem Hastalik Cerrahisi* 2015; 26: 16–20.
  20. Celik D, Atalar AC, Gülu A, et al. The contribution of subacromial injection to the conservative treatment of impingement syndrome. *Acta Orthop Traumatol Turc* 2009; 43: 331–335.
  21. Wang L, Yang YY, Chung TS, et al. Determination of betamethasone disodium phosphate in the in vitro media of PLGA microspheres by high-performance liquid chromatography. *J Pharm Biomed Anal* 2002; 28: 629–635.
  22. Syed AP, Greulich F, Ansari SA, et al. Anti-inflammatory glucocorticoid action: genomic insights and emerging concepts. *Curr Opin Pharmacol* 2020; 53: 35–44.
  23. Zhang YK, Yang H, Zhang JY, et al. Comparison of intramuscular compound betamethasone and oral diclofenac sodium in the treatment of acute attacks of gout. *Int J Clin Pract* 2014; 68: 633–638.
  24. Ventura MT, Calogiuri GF, Matino MG, et al. Alternative glucocorticoids for use in cases of adverse reaction to systemic glucocorticoids: a study on 10 patients. *Br J Dermatol* 2003; 148: 139–141.