



Is naso-pharyngeal swab always safe for SARS-CoV-2 testing? An unusual, accidental foreign body swallowing

Luca De Luca¹ · Stefania Maltoni¹

Received: 14 July 2020 / Accepted: 3 September 2020 / Published online: 20 September 2020
© Japanese Society of Gastroenterology 2020

Abstract

Long and sharp objects can be foreign body intentionally or accidentally ingested. Timing of endoscopy relies on foreign body shape and size, localization in gastrointestinal tract, patient's clinical conditions, occurrence of symptoms, or onset of complications. We present a case of a 47-year-old male with no known comorbidity, who accidentally swallowed a portion of a naso-pharyngeal swab half-broken during the second diagnostic test for SARS-CoV-2. The intact swab had a total length of 15 cm and was made of wood. The patient was asymptomatic, laboratory tests were normal, and neck-chest-abdominal X-ray and CT scan were negative for major complications. Upper gastrointestinal endoscopy was promptly performed to prevent the long sharp swab from crossing the pylorus leading to serious complications and, therefore, risk surgical intervention. The patient was intubated and the procedure was carried out under general anesthesia. In the gastric body, broken naso-pharyngeal swab was detected among the food debris, and using a latex rubber hood, the 7.5 cm foreign body was removed with a retrieval alligator-tooth forceps. Our hospital is located in a high-risk area of COVID-19 outbreak where many naso-pharyngeal swabs are performed, and to our knowledge, this is the first report of swab ingestion during SARS-CoV-2 test.

Keywords Foreign body · Naso-pharyngeal swab · SARS-CoV-2 test · Upper GI endoscopy

Introduction

In healthy adult, foreign body ingestion is a potentially dangerous clinical problem with an estimated annual incidence of 13/10,000 people [1]. A variety of indigestible foreign bodies are encountered in clinics that 80–90% of patients pass spontaneously without the need for intervention [2, 3], while 10–20% of cases require endoscopic removal. Surgical approach is necessary if endoscopy fails or in the treatment of complications such as perforation. Timing of endoscopy relies on object shape and size, localization in gastrointestinal (GI) tract, patient's clinical conditions, occurrence of symptoms (such as choking, dysphagia, odynophagia, or wheezing), or onset of complications. In this report, we present a gastric endoscopic removal of a broken naso-pharyngeal swab (NPS) accidentally ingested during second diagnostic test for SARS-CoV-2.

Case report

A 47-year-old man was admitted in emergency department of local hospital on May 2020. He was in good health, with no medical history or home therapy. In the early afternoon, he was tested for SARS-CoV-2, after 4 weeks of quarantine isolation. The kit including swab was approved by hospital regulation and the collection of naso-pharyngeal samples was carried out according to protocol [4]. During the procedure, the NPS was accidentally half-broken and swallowed. We looked for a sample of an intact swab and observed that it was made of wood. The total length was 15 cm. The patient was asymptomatic with no respiratory distress, dysphagia, odynophagia, or abdominal pain. Laboratory tests were normal. Nevertheless, we performed a neck, chest, and abdominal biplanar X-ray to exclude major complications. He underwent an otorhinolaryngology consultation and a laryngoscopy with no abnormalities found. Since the foreign body was quite long, it was easy to detect and confirm the site not beyond the stomach by performing Computer Tomography (CT). According to the guidelines, due to foreign body length and sharp pointed form, we decided to perform promptly an upper GI endoscopy. After explaining

✉ Luca De Luca
lucadeluca1210@gmail.com

¹ Department of Internal Medicine, Gastroenterology and Digestive Endoscopy Unit, Ospedali Riuniti Marche Nord, Piazzale Cinelli, 1, 61121 Pesaro, PU, Italy

the patient and his family the potential risks of the procedure, including the inability to retrieve the foreign body and the possibility of complications, we obtained his informed consent and set up the endoscopy room with all personal protective equipment for SARS-CoV-2. Before endoscopy, we tried to grasp a swab with our available devices to determine the most appropriate tool.

The patient was intubated for airway protection from possible ab-ingestis episode (his last meal was 4 h before) and upper GI endoscopy was carried out under general anesthesia and CO₂ insufflation. We used a standard endoscope (Pentax EG-2999i) for major flexibility and handling. In the gastric body, the broken NPS was identified among the food debris (Fig. 1). Since the swab was very long and sharp, we used a latex rubber hood to wrap the tip to avoid the risk of a procedure-related perforation or mucosal damage. After mobilizing food debris, we firmly grasped and gently extracted the foreign body with a retrieval alligator-tooth forceps. The length of the half-broken swab was 7.5 cm (Fig. 2). On a second look, the esophageal and gastric mucosa were undamaged (Fig. 3). The patient remained in observation for 4 h with no symptoms and then was discharged.

Discussion

To our knowledge, this is the first report of NPS ingestion and in particular during an SARS-CoV-2 test. Testing for COVID-19 involves inserting a 15 cm-long swab (like a long Q-tip) into the cavity between the nose and the mouth

for 15 s and gently rotating the swab several time. The swabbing should be then repeated on the other side of the nose to make sure that enough material is collected. The swabbing is then inserted into a container and sent to a lab for testing.

Published studies indicate that between 52 and 97% of foreign body ingestion in the general population are accidental [5]. Foreign body ingestions more frequently occur in pediatric population, adults with psychiatric disorders, prisoners, or edentulous individuals. The majority of them (80–90%) pass through the GI tract spontaneously and without complications [6]. Foreign body ingestion can be classified in blunt objects (e.g., coin, button, batteries, magnets, and small toys), sharp pointed objects (e.g., needle, bone, glass pieces, and razor blade), long objects (e.g., cord, toothbrush, pen, and cutlery), or packed illegal drugs.

The long objects (> 5 cm) more commonly remain in the stomach, but, in approximately 15% of cases, could pass through the pylorus stopping in the duodenal flexure for its angulation. Just in 4% of cases, they passed down until the intestine.

Endoscopy has become the choice as method of managing most of foreign bodies' ingestions with a success rate from 83 to 99% [7]. The timing of endoscopic intervention as well as the choice of retrieval devices are essentials for gastroenterologists to avoid complications and reduce morbidity.

As recommended by consensus statement [3], the first step is the patient diagnostic evaluation, by focusing on medical history or comorbidity, ingestion time, kind of foreign body, and clinical symptoms.

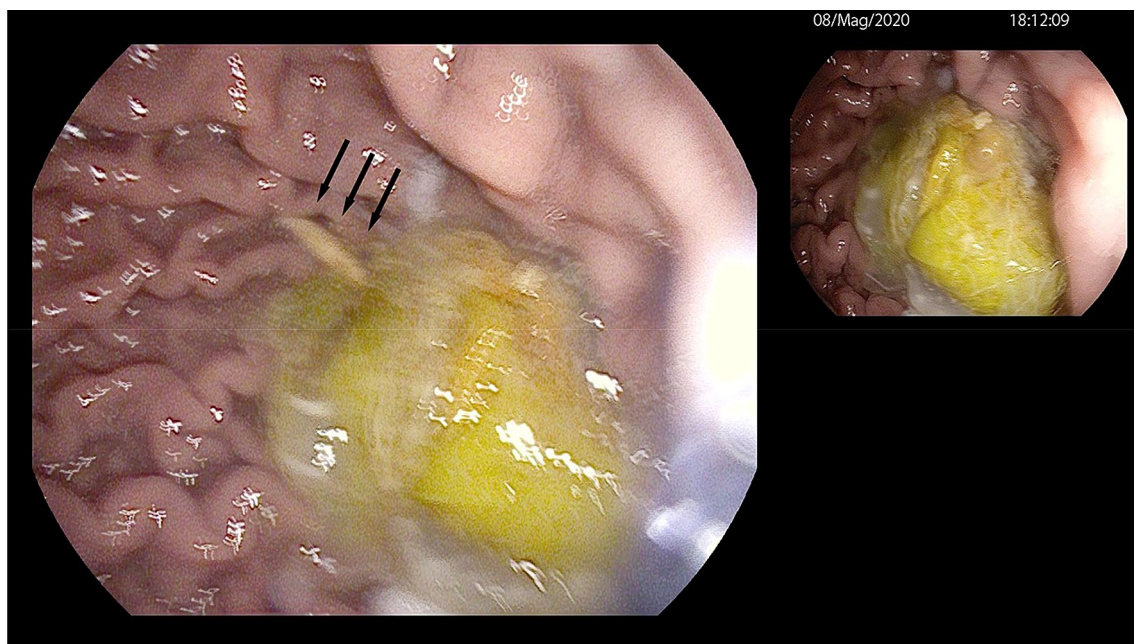


Fig. 1 Upper GI endoscopy revealed in the gastric body part of the broken NPS (black arrow) among the food debris

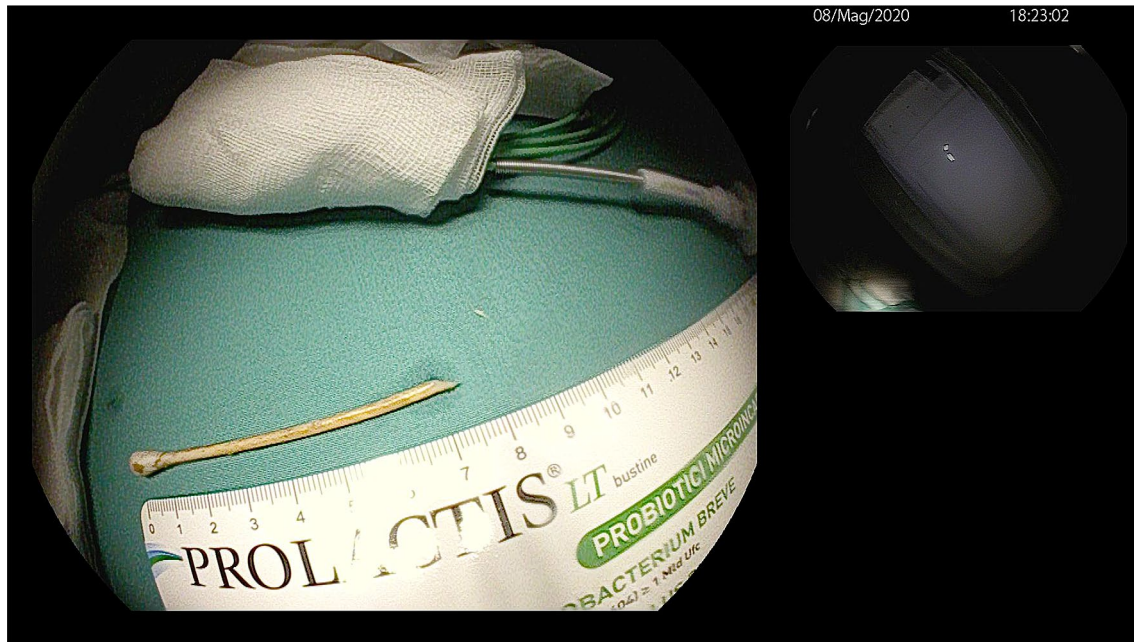


Fig. 2 The half-broken NPS was removed from stomach and seemed to be largely intact. The length of the long and sharp foreign body was 7.5 cm

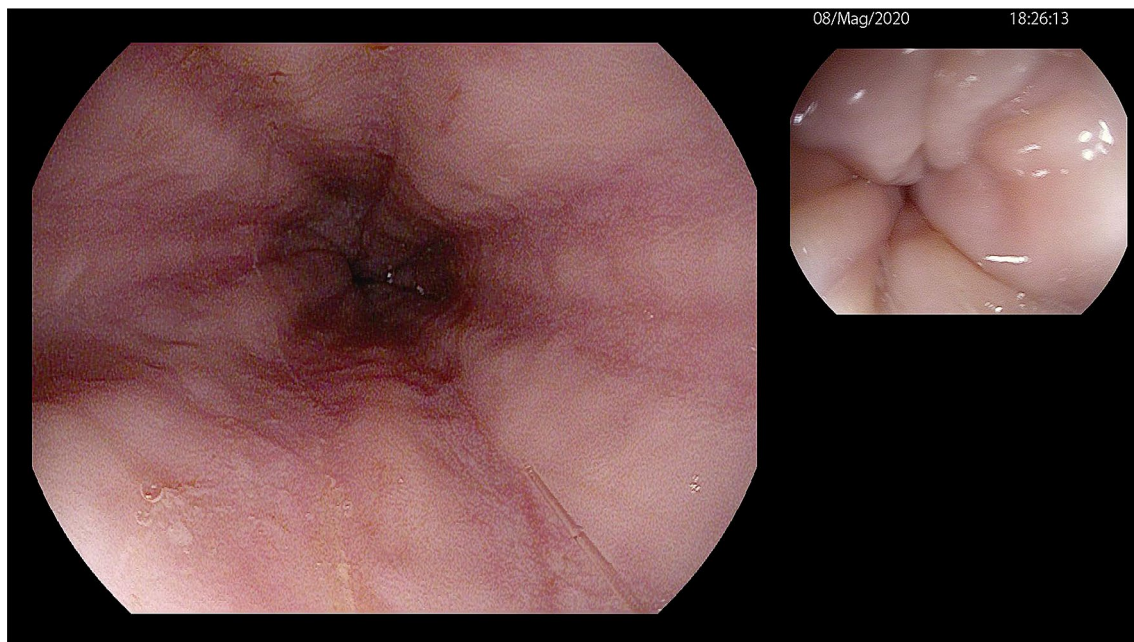


Fig. 3 On repeating endoscopic inspection, no esophageal mucosal trauma was observed

The second step is the foreign body anatomic localization with imaging studies. Biplanar X-rays of neck/chest/abdomen could provide information about dimension and site of radiopaque object. Barium swallow is not recommended for the risk of aspiration and to avoid worsening endoscopic visualization. If perforation or major

complications (abscess, mediastinitis, or fistulas) are suspected, CT scan is indicated. In patients with strong suspicion of non radiopaque foreign body ingestion and without evidence of complications (e.g., no evidence of perforation or respiratory distress), endoscopic evaluation is recommended.

Standard or therapeutic endoscopes are preferable, although small-caliber endoscopes may be successfully used [8]. Earlier intervention is associated with a lower risk of complications [9]. Several retrieval devices as rat tooth or alligator forceps, polypectomy snares or baskets, have been used. Before endoscopy, grasping an object which is similar to the ingested foreign body may increase the chance of success. An overtube or a latex rubber hood has to be used to prevent mucosal injuring during retrieval and accidental slippage of the object into the trachea.

In the case described, nursing staff carried out the procedure, but we are unable to establish whether the rupture of the NPS was attributable to the defective kit or to excessive pressure during the test by the operator. The swab should be inserted gently along the nasal septum, just above the floor of the nasal passage, to the nasopharynx, until resistance is felt. However, if you feel resistance to the tampon, you should step back and try to reinsert it at a different angle, closer to the floor of the nasal canal leaving the swab in place for several seconds to absorb secretions and then slowly removing the swab by twisting it.

It was essential to intervene promptly to prevent the long sharp swab from crossing the pylorus leading to serious complications and, therefore, risk surgical intervention. Furthermore, the presence of food in the stomach made the procedure very challenging for the endoscopist trying to remove the foreign body safely. The current report highlights a unique, accidental foreign body ingestion that should be managed conservatively in appropriate setting and expertise. Furthermore, it must be considered that our hospital is located in a high-risk area of COVID-19 outbreak where many NPSs are performed and it has undergone a dramatic burden for endoscopy unit, disrupting its daily routine [10]. Therefore, in COVID-era, we must be very careful when carrying out NPS tests, because it can transform in a potentially dangerous foreign body for endoscopists!

Author contributions All authors have contributed equally to the study. They have read and agreed to the published version of the manuscript.

Funding This case report received no external funding.

Compliance with ethical standards

Conflict of interest Luca De Luca and Stefania Maltoni declare that they have no conflict of interest.

Human and animal rights All procedures followed have been performed in accordance with the ethical standards laid down in the 1964 Declaration of Helsinki and its later amendments.

Informed consent Informed consent was obtained from all patients for being included in the study.

References

1. Longstreth GF, Longstreth KJ, Yao JF. Esophageal food impaction: epidemiology and therapy. A retrospective, observational study. *Gastrointest Endosc.* 2001;53:193–8.
2. ASGE Standards of Practice Committee, Ikenberry SO, Kue TL, Andersen MA, et al. Management of ingested foreign bodies and food impactions. *Gastrointest Endosc.* 2011;73:1085–91.
3. Birk M, Bauerfeind P, Deprez PH, et al. Removal of foreign bodies in the upper gastrointestinal tract in adults: European Society of Gastrointestinal Endoscopy (ESGE). *Clin Guidel Endosc.* 2016;48:489–96.
4. Marty FM, Chen K, Verrill KA. How to obtain a nasopharyngeal swab specimen. *N Engl J Med.* 2020;382:e76.
5. Chaves DM, Ishioka S, Felix VN, et al. Removal of a foreign body from the upper gastrointestinal tract with a flexible endoscope: a prospective study. *Endoscopy.* 2004;36:887–92.
6. Webb WA. Management of foreign bodies of the upper gastrointestinal tract: update. *Gastrointest Endosc.* 1995;41:39–51.
7. Katsinelos P, Kountouras J, Paroutoglou G, et al. Endoscopic techniques and management of foreign body ingestion and food bolus impaction in the upper gastrointestinal tract: a retrospective analysis of 139 cases. *J Clin Gastroenterol.* 2006;40:784–9.
8. Chu KM, Choi HK, Tuen HH, et al. A prospective randomized trial comparing the use of the flexible gastroscope versus the bronchoscope in the management of foreign body ingestion. *Gastrointest Endosc.* 1998;47:23–7.
9. Chaves DM, Ishioka S, Félix VN, et al. Removal of a foreign body from the upper gastrointestinal tract with a flexible endoscope: a prospective study. *Endoscopy.* 2004;36:887–92.
10. Repici A, Pace F, Gabbiadini R, et al. Endoscopy units and the COVID-19 Outbreak: a multi-center experience from Italy. *Gastroenterology.* 2020;159(1):363–366.e3.

Publisher's Note Springer Nature remains neutral with regard to jurisdictional claims in published maps and institutional affiliations.