

Received: 2016.02.12  
Accepted: 2016.03.01  
Published: 2016.10.11

# Prophylactic Administration of Silybin Ameliorates L-Arginine-Induced Acute Pancreatitis

Authors' Contribution:  
Study Design A  
Data Collection B  
Statistical Analysis C  
Data Interpretation D  
Manuscript Preparation E  
Literature Search F  
Funds Collection G

ABCDE 1 **Feyzullah Uçmak**  
BCEF 2 **Nazım Ekin**  
BEF 3 **İbrahim İbiloğlu**  
EF 4 **Serkan Arslan**  
BE 5 **İbrahim Kaplan**  
ADEF 6 **Ebubekir Şenates**

1 Department of Gastroenterology, Dicle University, School of Medicine, Diyarbakir, Turkey  
2 Gastroenterology Clinic, Gazi Yasargil Education and Research Hospital, Diyarbakir, Turkey  
3 Department of Pathology, Dicle University, School of Medicine, Diyarbakir, Turkey  
4 Department of Pediatric Surgery, Dicle University, School of Medicine, Diyarbakir, Turkey  
5 Department of Biochemistry, Dicle University, School of Medicine, Diyarbakir, Turkey  
6 Department of Gastroenterology, Medeniyet University, School of Medicine, İstanbul, Turkey

**Corresponding Author:** Feyzullah Ucmak, e-mail: ucmakfeyz@gmail.com  
**Source of support:** Departmental sources

**Background:** Oxidative stress have been shown to play a role in the pathogenesis of acute pancreatitis. The aim of this study was to investigate the potential effect of silybin, a potent antioxidant, on L-arginine-induced acute pancreatitis in an experimental rat model.

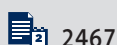**Material/Methods:** Forty female Wistar Albino rats were divided into 5 groups as follows: Group 1 (C): control group (n=8), Group 2 (SL): silybin group (n=8), Group 3 (LA): acute pancreatitis group (n=8), Group 4 (SLLA): prophylaxis group (n=8), and Group 5 (LASL): treatment group (n=8). Group C (control) received 2 intraperitoneal (i.p.) injections of physiological saline at an interval of 1 h. Group SL received only a single i.p. injection of silybin. The SLLA group received a single i.p. injection of silybin before the induction of acute pancreatitis with L-arginine, whereas the LASL group received the same injection after the induction of acute pancreatitis with L-arginine. Pancreatic tissues were histopathologically examined. Levels of amylase and oxidative stress markers (total oxidant status and total anti-oxidant status) were determined in the blood samples. Oxidative stress index was calculated.

**Results:** In comparison to the LA, the prophylaxis and treatment groups showed significant improvements in serum oxidative stress parameters (p=0.001 and p=0.005, respectively). Histopathological analysis showed that the treatment group had significant improvements in edema scores only (p=0.006), whereas the prophylaxis group had the same improvements in inflammation and necrosis scores as well as in total scores (p=0.004, 0.006, and 0.004, respectively).

**Conclusions:** When used for prophylactic rather than therapeutic purposes, silybin ameliorates serum oxidative stress parameters and improves histopathological results via its antioxidant and anti-inflammatory properties.

**MeSH Keywords:** Antioxidants • Arginine • Pancreatitis, Acute Necrotizing • Silymarin

**Full-text PDF:** <http://www.medscimonit.com/abstract/index/idArt/898014>



2467



1



1



38



## Background

Acute pancreatitis (AP) is a common disease of the gastrointestinal tract, with a serious potential to burden the patient with physical, emotional, and economic problems [1,2]. The reported case fatality rate for AP has gone down over time; however, the overall population mortality rate has not meaningfully changed [1].

AP is typically characterized by edema and inflammatory infiltration. However, it might also manifest with necrosis and hemorrhage in severe cases [3]. A full recovery is usually expected in the vast majority of the cases that show a non-complicated progress. However, the disease progress into the severe form in 15–20% of cases. This severe form is called necrotizing pancreatitis and might exhibit a mortality rate as high as 30% [4,5].

There are still debates over the exact mechanism of pancreatitis, which remains a complex disease. Injured pancreatic acinar cells pave the way for a series of complex events, including increased generation of reactive oxygen species (ROS) [6]. Polyunsaturated fatty acids, which are abundantly present in the mitochondrial membrane and in the plasma membrane, are easily targeted by ROS. A reaction between these acids and ROS (especially hydroxyl free radicals) causes lipid peroxide formation, resulting in membrane disintegration and pancreatic necrosis [7].

Silybin is a flavanolignan that accounts for 60% of silymarin. As a major active agent, it exerts antioxidant effects by inhibiting formation of radicals, scavenging free radicals, and hampering lipid peroxidation of membranes and thereby controlling membrane permeability, and causing increased intracellular content of scavenger [8]. In several hepatotoxicity models, it was shown to provide protection against oxidative peroxidation of cells [9,10]. Moreover, it was reported to prevent severe hepatic failure and save lives when administered within 48 h after *Amanita phalloides* mushroom poisoning in humans [11].

The aim of the present study was to investigate the potential effect of silybin on AP, considering its experimentally and clinically proven antioxidant effects on hepatic diseases.

## Material and Methods

This study was undertaken with approval of the local ethics committee. It was performed at the Experimental Animals and Research Laboratory of the Faculty of Medicine of Dicle University (Diyarbakir, Turkey). All the animals were provided with proper care in accordance with the Principle of Laboratory Animal Care formulated by the National Society for Medical Research.

Forty female Wistar albino rats weighing 200–250 g were included in the study. The animals were fed with standard rat chow and tap water ad libitum. They were maintained in a 12-h light/dark cycle at 21°C for 1 week prior to the study. They were placed on restricted food intake with no restriction on water intake 12 h before the induction of anesthesia.

AP was induced by 2 injections of 250 mg/100 g of L-arginine (Sigma Chemical, St. Louis, MO, USA) prepared with 20% 0.15 M NaCl and administered via intraperitoneal (i.p.) route at 1-h intervals [12].

As in the previously reported studies, 528.5 mg of silybin (Legalon® SIL, Madaus Co., Koln, Germany) was dissolved in 35 ml of 0.9% NaCl+5% dextrose water (D55N) and administered at a single dose of 100 mg/kg by i.p. injection [13].

The rats were anesthetized with 50 mg/kg of ketamine hydrochloride (Ketalar® Pfizer, Istanbul) and 5 mg/kg of xylazine hydrochloride (Rompon® Bayer, Sisli, Istanbul) administered via intramuscular (i.m.) route under aseptic conditions. With the rats placed in the spine position, the anterior abdominal wall was shaved, and povidone iodine antiseptic was applied. The rats were divided into 5 groups, each consisting of 8 subjects.

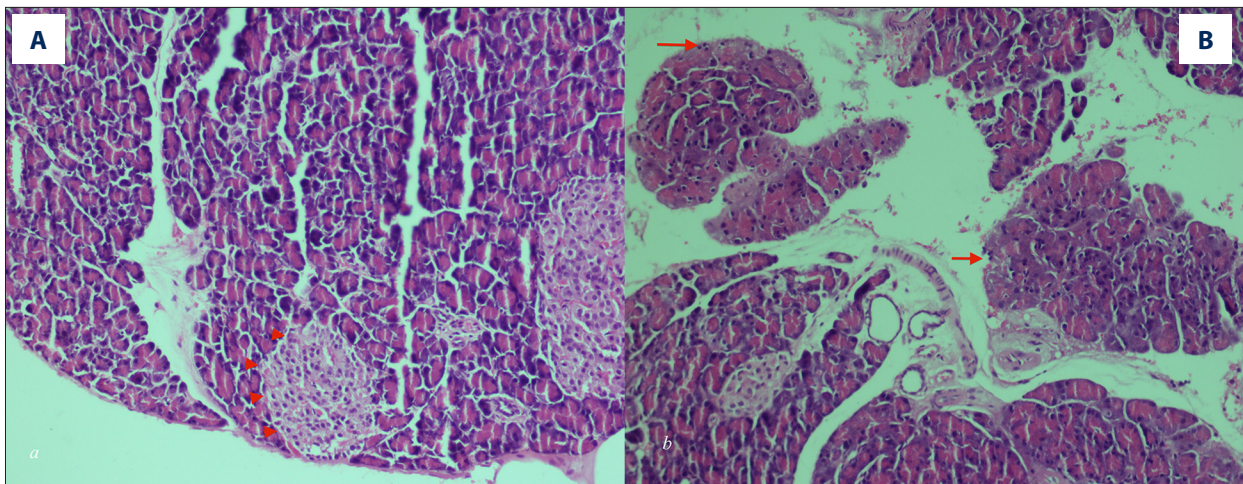
## Groups

After 7 days of acclimatization, the rats were divided into 5 groups ( $n=8$  per group). The LA group received 2 i.p. injections of L-arginine 1 h apart. The SLLA group received a single i.p. injection of silybin at a dose of 100 mg/kg body weight 60 min before the induction of AP with L-arginine, whereas the LASL group received the same dose of silybin after the second injection of L-arginine. The SL group received a single i.p. injection of silybin at a dose of 100 mg/kg body weight. Lastly, group C served as the control group and received 2 i.p. injections of physiological saline 1 h apart.

## Biochemical and histopathological analyses

Blood samples were taken from the rats following cardiac puncture to measure amylase, TAS, and TOS levels. These samples were placed in ice and transported to the Biochemistry Laboratory, where they were centrifuged at 3000 rpm for 3 min for separation. Laparotomy was performed in the rats to remove the pancreatic tissue.

The pancreatic tissue samples were fixed in 10% neutral buffered formalin solution for histopathological analysis. The microscopic sections were stained with hematoxylin-eosin. All histopathological analyses were performed under light microscopy in a blinded manner by the same pathologist (I.I.). Edema, acinar cell necrosis, hemorrhage, and inflammation



**Figure 1.** Normal pancreatic tissue and Langerhans cells (arrow heads) were observed in the LA group (A) (H-E stain,  $\times 200$ ). Severe acinar cell necrosis of the pancreas (arrows) by L-arginine in the LA group (B) (H-E stain,  $\times 200$ ).

were histopathologically evaluated in the pancreas (Figure 1). Histopathological evaluations were performed using the scoring system described by Spormann et al. [14].

Amylase levels were measured on an Architect C 16000 device manufactured by Abbott, using the original Abbott kits.

TAS and TOS levels were measured with the Abbott Architect C16000 auto analyzer (Illinois, USA) using the commercially available kits (Relassay, Turkey). The automated colorimetric measurement methods developed by Erel were employed for TAS and TOS measurements [15,16]. The ratio of TOS to TAS was accepted as OSI. TAS levels were converted to  $\mu\text{mol Trolox Eq/L}$ . OSI was calculated using the following formula:  $\text{OSI} = \text{TOS} (\mu\text{mol/L H}_2\text{O}_2) / [\text{TAS} (\mu\text{Mol/L Trolox}) \times 100]$ .

### Statistical analyses

All statistical analyses were performed using SPSS 18.0 for Windows. Data are expressed as means and standard deviations (SD). Multiple comparisons among groups were performed by means of the Kruskal-Wallis test and the Mann-Whitney U test. Statistical significance was determined using two-tailed tests. A  $p$  value smaller than 0.05 was considered statistically significant.

## Results

One of the rats in the Group LA died before the procedure. As a result, 39 rats were operated on in this study. The SL group exhibited no significant alterations in the measured parameters in comparison to the control group.

The results of the biochemical analyses are demonstrated in Table 1. The highest amylase level was observed in the LA

group ( $1396 \pm 1154$  IU/ml). There was a significant difference between the LA group and the control group in amylase levels ( $p=0.008$ ). TOS and OSI levels were significantly elevated in the LA group compared to the SLLA and LASL groups ( $p=0.001$  and  $p=0.005$ , respectively). The highest TAS level was detected in the LASL group ( $0.87 \pm 0.25 \mu\text{mol H}_2\text{O}_2$  equivalent/L) and the lowest in the LA group ( $0.57 \pm 0.10 \mu\text{mol H}_2\text{O}_2$  equivalent/L). TAS levels in the SLLA and LASL groups were significantly higher than those in the LA group ( $p=0.001$  and  $0.003$ , respectively).

The histopathological analyses revealed that edema, perivascular inflammation, and necrosis scores, as well as total scores, were highest in the LA group. All the scores except for hemorrhage score were significantly higher in the LA group compared to the control group ( $p=0.001$ ). The histopathological evaluations demonstrated that perivascular inflammation and necrosis scores as well as total scores were significantly lower in the SLLA group than in the LA group ( $p=0.004$ ,  $p=0.011$  and  $p=0.007$ , respectively). Detailed analyses of the scores are demonstrated in Table 1. Total scores and perivascular inflammation scores were significantly lower in the SLLA group than in the LASL group ( $p=0.012$  and  $p=0.044$ , respectively).

## Discussion

Although it has long been a prominent subject of research, pancreatic inflammation still lacks a through pathogenetic explanation and a specific treatment strategy. Today, common therapeutic approaches used for AP include enteral and parenteral nutrition, antibiotic treatment, and surgical removal of the necrotic tissue [17,18], which mostly fail to target the primary insult to the pancreas and instead deal with symptoms and complications. Therefore, experimental studies investigating potential treatment strategies that might complement the

**Table 1.** Scores of pancreatic damage and biochemical parameters of all groups.

	Groups*					p, comparison between groups**			
	Control	Silybin	LA	SLLA	LASL	Control & LA	LA & SLLA	LA & LASL	SLLA & LASL
<b>Histopathologic findings of pancreas</b>									
Edema	0	0	0.85±0.37	0.50±0.53	0.12±0.35	0.001	>0.05	0.006	>0.05
Inflammation	0	0	1.00±0.00	0.25±0.46	0.87±0.83	<0.001	0.004	>0.05	>0.05
Necrosis	0	0	1.00±0.57	0.12±0.35	1.12±0.83	0.001	0.006	>0.05	0.012
Hemorrhage	0.25±0.46	0.25±0.46	0.14±0.37	0	0.12±0.35	>0.05	>0.05	>0.05	>0.05
Total score	0.25±0.46	0.25±0.46	3.00±1.00	0.75±1.03	2.25±1.58	0.001	0.004	>0.05	0.044
<b>Biochemical parameters</b>									
TOS (µm Trolox equiv/L)	4919±2163	2768±1322	6409±3882	703±389	1403±1052	>0.05	0.001	0.005	>0.05
TAS (µm H <sub>2</sub> O <sub>2</sub> equiv/L)	0.64±0.16	0.59±0.12	0.57±0.10	0.86±0.08	0.87±0.25	>0.05	0.001	0.003	>0.05
OSI (Arbitrary unit)	80.8±35.3	65.7±44.0	112.1±69.8	7.9±4.1	15.6±9.7	>0.05	0.001	0.001	>0.05
Amylase	464±87	444±76	1396±1154	765±77	1470±1013	0.008	>0.05	>0.05	>0.05

\* Values are given mean ±SD; \*\* Comparasions was done by Mann Whitney U test.

available therapeutic approaches for this catastrophic disease are of paramount importance.

In this experimental study, the effectiveness of silybin on L-arginine-induced AP was investigated. We found that serum levels of oxidative stress parameters were significantly elevated in the rats with L-arginine-induced AP. When compared to the LA group, the LASL group showed significant improvements in serum oxidative stress parameters only, whereas the SLLA group exhibited these improvements in both histopathological and serum oxidative parameters.

Although the pathogenesis of AP has yet to be fully explained, the involvement of oxidative stress is quite obvious [6,19]. Unstable reactive nitrogen species (RNS) and ROS are inclined to reaction with essential cellular components. Glutathione (GSH) is the primary cellular ROS scavenger in the pancreas. The thiol group in the cysteine moiety of GSH is its reducing capability. The pancreatic concentration of GSH is the fourth largest concentration among all visceral organs [20]. Although GSH has the major cellular antioxidant capacity in the pancreas, there are also other cellular antioxidants in the pancreas [19]. Elimination of ROS in general, and of ROS in the peroxide family (ROOH) in particular, happens through the actions of an enzyme containing selenium – GSH peroxidase (GPx). GPx

causes a facilitated process of peroxide reduction into water or related alcohols via oxidation of GSH [19]. Reduced activity and/or expression of enzymes with antioxidant effects adds to the oxidative stress in pancreatitis. The levels of pancreatic GPx were reported to show significant alterations in different experimental AP and CP models [21]. Induction of AP by administration of arginine was shown to cause a reduction in pancreatic GPx activity [22]. Patients with AP were reported to exhibit reduced red blood cell GPx activity [23]. In addition, patients with severe AP had lower serum GPx activity than patients with mild AP, which suggests a correlation between GPx activity and severity of disease [24].

Oxidative stress shows a self-amplifying property, which is due to the recruitment of ROS-producing inflammatory cells to the pancreas. These recruited cells cause further insult to the pancreas as they put an extra oxidative burden on the glands through a respiratory burst [19]. Mitogen-activated protein kinase (MAPK) and nuclear factor kappa B (NFkB), which control a number functions related to cytoskeletal regulation, transcription factor activation, apoptosis, differentiation, proliferation, growth and inflammation, are sensitive to oxidative stress. MAPK and NFkB are present in pancreatic exocrine cells [19,25]. ROS initiate the activation of MAPK and regulate NFkB, an effective proinflammatory transcription factor [19].

L-arginine is an essential amino acid that was previously used to induce severe necrotizing AP in rats. Tani et al. reported that i.p. injection of L-arginine induced acute necrotizing pancreatitis in a rat model [12]. L-arginine creates free oxygen radicals (FOR) and exerts effects on microcirculation, whereby it damages the pancreas. [26].

Silybin exerts effects generally through its antioxidant and anti-inflammatory properties. Its antioxidant properties were shown in all of the cells that were previously investigated. It shows antioxidant effects by inhibiting formation of radicals, scavenging free radicals, hampering lipid peroxidation of membranes (thereby controlling membrane permeability), and causing an increased intracellular content of scavenger [27]. In broad terms, silymarin and silybin interfere with the transduction cascade controlled by NF $\kappa$ B, an inducible and abundantly expressed DNA-binding protein acting as a transcription factor for genes engaged in cell survival, differentiation, inflammation, and growth [28].

In the present study, histopathological evaluations revealed significant improvements in inflammation and necrosis scores in the SLLA group, which received early prophylactic treatment, whereas such improvements were limited to edema scores in the LASL group. Similarly, a previous study in a rat model of L-arginine-induced AP demonstrated distant organ improvements in the lungs as well as pancreatic improvements following early antioxidant treatment. It is likely that these results arise from the recruitment of inflammatory cells and less strong induction of NF $\kappa$ B as a result of reduced self-amplifying effects of ROS in the presence of strong antioxidants at the outset of the inflammation.

Severe AP, characterized by persistent organ failure that fails to resolve within 48 h and/or death, represents 15–20% of the cases [5,29]. Pancreatic necrosis is a serious condition that can cause local and systemic complications [5,29]. Polyunsaturated fatty acids, which are abundantly present in the mitochondrial membrane as well as in the plasma membrane, are easily targeted by ROS/RNS. A reaction between these acids and ROS (especially hydroxyl free radicals) causes lipid peroxide formation, resulting in membrane disintegration and pancreatic necrosis [7]. In the present study, silybin was shown to cause significant improvements in pancreatic necrosis scores in the SLLA group compared to the LA group ( $p=0.006$ ).

AP is most commonly caused by gallstones and alcohol [30]. It is the most frequently observed complication of endoscopic retrograde cholangiopancreatography (ERCP), which was reported to occur in 5–10% of the cases and in 20–40% of certain high-risk procedures [31]. Numerous pharmacological drug trials were undertaken in an effort to prevent this complication,

but they mostly failed to give the desired results [32]. In this respect, the drugs with the most promising results in weakening the inflammatory response of AP are the non-steroidal anti-inflammatory drugs (NSAIDs) [33]. Rectal NSAIDs have considerable potential to prevent post-ERCP pancreatitis; however, they fail to show the same potential to prevent the development of severe post-ERCP pancreatitis [31]. In the present study, the greatest improvements in oxidative stress and histopathological parameters were observed in the prophylaxis group, suggesting that prophylactic administration of silybin could be helpful in avoiding post-ERCP pancreatitis, which remains a serious complication today.

AP is a multi-system disease that can involve not only pancreas but also liver, lungs, and kidneys, with serious potential to cause distant organ dysfunction and death [34,35]. The liver assumes pivotal importance in metabolic homeostasis and clearance of toxic substances and is involved in the systemic response to critical illnesses [36]. In a caerulein-induced AP model, Esresföglu et al. demonstrated the restrictive power the antioxidant agents exerted over pancreatic and hepatic damage through tissue antioxidant enzyme activities [35]. Silybin, which was experimentally and clinically shown to be effective in hepatic diseases, is likely to be as effective as other antioxidants in hepatic damage caused by AP [9–11].

AP was previously reported to interfere with the endocrine functions of the pancreas [37]. On the other hand, silybin was shown in animal and human studies to exert positive effects on these functions [38,39]. These studies demonstrated the significant effects of silybin on plasma glucose and triglyceride levels, with a trend toward reduced levels of hemoglobin A1c.

## Conclusions

Silybin treatment ameliorated increased oxidative stress in an experimental AP model in this study. Prophylactic administration of silybin, on the other hand, ameliorated both histopathological and oxidative stress parameters. Available therapeutic approaches targeting oxidative stress, a critical pathogenic factor, fail to produce the desired results in acute inflammation of the pancreas. Therefore, there is a need to try new agents. The present study shows that silybin, which has both antioxidant and anti-inflammatory properties and can safely be used in hepatic diseases, can be a helpful clinical agent in AP. However, further studies are required to confirm the findings of this study.

## Conflict of interest

None.

## References:

- Peery AE, Dellon ES, Lund J et al: Burden of gastrointestinal diseases in the United States: 2012 Update. *Gastroenterology*, 2012; 143: 1179–87
- Fagenholz PJ, Fernandez-del Castillo C, Harris NS et al: Direct medical costs of acute pancreatitis hospitalizations in the United States. *Pancreas*, 2007; 35: 302–7
- Chan YC and Leung PS: Acute pancreatitis: Animal models and recent advances in basic research. *Pancreas*, 2007; 34: 1–14
- Weber CK, Adler G: From acinar cell damage to systemic inflammatory response: Current concepts in pancreatitis. *Pancreatology*, 2001; 1: 356–62
- Banks PA, Freeman ML: Practice guidelines in acute pancreatitis. *Am J Gastroenterol*, 2006; 101: 2379–400
- Robles L, Vaziri ND, Ichii H: Role of oxidative stress in the pathogenesis of pancreatitis: Effect of antioxidant therapy. *Pancreat Disord Ther*, 2013; 3: 112
- Schoenberg MH, Birk D, Beger HG: Oxidative stress in acute and chronic pancreatitis. *Am J Clin Nutr*, 1995; 62: 1306–145
- Trouillas P, Marsal P, Svobodová A et al: Mechanism of the antioxidant action of silybin and 2,3-dehydrosilybin flavonolignans: A joint experimental and theoretical study. *J Phys Chem A*, 2008; 112: 1054–63
- Letteron P, Labbe G, Degott C et al: Mechanism for the protective effects of silymarin against carbon tetrachloride-induced lipid peroxidation and hepatotoxicity in mice. Evidence that silymarin acts both as an inhibitor of metabolic activation and as a chain-breaking antioxidant. *Biochem Pharmacol*, 1990; 39: 2027–34
- Muriel P, Garcapiña T, Perez-Alvarez V, Mourelle M: Silymarin protects against paracetamol-induced lipid peroxidation and liver damage. *J Appl Toxicol*, 1992; 12: 439–42
- Salhanick SD, Wax PM, Schneider SM: In response to Tong TC, et al. Comparative treatment of alpha-amanitin poisoning with N-acetylcysteine, benzylpenicillin, cimetidine, thiocetic acid, and silybin in a murine model. *Ann Emerg Med*, 2008; 52: 184–85
- Tani S, Itoh H, Okabayashi Y et al: New model of acute necrotizing pancreatitis induced by excessive doses of arginine in rats. *Dig Dis Sci*, 1990; 35: 367–74
- Jung UJ, Jeon MT, Choi MS, Kim SR: Silybin attenuates MPP<sup>+</sup>-induced neurotoxicity in the substantia nigra *in vivo*. *J Med Food*, 2014; 17: 599–605
- Spormann H, Sokolowski A, Letko G: Effect of temporary ischemia upon development and histological patterns of acute pancreatitis in the rat. *Pathol Res Pract*, 1989; 184: 507–13
- Erel O: A new automated colorimetric method for measuring total oxidant status. *Clin Biochem*, 2005; 38(12): 1103–11
- Erel O: A novel automated direct measurement method for total antioxidant capacity using a new generation, more stable ABTS radical cation. *Clin Biochem*, 2004; 37(4): 277–85
- Makola D, Krenitsky J, Parrish CR: Enteral feeding in acute and chronic pancreatitis. *Gastrointest Endosc Clin North Am*, 2007; 17: 747–64
- Mitchell RM, Byrne MF, Baillie J: Pancreatitis. *Lancet*, 2003; 361: 1447–55
- Leung PS, Chan YC: Role of oxidative stress in pancreatic inflammation. *Antioxid Redox Signal*, 2009; 11: 135–65
- Githens S: Glutathione metabolism in the pancreas compared with that in the liver, kidney, and small intestine. *Int J Pancreatol*, 1991; 8: 97–109
- Szuster-Ciesielska A, Daniluk J, Kandefler-Szerszeń M: Oxidative stress in blood of patients with alcohol-related pancreatitis. *Pancreas*, 2001; 22: 261–66
- Czakó L, Takács T, Varga IS et al: Oxidative stress in distant organs and the effects of allopurinol during experimental acute pancreatitis. *Int J Pancreatol*, 2000; 27: 209–16
- Musil F, Zadák Z, Solichová D et al: Dynamics of antioxidants in patients with acute pancreatitis and in patients operated on for colorectal cancer: A clinical study. *Nutrition*, 2005; 21: 118–24
- Wereszczynska-Siemiakowska U, Mroczko B, Siemiakowski A et al: The importance of interleukin 18, glutathione peroxidase, and selenium concentration changes in acute pancreatitis. *Dig Dis Sci*, 2004; 49: 642–50
- Kikuta K, Masamune A, Satoh M et al: 4-hydroxy-2, 3-nonenal activates activator protein-1 and mitogen-activated protein kinases in rat pancreatic stellate cells. *World J Gastroenterol*, 2004; 10: 2344–51
- Hegyi P, Rakonczay Z Jr, Sari R et al: L-arginine-induced experimental pancreatitis. *World J Gastroenterol*, 2004; 10: 2003–9
- Loguercio C, Festi D: Silybin and the liver: From basic research to clinical practice. *World J Gastroenterol*, 2011; 17: 2288–301
- Bremner P, Heinrich M: Natural products as targeted modulators of the nuclear factor-kappaB pathway. *J Pharm Pharmacol*, 2002; 54: 453–72
- Banks PA, Bollen TL, Dervenis C et al: Classification of acute pancreatitis – 2012: Revision of Atlanta classification and definitions by international consensus. *Gut*, 2013; 62: 102–11
- Tenner S, Baillie J, DeWitt J, Vege SS, American College of Gastroenterology: American College of Gastroenterology guideline: management of acute pancreatitis. *Am J Gastroenterol*, 2013; 108: 1400–15
- Isaji S, Takada T, Mayumi T et al: Revised Japanese guidelines for the management of acute pancreatitis 2015: Revised concepts and updated points. *J Hepatobiliary Pancreat Sci*, 2015; 22: 433–45
- Badalov N, Tenner S, Baillie J: Prevention and treatment of post-ERCP pancreatitis. *JOP*, 2009; 10: 88–97
- Elmunzer BJ, Waljee AK, Elta GH et al: A meta-analysis of rectal NSAIDs in the prevention of post-ERCP pancreatitis. *Gut*, 2008; 57: 1262–67
- Norman J: The role of cytokines in the pathogenesis of acute pancreatitis. *Am J Surg*, 1998; 175: 76–83
- Eşrefoğlu M, Gül M, Ates B et al: Antioxidative effect of melatonin, ascorbic acid and N-acetylcysteine on caerulein-induced pancreatitis and associated liver injury in rats. *World J Gastroenterol*, 2006; 12: 259–64
- Malecka-Panas E, Gasiorowska A, Kropiwnicka A et al: Endocrine pancreatic function in patients after acute pancreatitis. *Hepatogastroenterology*, 2002; 49: 1707–12
- Maghrani M, Zeggwagh NA, Lemhadri A et al: Study of the hypoglycaemic activity of *Fraxinus excelsior* and *Silybum marianum* in an animal model of type 1 diabetes mellitus. *J Ethnopharmacol*, 2004; 91: 309–16
- Huseini HF, Larijani B, Heshmat R et al: The efficacy of *Silybum marianum* (L.) Gaertn. (silymarin) in the treatment of type II diabetes: A randomized, double-blind, placebo-controlled, clinical trial. *Phytother Res*, 2006; 20: 1036–39