



Broncholithiasis associated with lower airway inflammation and subsequent pyothorax in a cat

Ferran Valls Sanchez^{1*}, Jennifer Stewart², Catherine Bovens^{1†} and Jordi Puig^{1‡}

Journal of Feline Medicine and Surgery Open Reports
1–6

© The Author(s) 2017

Reprints and permissions:

sagepub.co.uk/journalsPermissions.nav

DOI: 10.1177/2055116917746798

journals.sagepub.com/home/jfmsopenreports

This paper was handled and processed by the European Editorial Office (ISFM) for publication in *JFMS Open Reports*



Abstract

Case summary A 12-year-old female spayed domestic shorthair cat presented with history of a long-term chronic cough that had worsened during the previous 2 months. Thoracic radiographs revealed numerous mineral opacities throughout the lung fields. Multiple bronchial plugs of pale yellow material were present on bronchoscopy, consistent with broncholithiasis. Bronchoalveolar lavage cytology revealed a mild neutrophilic inflammation and bacterial culture was negative. The cat was diagnosed with chronic inflammatory lower airway disease and broncholithiasis, suspected to be due to mineralisation of secretions in the bronchial lumen. The cat was treated for 6 years with oral prednisolone and responded well to treatment. Six years later, the cat developed severe respiratory distress and died. Post-mortem examination identified chronic multifocal broncholithiasis, pulmonary abscessation and pyothorax.

Relevance and novel information Broncholithiasis is a very rare condition in feline medicine; however, we are reporting a new case and it should be considered as a differential diagnosis for chronic coughing in cats, especially when other common causes have been ruled out and the radiographic findings are suggestive of it. We hypothesise that pathogenesis of the pulmonary abscessation and pyothorax in our patient was, at least partially, due to broncholithiasis. Pleural disease should be considered a complication of broncholithiasis.

Accepted: 11 November 2017

Introduction

Broncholithiasis is defined as the presence of calcified or ossified material within the bronchial lumen.^{1,2} In humans, it is a rare disorder with an incidence of 0.1–0.2% of all lung diseases.³ To the authors' knowledge, only four cases of broncholithiasis in cats have been reported in the veterinary literature.^{4–7} This condition is not reported in dogs. This case report describes a new case of feline broncholithiasis (including the first report of bronchoscopic appearance of the bronchololiths), its long-term outcome and its association with pleural disease.

Case description

A 12-year-old female neutered domestic shorthair cat was referred to the Animal Health Trust for a worsening cough over the past 2 months. The cat was vaccinated yearly (for feline calicivirus, feline herpesvirus, feline panleukopaemia and feline leukaemia), was wormed regularly (praziquantel + emodepside) and was an outdoor cat.

On presentation, physical examination demonstrated a mild tachypnoea (respiratory rate was 48 breaths per minute) with a normal respiratory pattern and mild inspiratory wheezes on pulmonary auscultation. Haematology and biochemistry were unremarkable. Thoracic radiographs revealed the presence of numerous clusters of cauliflower-like, mineral opacity structures of 3–6 mm diameter throughout the lung fields affecting all

¹Department of Small Animal Internal Medicine, UK

²Department of Pathology, Animal Health Trust, Kentford, UK

*Current address: Dick White Referrals, Cambridgeshire, UK

†Current address: Veterinary Referral Hospital, Princes Highway, Australia

‡Current address: Hospital Ars Veterinaria, Barcelona, Spain

Corresponding author:

Ferran Valls Sanchez DVM, Dick White Referrals, Station Farm, London Road, Six Mile Bottom, Cambridgeshire CB8 0UH, UK
Email: fvs@dwr.co.uk



Creative Commons Non Commercial CC BY-NC: This article is distributed under the terms of the Creative Commons

Attribution-NonCommercial 4.0 License (<http://www.creativecommons.org/licenses/by-nc/4.0/>) which permits non-commercial use, reproduction and distribution of the work without further permission provided the original work is attributed as specified on the SAGE and Open Access pages (<https://us.sagepub.com/en-us/nam/open-access-at-sage>).

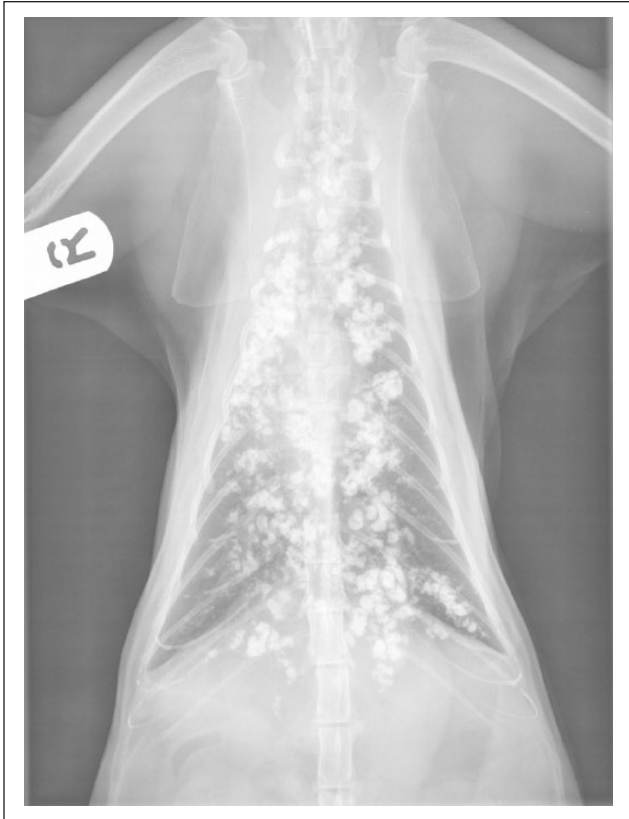

Figure 1 Ventrodorsal radiograph of the thorax. Numerous irregular mineral opacities of 3–6 mm diameter were present throughout the lung fields

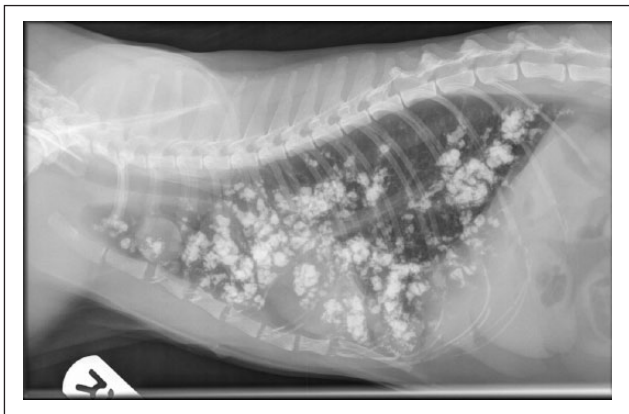

Figure 2 Lateral radiograph of the thorax. Numerous irregular mineral opacities of 3–6 mm diameter were present throughout the lung fields

pulmonary lobes but more severe in the right cranial and middle lung lobes (Figures 1 and 2). Differential diagnoses were mucous gland calcifications, dystrophic calcifications, inhaled mineral foreign bodies, broncholithiasis, neoplasia, hypervitaminosis D or granulomatous disease. Thoracic radiographs also showed a 1.7 cm diameter

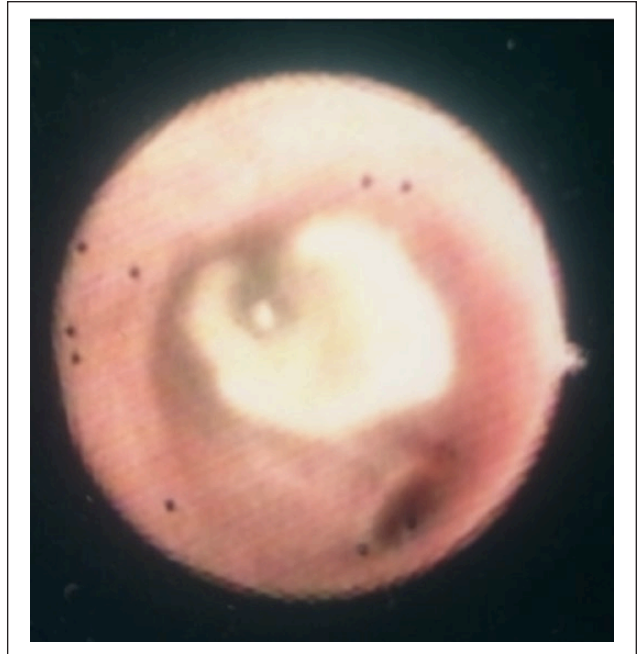


Figure 3 Bronchoscopic image showing light yellow solid material obstructing most of the lumen of a bronchus

soft tissue circular nodule in the cranial thorax and a 2 cm soft tissue nodule cranial to the cardiac silhouette. Thoracic ultrasound revealed a 1.3 cm diameter nodule, heterogeneous nodule in the left cranial lung field, consistent with one of the soft tissue nodules. The other nodule seen on radiography could not be seen on ultrasonography. On bronchoscopy, the interbronchial septae appeared rounded and the mucosa was diffusely erythematous. An excessive amount of mucus was present in the lower airways. Light yellow plugs of solid material were present in numerous bronchi, either partially or completely obstructing their lumen, depending on the case, consistent with broncholithiasis (Figures 3 and 4). Mineral material was not retrieved during bronchoalveolar lavage (BAL). BAL cytology revealed moderate cellularity with mild neutrophilic inflammation (red blood cells: 30/ μ l; nucleated cells: 230/ μ l). Microorganisms were not seen on cytology, and a Ziehl–Neelsen stain was negative. Bacterial aerobic and anaerobic cultures were negative. Investigations were consistent with feline inflammatory lower airway disease and multifocal broncholithiasis.

During the bronchoscopy, an iatrogenic pneumothorax developed as a result of perforation of an airway. It was drained immediately and a unilateral small-bore wire guided thoracostomy tube was placed. The cat was treated with amoxicillin/clavulanate (20 mg/kg IV q8h) and dexamethasone (0.1 mg/kg IV once), followed by prednisolone (0.5 mg/kg PO q12h) as feline inflammatory lower airway disease was suspected and this was the standard therapeutic approach

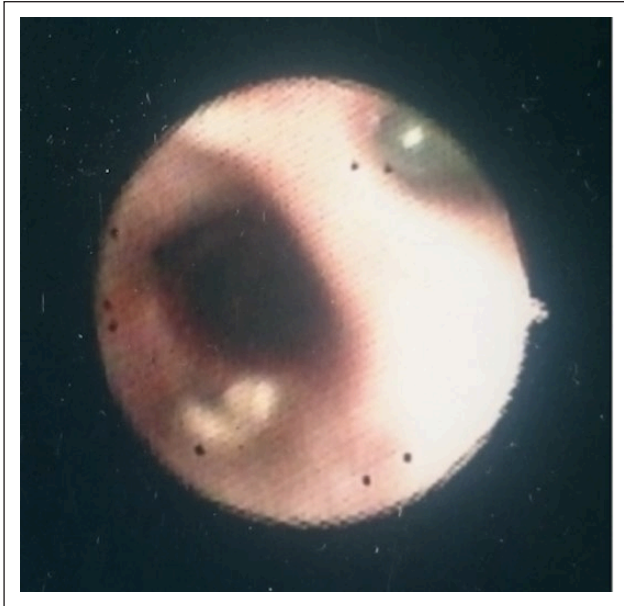


Figure 4 Bronchoscopic image showing the presence of pale yellow material in the lumen of a bronchus

of this condition by the clinical team involved. The cat was initially started on antibiotics while waiting for the results of the BAL and kept on them as a preventive measure because of the iatrogenic pneumothorax and risk of secondary pleural infection and ongoing clinical improvement. The thoracic drain was removed 3 days after placement. The cat was discharged 6 days after presentation with amoxicillin/clavulanate (20 mg/kg PO q12h) for a further 2 weeks, prednisolone (0.5 mg/kg PO q12h) and nebulisations with isotonic sterile saline for 5–10 mins q8h.

The cat was managed at the first-opinion veterinary practice for the following 6 years. According to the first-opinion practice, the cat was reported to have received prednisolone at a dose of 0.34 mg/kg PO q12–24h during the 6 years, depending on the severity and frequency of the coughing, and was asymptomatic on this dose. Further tapering of the prednisolone dose was attempted but resulted in relapse of dyspnoea. An episode of tachypnoea occurred 5 years after referral, at which time a right-sided grade III/VI systolic heart murmur was reported by the primary practice. No diagnostic investigations were performed at that stage and the cat was started on furosemide (1.7 mg/kg PO q12h) and benazepril (0.8 mg/kg PO q24h).

The cat presented with acute respiratory distress to the first-opinion practice 6 years after the initial diagnosis. It was treated with oxygen therapy, intravenous furosemide and dexamethasone. There was a clinical improvement and the cat was discharged on oral furosemide (1.6 mg/kg PO q12h) and telmisartan (dose for a 3 kg cat). It died at home 24 h later.

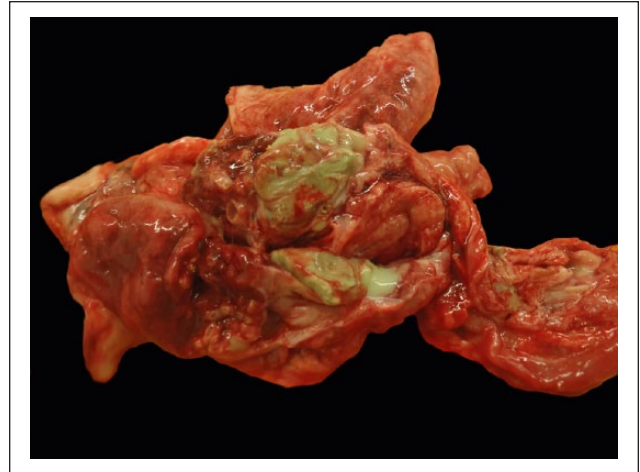


Figure 5 Macroscopic appearance of the lungs. Accumulations of yellow-green, thick, pasty pus are expanding multiple bronchioles

Post-mortem examination was performed at the Animal Health Trust. At gross necropsy, the thoracic cavity was filled with 50 ml watery-grey turbid fluid and the pleural surface of the ribs had multiple slightly raised, 2 mm white lesions. The lungs had an irregular nodular appearance. The nodules were up to 7–10 mm in diameter, and many contained light-green purulent material on cut surface (Figure 5). The heart showed mild left ventricular hypertrophy. The remaining organs were macroscopically normal. Cytology of the pleural fluid and suspected pulmonary abscessation revealed neutrophilic inflammation with intracellular bacteria. Neither bacterial culture nor special stains of these samples were performed.

Histology identified numerous bronchi and bronchioli severely distended by large quantities of calcified proteinaceous material, with mucus and neutrophils also present within the lumen. A von Kossa stain of the lumen contents was positive, confirming calcification (Figure 6). No bacteria were seen. Severe hyperplasia and hypertrophy of the peribronchiolar mucous glands were present. The histopathologic diagnosis was chronic purulent bronchitis and bronchiolitis with pulmonary abscessation, severe chronic bronchiectasis and moderate miliary bronchiolitis, and secondary pyothorax and pleuritis.

Discussion

The pathogenesis of feline bronchiolithiasis has not been determined. The most common aetiology in humans is granulomatous lymphadenitis (most commonly due to fungal infection in the US and mycobacterial infection in the rest of the world), with erosion of the bronchus by a calcified lymph node which then extrudes into the lumen.^{1–3,8} Chronic pneumonia by *Mycobacterium*

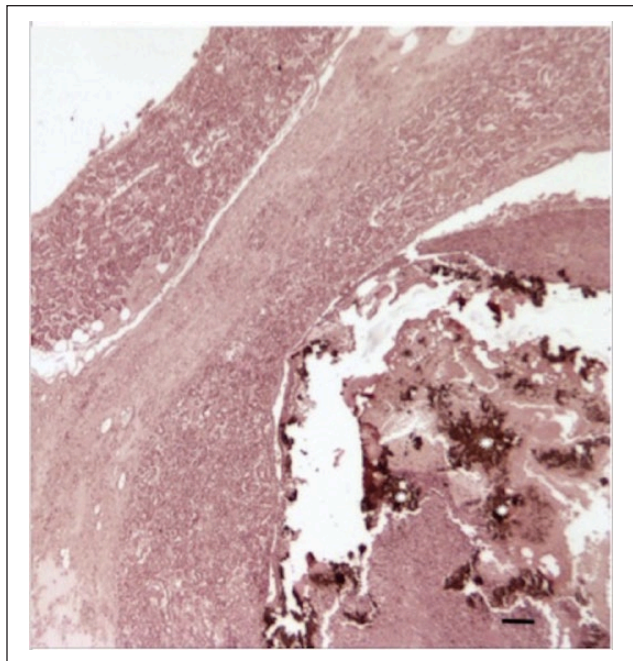


Figure 6 Von Kossa stain. Histology of lung sample. Intraluminal brown–black concretions, confirming the presence of mineralised material. Bar = 10 µm

thermoresistibile has been associated with pulmonary mineralization in a cat.⁹ Other causes include silicosis, aspiration of mineral material, in situ calcification of mucus or aspirated foreign material or erosion/extrusion of calcified bronchial cartilage plates.^{1–3}

There was no evidence of a bacterial airway infection in our case or most of the previously reported feline cases; however, an infectious agent could have played a trigger role for chronic inflammation in two reported cases.^{9,10} BAL bacterial culture was negative in our case and two other cases.⁶ In our case, an underlying mycobacterial infection was considered unlikely considering the clinical presentation and negative Ziehl–Neelsen stain on BAL sample cytology at initial diagnosis; however, the sensitivity of this test can be low and one of the limitations of this case report is that no other tests were performed to rule this condition completely out. Fungal infection was considered unlikely in the absence of fungal organisms on cytology and because pulmonary fungal infections are very rare in the UK. The appearance of the intraluminal material on bronchoscopy and on post-mortem examination results did not support foreign body inhalation.

A common feature in all the feline reported cases has been the presence of multiple bronchololiths, whereas in human medicine the number of bronchololiths is smaller and the disease is localised. This might be because in cats a generalised lower airway disease is causing the bronchololithiasis, contrary to a local injury as in humans.

In the previously reported cases of bronchololithiasis in cats, mineralisation of inspissated bronchial secretions was considered the likely cause for the bronchololiths.^{4–6} We suspect that this was also the cause for the bronchololithiasis in our case. Histopathology revealed hyperplasia and hypertrophy of the peribronchiolar mucous glands in our case and the two other cases in which histopathology was performed.^{4,5} This would have predisposed to the production of excessive secretion in the airways and supports the aforementioned theory. Intraluminal material (along with bronchololiths) of a different nature was described histologically in our case and two of the previously reported cases.^{4,5} In two cases where a CT scan of the thorax was performed, the bronchololiths were embedded in soft tissue density material in the bronchial lumen.⁷ Hyperplasia and hypertrophy of the bronchial mucous glands is a non-specific response to injury, and may be initially triggered by an inflammatory or infectious event and the excessive production of airway mucus become self-perpetuating.⁵ In the present case, feline inflammatory lower airway disease may have caused the excessive production of mucus in the lower airways, which could have undergone a process of mineralisation and consequent formation of bronchololiths. Miliary bronchololithiasis has been associated with chronic and progressive feline lower airway respiratory disease in a cat, which was initially diagnosed with *Mycoplasma* species infection and had no radiographic evidence of this bronchololithiasis.¹⁰ Inflammation without evidence of infection was also present in two other reported cases.^{4,6} Based on our case and those reports, the presence of bronchololithiasis in a cat may suggest the presence of lower airway inflammation, and investigation for this would be recommended.

In our case, bronchololithiasis was radiographically suspected and diagnosed in the light of the presence of intraluminal plugs of yellow, solid material in multiple bronchi on bronchoscopy, consistent with bronchololiths. Our case describes the first reported bronchoscopy in a cat with bronchololithiasis. In human medicine, a thoracic CT scan or bronchoscopy are required to confirm bronchololithiasis.^{1,3} In humans, bronchoscopy has a low sensitivity of 50%;^{1,2} however, the likelihood of visualising bronchololiths may be higher in cats as they appear to have more diffuse disease with multiple bronchololiths. The exact chemical composition of the bronchololiths was not determined, but the von Kossa stain of the material in the bronchial lumen confirmed that the suspected bronchololith contained calcified material.

Therapeutic options in affected humans include monitoring and conservative management, bronchoscopic removal of bronchololiths or surgery.^{1–3} Conservative management and monitoring can be recommended in asymptomatic patients.^{1,6} In our cat, bronchoscopic or surgical removal of the bronchololiths was considered not

feasible because of the large number and diffuse distribution of the bronchololiths. The optimal treatment for broncholithiasis in cats remains unknown. If the broncholithiasis is suspected to be secondary to feline lower airway inflammation, treatment for this condition is recommended. Long-term treatment with steroids is frequently needed in these patients.¹¹ Long-term treatment with inhaled steroids such as fluticasone has been reported as effective in cats with inflammatory lower airway disease.¹¹ However, at the time of the presentation, the use of inhaled corticosteroids was not as widespread as it is currently and, furthermore, it was hypothesised by the clinical team that the efficacy of inhaled steroids may be impaired in cats with broncholithiasis as physical obstruction of the lumen by the bronchololiths may impair complete delivery of inhaled drugs. Systemic treatment was therefore elected for in the present case. However, current published data has reported the long-term treatment with inhalations of fluticasone and salbutamol to be successful in one case of broncholithiasis, with no clinical signs for 3 years.⁷

Potential complications of broncholithiasis described in human medicine are recurrent infections, haemoptysis, bronchiectasis and bronchial fistulas.^{2,3,8} In our case, reported complications were iatrogenic pneumothorax, development of pulmonary abscessation and pyothorax. The cat in this report may have been predisposed to the development of an iatrogenic pneumothorax during bronchoscopy due to inflamed or more rigid lower airway walls¹² or, this may be a genuine iatrogenic damage. Pneumothorax is considered a possible complication of a bronchoscopy and it was reported to occur in 3% of cats undergoing a bronchoscopy according to one study.¹³ In our patient, post-mortem findings revealed a pyothorax, most likely secondary to pulmonary abscessation. We suspect that the pulmonary abscessation could have been due to the large number of bronchololiths. A predisposition to infection may be possible due to the bronchololiths acting as a nidus for bacteria. A similar case has been reported in a human patient suffering from broncholithiasis, who developed a secondary intraparenchymal pulmonary abscess associated with *Histoplasma capsulatum* and pyothorax.¹⁴ Investigation for possible respiratory or pleural infections would be recommended in cats with broncholithiasis with clinical deterioration. However, in the present case, the chronic administration of corticosteroids could also have played a role and predisposed the patient to secondary infections.

Regarding the prognosis, the first reported cat with broncholithiasis was euthanased within 12 months of diagnosis due to worsening respiratory signs.⁴ The second reported cat was euthanased owing to an unrelated condition 3 years following diagnosis; the cat was treated initially with doxycycline and prednisolone but only

received intermittent terbutaline after that and no other treatments.⁵ Two other reported cats were alive 3 and 4 years after initial diagnosis, respectively, and were treated long-term with inhalations of salbutamol and fluticasone.⁷ In the present case, the cat remained asymptomatic on oral prednisolone for 6 years after the initial diagnosis of broncholithiasis.

Conclusions

Broncholithiasis is an uncommon condition, which should be considered as a differential diagnosis for cats with chronic respiratory disease. Affected cats may develop broncholithiasis secondary to a diffuse inflammatory lower airway disease with mineralisation of secretions in the airways. Consequently, investigation for underlying lower airway inflammation is recommended. The optimal treatment of broncholithiasis in cats is unknown but may involve treatment for underlying airway inflammation if present. Local treatment (endoscopic or surgical removal) in the absence of available data, seems unlikely to be indicated because of the diffuse distribution of the disease in cats; however, further research is necessary in that regard. Iatrogenic pneumothorax (while performing the bronchoscopy), secondary pulmonary abscessation and pyothorax are possible complications of the disease, but good long-term prognosis is possible.

Conflict of interest The authors declared no potential conflicts of interest with respect to the research, authorship, and/or publication of this article.

Funding The authors received no financial support for the research, authorship, and/or publication of this article.

References

- 1 Seo JB, Song KS, Lee JS, et al. **Broncholithiasis: review of the causes with radiologic-pathologic correlation.** *Radiographics* 2002; 22: S199–S213.
- 2 Lim SY, Lee KJ, Jeon K, et al. **Classification of bronchololiths and clinical outcomes.** *Respirology* 2013; 18: 637–642.
- 3 Anwer M and Venkatram S. **Broncholithiasis: ‘incidental finding during bronchoscopy’ – case report and review of the literature.** *J Bronchol Intervent Pulmonol* 2011; 18: 181–183.
- 4 Allan GS and Howlett CR. **Miliary bronchiolithiasis in a cat.** *J Am Vet Med Assoc* 1973; 162: 214–216.
- 5 Brummer DG. **Microlithiasis associated with chronic bronchopneumonia in a cat.** *J Am Vet Med Assoc* 1989; 194: 1061–1064.
- 6 Talavera J, Fernandez del Palacio MJ, Bayon A, et al. **Broncholithiasis in a cat: clinical findings, long-term evolution and histopathological features.** *J Feline Med Surg* 2008; 1: 95–101.
- 7 Byrne P, Berman JS, Allan GS, et al. **CT findings in two cats with broncholithiasis.** *JFMS Open Rep* 2016; 2: 1–6.

- 8 Ungprasert P, Srivali N, Bauer MA, et al. **Broncholithiasis: an uncommon cause of chronic cough.** *J Bronchol Intervent Pulmonol* 2014; 21: 102–103.
- 9 Foster SF, Martin P, Davis W, et al. **Chronic pneumonia caused by *Mycobacterium thermoresistibile* in a cat.** *J Small Anim Pract* 1999; 40: 433–438.
- 10 Baral RM. **Lower respiratory tract diseases.** In: Little SE (ed). *The cat, clinical medicine and management.* St Louis, MO: Elsevier, 2010, pp 861–891.
- 11 Padrid P. **Chronic bronchitis and asthma in cats.** In: Bonagura JD and Twedt DC (eds). *Kirk's current veterinary therapy XV.* St Louis, MO: Elsevier, 2014, pp 673–680.
- 12 Mooney ET, Rozansky EA and King RGP. **Spontaneous pneumothorax in 35 cats (2001–2010).** *J Feline Med Surg* 2012; 14: 384–391.
- 13 Johnson LR and Drazenovich TL. **Flexible bronchoscopy and bronchoalveolar lavage in 68 cats (2001–2006).** *J Vet Intern Med* 2007; 21: 219–225.
- 14 Summers SM. **Broncholithiasis with post-obstructive pneumonia and empyema.** *J Emerg Med* 2013; 45: 612–614.