



Since January 2020 Elsevier has created a COVID-19 resource centre with free information in English and Mandarin on the novel coronavirus COVID-19. The COVID-19 resource centre is hosted on Elsevier Connect, the company's public news and information website.

Elsevier hereby grants permission to make all its COVID-19-related research that is available on the COVID-19 resource centre - including this research content - immediately available in PubMed Central and other publicly funded repositories, such as the WHO COVID database with rights for unrestricted research re-use and analyses in any form or by any means with acknowledgement of the original source. These permissions are granted for free by Elsevier for as long as the COVID-19 resource centre remains active.



LETTER TO THE EDITOR

The unfriendly side of “happy hypoxaemia”: Sudden cardiac death



A 31 year-old female patient was admitted to our dedicated COVID-19 Intensive Care Unit with hypoxaemic respiratory insufficiency due to COVID-19 pneumonitis. Her past medical history was unremarkable, except for extreme obesity (BMI 70.3). She was not taking any medications, and was not under any regular medical care. Her chest X-ray at admission showed bilateral interstitial pulmonary consolidations (Fig. 1A). At admission, our patient was tachypneic, with a respiratory rate of 30-40/min, with SpO₂ 85% to 90% while on a non-rebreather mask. We started our patient on dexamethasone, tocilizumab and enoxaparin in a therapeutic dose. Oxygenation improved markedly upon initiation of non-invasive ventilation (NIV) through a mask interface (IPAP 12 cmH₂O, EPAP 10 cmH₂O, FiO₂ started at 100% and titrated to SpO₂). Initially, while on NIV, she maintained SpO₂ > 90%, with FiO₂ of 60-80%, whereas saturations would drop within minutes while on a non-rebreather mask (15L / min), during attempted breaks from NIV. We did not offer high-flow nasal cannula (HFNC) oxygen therapy, partially because of its excessively high oxygen consumption, which presented logistical barriers in our resource-limited setting during a pandemic. Furthermore, we expected “true” positive pressure ventilation to have more beneficial effects on obesity-related, position-dependent atelectasis, and on a potentially present obstructive sleep apnea. Over the first week of admission, she developed progressive hypoxaemia, while denying dyspnoea. Our patient repeatedly refused intubation and invasive ventilation, citing a lack of symptoms, and a fear for a worse outcome with mechanical ventilation. On day three, the patient desaturated to S_pO₂ of about 50% (despite FiO₂100%), while denying dyspnoea, and without exhibiting tachypnea. Following prone positioning, saturations recovered to above 90%. Intermittent awake proning was, from that moment on, continued three times daily. On day seven, S_pO₂ again dropped to 30-55%, from then on never exceeding 60%, and at times reaching levels as low as 21%, with no further response to prone positioning. Changes in ventilatory settings (EPAP as low as 6 and up to 14cmH₂O; as CPAP, or with pressure support of up to 6 cmH₂O; FiO₂ from here on never below 100%) yielded no improvement in respiratory parameters. An arterial line was placed in the

left brachial artery, to allow for regular blood sampling. Arterial blood was extremely dark (Fig. 1B), with a P_aO₂ of 28mmHg. Accidental venous sampling was excluded with an adequate arterial blood pressure waveform. There was no methemoglobinaemia. Meanwhile, our patient was able to speak coherent, full sentences, and denied having any sensation of dyspnoea, although she was at times tachypneic. She remained firm in her view, and persistently refused endotracheal intubation. After enduring extreme hypoxaemia for about two days in a seemingly stable condition, she suddenly developed ventricular fibrillation, rapidly followed by asystole and death. Resuscitative efforts were not successful.

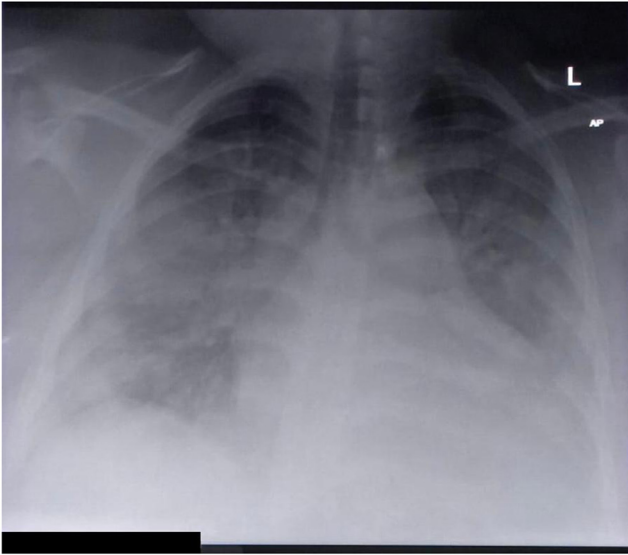
Silent, or “happy” hypoxaemia is a well-known phenomenon in COVID-19.^{1,2} Several theories have been proposed for its existence, most revolving around intrapulmonary shunting as the primary driver of hypoxaemia, with relative preservation of lung compliance in the early stages of the disease,³ and resultant normocarbia or even hypocarbia,⁴ although a neural factor has also been proposed.⁵ In our case, we think a certain level of hypoxaemia at baseline associated with previously undiagnosed, but potentially present obesity hypoventilation syndrome may have contributed to our patient’s tolerance of extremely low arterial oxygen levels.

The optimal timing of intubation in severe COVID-19 remains controversial. Early on in the pandemic, prominent authors urged clinicians to intubate early, in order to prevent patient self-induced lung injury (P-SILI), which was hypothesised to result from excessive respiratory effort.⁶ Furthermore, non-invasive respiratory support was feared to lead to droplet formation, putting health-care workers at risk.⁷ Conversely, it has been argued that early, potentially unnecessary intubation may increase mortality by exposing patients to the risks of sedation and invasive ventilation.⁸ As the pandemic progressed, many clinicians adopted a “wait-and-see” strategy, where patients are initially managed with non-invasive ventilatory support (including NIV and HFNC), and are intubated only upon failure of such therapies.⁹ More recent studies yield conflicting results, and although non-invasive respiratory support appears safe, and has been shown to reduce the need for invasive ventilation, the optimum timing of intubation in COVID-19 is as of yet still unknown.¹⁰ It may be reasonable to use a step-up approach, starting HFNC in patients who fail conventional oxygen therapy, failure of which could be followed by a trial of CPAP, and eventually, if indicated, intubation.¹¹

<https://doi.org/10.1016/j.pulmoe.2022.05.004>

2531-0437/© 2022 Sociedade Portuguesa de Pneumologia. Published by Elsevier España, S.L.U. This is an open access article under the CC BY-NC-ND license (<http://creativecommons.org/licenses/by-nc-nd/4.0/>).

a



b




Fig. 1 (A) Chest X-ray taken in a patient with severe COVID-19, showing extensive bilateral opacities, with a slight predominance for the peripheral and basal lung fields. **(B)** Arterial blood sample, drawn from a patient with COVID-19 receiving non-invasive ventilation (EPAP 12; Pressure Support 4; FiO₂ 100%). Blood gas analysis revealed a P_aO₂ of 28mmHg (P/F ratio 28mmHg). Despite oxygen saturations below 40%, the patient denied dyspnoea and did not have elevated work of breathing.

To aid in deciding whom to intubate, authors have proposed using the ROX index,¹² which, in several retrospective series, has been reported to predict failure of non-invasive respiratory support in COVID-19.^{12,13} While most studies were performed in cohorts treated with HFNC, the ROX index has been reported to correlate with outcomes after CPAP as well.¹⁴ It should be noted that different studies report different cut-offs (such as <3.85¹² and <5.99¹³). Our patient had ROX-indexes as low as 1.12, clearly indicating a high risk of treatment failure.

The phenomenon of seemingly well-tolerated hypoxaemia in COVID-19 has led to further controversy, as it seems counter-intuitive to intubate a patient who, despite having low oxygen saturations, is feeling well. This discrepancy between subjective and objective findings has led some authors to argue that such patients should not be intubated, as long as they remain asymptomatic, and do not exhibit increased work of breathing.¹⁵ Even though we are inclined to agree with this concept in general, as long as hypoxaemia is mild to moderate, we believe our case demonstrates the dangers when such an approach is taken to the extreme. There is a point where hypoxaemia can lead to rapid cardiovascular decompensation,² where “happy” hypoxaemia can show its unfriendly side: sudden cardiac death.

Funding

The authors declare that no external funding was received for the conduct of this study and/or the preparation of this manuscript.

Conflicts of interest

The authors have no conflicts of interest to declare.

References

1. Tobin MJ, Laghi F, Jubran A. Why COVID-19 silent hypoxemia is baffling to physicians. *Am J Respir Crit Care Med.* 2020;202:356–60.
2. Tobin MJ. Basing respiratory management of COVID-19 on physiological principles. *Am J Respir Crit Care Med.* 2020;201:1319–20.
3. Haryalchi K, Heidarzadeh A, Abedinzade M, Olangian-Tehrani S, Ghazanfar Tehran S. The importance of happy Hypoxemia in COVID-19. *Anesth Pain Med.* 2021;11:e111872.
4. Bickler PE, Feiner JR, Lipnick MS, McKleroy W. “Silent” presentation of hypoxemia and cardiorespiratory compensation in COVID-19. *Anesthesiology.* 2021;134:262–9.
5. Rahman A, Tabassum T, Araf Y, Al Nahid A, Ullah MA, Hosen MJ. Silent hypoxia in COVID-19: pathomechanism and possible management strategy. *Mol Biol Rep.* 2021;48:3863–9.
6. Marini JJ, Gattinoni L. Management of COVID-19 respiratory distress. *JAMA.* 2020;323:2329–30.
7. Crimi C, Noto A, Cortegiani A, et al. Noninvasive respiratory support in acute hypoxemic respiratory failure associated with COVID-19 and other viral infections. *Minerva Anestesiol.* 2020;86:1190–204.
8. Tobin MJ, Laghi F, Jubran A. Caution about early intubation and mechanical ventilation in COVID-19. *Ann Intensive Care.* 2020;10. 78-020-00692-6.

9. Papoutsis E, Giannakoulis VG, Xourgia E, Routsis C, Kotanidou A, Siempos II. Effect of timing of intubation on clinical outcomes of critically ill patients with COVID-19: a systematic review and meta-analysis of non-randomized cohort studies. *Crit Care*. 2021;25. 121-021-03540-6.
10. Weerakkody S, Arina P, Glenister J, et al. Non-invasive respiratory support in the management of acute COVID-19 pneumonia: considerations for clinical practice and priorities for research. *Lancet Respir Med*. 2022;10:199–213.
11. Winck JC, Scala R. Non-invasive respiratory support paths in hospitalized patients with COVID-19: proposal of an algorithm. *Pulmonology*. 2021;27:305–12.
12. Myers LC, Mark D, Ley B, et al. Validation of respiratory rate-oxygenation index in patients with COVID-19-related respiratory failure. *Crit Care Med*. 2022.
13. Vega ML, Dongilli R, Olaizola G, et al. COVID-19 Pneumonia and ROX index: Time to set a new threshold for patients admitted outside the ICU. *Pulmonology*. 2022;28:13–7.
14. De Vita N, Scotti L, Cammarota G, et al. Predictors of intubation in COVID-19 patients treated with out-of-ICU continuous positive airway pressure. *Pulmonology*. 2022;28(3):173–80.
15. Voshaar T, Stais P, Köhler D, Dellweg D. Conservative management of COVID-19 associated hypoxaemia. *ERJ Open Res*. 2021;7:00026–2021. eCollection 2021 Jan.

C.M.C. Serbanescu-Kele Apor de Zalán, MD ^{a,b,*}, R.P. Banwarie, MD ^{a,c}, K.D. Banwari, MD ^a, B.A. Panka, MD ^{a,c}

^a *Department of Internal Medicine and Intensive Care, s Lands Hospitaal, Paramaribo, Suriname*

^b *Department of Intensive Care, VieCuri Medical Center, Venlo, 5900 BX Venlo, the Netherlands*

^c *Department of Intensive Care, Academic Hospital Paramaribo, Paramaribo, Suriname*

* Corresponding author.

E-mail address: cserbanescu@viecuri.nl

(C.M. Serbanescu-Kele Apor de Zalán).

Received 3 February 2022; Accepted 28 May 2022

Available online 19 July 2022