

CASE REPORT

doi: 10.5455/medarch.2017.71.144-147

MED ARCH. 2017 APR; 71(2): 144-147

RECEIVED: JAN 25, 2017 | ACCEPTED: MAR 29, 2017

Genetic Counseling and Prenatal Diagnosis of Triploidy During the Second Trimester of Pregnancy

Milenko Kolarski¹, Begzudin Ahmetovic², Maja Beres², Radomir Topic², Vedran Nikic², Ivana Kavacan¹, Semin Sabic²

¹Institute for Child and Young Children Health Care of Vojvodina, Novi Sad, Serbia

²Department of Gynecology and Obstetrics, General Hospital Brcko District, Brcko, Bosnia and Herzegovina

Corresponding author: Begzudin Ahmetovic, MD.
Phone: +38761258389. E-mail: begzudin@hotmail.com, ORCID ID: 0000-0001-5028-226X

ABSTRACT

Introduction: Triploidy is a lethal chromosomal numeric abnormality, characterized on extra haploid set of chromosomes. It occurs in 2 to 3% of conceptuses and accounts for approximately 20% of chromosomally abnormal first-trimester miscarriages. As such, triploidy is estimated to occur in 1 of 3,500 pregnancies at 12 weeks', 1 in 30,000 at 16 weeks', and 1 in 250,000 at 20 weeks' gestation. **Case report:** We present a case of second-trimester triploidy diagnosed prenatally at our center. 28-years-old gravida with a first spontaneous pregnancy had early gestational hypertension. Ultrasound examination in 14^{6/7} weeks' gestation revealed asymmetric intrauterine growth retardation. We recommended biochemical maternal serum screening during second trimester of pregnancy (AFP, HCG, uE3). Result of biochemical screening was indication for cytogenetic analysis from amniotic fluid cells and we recommended early amniocentesis in 15^{6/7} weeks' gestation. Result showed abnormal karyotype of the fetus (69,XXX triploidy), and DNA analysis confirmed Type-2 Digyny. Parents decided to terminate this pregnancy, and it was done at 22 weeks' gestation. **Conclusion:** We emphasize the importance of non-invasive prenatal examinations-biochemical serum screening during second trimester of pregnancy, and ultrasound examinations in prenatal screening of syndrome Down and other chromosomal abnormalities.

Keywords: Prenatal diagnostics, biochemical screening, early amniocentesis, triploidy, 69,XXX.

1. INTRODUCTION

Triploidy is a rare lethal numeric chromosomal aberration caused by the presence of an extra haploid chromosome set. It occurs in about 17% of all spontaneous abortion during first trimester and occurring in up to 3% of recognized human conceptuses. The majority of fetuses with triploidy are spontaneously miscarried between 7th and 17th week of gestation (1, 2). This extra set of chromosomes is a cause of variety of serious birth defects, placental problems, hydatidiform molar findings, and severe growth problems in a fetus. Infants with this lethal condition are generally small due to severe intrauterine growth retardation (IUGR) and they have multiple birth defects, including facial abnormalities, micrognathia, cleft lip, heart defects, neural tube defects (spina bifida), and other serious birth defects of limb, kidney and umbilical cord. Anomaly also includes single umbilical artery (3, 4, 5). The low frequency of triploidy among advanced pregnancies has led to discrepancies in

prevalence estimates, ranging from as low as 1 in 250,000 at 20 weeks to as high as 1 in 50,000 among live-born infants (6, 7). It can be recurrent, and maternally derived cases appear to live longer than paternally derived cases. There are three different mechanisms that may produce triploidy: an extra haploid chromosome set can be paternal (diandric) or maternal (digynic) in origin (8). The majority of diandric triploids result from simultaneous fertilization by two sperm. Other triploidies of diandric origin arise from normal fertilization of the ovum by a diploid sperm, the result of complete non-disjunction during spermatogenesis. Triploidies of digynic origin result from fertilization of a primary oocyte or from fertilization of a diploid oocyte that is a product of nondisjunction during meiosis I, meiosis II, or retention of a polar body (9, 10).

This can result of two sperm fertilizing one normal egg, it can also occur if a normal sperm fertilizes an egg has an extra set of chromosomes (11).

© 2017 Milenko Kolarski, Begzudin Ahmetovic, Maja Beres, Radomir Topic, Vedran Nikic, Ivana Kavacan, Semin Sabic

This is an Open Access article distributed under the terms of the Creative Commons Attribution Non-Commercial License (<http://creativecommons.org/licenses/by-nc/4.0/>) which permits unrestricted non-commercial use, distribution, and reproduction in any medium, provided the original work is properly cited.

Cases of triploidy are grouped into two fetal and placental phenotypes that roughly correspond to the parental origin of the extra set of chromosomes (12):

Type I: well formed fetus with a normal or microcephalic head and a large placenta with cystic changes-associated with diandry;

Type II: fetus with growth restriction and a large head and a small, noncystic placenta-associated with digyny.

Genetic counseling and prenatal diagnostics of congenital anomalies is one of the most important improvements in preventive medicine in the last century in the world. Pregnant women were genetically advised and those women who had high risk for chromosomal aberration of the fetus, were recommended for early amniocentesis and chromosome analysis. Second trimester maternal serum alpha-fetoprotein (AFP), human chorionic gonadotropin (hCG), and unconjugated estriol (uE3) levels are evaluated in pregnancy in order to determine the risk of aneuploidy, trisomy 13,18,21 and polyploidy (13, 14).

Prenatal diagnostics by non-invasive testing (biochemical and ultrasound examinations) during first and second trimester pregnancies, give us most important data about genetic health of fetus (13). Prenatal diagnosis of Sy. Down and other aneuploidies and structural chromosomal aberrations is the most important goal.

Triploidy may be prenatally diagnosed through cytogenetic analysis of cells obtained through procedures such as amniocentesis. Fetal nuchal translucency in the first trimester is frequently increased in fetuses with triploidy (15, 16). It is also associated with elevated maternal serum alpha fetoprotein (AFP) and total and beta-human chorionic gonadotropin (hCG) levels and low maternal serum pregnancy-associated plasma protein-A (PAPP-A) levels in the first trimester (17,18). Fetal ultrasound examination during first and second trimester of gestation is most important, and gives support in discovery of chromosomal aberration of the fetus and congenital anomalies (19). Screening for Sy. Down includes measurement of nuchal translucency and nuchal fold skin thickens, identification of asymmetric IUGR and congenital anomaly of the fetus. (20, 21).

Here we present a case of prenatally diagnosed triploidy of fetus undergoing routinely amniocentesis, where indications for prenatal diagnosis were ultrasound findings and biochemical markers screened in the 14^{6/7} weeks' gestation. We discovered only one case of triploidy during 12 years.

2. PATIENT AND METHODS

We present prenatally diagnosed abnormal karyotype of fetus. It was polyploidy - 69, XXX triploidy Type 2 Digyny, discovered during second trimester of pregnancy. The patient was a 28-years-old woman with a spontaneous pregnancy referred to our institution at 14^{6/7} weeks' gestation after anatomy ultrasound examination revealed severe intrauterine growth restriction. Pregnancy complications included gestational hypertension.

Ultrasound examination revealed asymmetric intrauterine growth restriction. Ultrasound screen and re-

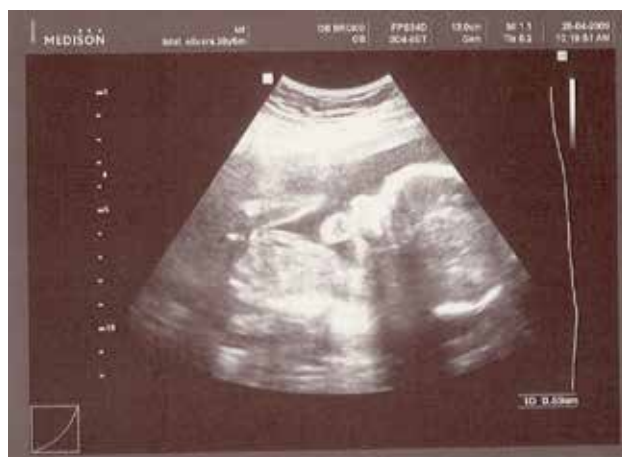

Figure 1. Ultrasound examination: asymmetric IUGR of the fetus and micrognathia

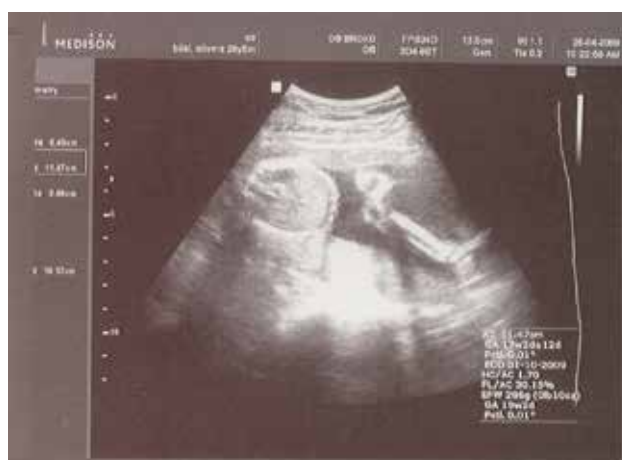

Figure 2. Ultrasound examination: gestational age 116/7 gw; FI/AC 0.30; asymmetric IUGR (3 weeks); normal ultrasound morphology of placental tissue and amniotic fluid

sult maternal biochemical serum screening (Triple test) during second trimester of pregnancy showed high risk of chromosomopathies and it was indication for cytogenetic analyses (early amniocentesis). Result of cytogenetic analysis of amniotic cells showed abnormal karyotype-triploidy and DNA (PCR) analysis discovered Type II (Digyny), with extra set of haploid chromosomes of maternal origin.

Ultrasound examination

Ultrasound examination revealed asymmetric intrauterine growth restriction (Figure 1). Gestational age according to last menstrual period was 14^{6/7}, but according to ultrasound finding (USGA) it was 11^{6/7} (CRL 47,0 mm; Nuchal translucency 1,7 mm–1,32 Mom, and IUGR 3 gw; Interorbital distance-11mm/18gw). Other abnormal ultrasound findings included micrognathia and single umbilical artery. Placental tissue had normal morphology and did not have trophoblastic tissue-molla (characteristics for triploidy Type 1, with extra set of haploid chromosomes of paternal origin). Amniotic fluid was normal and no other pathological ultrasound findings were found (Figure 2).

Biochemical findings

Result of biochemical analysis during the second trimester of pregnancy (alpha-fetoprotein 18,1-0,61 MoM

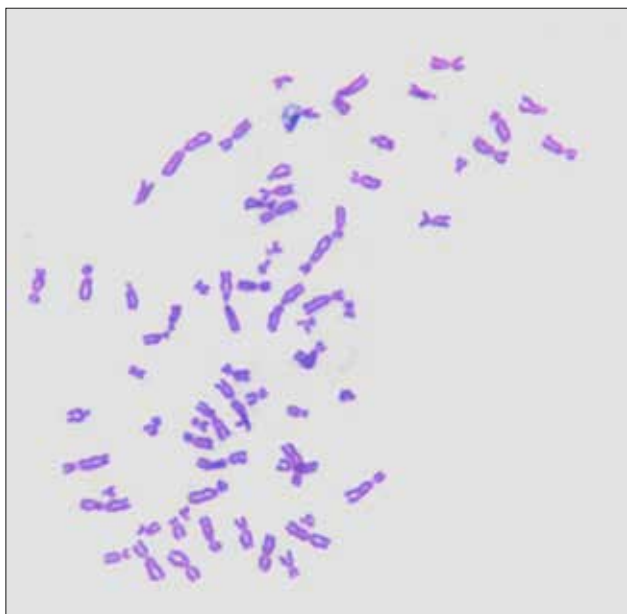


Figure 3. Karyotype of the fetus: Poliploidy-triploidy 69,XXX (karyotype from amniotic fluid)

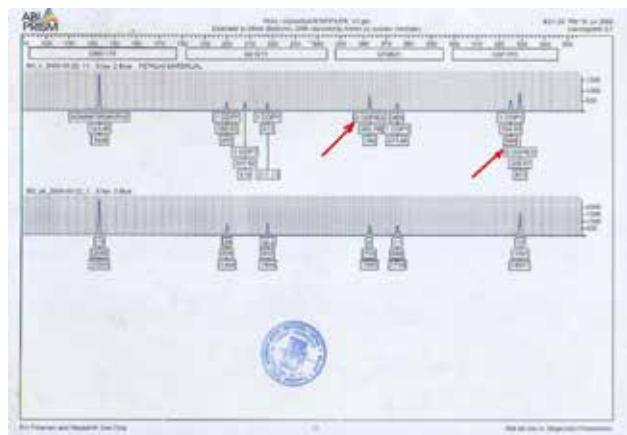


Figure 4. PCR - DNA analysis: Triploidy 69, XXX, Type-2 (Digyny)

low; human chorion gonadotropin-hCG 4630,0–0,14 MoM low; unconjugated estriol-uE3, 3,36 – 0,51 MoM low), did not show high risk of Syndrome Down (1:6241) but showed high risk of Syndrome Edwards (1:101) and triploidy 69 XXX.

Genetic counseling, cytogenetic analysis and DNA (PCR) analysis

Genetic counselor advised that cytogenetic analyses should be done. Results of cytogenetic analysis revealed numeric chromosomal aberrations (69, XXX-triploidy) (Figure 3) and PCR-DNA method showed type II-poliploidy (digyny), with extra haploid set of chromosomes of maternal origin (Figure 4).

Pathoanatomical examination of fetus after termination of pregnancy confirmed ultrasound pathological findings. No other pathological findings were found.

Chromosomal findings from amniotic fluid: Amniocytes were grown using standard method for harvesting of amniocytes: amniotic cell pellet was seeded into tissue flask containing Amniomax Complete II (Invitrogen-Gibco). After passaging cells into duplicate flask, colchicines were added for 3 hours afterwards pellet

was treated with hypotonic solution (0.56% KCl) for 15 minutes at 37°C, cells were collected by centrifugation, and fixed using Karnoy's fixative (methanol: acetic acid in the ratio 3:1). Fixed cells were spread onto clean slides, and stained with Giemsa. Metaphase analyses were carried out using microscope Zeiss, magnification 1400. Metaphases were recorded by CCD camera Axiocam 5. Classic and GTG banded chromosomes were analyzed. Analysis revealed karyotype 69,XXX.

Chromosomal findings in cordocentesis: 0.5ml of cord blood sample was put into medium PBmax karyotyping medium and harvested up to 72 hours. Metaphases were collected by adding colchicine for 3 hours. After standard preparation and fixation metaphase spreads were analyzed on Giemsa stained slides. In parallel to classical chromosomal analysis chromosomes were analyzed employing Giemsa-trypsin-Giemsa banding technique. Analysis revealed karyotype 69,XXX.

DNA analysis: DNA was isolated from amniocytes (duplicate culture), whereas sample of mother DNA was isolated from buccal cells. 14 markers were compared (TPOX, D18S51, D3S1358, THO1 vWA, D135317, D16S539, D2S13382, D2S1334, D165519, D138317, D138317, THO1-2, D351358). Results have shown that 2 markers were noninformative, whereas in other 12 doubled copies of maternal genetic material have been found in fetal tissue. The result of the DNA analysis have shown that triploidy is of maternal origin. This finding was in accordance to ultrasound observation and autopsy finding of placenta.

3. DISCUSSION

Triploidy is the third most frequent chromosomal anomaly and is responsible for 15-18% of spontaneous abortions. Only 1 in 1,200 triploid fetuses live after birth. The frequency of triploidy in live births is 1:10,000, and males represent 51-69 % of all cases (1, 6).

Two different mechanisms have been described that are responsible for triploidy. The extra-haploid set of chromosomes may be maternal (digynic triploids) or paternal (diandric triploids). Digynic triploidy may result from the fertilization of normal oocyte produced through an error at either the first or second meiotic division. Diandric triploidy may occur through fertilization of normal oocyte by a diploid sperm as a result of an error at either the first or second meiotic division or through fertilization of an oocyte by two sperms (dispermy) (8, 9). According to previous reports, 66.4% of triploid infants are due to dispermy, 23.6% due to a diploid sperm and 10% due to a diploid oocyte. Usually, the extra-haploid set of chromosomes has a paternal origin. Digynic embryos have a better chance to reach the second trimester of gestation or even to be born (10, 22).

The sex chromosomes in triploid individuals of maternal origin should be in 50% of the cases XXX and 50% XXY, and in those of paternal origin, 25% XXX, 50% XXY and 25% XYY. According to previous studies, the frequency of triploids is the following: 31-49% 69,XXX, 49-69% 69,XXY and 0,3% 69,XYY. The low frequency of the 69,XYY chromosomal aberration suggests that this

karyotype leads to low viability and early abortion of the zygote, otherwise the mechanism through which it occurs is very rare (7, 11, 12).

Many pregnancies were terminated by spontaneous abortion during the first trimester pregnancy, because had chromosomal aberration or congenital anomaly.

Some affected fetuses had chromosomal aberration and congenital anomaly but were not terminated by spontaneous abortion and we have to submit this pregnancies to prenatal diagnostics. Syndrome Edwards and triploidy have many similar biochemical and ultrasound findings and characteristics (20, 21, 22). We have to introduce cytogenetic and PCR-DNA analysis during diagnosis and these results give us more information about genetic health of the fetus and chromosomal aberration.

4. CONCLUSION

Frequency of chromosomopathies diagnosed by prenatal diagnostics in Brcko District is about 2% during 8 year period (2003-2011) and all pregnancies were terminated on request of pregnant women and approval of Ethical committee before 24 weeks' gestational age. We emphasize the importance of prenatal ultrasound and biochemical screening and testing during the first and second trimester. This case report highlights the importance of cytogenetic and PCR-DNA analysis in discovered congenital anomaly and chromosomal aberration of the fetus during the second trimester of pregnancy.

There are no risk factors. Triploidy is not more common in older mothers, like some other chromosomal abnormalities such as Sy. Down. Couples who have one pregnancy with triploidy do not have an increased risk in future pregnancies. Multidisciplinary approach of different specialists (gynecologist, genetic counselor, biologist, psychologist, social worker) is important for good results in early prenatal detection of chromosomopathies.

- Conflict of interest: none declared.

REFERENCES

- Gardner RJM, Sutherland GR, Schaffer LG. Chromosome Abnormalities and Genetic Counseling 4th ed. New York, NY: Oxford University Press, 2012.
- Huang T, Alermon E, Wald N, Summens AM. Triploidy identified through second-trimester serum screening. *Prenatal diagnosis*. 2005; 25: 229-33.
- Khong Ty, George K. Chromosomal abnormalities associated with a single umbilical artery. *Prenatal Diagnosis*. 1992; 12: 965-8.
- Hassold T, Chen N, Funkhouser J et al: A cytogenetic study of 1000 spontaneous abortions. *Ann Hum Genet*. 1980; 44: 151-78.
- Doshi N, Surti U, Szulman AE. Morphologic anomalies in triploid liveborn fetuses. *Hum Pathol*. 1983; 14: 716-23.
- Wick JB, Johnson KJ, O'Brien J, Wick MJ. Second-trimester diagnosis of triploidy: a series of four cases. *AJP Rep*. 2013; 3(1): 37-40.
- McFadden DE, Robinson WP. Phenotype of triploid embryos. *J Med Genet*. 2006.
- Brancati F, Mingarelli R, Dallapiccola B: Recurrent triploidy of maternal origin. *Eur J Hum Genet*. 2003; 11: 972-4.
- Baumer A, Balmer D, Binkert F, Schinzel A. Parental origin and mechanisms of formation of triploidy: a study of 25 cases. *Eur J Hum Genet*. 2000; 8: 911-7.
- McFadden DE, Langlois S. Parental and meiotic origin of triploidy in the embryonic and fetal periods. *Clin Genet*. 2000; 58: 192-200.
- Zaragoza MV, Surti U, Redline RW, Millie E, Chakravarti A, Hassold TJ. Parental origin and phenotype of triploidy in spontaneous abortions: predominance of diandry and association with the partial hydatidiform mole. *Am J Hum Genet*. 2000; 66:
- McFadden DE, Kalousek DK. Two different phenotypes of fetuses with chromosomal triploidy: correlation with parental origin of the extra haploid set. *Am J Med Genet*. 1991; 38: 535-8.
- Nicolaides KH, Wright D, Poon LC, Syngelaki A, Gil MM. First-trimester contingent screening for trisomy 21 by biomarkers and maternal blood cell-free DNA testing. *Ultrasound Obstet Gynecol*. 2013; 42(1): 41-50.
- Jauniaux E, Brown R, Sniijders RJ, Noble P, Nicolaides KH. Early prenatal diagnosis of triploidy. *Am J Obstet Gynecol* 1997; 176: 550-4.
- Sehnert AJ, Rava RP, Bianchi DW. A new era in noninvasive prenatal testing. *N Engl J Med*. 2013; 369(22): 2164-5.
- Norton ME, Rose NC, Benn P. Noninvasive prenatal testing for fetal aneuploidy: clinical assessment and a plea for restraint. *Obstet Gynecol*. 2013; 121(4): 847-50.
- American College of Obstetricians and Gynecologists Committee on Genetics Committee Opinion No 545: Noninvasive prenatal testing for fetal aneuploidy. *Obstet Gynecol*. 2012; 120(6): 1532-4.
- Larion S, Warsof SL, Romary L, Mlynarczyk M, Peleg D, Abuhamad AZ. Association of combined first-trimester screen and noninvasive prenatal testing on diagnostic procedures. *Obstet Gynecol*. 2014; 123(6): 1303-10.
- Benacerraf BR, Gelman R, Frigoletto. Sonographic identification of second trimester foetus with Down syndrome. *New England Journal of Medicine*. 1987; 317(22): 371-6.
- Agathokleous M, Chaveeva P, Poon LC, Kosinski P, Nicolaides KH. Meta-analysis of second-trimester markers for trisomy 21. *Ultrasound Obstet Gynecol*. 2013; 41: 247-61.
- Nicolaides KH. Screening for chromosomal defects. *Ultrasound Obstet Gynecol*. 2003; 21:313-21.
- Phillipp T, Grillenberger K, Separovic ER, Philipp K, Kalousek DK. Effects of triploidy on early human development. *Prenatal Diagnosis*. 2004; 24: 276-81.