

Intraoperative assessment of femoral head perfusion during surgical hip dislocation for slipped capital femoral epiphysis

Adrian Michalopoulos ^{1,*}, Christopher Spelman¹, Jitendra Balakumar^{1,2} and David Slattery¹

¹Department of Orthopaedics, Royal Children's Hospital, 50 Flemington Road Parkville, VIC 3052, Melbourne, Australia and

²Melbourne Orthopaedic Group, Orthopaedic Group, 33 The Avenue Windsor, VIC 3181, Melbourne, Australia.

*Correspondence to: A. Michalopoulos. E-mail: adrian.michalopoulos@gmail.com

Submitted 21 October 2020; Revised 2 March 2021; revised version accepted 11 March 2021

ABSTRACT

Avascular necrosis is the most devastating complication of slipped capital femoral epiphysis, leading to collapse of the femoral head, increased risk of osteoarthritis and the requirement of early total hip arthroplasty. It is believed that intraoperative femoral head perfusion assessment may be an accurate predictor of post-operative avascular necrosis (radiographic collapse). At our institution, femoral head perfusion is assessed intraoperatively during all sub-capital realignment procedures. We hypothesize that our method is accurate in predicting the risk of developing post-operative avascular necrosis. In this retrospective study, we collected data from all patients that had intraoperative blood flow measurements during sub-capital realignment procedures. We correlated this with long-term radiographs looking for radiographic collapse. The intraoperative femoral head perfusion assessments during sub-capital realignment procedures for slipped capital femoral epiphysis at our institution, between January 2015 and March 2020 inclusive were assessed for reliability. In total, 26 of 35 patients had intraoperative femoral head perfusion present. Only 2 (8%) of these patients developed radiographic collapse. In contrast, 7 (78%) of the 9 patients who did not have femoral head perfusion present intraoperatively developed radiographic collapse, indicating that our method may be reliable in predicting a patient's post-operative risk of developing avascular necrosis.

INTRODUCTION

Slipped capital femoral epiphysis (SCFE) is a condition that most commonly occurs in adolescents [1]. It is characterized by displacement of the femoral neck anterosuperior, resulting in a posteroinferior femoral head position relative to the neck. Multiple classification systems have been developed for the assessment of SCFEs. The Loder classification divides slips into stable or unstable based on the patient's ability to weight bear [2]. The Southwick classification classifies slip severity [3] and a chronological classification based on a patient's symptomatology are also utilized [4]. The strong correlation between Loder's classification of an unstable slip and femoral head avascular necrosis [5] guides surgical treatment and informs surgeons and patients of potential negative outcomes.

Avascular necrosis (AVN) is the most serious complication of SCFE, leading to collapse of the femoral head, increased risk of osteoarthritis and the requirement of early total hip arthroplasty [6]. The rate of AVN with unstable SCFEs has been described as high as 47% [2]. A more recent review article demonstrated the rate of AVN to be 23.9% in unstable SCFEs [5]. Stable SCFEs have a near 0% risk of AVN [7, 8] and are most commonly treated with *in situ* pinning [9]. The treatment of unstable SCFE is more controversial and many techniques have been described. These include *in situ* pinning [10], reduction with decompression arthroscopy and pinning [11], open reduction and pinning [12] and sub-capital realignment using the modified Dunn procedure [13].

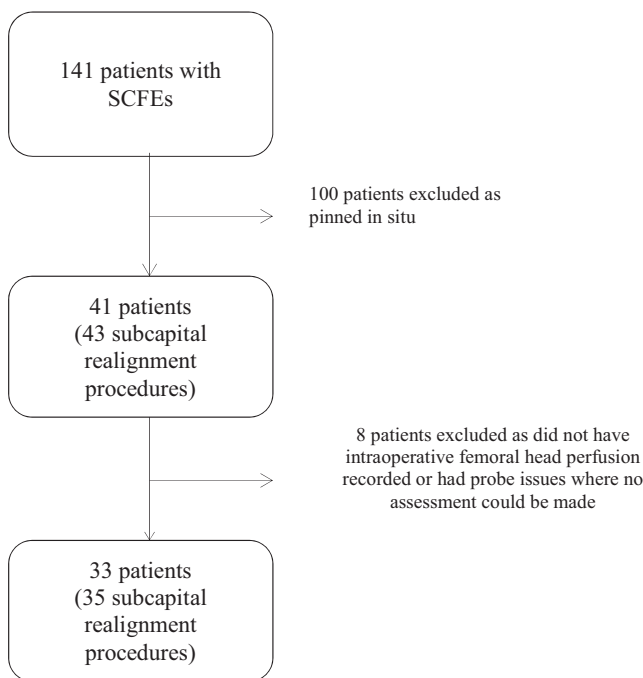
It is believed that intraoperative femoral head perfusion assessment may be an accurate predictor of post-operative

AVN. Intraoperative assessment of femoral head perfusion may allow for real-time adjustment of osteotomy and reduction in an attempt to restore perfusion and therefore decrease the risk of development of AVN. Multiple techniques of intraoperative assessment of femoral head perfusion have been described in the literature [14–20].

At our institution, femoral head perfusion assessment is performed intraoperatively during all sub-capital realignment procedures. We will describe our method and outcomes below. We hypothesize that the presence or absence of intraoperative femoral head perfusion may predict the risk of developing post-operative AVN.

MATERIALS AND METHODS

In this retrospective study, we collected data from all patients that had intraoperative femoral head perfusion assessment during sub-capital realignment procedures for SCFEs at our institution. Data were collected from January 2015 to March 2020 inclusive. During this period, 41 patients had 43 sub-capital realignment procedures. Unfortunately, eight patients had to be excluded, as six patients did not have any documentation of intraoperative femoral head perfusion assessment and two patients had probe issues that could not be resolved therefore no assessment was possible. This resulted in 33 patients who had 35 sub-capital realignment procedures with femoral head perfusion assessment being included in our study.



At our institution, femoral head perfusion was documented in two ways. First, the presence or absence of blood flow

from a hole drilled by a 1.5-mm drill was recorded pre- and post-provisional fixation of the epiphysis. Second, an arterial line monitoring system was used to record femoral head perfusion (Fig. 1).

Our technique involved the use of an 18-gauge side venting intraosseous needle that was connected to a luer lock connector. This was attached to an arterial line, which was then primed and connected to the anaesthetic arterial line monitor. The needle was then placed into a 1.5-mm diameter drill hole that was drilled superolaterally in the femoral epiphysis. This drill hole did not penetrate the physis. The arterial line waveform parameters were set to central venous pressure settings to account for the narrow pulse pressure to allow visualization of a waveform. The presence of a waveform indicated the femoral head was perfused and no waveform indicated a lack of femoral head perfusion. Femoral head perfusion was recorded both pre- and post-reduction of the epiphysis when possible. In a subgroup of patients where vascularity was compromised intra-operatively via our technique, perfusion imaging was performed post-operatively either via MRI or bone scan to confirm vascularity. Radiological collapse was the earliest sign of AVN, and as such, AVN was defined by the presence of femoral collapse on post-operative radiographs (Figs 2–4).

All procedures were performed by a combination of our three-subspecialist paediatric hip preservation surgeons via a Ganz surgical hip dislocation approach with a modified Dunn procedure to achieve capital realignment. Weight-bearing status and post-operative follow-up varied

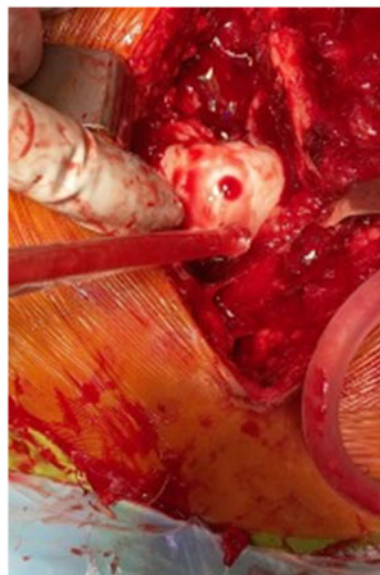

Fig. 1. Bleeding from femoral epiphysis via 1.5 mm drill hole.

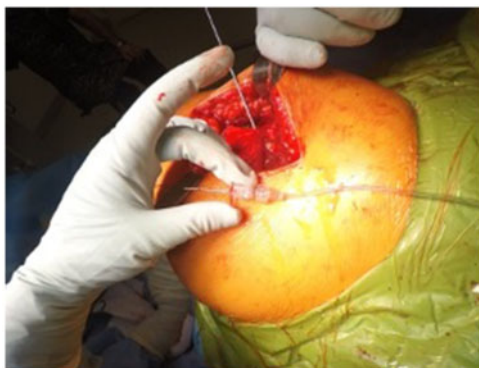

Fig. 2. Intraosseous needle before insertion into femoral epiphysis.

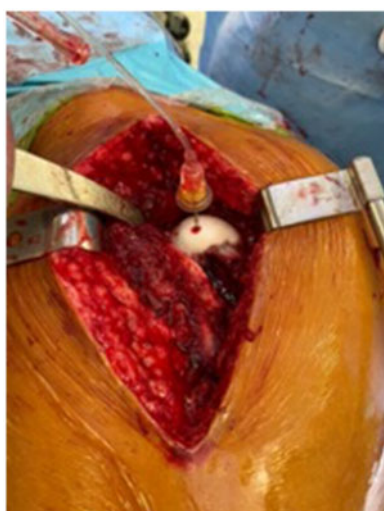

Fig. 3. Intraosseous needle placed into 1.5 mm drill hole in femoral epiphysis to assess femoral head perfusion.

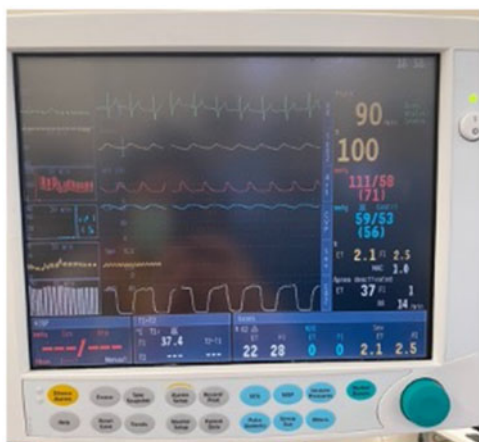

Fig. 4. Arterial monitor showing the presence of a pulsatile waveform (blue) indicating that the femoral head is perfused.

depending on the surgeon involved and degree of the slip but usually entailed 6–12 weeks of non-weight bearing on the affected side, with gradual increasing in weight bearing if deemed suitable at that follow-up appointment. Serial radiographs were performed to look for development of AVN, femoral head collapse, physal closure and union of osteotomies at follow-up clinic appointments. Follow-up was continued until skeletal maturity.

RESULTS

In total, 35 sub-capital alignment procedures were performed from 2015 to March 2020 that had intraoperative femoral head perfusion assessment with arterial line monitoring. Of these, 20 (57%) were classified as unstable as per Loder’s criteria, 21 (60%) were classified as severe based on Southwick’s classification and 14 as moderate with an average slip angle of 51 degrees.

Nineteen (54%) patients were female and sixteen (46%) were male. The average age of the patients was 12 and the average follow-up time was 2 years and 4 months (Table I).

Of the 26 (74%) patients who had documented waveform present intraoperatively, two of these patients developed AVN post-operatively (8%). Both of these patients had perfusion only after reduction of the epiphysis. Therefore, if an intraoperative waveform was present, the positive predictive value of the patient avoiding AVN was 0.92. Of these 26 patients, three patients had a waveform restored after reduction of the epiphysis that did not have one prior. AVN developed in two of these three patients.

In total, 9 (26%) patients had no waveform present intraoperatively both before reduction of the epiphysis and post-reduction of the epiphysis. Of these, seven patients developed AVN (78%). The positive predictive value, that is if no waveform was present the chance of a patient developing AVN was 0.78. In these patients where no waveform was present, post-operative perfusion imaging

Table I. Patient characteristics

<i>Patient characteristics</i>	
Age (years)	12
Sex (male)	16
Chronology (chronic)	12
Stability (unstable)	20
Severity (severe)	21
Slip angle average (degrees)	51
Follow up (years)	2.4

was performed either by bone scan or MRI. All 7 patients that developed AVN had avascular post-operative perfusion imaging whereas the two patients that did not develop AVN, had vascular post-operative perfusion imaging. No patients had a waveform present before the reduction of the epiphysis which was then lost after reduction of the epiphysis.

Out of 35 cases, 9 (26%) patients developed post-operative AVN. Of these 9 patients, 7 had no waveform intraoperatively and 2 had a waveform but only after reduction of the epiphysis (Tables II–IV).

DISCUSSION

AVN is a devastating complication of SCFEs. The exact mechanism for the development of AVN is unclear. Numerous causes and theories have been described. Kinking or tearing of the retinacular vessels at the time of the slip [5, 21], stretching of the vessels by posteromedial callus of the femoral neck during reduction [22] or increases in intracapsular pressure causing a tamponade effect [23, 24] have all been described to increase the risk of AVN development. Timing of the slip [25–27], severity of the slip as defined by the Southwick angle [3] and patient's age [27] have also been described as non-modifiable risk factors for the development of AVN.

The modified Dunn technique described by Ganz in 2001 [13, 28] is an open surgical hip dislocation approach with dissection and elevation of a retinacular flap containing and protecting the nutrient vessels to the femoral head. It has revolutionized treatment algorithms for unstable and severe SCFEs. The modified Dunn technique provides direct visualization of the femoral head, controlled reduction, protection of the vascular retinaculum and allows assessment of femoral head perfusion intraoperatively—potentially predicting the risk of AVN [29]. However, results of this technique are varied, with some studies suggesting that there may be an increased risk of AVN in stable SCFEs [30] and an increased risk of iatrogenic complications due to the technical complexity of the procedure [16].

The intraoperative assessment of femoral head perfusion is becoming increasingly common when treating SCFEs [31, 32]. Many studies have now published results suggesting that this may be a more accurate and easier way to predict the development of AVN rather than previously described methods such as MRI, bone scan or angiography [14, 19]. It also has the benefit of real-time adjustment of osteotomy and reduction position to ensure adequate head perfusion is maintained. This therefore provides a real-time assessment and the ability to change the patient's outcome, in contrast to waiting for a post-operative radiological assessment.

The methods of assessing femoral head perfusion that have been described are evaluation of bleeding by creating a drill hole [16, 29, 33], the use of Laser Doppler Flowmetry [17, 20] and intracranial pressure monitoring (ICP) [14, 19]. Assessing bleeding via a drill hole is a simple way to assess femoral head perfusion but can only be done with open surgeries. The use of ICP monitoring requires the presence and use of specialized equipment and can be utilized with both open and percutaneous techniques. Both these techniques were compared in the treatment of unstable SCFEs in 2016 by assessing femoral head perfusion before and after reduction with the modified Dunn technique. This study concluded that both methods are effective at determining the patients who do develop AVN [14].

A percutaneous approach with ICP monitoring to assess femoral head perfusion by placing an ICP monitor through a cannulated screw has also been described. Six out of their 26 patients had no measurable flow, but all regained flow following a percutaneous capsular decompression. None of these patients developed post-operative AVN [19].

Similar to our technique an epidural catheter attached to an arterial pressure transducer has previously shown a good correlation between a pressure wave intraoperatively and femoral head vascularity [34].

Our proposed technique is inexpensive and easily reproducible using an 18-gauge intraosseous side venting needle connected to an arterial line that is placed into a 1.5-mm drill hole in the femoral epiphysis. This allows visualization and recording of a pulsatile waveform. Of our patient cohort, only 2 of 26 patients that had an intraoperative waveform present developed AVN. Both of these patients were classified as having unstable SCFEs and having an acute presentation of a chronic slip. They both had an intraoperative waveform present, but only after reduction of the epiphysis. Interestingly the two patients that did not develop AVN, who did not have an intraoperative waveform present both had chronic stable slips. This is consistent with the rest of our data showing that no patient with chronic or stable slips, developed AVN. One theory to explain this is that the femoral head develops a collateral blood supply with chronic SCFEs, thus reducing the risk of AVN. However, a recent study showed limited perforating vessels in those with chronic SCFEs [35]. Another theory is that an acute unstable SCFE can shear the vessels whereas a chronic SCFE does not kink the retinacular vessels and therefore reduces the risk of AVN developing.

Our results indicate that our technique may be an accurate one at predicting the post-operative risk of AVN. Using our technique if a waveform was present intraoperatively, the post-operative risk of AVN is low. In contrast, if there

Table II. Comparison of intraoperative and post-operative measures of femoral head perfusion and the development of avascular necrosis

Age (years)	Sex	Chronology	Stability	Severity	Slip angle (degrees)	Drill hole	Waveform	AVN
11	F	Acute on chronic	Unstable	Severe	52	Not bleeding	No waveform	Yes
7	M	Acute on chronic	Unstable	Severe	53	Not bleeding	No waveform	Yes
10	F	Acute on chronic	Unstable	Severe	74	Not bleeding	No waveform	Yes
11	F	Acute on chronic	Unstable	Severe	61	Not bleeding	No waveform	Yes
12	M	Acute on chronic	Unstable	Severe	58	Not bleeding	No waveform	Yes
8	F	Acute on chronic	Unstable	Moderate	43	Not documented	No waveform	Yes
12	F	Acute on chronic	Unstable	Severe	50	Not bleeding	No waveform	Yes
13	F	Chronic	Stable	Moderate	39	Bleeding	No waveform	No
11	M	Chronic	Stable	Severe	69	Not bleeding	No waveform	No
14	M	Acute on chronic	Unstable	Severe	70	Bleeding	Waveform present	Yes
11	F	Acute on chronic	Unstable	Severe	50	Not bleeding	Waveform present	Yes
13	F	Acute on chronic	Stable	Severe	72	Bleeding	Waveform present	No
11	F	Acute on chronic	Unstable	Moderate	35	Bleeding	Waveform present	No
18	M	Acute	Unstable	Severe	55	Bleeding	Waveform present	No
12	F	Chronic	Stable	Severe	60	Bleeding	Waveform present	No
14	F	Chronic	Stable	Severe	51	Bleeding	Waveform present	No
13	F	Chronic	Stable	Moderate	32	Bleeding	Waveform present	No
11	F	Chronic	Unstable	Moderate	42	Bleeding	Waveform present	No
12	M	Acute on chronic	Stable	Moderate	35	Not documented	Waveform present	No
13	F	Chronic	Stable	Moderate	41	Bleeding	Waveform present	No
13	F	Acute on chronic	Stable	Moderate	43	Bleeding	Waveform present	No
9	F	Acute on chronic	Unstable	Severe	56	Bleeding	Waveform present	No
14	M	Chronic	Stable	Moderate	43	Bleeding	Waveform present	No
12	M	Chronic	Unstable	Moderate	44	Bleeding	Waveform present	No
12	M	Chronic	Unstable	Moderate	43	Bleeding	Waveform present	No
12	M	Acute on chronic	Unstable	Severe	54	Bleeding	Waveform present	No
15	M	Acute on chronic	Stable	Severe	52	Bleeding	Waveform present	No
12	M	Chronic	Stable	Moderate	32	Bleeding	Waveform present	No
13	F	Acute on chronic	Unstable	Moderate	45	Bleeding	Waveform present	No
14	M	Acute on chronic	Unstable	Severe	56	Bleeding	Waveform present	No

(continued)

Table II. (continued)

Age (years)	Sex	Chronology	Stability	Severity	Slip angle (degrees)	Drill hole	Waveform	AVN
14	M	Acute on chronic	Unstable	Severe	53	Bleeding	Waveform present	No
9	M	Acute on chronic	Unstable	Severe	70	Bleeding	Waveform present	No
10	F	Chronic	Stable	Moderate	44	Bleeding	Waveform present	No
13	M	Acute on chronic	Stable	Severe	55	Bleeding	Waveform present	No
12	F	Acute on chronic	Stable	Severe	57	Bleeding	Waveform present	No

Table III. Presence or absence of an intraoperative waveform based on sex and slip characteristics

	Overall (n = 35)	Waveform (n = 26)	No waveform (n = 9)
Male (% of hips)	16 (46)	13 (50)	3 (33)
Female (% of hips)	19 (54)	13 (50)	6 (67)
Acute (% of hips)	1 (3)	1 (4)	0 (0)
Acute on chronic (% of hips)	22 (63)	15 (58)	7 (78)
Chronic (% of hips)	12 (34)	10 (38)	2 (22)
Stable (% of hips)	15 (43)	13 (50)	2 (22)
Unstable (% of hips)	20 (57)	13 (50)	7 (78)
Severe (% of hips)	21 (60)	14 (54)	7 (78)
Moderate (% of hips)	14 (40)	12 (46)	2 (22)

Table IV. Post-operative perfusion imaging in those patients with absent intraoperative waveform

Age (years)	Sex	Chronology	Stability	Severity	Slip Angle (degrees)	Waveform	Perfusion Imaging	AVN
11	F	Acute on chronic	Unstable	Severe	52	No waveform	Avascular	Yes
7	M	Acute on chronic	Unstable	Severe	53	No waveform	Avascular	Yes
10	F	Acute on chronic	Unstable	Severe	74	No waveform	Avascular	Yes
11	F	Acute on chronic	Unstable	Severe	61	No waveform	Avascular	Yes
12	M	Acute on chronic	Unstable	Severe	58	No waveform	Avascular	Yes
8	F	Acute on chronic	Unstable	Moderate	43	No waveform	Avascular	Yes
12	F	Acute on chronic	Unstable	Severe	50	No waveform	Avascular	Yes
13	F	Chronic	Stable	Moderate	39	No waveform	Vascular	No
11	M	Chronic	Stable	Severe	69	No waveform	Vascular	No

was no waveform present, the risk of developing AVN is high. If no waveform was present but pulsatile flow was seen from the femoral epiphysis drill holes, it allows real-time adjustment to attempt to restore evidence of femoral head perfusion. First, technical factors with the use of the arterial line are addressed. These include making sure the arterial line is zeroed at the patient level, making sure the needle is the correct size for the hole drilled or making sure the needle bore is not stuck or blocked. After these factors were addressed, if there was still no waveform is present, iatrogenic factors were considered. This meant the correction would be taken down and reassessed, any extra posterior callus removed and potentially accompanied with further shortening. Perfusion was then again reassessed following this. This real-time assessment helps us guide intraoperative and post-operative care. It allows us to counsel parents accordingly and more aggressively monitor those who are at higher risk of developing AVN post-operatively and therefore plan measures to delay or prevent the onset of AVN such as longer periods of non-weight bearing. In these patients who did not have an intraoperative waveform present, post-operative perfusion imaging was performed to confirm vascularity.

These results are similar to previous studies that show those with no perfusion intraoperative are at high risk of developing AVN [15, 16, 20] and those who do have perfusion intraoperatively are at low risk of developing AVN [18, 19]. In comparison to other techniques which have used laser Doppler flowmetry or ICP monitoring, our paper describes a novel, inexpensive, readily available and reliable way to assess intraoperative perfusion using an arterial line.

The main limitation of our study is that it is a retrospective study with relatively low numbers. Eight cases also needed to be excluded due to no documentation of intraoperative arterial monitoring or probe issues that did not enable an assessment to be made. This reduced the total numbers in our study, however, the numbers in our study are comparable with the numbers in previous studies that have assessed intraoperative femoral head perfusion and its correlation with post-operative AVN [14, 19].

Our study does demonstrate a simple, cheap and reliable way to assess femoral head perfusion intraoperatively during surgical hip dislocation and sub-capital realignment procedures. It may be an accurate measure of predicting a patient's risk of developing post-operative AVN.

Further prospective studies would allow for improved data to support the use of our technique of intraoperative perfusion assessment and its accuracy in predicting a patient's post-operative risk of avascular necrosis.

CONFLICT OF INTEREST

No conflicts of interest to declare.

REFERENCES

- Loder RT, Skopelja EN. The epidemiology and demographics of slipped capital femoral epiphysis. *ISRN Orthop* 2011; **2011**: 486512.
- Loder RT, Richards B, Shapiro PS *et al*. Acute slipped capital femoral epiphysis: the importance of physeal stability. *J Bone Joint Surg Am Vol* 1993; **75**: 1134–40.
- Southwick WO. Osteotomy through the lesser trochanter for slipped capital femoral epiphysis. *JBJS* 1967; **49**: 807–35.
- Georgiadis AG, Zaltz I. Slipped capital femoral epiphysis: how to evaluate with a review and update of treatment. *Pediatr Clin* 2014; **61**: 1119–35.
- Zaltz I, Baca G, Clohisy JC. Unstable SCFE: review of treatment modalities and prevalence of osteonecrosis. *Clin Orthop Related Res* 2013; **471**: 2192–8.
- Larson AN, McIntosh AL, Trousdale RT *et al*. Avascular necrosis most common indication for hip arthroplasty in patients with slipped capital femoral epiphysis. *J Pediatr Orthop* 2010; **30**: 767–73.
- Naseem H, Chatterji S, Tsang K *et al*. Treatment of stable slipped capital femoral epiphysis: systematic review and exploratory patient level analysis. *J Orthop Traumatol* 2017; **18**: 379–94.
- Tokmakova KP, Stanton RP, Mason DE. Factors influencing the development of osteonecrosis in patients treated for slipped capital femoral epiphysis. *JBJS* 2003; **85**: 798–801.
- Ward WT, Stefko J, Wood K *et al*. Fixation with a single screw for slipped capital femoral epiphysis. *J Bone Joint Surg Am Vol* 1992; **74**: 799–809.
- Palocaren T, Holmes L, Rogers K *et al*. Outcome of in situ pinning in patients with unstable slipped capital femoral epiphysis: assessment of risk factors associated with avascular necrosis. *J Pediatr Orthop* 2010; **30**: 31–6.
- Gordon JE, Abrahams MS, Dobbs MB *et al*. Early reduction, arthrotomy, and cannulated screw fixation in unstable slipped capital femoral epiphysis treatment. *J Pediatr Orthop* 2002; **22**: 352–8.
- Parsch K, Weller S, Parsch D. Open reduction and smooth Kirschner wire fixation for unstable slipped capital femoral epiphysis. *J Pediatr Orthop* 2009; **29**: 1–8.
- Ganz R, Gill T, Gautier E *et al*. Surgical dislocation of the adult hip: a technique with full access to the femoral head and acetabulum without the risk of avascular necrosis. *J Bone Joint Surg Br Vol* 2001; **83**: 1119–24.
- Novais EN, Sink EL, Kestel LA *et al*. Is assessment of femoral head perfusion during modified Dunn for unstable slipped capital femoral epiphysis an accurate indicator of osteonecrosis? *Clin Orthop Related Res* 2016; **474**: 1837–44.
- Madan S, Cooper A, Davies A *et al*. The treatment of severe slipped capital femoral epiphysis via the Ganz surgical dislocation and anatomical reduction: a prospective study. *Bone Joint J* 2013; **95-B**: 424–9.
- Sankar WN, Vanderhave KL, Matheney T *et al*. The modified Dunn procedure for unstable slipped capital femoral epiphysis: a multicenter perspective. *JBJS* 2013; **95**: 585–91.

17. Huber H, Dora C, Ramseier L *et al.* Adolescent slipped capital femoral epiphysis treated by a modified Dunn osteotomy with surgical hip dislocation. *J Bone Joint Surg Br Vol* 2011; **93**: 833–8.
18. Jackson JB, Frick SL, Brighton BK *et al.* Restoration of blood flow to the proximal femoral epiphysis in unstable slipped capital femoral epiphysis by modified Dunn procedure: a preliminary angiographic and intracranial pressure monitoring study. *J Pediatr Orthop* 2018; **38**: 94–9.
19. Schrader T, Jones CR, Kaufman AM *et al.* Intraoperative monitoring of epiphyseal perfusion in slipped capital femoral epiphysis. *JBJS* 2016; **98**: 1030–40.
20. Ziebarth K, Leunig M, Slongo T *et al.* Slipped capital femoral epiphysis: relevant pathophysiological findings with open surgery. *Clin Orthop Related Res* 2013; **471**: 2156–62.
21. Loder RT. What is the cause of avascular necrosis in unstable slipped capital femoral epiphysis and what can be done to lower the rate? *J Pediatr Orthop* 2013; **33**: S88–S91.
22. Loder RT, Dietz FR. What is the best evidence for the treatment of slipped capital femoral epiphysis? *J Pediatr Orthop* 2012; **32**: S158–S65.
23. Peterson MD, Weiner DS, Green NE *et al.* Acute slipped capital femoral epiphysis: the value and safety of urgent manipulative reduction. *J Pediatr Orthop* 1997; **17**: 648–54.
24. Herrera-Soto JA, Duffy MF, Birnbaum MA *et al.* Increased intracapsular pressures after unstable slipped capital femoral epiphysis. *J Pediatr Orthop* 2008; **28**: 723–8.
25. Kaewpornsawan K, Sukvanich P, Eamsobhana P *et al.* The most important risk factors for avascular necrosis and chondrolysis in patients with slipped capital femoral epiphysis. *J Med Assoc Thai* 2014; **97**: S133–S38.
26. Rattey T, Piehl F, Wright J. Acute slipped capital femoral epiphysis. Review of outcomes and rates of avascular necrosis. *JBJS* 1996; **78**: 398–402.
27. Sankar WN, McPartland TG, Millis MB *et al.* The unstable slipped capital femoral epiphysis: risk factors for osteonecrosis. *J Pediatr Orthop* 2010; **30**: 544–8.
28. Dunn DM. The treatment of adolescent slipping of the upper femoral epiphysis. *J Bone Joint Surg Br Vol* 1964; **46**: 621–9.
29. Ziebarth K, Zilkens C, Spencer S *et al.* Capital realignment for moderate and severe SCFE using a modified Dunn procedure. *Clin Orthop Related Res* 2009; **467**: 704–16.
30. Davis RL, Samora WP, III, Persinger F *et al.* Treatment of unstable versus stable slipped capital femoral epiphysis using the modified Dunn procedure. *J Pediatr Orthop* 2019; **39**: 411–5.
31. Daley E, Zaltz I. Strategies to avoid osteonecrosis in unstable slipped capital femoral epiphysis: a critical analysis review. *JBJS Rev* 2019; **7**: e7.
32. Otani T, Kawaguchi Y, Marumo K. Diagnosis and treatment of slipped capital femoral epiphysis: recent trends to note. *J Orthop Sci* 2018; **23**: 220–8.
33. Aprato A, Bonani A, Giachino M *et al.* Can we predict femoral head vitality during surgical hip dislocation? *J Hip Preserv Surg* 2014; **1**: 77–81.
34. Madhuri V, Dutt V, Samuel K *et al.* Intra-operative femoral head vascularity assessment: an innovative and simple technique. *Indian J Orthop* 2011; **45**: 231–5.
35. Shore BJ, Mardam-Bey SW, Kim Y-J *et al.* Vascular supply to the femoral head in patients with healed slipped capital femoral epiphysis. *J Pediatr Orthop* 2020; **40**: e53–7.