

Management of Developing Skeletal Class III Malocclusion in a Prepubertal Girl with Prognathic Mandible in Late Mixed Dentition

Abstract

Treatment of skeletal Class III patients at younger age is highly unpredictable. The patient may respond well to the treatment or may show excessive mandibular growth during growth spurt which may require orthognathic surgery later on. If not treated at earlier stages of life, the condition may worsen with time. This case report will present the comprehensive orthodontic management of a 9-year-old prepubertal girl in late mixed dentition with prognathic mandible. Chin cup therapy was started and continued for 3 years. After chin cup therapy, maxillary and mandibular dentition were bonded with standard edgewise appliance. After leveling and alignment, Class III elastics were started. Fixed orthodontic treatment was completed in 3 years. At the end, good Class I molar and canine relationship with normal overjet and overbite were achieved. The total treatment time of orthopedic and orthodontic correction was 6 years, 2 months. The patient revealed the same Class I molar and canine relationship after 6 years of treatment. Redirection of mandibular growth pattern from hyperdivergent to normodivergent advocates the use of chin cup as a viable treatment regimen for the management of prognathic mandible in prepubertal patients.

Keywords: *Chin cup therapy, Class III malocclusion, hyperdivergent growth pattern, mandibular prognathism, mixed dentition, prepubertal*

Introduction

Skeletal Class III malocclusion in mixed dentition or late deciduous dentition is most challenging for the orthodontists to treat. It may result either from maxillary deficiency or mandibular prognathism or a combination of both.^[1-3] This condition presents as concave facial profile with Angle's Class III malocclusion. The treatment approach during growth is to apply orthopedic force to the maxilla or mandible, depending on where basically the skeletal problem exists.^[4] In cases with maxillary retrusion or deficiency, facemask or facemask with rapid maxillary expansion is the treatment of choice, whereas in mandibular prognathism, chin cup therapy is the traditional treatment modality. Chin cup therapy redirects the mandibular growth at chin, helps in backward repositioning of the mandible, retards the growth at condyle, and remodels the mandibular morphology at gonial angle and symphysis.^[5-16] Results of a recent meta-analysis and systematic review had showed that chin cup therapy reduced the gonial angle and angle SNB significantly when compared to untreated patients.^[17]

This is an open access article distributed under the terms of the Creative Commons Attribution-NonCommercial-ShareAlike 3.0 License, which allows others to remix, tweak, and build upon the work non-commercially, as long as the author is credited and the new creations are licensed under the identical terms.

For reprints contact: reprints@medknow.com

The recommended age range for the use of chin cup therapy had been suggested from 4 to 14 years.^[18,19] A longitudinal study reported by Wendell *et al.* claimed that patients treated with chin cup therapy showed reduced downward displacement of mandible than that of control group and improvement in skeletal profile.^[20] In those cases where Class III malocclusion is because of the combination of maxillary deficiency and mandibular prognathism, chin cup with facemask is the treatment of choice. The purpose of this article is to present a comprehensive approach to manage a 9-year-old prepubertal girl at her late mixed dentition stage with skeletal Class III malocclusion due to prognathic mandible. Initial orthopedic interception with chin cup therapy (combination type) followed by fixed orthodontic treatment with multibracketed standard edgewise appliance was instituted. After 6 years posttreatment, her occlusion was stable with harmonious soft-tissue profile.

Case Report

A 9-year-old prepubertal girl reported to the Unit of Orthodontics, Oral Health Sciences

How to cite this article: Singh SP, Kumar V, Verma R, Singh S. Management of developing skeletal class III malocclusion in a prepubertal girl with prognathic mandible in late mixed dentition. *Contemp Clin Dent* 2017;8:139-44.

**Satinder Pal Singh,
Vinay Kumar,
Rashmi Verma,
Sombir Singh**

*Oral Health Sciences Centre,
Unit of Orthodontics,
Postgraduate Institute of
Medical Education and
Research, Chandigarh, India*

Address for correspondence:

*Dr. Satinder Pal Singh,
Unit of Orthodontics, Oral
Health Sciences Centre,
Postgraduate Institute of
Medical Education and
Research, Chandigarh, India.
E-mail: drspsingh_chd@yahoo.
com*

Access this article online

Website:

www.contempclindent.org

DOI: 10.4103/ccd.ccd_1078_16

Quick Response Code:



Center, Postgraduate Institute of Medical Education and Research, Chandigarh, with a chief complaint of lower teeth coming in front of the upper teeth. On clinical examination, she had apparently symmetrical leptoprosopic face. She had orthognathic facial profile. Her facio-maxillary midline was concordant, but facio-mandibular midline was shifted to the right by 1 mm. There was no shift of midline on mandibular closure [Figure 1a-c]. On intraoral examination, her dentition revealed late mixed dentition stage with Class I molar relation on the right side and Class III molar relation on the left side with edge-to-edge incisor relation. Maxillary and mandibular arches were asymmetric with flattening on the right side. Maxillary and mandibular incisors were in edge-to-edge relation [Figure 1d]. Maxillary dentition revealed cross-bite tendency [Figure 2a-d].

Examination of intraoral periapical (IOPA) radiographs in relation to maxillary and mandibular incisors revealed no periapical pathology [Figure 3a and b]. Panoramic radiograph revealed that full complement of teeth was present in both maxillary and mandibular arches. All second molars were in the Nolla's stage 6 of teeth development. No clinical significant abnormality was observed [Figure 3c].

Cephalometric analysis showed a skeletal Class III bases due to mandibular prognathism with hyperdivergent growth pattern (FMA; 31° , SNMP; 38°), proclined and protruded upper incisors (5 mm and 31°), and retroclined lower incisors with normal nasolabial angle. She was in Cervical Vertebrae Maturation Indicator Stage 2 [Figure 3d].

Problem list

- Skeletal Class III bases due to mandibular prognathism in sagittal and vertical planes
- Edge-to-edge incisor relationship
- Hyperdivergent growth pattern due to downward and backward rotations of mandible
- Proclined and protruded upper incisors (compensatory proclination)
- Discordant midlines.

Objectives of treatment

- Interception of developing Class III skeletal bases due to mandibular prognathism
- To intercept the hyperdivergent growth pattern
- To achieve optimal overjet and overbite
- Correction of proclined and protruded upper incisors
- Correction of midline discordant.

Treatment plan

- Chin cup therapy to redirect mandibular growth in both sagittal and vertical planes
- Followed by comprehensive orthodontic treatment with fixed appliance and Class III mechanics.

Treatment progress

As this patient reported at an early age with Class III skeletal pattern due to mandibular prognathism, chin cup

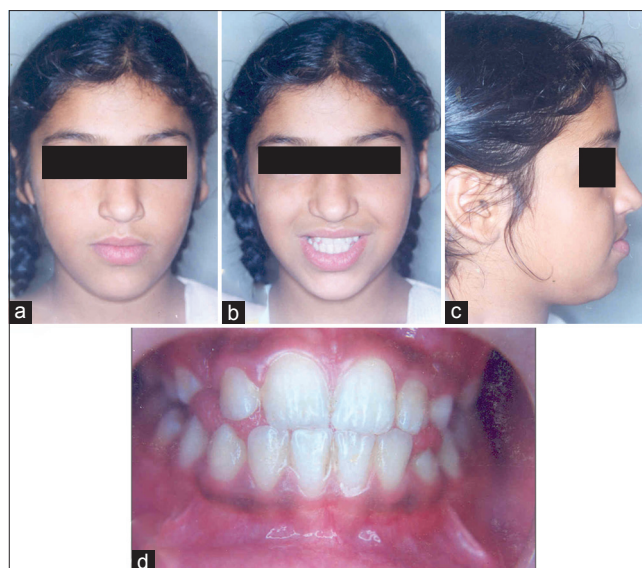

Figure 1: Patient's pretreatment photographs (a) extraoral frontal (b) extraoral smile (c) profile (d) intraoral frontal

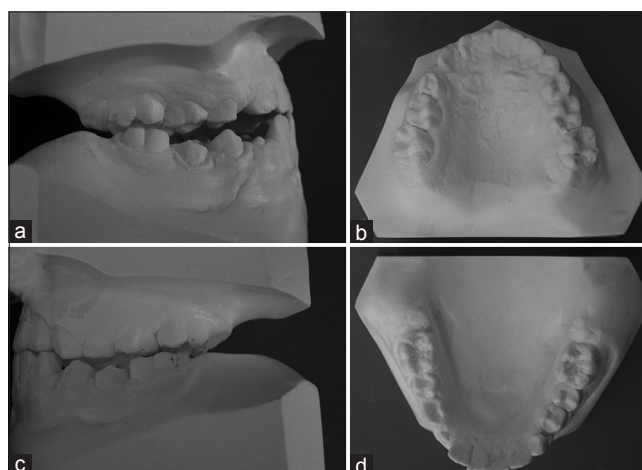


Figure 2: Pretreatment study models (a) right buccal occlusion (b) left buccal occlusion (c) maxillary occlusal view (d) mandibular occlusal view

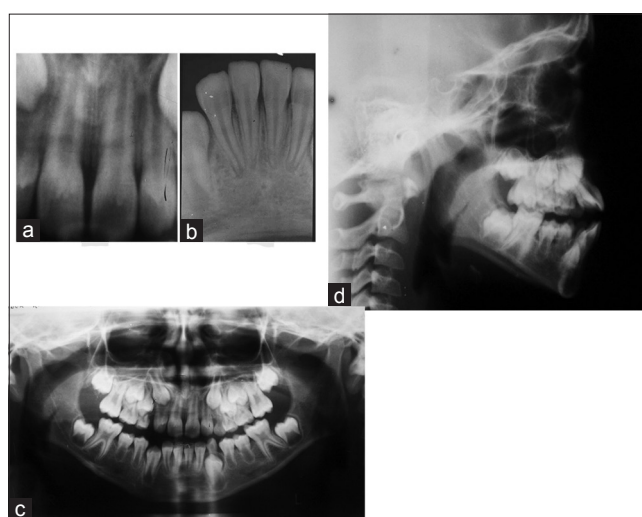


Figure 3: Pretreatment radiographs (a) maxillary intraoral periapical (b) mandibular intraoral periapical (c) orthopantomograph (d) lateral cephalogram

therapy [Figure 4a] was started at this stage and advised to wear it for approximately 14–16 h/day. Orthopedic force delivered was 300 g initially to a maximum of 600 g/side.^[21] This regimen was continued for 3 years. After chin cup therapy [Figure 4b] full-arch bonding of the upper and lower arches was done using 018” slot Standard edgewise appliance. After leveling and alignment, Class III elastics (3/16”, 3.5 oz) were started. Comprehensive orthodontic treatment with fixed appliance was completed in 3 years. The total treatment time of orthopedic and orthodontic correction was 6 years, 2 months. There was improvement in facial profile, nasolabial angle, and mentolabial sulcus [Figure 5a-d]. At the end, good Class I molar and canine relationship with normal overjet and

overbite was achieved [Figure 5e-i]). The upper incisor to NA was normalized at the end of treatment [Figure 6]. Posttreatment occlusion, function and esthetics were fairly good. Following comprehensive orthodontic treatment with chin cup and multibracketed appliance, dental health component of the patient improved from 4 at the start of treatment to 1 (post treatment) whereas the esthetic component improved from 3 to 1. PAR index showed 100% of improvement. The upper and lower Hawley’s appliance was used for retention.

Results

The main treatment objectives were achieved with the correction of developing anterior crossbite. The esthetic and functional aspects were satisfactory. The treatment time was 6 years, 2 months. Since skeletal Class III malocclusion was mainly due to prognathic mandible, chin cup therapy was instituted for 3 years. Cephalometric superimposition [Figure 7] showed improvement in facial profile. We had achieved good Class I canine and molar relationship with near-to-ideal overjet and overbite. There was an improvement in interincisal angle with increase in the upper incisor proclination. The evaluation of panoramic radiograph showed good root parallelism of all teeth. Posttreatment, IOPA showed Grade I resorption of roots of the upper and lower incisors. In the present case, Class III correction was mainly achieved by dentional changes with little skeletal improvement. After 6 years

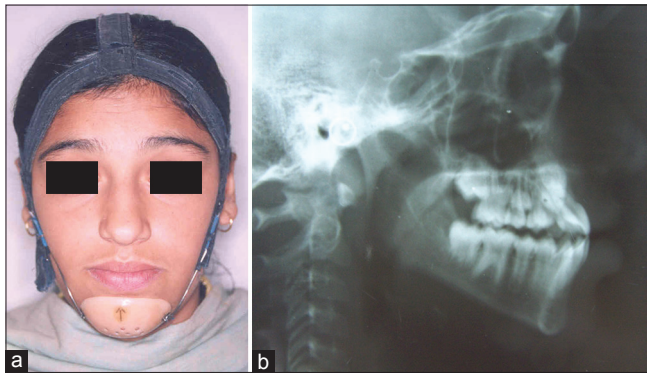


Figure 4: (a) Chin cup delivery (b) lateral cephalogram at the end of chin cup therapy

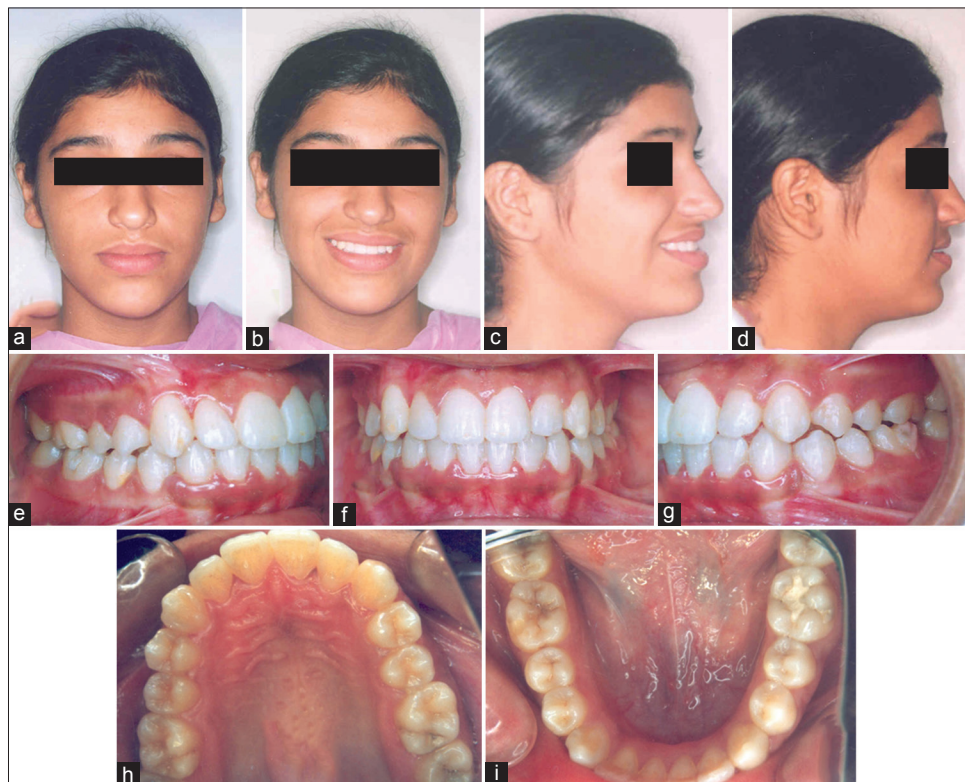

Figure 5: Posttreatment photographs (a-d) extraoral photographs (e-i) intraoral photographs

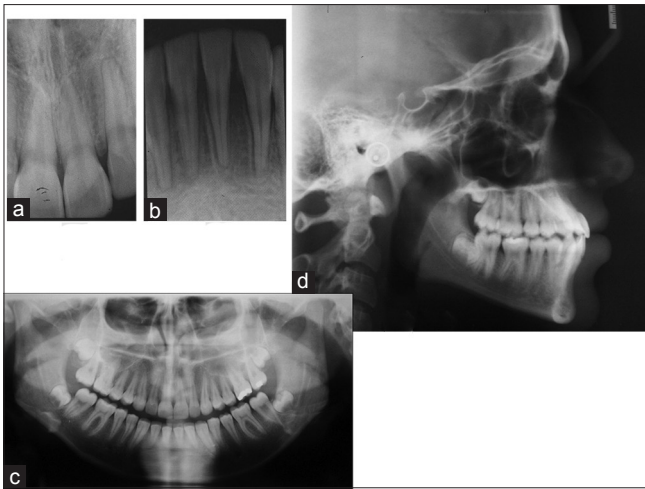


Figure 6: Posttreatment radiographs (a) maxillary intraoral periapical (b) mandibular intraoral periapical (c) orthopantomograph (d) lateral cephalogram

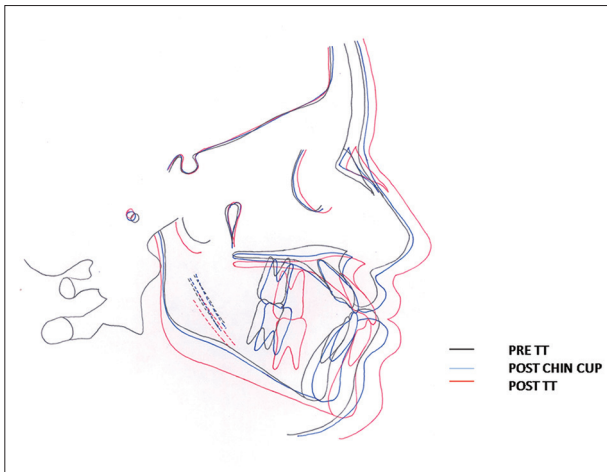


Figure 7: Superimposition at SN plane with registration point at S

of debonding, her facial profile and occlusion are stable [Figure 8a-g].

Discussion

Class III malocclusion treatment in the growing patients is most perplexing for the orthodontists. Although if left untreated, Class III malocclusion tends to worsen, and considerable percentage of adult patients may require orthognathic surgery.^[16] Early treatment is mainly indicated to achieve normal jaw relationships by growth modulation. Mixed dentition period is the best time for the interception. Skeletal Class III malocclusion should be corrected as soon as we see the first sign. Although mandibular growth is under genetic control, chin cup therapy redirects the mandibular growth at chin, retards mandibular growth at condyle, repositions the mandible backward, and remodels the morphology of gonial angle and symphysis.^[6,8,9,11] A minimum of 2 years of chin cup therapy with night time use is necessary as the condyles should be at rest when compressive stress is applied. When planning chin cup therapy, the clinician must take into account the onset and duration of growth spurt.

In the present case, choice of chin cup therapy was made because the skeletal Class III malocclusion was due to the mandibular prognathism. The desired functional and esthetic results were achieved. The use of chin cup improved the maxillomandibular relationship both sagittally and vertically [Table 1]. There was a remarkable improvement in FMA from 31° to 26°. There was a significant improvement in the gonial angle from pretreatment value of 122° to 120° at the completion of chin cup therapy. The literature is well documented with the closure of gonial angle following chin cup therapy. Deguchi and McNamara^[22] reported a significant reduction of pretreatment gonial angle from 127.3° to posttreatment

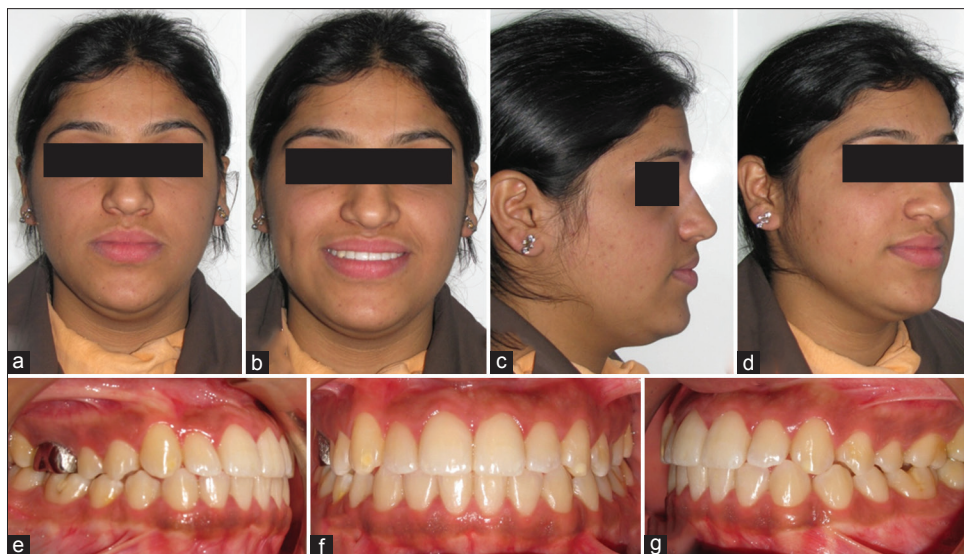


Figure 8: Photographs after 6-year posttreatment (a-d) extraoral (e-g) intraoral

Table 1: Comparison of pretreatment, postchin cup, and posttreatment cephalometric measurements

Parameters	Pretreatment	Postchin cup	Posttreatment
Sagittal skeletal relationship			
SNA (°)	82	81	83
SNB (°)	80	80	83
ANB (°)	2	1	0
Wits appraisal (mm)	-1	-2	-2
Vertical skeletal relationships			
FMA (°)	31	26	24
SN-MP (°)	38	33	31
Gonial angle (Ar-Go-Me) (°)	122	120	118
Sum (Bjork's) (°)	397	393	394
Upper anterior face height (%)	42	44	45
Lower anterior face height (%)	58	56	55
Jarabak ratio (%)	60	64	64
Maxillary length (mm)	47	51	51
Mandibular length (mm)	75	79	85
Dental base relationship			
Upper incisor to NA (mm/°)	5/35	6.5/31	8/32
Lower incisor to NB (mm/°)	6/25	6.5/24	6.5/24
Upper incisor to SN plane (°)	116	116	118
IMPA (°)	90	90	92
Dental relationship			
Interincisal angle (°)	120	120	122
Lower incisor to APog line (mm)	6	6	7
Overbite (%)	0	0	5
Overjet (mm)	0	0	1
Soft tissues			
Upper lip to Ricketts E plane (mm)	-4	-4	-5
Lower lip to Ricketts E plane (mm)	+1	-1	-1
Upper lip to S plane (mm)	0	1	-1.5
Lower lip to S plane (mm)	+4	1	+2
Nasolabial angle (°)	98	102	110
McNamara analysis (mm)			
N perpendicular A	-1	-1	-1
N perpendicular B	-5	-1	0
N perpendicular Pg	-4	-1	0

value of 126.6° on Japanese females. Another study reported by Deguchi *et al.*^[23] has reported 8.2° reduction in the gonial angle after chin cup therapy. The posttreatment decrease in the gonial angle after chin cup therapy has been widely supplied with literature^[24-27] and could be explained with the direction of force applied by chin cup therapy.^[28] In the present case, direction of force applied was anterior and more vertical to the centre of resistance of mandible (CRes) leading to compression of the gonial angle. Since mandibular length in this patient has increased nearly twice the amount of maxilla [Table 1], the occlusion after 6 years of debonding was maintained on the right buccal segment, optimal overjet, and overbite with concordant maxillomandibular midlines, whereas the left buccal segment revealed super Class I molar relation, with acceptable facial profile.

Conclusion

Treatment effects produced by traditional chin cup therapy in redirecting the mandibular growth pattern from hyperdivergent to normodivergent have been described. Selected cases can be benefitted from the chin cup therapy if it is instituted at the right time.

Declaration of patient consent

The authors certify that they have obtained all appropriate patient consent forms. In the form the patient(s) has/have given his/her/their consent for his/her/their images and other clinical information to be reported in the journal. The patients understand that their names and initials will not be published and due efforts will be made to conceal their identity, but anonymity cannot be guaranteed.

Financial support and sponsorship

Nil.

Conflicts of interest

There are no conflicts of interest.

References

- Sanborn RT. Differences between the facial skeletal patterns of class III malocclusion and normal occlusion. *Angle Orthod* 1955;25:208-22.
- Guyot EC, Ellis EE 3rd, McNamara JA Jr., Behrents RG. Components of class III malocclusion in juveniles and adolescents. *Angle Orthod* 1986;56:7-30.
- Williams S, Andersen CE. The morphology of the potential class III skeletal pattern in the growing child. *Am J Orthod Dentofacial Orthop* 1986;89:302-11.
- Mitani H. Recovery growth of the mandible after chin cup therapy: Fact or fiction. *Semin Orthod* 2007;13:186-99.
- Graber LW. The alterability of mandibular growth. In: McNamara JA Jr., editor. *Determinants of Mandibular Form and Growth*. Ann Arbor: Monograph 4, Craniofacial Growth Series. Center of Human Growth and Development, University of Michigan; 1975. p. 229-41.
- Sawa S. Roentgeno-cephalometric study on the dentocranofacial growth of the individuals with reversed occlusion. *Nihon Kyosei Shika Gakkai Zasshi* 1978;37:237-68.
- Suzuki N. A cephalometric observation on the effect of the Chin cap. *Nihon Kyosei Shika Gakkai Zasshi* 1972;31:64-74.
- Susami R, Akiyama K, Oonishi K, Yamano C, Deguchi T. Cephalometric survey of reaction to orthodontic treatment in anterior cross-bite cases 3. Cases treated with the chin cap. *Nihon Kyosei Shika Gakkai Zasshi* 1966;25:75-82.
- Irie M, Nakamura S, Yamamoto S, Fuji H, Wada Y. Cephalometric changes in treatment of anterior crossbite cases with the chin cap. *Nihon Kyosei Shika Gakkai Zasshi* 1972;31:75-86.
- Nukatsuka S. The longitudinal study of orthopedic effects caused by chin cap treatment. *Tohoku Univ Dent J* 1982;1:1-17.
- Armstrong CJ. A clinical evaluation of the chincup. *Aust Orthod J* 1968;6:338-46.
- Cleall JF. Dentofacial orthopedics. *Am J Orthod* 1974;66:237-50.
- Nanda R. Biomechanical and clinical considerations of a modified protraction headgear. *Am J Orthod* 1980;78:125-39.
- Mitani H, Sakamoto T. Chin cap force to a growing mandible. Long-term clinical reports. *Angle Orthod* 1984;54:93-122.
- Thilander B. Treatment of angle class III malocclusion with chin cup. *Trans Eur Orthod Soc* 1963;39:384-98.
- Graber LW. Chin cup therapy for mandibular prognathism. *Am J Orthod* 1977;72:23-41.
- Chatzoudi MI, Ioannidou-Marathiotou I, Papadopoulos MA. Clinical effectiveness of chin cup treatment for the management of class III malocclusion in pre-pubertal patients: A systematic review and meta-analysis. *Prog Orthod* 2014;15:62.
- Barrett AA, Baccetti T, McNamara JA Jr. Treatment effects of the light-force chincup. *Am J Orthod Dentofacial Orthop* 2010;138:468-76.
- Sugawara J. Clinical practice guidelines for developing class III malocclusion. In: Nanda R, editor. *Biomechanics and Esthetic Strategies in Clinical Orthodontics*. US: Saunders; 2005. p. 211-63.
- Wendell PD, Nanda R, Sakamoto T, Nakamura S. The effects of chin cup therapy on the mandible: A longitudinal study. *Am J Orthod* 1985;87:265-74.
- Abdelnaby YL, Nassar EA. Chin cup effects using two different force magnitudes in the management of class III malocclusions. *Angle Orthod* 2010;80:957-62.
- Deguchi T, McNamara JA. Craniofacial adaptations induced by chincup therapy in class III patients. *Am J Orthod Dentofacial Orthop* 1999;115:175-82.
- Deguchi T, Kuroda T, Minoshima Y, Graber TM. Craniofacial features of patients with class III abnormalities: Growth-related changes and effects of short-term and long-term chincup therapy. *Am J Orthod Dentofacial Orthop* 2002;121:84-92.
- Sakamoto T, Iwase I, Uka A, Nakamura S. A roentgenocephalometric study of skeletal changes during and after chin cup treatment. *Am J Orthod* 1984;85:341-50.
- Liu ZP, Li CJ, Hu HK, Chen JW, Li F, Zou SJ. Efficacy of short-term chincup therapy for mandibular growth retardation in class III malocclusion. *Angle Orthod* 2011;81:162-8.
- Sugawara J, Mitani H. Facial growth of skeletal class III malocclusion and the effects, limitations, and long-term dentofacial adaptations to chincap therapy. *Semin Orthod* 1997;3:244-54.
- Alarcón JA, Bastir M, Rosas A, Molero J. Chincup treatment modifies the mandibular shape in children with prognathism. *Am J Orthod Dentofacial Orthop* 2011;140:38-43.
- Deguchi T. Force distribution of the temporomandibular joint and temporal bone surface subjected to the head-chincup force. *Am J Orthod Dentofacial Orthop* 1998;114:277-82.