

Case Report

When paediatric facial nerve paralysis is not a Bell's palsy: A case of cerebellopontine angle tumour

Meriam T. Ismail, MBBS, Razlina A. Rahman, MMed* and Nur S. Idris, MMed

Department of Family Medicine, School of Medical Sciences, Health Campus, Universiti Sains Malaysia, Kubang Kerian, Kelantan, Malaysia

Received 3 May 2021; revised 9 August 2021; accepted 16 August 2021; Available online 4 September 2021



المخلص

يعتبر شلل العصب الوجهي عند الأطفال حالة سريرية نادرة يمكن أن تؤدي إلى مضاعفات خطيرة. بسبب ندرة حدوثه، هذه الأورام خاصة في الزاوية المخيخية الجسرية، يمكن ألا تُلاحظ. نبلغ عن حالة ورم في الزاوية المخيخية الجسرية عند طفل ذكر عمره 8 أعوام حضر بشلل العصب الوجهي في الجانب الأيمن من نوع العصبون الحركي السفلي. كما أظهر الفحص رأياً ثنائية خفيفة. ولكن، تم تضليله بالتشخيص الأولي بشلل بيل، كان هناك تأخير في إجراء التصوير بالرنين المغناطيسي التشخيصي للدماغ، والذي أظهر ورم كبير في الزاوية المخيخية الجسرية. لاحقاً، وبعد ستة أسابيع من حضوره الأولي، مات الطفل من المرض. توضح هذه الحالة أن الفحص السريري الدقيق حتى في الحالات التي تبدو بسيطة أمراً ضرورياً لتجنب أخطاء التشخيص.

الكلمات المفتاحية: شلل بيل؛ رأياً؛ الزاوية المخيخية الجسرية؛ العصب الوجهي؛ الفحص السريري

Abstract

Facial nerve paralysis in children is a rare clinical condition that can lead to serious complications. Due to their rare occurrence, tumours, especially in the cerebellopontine angle, may be overlooked. We report a case of cerebellopontine angle tumour in an 8-year-old boy who presented with a right-sided lower motor neuron type of facial nerve palsy. Further examination showed a mild bilateral nystagmus. However, misled by the initial diagnosis of Bell's palsy, there was a delay in performing

diagnostic magnetic resonance imaging of the brain, which showed a large mass in the cerebellopontine. Subsequently, six weeks after his initial presentation, the boy succumbed to the disease. This case illustrates that careful clinical examination, even in a seemingly simple case, is imperative to avoid diagnostic errors.

Keywords: Bell's palsy; Cerebellopontine angle; Clinical examination; Facial nerve; Nystagmus

© 2021 The Authors.

Production and hosting by Elsevier Ltd on behalf of Taibah University. This is an open access article under the CC BY-NC-ND license (<http://creativecommons.org/licenses/by-nc-nd/4.0/>).

Introduction

Facial nerve palsy is a common cranial nerve dysfunction, and the idiopathic form contributes to 60–75% of the cases. Facial nerve palsy in children is quite rare compared to adults¹ and may have serious implications due to its various aetiologies, treatment options, and prognoses. The common causes of facial nerve palsy in children may range from congenital to acquired causes, such as infection, inflammation, trauma, or iatrogenic causes, while the less common causes are tumours and stroke.^{2,3} The diagnosis of Bell's palsy, the idiopathic form of facial nerve paralysis, can only be made after all these causes have been excluded. Therefore, a thorough clinical examination and diagnostic workup should be performed, particularly in the case of paediatric facial nerve palsy, in order to establish an accurate diagnosis, and thus, the appropriate treatment can be executed according to the specific aetiology.³

* Corresponding address: Department of Family Medicine, School of Medical Sciences, Universiti Sains Malaysia, 16150, Kubang Kerian, Kelantan, Malaysia.

E-mail: razlina@usm.my (R.A. Rahman)

Peer review under responsibility of Taibah University.



Cerebellopontine angle (CPA) tumours, which account for less than 10% of all posterior fossa tumours, are among the most serious causes of facial nerve palsy among children.⁴ The presentation varies from general symptoms of headache, lethargy, and vomiting to localised symptoms of cerebellar dysfunction or cranial nerve paresis.⁴ Owing to the rarity of its incidence in children, it poses challenges in terms of the diagnosis, treatment strategies, surgical approaches, and prognosis of the patient.⁵ In the case of malignant CPA tumours, the prognosis was observed to be poor with high surgical morbidity.⁵

Case report

An 8-year-old boy, accompanied by his father, presented to a general practitioner with a complaint of right facial asymmetry for a period of six days. He was unable to fully close his right eye for three days by that time. Subsequently, he was referred to a tertiary hospital with a diagnosis of right facial nerve palsy for further work-up. Both parents claimed that they noticed that his smile was lopsided with drooping of the right angle of the mouth, which became gradually more prominent within the six days duration. This was followed by a gradual difficulty in fully closing his right eye. He had difficulty drinking as water dribbled from the right side of his mouth. Otherwise, he was able to manage orally well and had no speech problems. He was able to walk and continued with his usual daily activities, including going to school. There was no history of fever, rash, or ear problems preceding the event. There were also no symptoms suggestive of increased intracranial pressure, such as vomiting, headache, or blurring of vision.

On examination, his vital signs were normal. His pupils were reactive, equal with no signs of relative afferent pupillary defect (RAPD). His visual acuity was 6/9 in both the eyes. His facial nerve examination revealed right-sided lower motor neuron facial nerve palsy (Figure 1). The other cranial nerves, cerebellar signs, and neurological examinations were unremarkable. The child was admitted to the paediatric ward and was seen by a paediatrician the subsequent morning,

since they presented during the night. The paediatrician noticed that the child had a very slight bilateral nystagmus. He was then referred to the ophthalmology and otorhinolaryngology teams for further assessment and was planned for brain imaging. The assessment by both the teams did not reveal new signs, and he was concluded to have severe seventh cranial nerve (CN VII) palsy (House-Brackmann Grade V) with no other remarkable examination findings. He was symptomatically treated for Bell's palsy and was started on oral prednisolone 1 mg/kg/day. His parents claimed that the child's facial weakness improved after starting the prednisolone therapy.

Computed tomography (CT) of the brain with contrast, which was performed on the second day of admission, did not show any obvious abnormality initially. However, after the image was reviewed by a radiologist, he noted that there were some ill-defined hypodense areas at the right cerebellar peduncle. A repeated plain CT brain was ordered on the same day to confirm the presence of the lesion, since it does not require any preparation or monitoring of renal function. The report of the images returned on the sixth day of admission and reported a mass lesion at the right cerebellar peduncle with perilesional oedema. He was immediately scheduled for magnetic resonance imaging (MRI) on the seventh day of admission and was found to have a right CPA tumour. The tumour appeared to arise from the right side of the pons and cerebellar peduncle, measuring $4.0 \times 3.6 \times 3.6$ cm in size, occluding the porus acusticus, but not extending to the internal auditory canal. The 4th ventricle was pushed and compressed to the contralateral side with no evidence of hydrocephalus. The tumour abutted the basilar artery, right vertebral artery, and posterior inferior cerebellar artery and crossed the midline (Figure 2).

Subsequently, he was referred to the neurosurgical team as well as to a paediatric oncologist with a diagnosis of a right CPA tumour, provisionally glioma. Surgical resection was necessary for the exact diagnosis of the tumour. However, after some consideration of the pros and cons, the neurosurgical team decided that surgical intervention may not be the best option for the child due to the size and

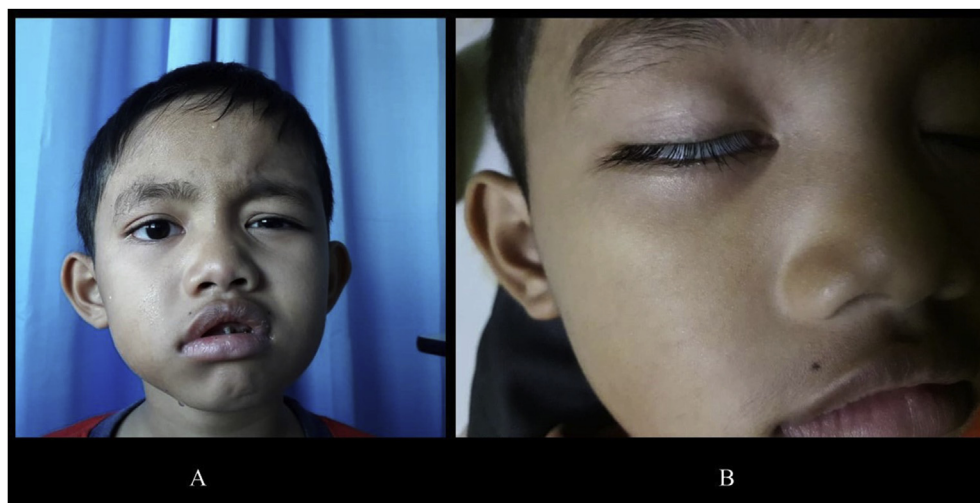

Figure 1: A. Right-sided lower motor neuron facial nerve palsy in the child with weakness of the frontalis muscles, loss of nasolabial fold, drooping corner of mouth, and inability to close the right eye with the widening of palpebral fissure. B. Inability to fully close the right eyes.

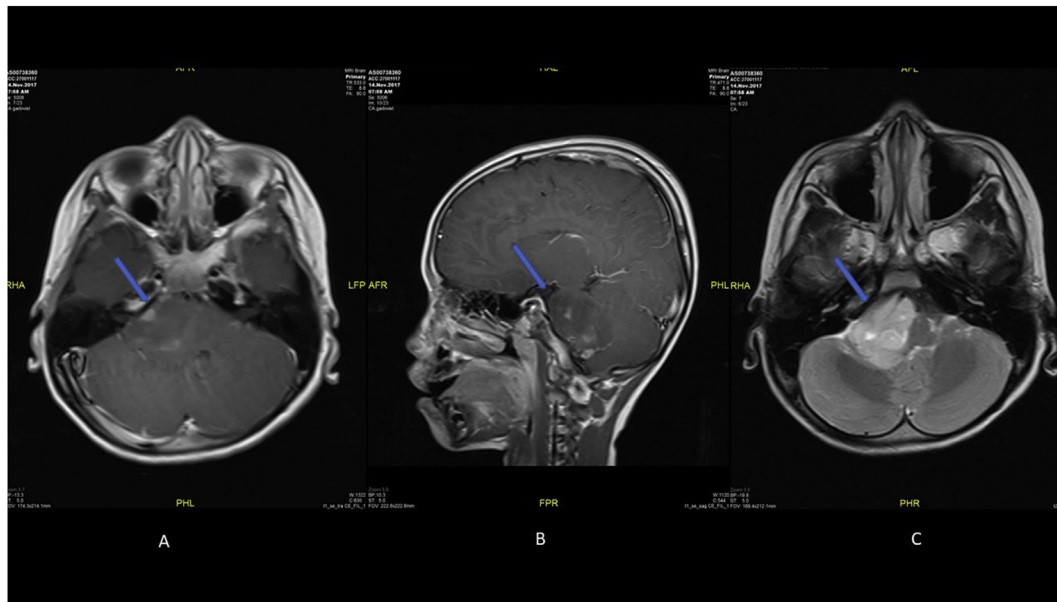


Figure 2: CPA mass arising from the right side of pons and cerebellar peduncle occluding the porus acusticus and causes mass effect onto the 4th ventricle. The axial (A) and sagittal view (B) of the T1-weighted post contrast images showing a well-defined heterogeneous solid mass at the right CP angle with only small areas of enhancement post-contrast. The T2-weighted image (C) shows enhancement of the lesion with areas of hypertense signal suggestive of a cystic component. There is also evidence that the mass has abutted the basilar and right vertebral artery. The arrows point to the lesion.

location of the tumour and suggested radiotherapy. Both parents were informed of the grave prognosis of the disease, and they decided to postpone the treatment and try alternative medicine. At the time of discharge, the child was still active, as usual. However, three weeks later, he developed symptoms of increased intracranial pressure and was readmitted. A repeat CT-brain showed that the size of the mass had increased, resulting in obstructive hydrocephalus and brain oedema. He underwent a ventriculoperitoneal shunt, and his condition seemed to improve initially post-operatively. However, after a few days, his condition worsened, and he succumbed to the disease two weeks after his second admission.

Discussion

The estimated incidence of acquired peripheral facial nerve paralysis in children varies from 5 to 21 per 100 000 annually.⁶ The vast majority of the patients presented with acute unilateral facial palsy occurring over a few hours to a day.⁶ Bell's palsy which accounts for half of the cases, is the most frequent form of facial nerve paralysis; however, 80%–90% of the patients are observed to recover.^{2,3} Nonetheless, Bell's palsy is a diagnosis of exclusion, and the diagnosis can only be made after a thorough examination. Peripheral facial nerve paralysis in children may be a sign of a more serious disease. As shown in this case, the patient presented with facial nerve paralysis with few other signs or symptoms.

Among the serious disorders not to be missed in cases of facial nerve palsy is the CPA tumour. The cerebellopontine angle is a small wedge-shaped cistern within the posterior fossa bordered by the petrous temporal bone, cerebellar peduncle, brain stem, and the arachnoid tissue of the lower

cranial nerves (CN IX, X, and XI).⁴ The cranial nerves VII and VIII cross the CPA before they enter the auditory canal, and lesions in this cistern can affect them. The cranial nerve VII is the most vulnerable where it can be directly compressed, stretched, or infiltrated by the tumour itself.⁷ CPA tumours which contribute to less than 10% of all posterior fossa tumours, are often secondary to the extension of tumours arising from the adjacent brainstem, cerebellar peduncle, and cerebellum. In addition, it can also stem from the direct extension of tumours originating in the fourth ventricle and lateral recess.⁴ These tumours can be either benign or malignant; thus, although rare, they are among the serious causes of facial nerve palsy, especially among children. A study of 44 infants and children with CPA tumours found equal distribution between malignant tumours [ependymomas, atypical teratoid rhabdoid tumour (ATRT), primitive neuroectodermal tumours (PNET), and glioblastomas] and benign tumours [pilocytic astrocytoma, epidermoid, meningiomas, nerve sheath tumours, and gangliogliomas].⁴ Half of them presented with signs and symptoms of hydrocephalus, such as headaches, vomiting, lethargy, and gait ataxia, and only 4.5% exhibited facial weakness. Other less common presentations include hearing loss, dysphagia/dysphonia, facial pain, sleep apnoea, and shoulder droop.⁴ The presentation itself reflected the structures, which were affected by the tumour in the small cistern, and the only definitive differentiation of the type of tumours can only be made by surgical resection and histological findings from tissue biopsy.

In our case, the child's main presentation was facial asymmetry. The subtle bilateral nystagmus was the only red flag presented and was the main turning point in the management of the case. Those with less experience may have

missed it. The bilateral nystagmus, otherwise known as Bruns nystagmus is distinctive of CPA tumours particularly those of a diameter more than 3.5 cm⁸ with the resultant distortion of the brainstem structures and compression of the flocculus and/or vestibulo-cerebellum.⁸ This is caused by multiple simultaneous impairments in different neural networks. It is depicted as an erratic nystagmus alternating between coarse, high-amplitude horizontal nystagmus with a low oscillatory frequency when gazing toward the side of the lesion, and fine, low-amplitude, high-frequency primary-position nystagmus when looking away from the side of the lesion.⁸ A coarse horizontal nystagmus occurs when the tumour compresses the ipsilateral pons which results in the dysfunction of the neural integrator and causes an inability to maintain the gaze toward the ipsilesional side (gaze paretic nystagmus). A concurrent vestibular dysfunction leads to decreased tonic firing, which results in a slow-phase movement towards the side of the lesion with a compensatory fast-beating component in the contralateral direction (vestibular nystagmus).⁸ This peculiar, rare variant nystagmus has a prevalence of 11% and is the key feature that may aid in the prompt clinical diagnosis of CPA tumours. Although rare, a bidirectional nystagmus may also be present in cases of pontine stroke and cerebellar apoplexy where the responsible structures are affected.⁸

Given that paediatric CPA tumours are relatively rare, the scarcity of studies on it is expected. Recent studies have suggested that the pathological spectrum of paediatric CPA tumours may be different from that of adults, and some suggest that age is a predictor of malignancy. A retrospective study involving 26 cases of CPA tumours found that malignant tumours tend to occur in younger children with a mean age of 4.4 years old whereas benign tumours occurred in older children with a mean age of 9 years old.⁵ In addition, malignancy may also be predicted from neuroimaging findings. In the case of facial nerve palsy, neuroimaging studies are not routinely performed unless features suggestive of the central pathology are present. It is meant to aid in the diagnosis as well as in the treatment plan. In this case, the detection of a subtle bidirectional bilateral nystagmus prompted the order of the CT brain. However, since the child improved on prednisolone and the absence of other signs, the provisional diagnosis of Bell's palsy seemed adequate and there was no need to push for urgent imaging.

A review of the literature showed that the cause of facial nerve paralysis was misdiagnosed in approximately 20% of the cases. The factors for these diagnostic errors may be multifaceted; however, the presence of a rare disease, atypical presentation, and failure to recognise physical examination findings are among the most common reasons.⁹ Other factors include false negatives or misinterpretations of neuroimaging studies. In our case, the initial CT brain showed an ill-defined hypodense area at the right cerebellar peduncle with a small faint area of hyperdensity. This was initially missed by our untrained eyes but was later picked up after being reviewed by a radiologist. Similar CT findings were shown in a study involving patients with CPA tumours, where 64% of them showed a mildly increased density on pre-contrast CT which was strongly associated with

malignant histology.⁵ Thus, it highlighted that in certain situations, the plain CT brain may also yield positive imaging results. In this case, the radiologist decided that a plain CT brain was sufficient to verify the presence of the CPA tumour, especially considering that the patient was a child, and it was not necessary to expose him to more contrast which may result in unnecessary complications and compromise his renal function. A subsequent MRI confirmed the presence of the CPA tumour in our patient with a clear view of the tumour showing plastic features with no clear margin. According to Phi et al., a tumour showing plastic features on MRI is highly suggestive of malignancy.⁵ Other features include multiple signal voids, the encasement of major arteries, widening of the lateral recess, focal cerebellar oedema, and hydrocephalus.⁵ Although the type and actual malignant status of the tumour can only be confirmed with a tissue biopsy, the features shown in the imaging favoured the malignant status. The ensuing rapid tumour growth causing hydrocephalus and death in a short period were also in favour of possible malignant histology.

From the literature, malignant CPA tumours are best managed by surgical resection, with the aim of complete resection of the malignant tissue without jeopardising the hearing and facial nerve function. However, the very complex anatomical structures of the cistern pose significant surgical challenges¹⁰ and result in high surgical morbidity and a poor long-term prognosis. Considering the size and all these challenges, the managing team in our case decided to defer the surgical intervention and suggested radiotherapy as the treatment option in the hope of reducing the size of the tumour. The literature shows that non-surgical treatment with fractionated radiotherapy is an option to reduce tumour size in the treatment of adult CPA schwannomas where the patient was not fit for surgery, to preserve hearing in cases of bilateral neurinomas, and post-resection with a subsequent relapse.¹¹ The cessation of tumour growth following radiation depends on the histological type, size, and location of the tumour.¹² Other non-surgical interventions include watchful waiting with serial tumour size surveillance and chemotherapy; however, these are options for tumours, which are small and benign.¹²

The uncertainties of the outcome drove parents to seek alternative treatments. Unfortunately, this is a common practice among the people in our community which only delays the treatment and worsens the outcome, as seen in this case where complications occur, leading to the demise of the child.

Conclusion and recommendation

As discussed above, facial nerve paralysis may arise from a broad spectrum of different aetiologies. Even though Bell's palsy is the most common aetiology of facial nerve paralysis, it remains the diagnosis of exclusion, and a high index of suspicion and thorough examination are needed to avoid missing sinister causes. Thus, it is imperative for health care professionals to be astute in their assessment of the patients, especially if the patient is a child, and be vigilant of other red flag signs in patients with peripheral facial palsy, as early

detection might lead to lower morbidity in the patients. In cases of uncertainty, it is better to err on the more cautious side and refer children with facial nerve palsy to paediatric oncologists for a second opinion in the light that, albeit rarely, it has very serious implications if CPA tumours are missed.

Source of funding

This research did not receive any specific grant from funding agencies in the public, commercial, or not-for-profit sectors.

Conflict of interest

The authors have no conflicts of interest to declare.

Ethical approval

The authors certify that all required patient consent forms have been received. The parents have given their permission for the relevant information as well as the photo of the child to be published in the journal since it is necessary to show the lesion.

Authors' contributions

MTI collected the necessary case information, wrote the original draft, and obtained the images. The NSI conceptualised the case report, its aims, and reviewed the initial draft. RAR revised the manuscript critically for intellectual content and edited the case for the final submission. All authors critically reviewed and approved the final draft and are responsible for the content and similarity index of the manuscript.

Acknowledgment

We thank the Director General of the Ministry of Health, Malaysia and the patient's parents for their consent for the writing of this case. We would also like to thank the Department of Radiology, Hospital Sultanah Bahiyah, Kedah, Malaysia for their contribution to the images.

References

1. Heckmann JG, Urban PP, Pitz S, Guntinas-Lichius O, Gágyor I. The diagnosis and treatment of idiopathic facial paresis (Bell's palsy). *Dtsch Arztebl Int* 2019; 116(41): 692–702.
2. Jenke AC, Stoek LM, Zilbauer M, Wirth S, Borusiak P. Facial palsy: etiology, outcome and management in children. *Eur J Paediatr Neurol* 2011; 15(3): 209–213.
3. Ciorba A, Corazzi V, Conz V, Bianchini C, Aimoni C. Facial nerve paralysis in children. *World J Clin Cases* 2015; 3(12): 973–979.
4. Tomita T, Grahovac G. Cerebellopontine angle tumors in infants and children. *Childs Nerv Syst* 2015; 31(10): 1739–1750.
5. Phi JH, Wang KC, Kim IO, Cheon JE, Choi JW, Cho BK, et al. Tumors in the cerebellopontine angle in children: warning of a high probability of malignancy. *J Neuro Oncol* 2013; 112(3): 383–391.
6. Özkale Y, Erol İ, Saygı S, Yılmaz İ. Overview of pediatric peripheral facial nerve paralysis: analysis of 40 patients. *J Child Neurol* 2015; 30(2): 193–199.
7. Portelinha J, Passarinho MP, Costa JM. Neuro-ophthalmological approach to facial nerve palsy. *Saudi J Ophthalmol* 2015; 29(1): 39–47.
8. Biswas SN, Ray S, Ball S, Chakraborty PP. Bruns nystagmus: an important clinical clue for cerebellopontine angle tumours. *BMJ Case Rep* 2018; 2018:bcr-2017-223378.
9. Bacorn C, Fong NST, Lin LK. Misdiagnosis of Bell's palsy: case series and literature review. *Clin Case Rep* 2020; 8(7): 1185–1191.
10. Rauniyar S, Gu J, Wang L, Shen Z, Meng Q, Xie S, et al. Cerebellopontine angle tumors: surgical and non-surgical outcomes in a cohort 321 cases. *Acta Sci Neurol* 2020; 3(6): 59–74.
11. Maire JP, Darrouzet V, Trouette R, Galli FS, Causse N, Demeaux H, et al. Fractionated radiation therapy in the treatment of cerebello-pontine angle neurinomas: 12 years of experience in 29 cases. *J Radiosurg* 1999; 2(1): 7–11.
12. Shohet JA, Talavera F, Gianoli GJ, Meyers AD. *Skull base tumor and other CPA tumors treatment & management*. Medscape; 18 June 2020. Available at: <https://emedicine.medscape.com/article/883090-treatment>. [Accessed 29 July 2021].

How to cite this article: Ismail MT, Rahman RA, Idris NS. When paediatric facial nerve paralysis is not a Bell's palsy: A case of cerebellopontine angle tumour. *J Taibah Univ Med Sc* 2022;17(1):141–145.