

## AcrySof toric intraocular lens for post-keratoplasty astigmatism

*Nishant Gupta, Jagat Ram, Manish Chaudhary*

We report a 63-year-old male who had undergone left eye optical penetrating keratoplasty for central leucomatous corneal opacity 10 years earlier. The eye had clear donor graft with residual astigmatism of  $-6.50$  diopter cylinder (DC) at  $30^\circ$ . The patient underwent clear corneal phacoemulsification with implantation of  $+6.0$  D spherical equivalent AcrySof SN60T9 intraocular lens (IOL). Postoperatively, at 10 months, the patient had distance corrected visual acuity of 20/30 with  $-2.00$  DC at  $20^\circ$ . AcrySof toric IOL offers an effective treatment option for post-

keratoplasty high corneal astigmatism in patients with cataract.

**Key words:** AcrySof SN60T9, cataract, phacoemulsification, post-keratoplasty astigmatism, toric intraocular lens

**Cite this article as:** Gupta N, Ram J, Chaudhary M. AcrySof toric intraocular lens for post-keratoplasty astigmatism. *Indian J Ophthalmol* 2012;60:213-5.

### Access this article online

#### Quick Response Code:



#### Website:

[www.ijo.in](http://www.ijo.in)

#### DOI:

10.4103/0301-4738.95875

Department of Ophthalmology, Advanced Eye Centre, PGIMER, Chandigarh, India

**Correspondence to:** Dr. Jagat Ram, Advanced Eye Centre, PGIMER, Chandigarh – 160012, India. E-mail: [drjagatram@yahoo.com](mailto:drjagatram@yahoo.com)

**Manuscript received:** 16.11.10; **Revision accepted:** 18.06.11

Phacoemulsification with implantation of foldable toric intraocular lens (IOL) has become the preferred management option in patients with high corneal astigmatism with coexistent cataract. Various treatment options available for patients with post-keratoplasty high corneal astigmatism in patients with

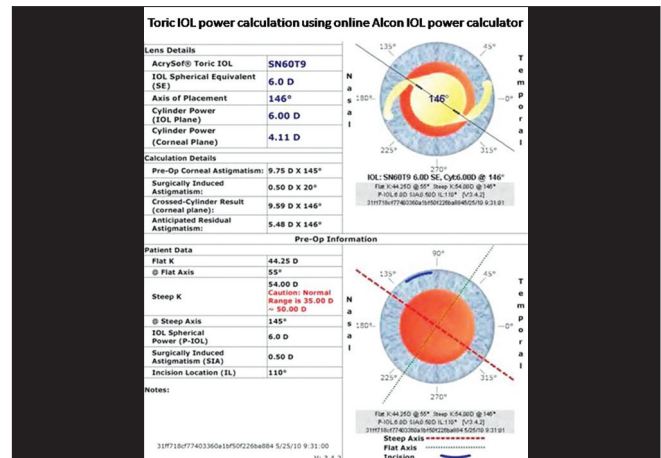
coexistent cataract are spectacles, toric contact lenses, rigid gas permeable lenses,<sup>[1]</sup> arcuate keratotomy with compression sutures<sup>[2]</sup> or astigmatic keratotomy with femtosecond laser,<sup>[3]</sup> photorefractive keratectomy,<sup>[4]</sup> laser-assisted *in situ* keratomileusis (LASIK),<sup>[5,6]</sup> intracorneal ring segments<sup>[7]</sup> and presently toric IOLs.<sup>[8-12]</sup> Artisan<sup>[8,9]</sup> and intraocular collamer lens (ICL)<sup>[10,11]</sup> of STAAR Surgicals have been used for the post-keratoplasty high astigmatism. Phacoemulsification with minimal surgically induced astigmatism with AcrySof toric IOLs offers an effective management option in patients with coexistent cataract. AcrySof toric IOL with improved rotational stability is effective for high corneal astigmatism.<sup>[13]</sup> Various studies have shown the postoperative rotational stability of the AcrySof toric IOLs in patients with high astigmatism.<sup>[13]</sup> PubMed search showed ours as the first case report of phacoemulsification with implantation of AcrySof toric IOL for post-keratoplasty high corneal astigmatism.

## Case Report

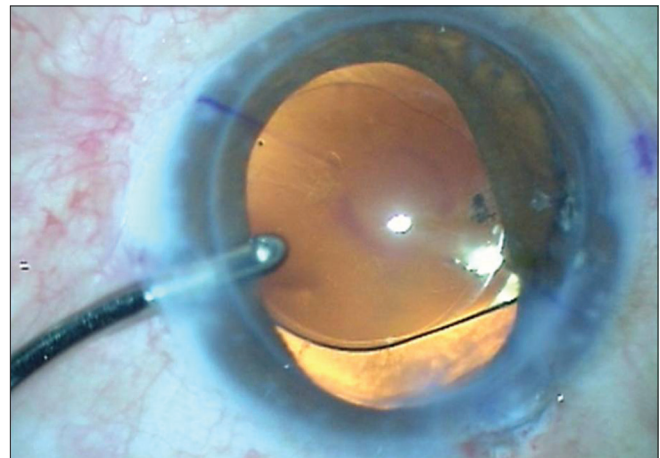
A 63-year-old male presented with complaints of gradually progressive painless diminution of vision in the left eye since last 1 year. The patient had undergone left eye optical penetrating keratoplasty 10 years back for leucomatous corneal opacity post corneal ulcer, managed medically.

The patient presented to us with visual acuity of 6/36 in the left eye with astigmatism of  $-6.50$  diopter cylinder (DC) at  $30^\circ$  and unaided visual acuity of 6/9 in the right eye. Intraocular pressure measured with Goldmann applanation tonometer was 16 and 18 mmHg.

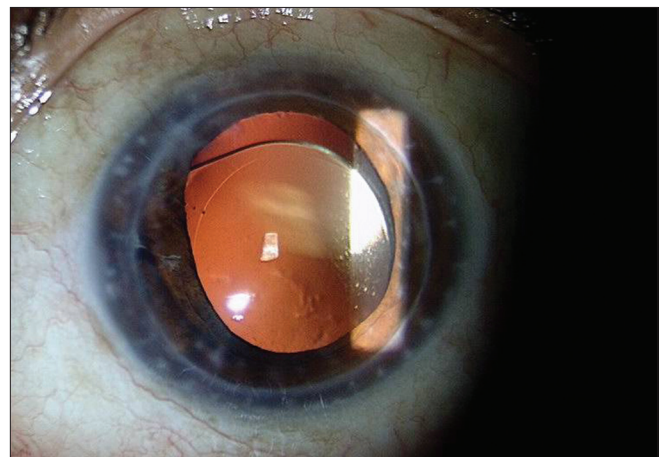
Slit-lamp examination of the left eye revealed clear, full thickness corneal graft of around 8 mm diameter with no graft edema, and cataract of nuclear colour (NC) and nuclear opalescence (NO) of grade 4. Early morning ultrasound pachymetry was  $526 \mu\text{m}$  for the left eye and  $546 \mu\text{m}$  for the right eye. A complete ophthalmological examination including refraction, pentacam for corneal topography, specular microscopy and pachymetry, biometry, IOL selection and systemic investigations were performed. Preoperative, endothelial cell count was  $1450 \text{ cells}/\text{mm}^2$  on specular microscopy. IOL Master keratometry readings of  $K_1$  44.25 D at  $55^\circ$ ,  $K_2$  54.0 D at  $145^\circ$  with preoperative corneal astigmatism of  $+9.75$  DC at  $145^\circ$  and average keratometry reading of 49.13 D were used for IOL power calculation. As per the calculation, the IOL recommended was AcrySof SN60T9 spherical equivalent  $+6$  D with residual cylindrical power of 5.48 D at  $146^\circ$  at the corneal plane [Fig. 1]. The patient underwent clear corneal phacoemulsification using Infiniti, Ozil system after markings for AcrySof toric IOL, with special surgical considerations for the corneal graft. Incision was placed at  $110^\circ$  with AcrySof toric IOL marks aligned along  $146^\circ$ . The preoperative 3, 6 and 9 o'clock markings were made with Nuijts reference corneal marker under topical anaesthesia with the patient sitting upright. Upright reference markings were applied to avoid supine cyclo-torsion. Intraoperatively, location of the corneal incision and axis of IOL placement was marked using Mendez ring and Nuijts toric axis marker.



**Figure 1:** Preoperative intraocular lens power calculation for AcrySof SN60T9 was spherical equivalent  $+6$  D with residual cylindrical power of 5.48 D at  $146^\circ$  at the corneal plane



**Figure 2:** Capsular bag implanted toric intraocular lens (IOL) at the end of surgery after viscoelastic removal. Note the position of toric IOL marks on the optic



**Figure 3:** Postoperatively at 10 months, there was clear corneal graft and no rotation of intraocular lens was noted

Two clear corneal side-port incisions were made at 2 and 9 o'clock hour positions. Graft endothelium was coated with Viscoat, Alcon (3% sodium hyaluronate + 4% chondroitin sulfate) and anterior chamber formed with Healon GV, AMO (Arshinoff soft shell technique). Triplanar clear corneal incision was made at 110°. Well-centered, approximately 5-mm continuous curvilinear capsulorrhexis was completed. Multi-quadrant hydrodissection was done and nucleus rotated. In the bag, nuclear emulsification was done with direct chop technique followed by cortical material removal. Care was taken to avoid sudden decompression of the anterior chamber throughout the surgery. Capsular bag was filled with Healon GV and IOL implanted into capsular bag with the axis of the IOL aligned around 15° short of the final axis of alignment (146°). Viscoelastic removal was done along with final rotation of the IOL, and the axis aligned [Fig. 2]. Side ports and clear corneal incisions were hydrated. Postoperatively, the patient was reviewed on day 1, 3, 14 days, 6 weeks, 4 ½ months and 10 months. On the immediate postoperative day, the corneal graft was clear with well-formed anterior chamber with 1+ cellular reaction, and well-centered aligned IOL with an intraocular pressure of 13 mmHg in Goldmann applanation tonometer. Refraction 6 weeks postoperative was -2.0 DC at 20°, vision improving to 20/30 on Snellen visual acuity chart. There was clear corneal graft and no rotation of IOL was noted. The patient was examined at 10 months follow-up and has best-corrected visual acuity (BCVA) of 20/30 and no rotation of toric IOL [Fig. 3]. Endothelial cell count was 1110 cells/mm<sup>2</sup>. Intraocular pressure was 14 mmHg.

## Discussion

At present, toric IOL provides an effective management option for the correction of post-keratoplasty high astigmatism and cataract.<sup>[8-12]</sup>

Nuijts *et al.*<sup>[8]</sup> implanted Artisan phakic toric IOL for the correction of post-keratoplasty high corneal astigmatism in 36 eyes of 35 patients and achieved an average of 88.8% reduction of astigmatism. But there was continued loss of the endothelial cells till 3 years of follow-up. Two patients developed irreversible graft rejection while one developed corneal decompensation. Akcay *et al.*<sup>[10]</sup> reported the use of ICL, a posterior chamber phakic toric IOL, for post-keratoplasty astigmatism. They reported marked reduction of astigmatism. No serious complication or refractive shift occurred at 1 year post surgery follow-up. The above authors have used phakic toric IOLs.

In our patient with post-keratoplasty high corneal astigmatism with coexisting cataract, we used AcrySof toric IOL. This patient achieved BCVA of 6/9 with astigmatism of -2 DC at 20° (astigmatism reduced to roughly one third) with clear corneal graft. There was no postoperative rotation of IOL

noted till 10 months post surgery. The better refractive result than that calculated can be explained as after keratoplasty, the biomechanical response of the corneal scleral tissue to the incision may be somewhat unpredictable, and a greater variability in surgically induced astigmatism may be seen.<sup>[8]</sup>

In conclusion, AcrySof toric IOL provides excellent correction of post-keratoplasty high corneal astigmatism in patients with coexistent cataract.

## References

1. Michaud L, Barriault C, Dionne A, Karwatsky P. Empirical fitting of soft or rigid gas-permeable contact lenses for the correction of moderate to severe refractive astigmatism: a comparative study. *Optometry* 2009;80:375-83.
2. Chang SM, Su CY, Lin CP. Correction of astigmatism after penetrating keratoplasty by relaxing incision with compression suture: a comparison between the guiding effect of photokeratoscope and of computer-assisted videokeratography. *Cornea* 2003;22:393-8.
3. Bahar I, Levinger E, Kaiserman I, Sansanavudh W, Rootman DS. Intralase-enabled astigmatic keratotomy for postkeratoplasty astigmatism. *Am J Ophthalmol* 2008;146:897-904.
4. Bilgihan K, Ozdek SC, Akata F, Hasanreisoglu B. Photorefractive keratectomy for post-penetrating keratoplasty myopia and astigmatism. *J Cataract Refract Surg* 2000;26:1590-5.
5. Busin M, Zambianchi L, Garzzone F, Macione V, Rossi S. Two-stage laser in situ keratomileusis to correct refractive errors after penetrating keratoplasty. *J Refract Surg* 2003;19:301-8.
6. Vajpayee R, Sharma N, Sinha R, Bhartiya P, Titiyal JS, Tandon R. Laser in-situ keratomileusis after penetrating keratoplasty. *Surv Ophthalmol* 2003;48:503-14.
7. Arriola-Villalobos P, Díaz-Valle D, Güell JL, Iradier-Urrutia MT, Jiménez-Alfaro I, Cuiña-Sardiña R, *et al.* Intrastromal corneal ring segment implantation for high astigmatism after penetrating keratoplasty. *J Cataract Refract Surg* 2009;35:1878-84.
8. Nuijts RM, Abhilakh Missier KA, Nabar VA, Japing WJ. Artisan toric lens implantation for correction of postkeratoplasty astigmatism. *Ophthalmology* 2004;111:1086-94.
9. Tahzib NG, Cheng YY, Nuijts RM. Three year follow-up analysis of Artisan Toric Lens implantation for correction of Postkeratoplasty Ametropia in Phakic and Pseudophakic eyes. *Ophthalmology* 2006;113:976-84.
10. Akcay L, Kaplan AT, Kandemir B, Gunaydin NT, Dogan OK. Toric intraocular Collamer lens for high myopic astigmatism after penetrating keratoplasty. *J Cataract Refract Surg* 2009;35:2161-3.
11. Chang J, Lau S. Toric intraocular Collamer lens for high myopic astigmatism Asian Eyes. *Ophthalmology* 2009;116:2340-7.
12. Moshirfar M, Feilmeier MR, Kang PC. Implantation of Verisyse phakic intraocular lens to correct myopic refractive error after penetrating keratoplasty in pseudophakic eyes. *Cornea* 2006;25:107-11.
13. Mendicutie J, Irigoyen C, Aramberri J, Ondarra A, Montés-Micó R. Foldable toric intraocular lens for astigmatism correction in cataract patients. *J Cataract Refract Surg* 2008;34:601-7.