

## Radiofrequency ablation is a treatment option for early stages of verrucous esophageal carcinoma

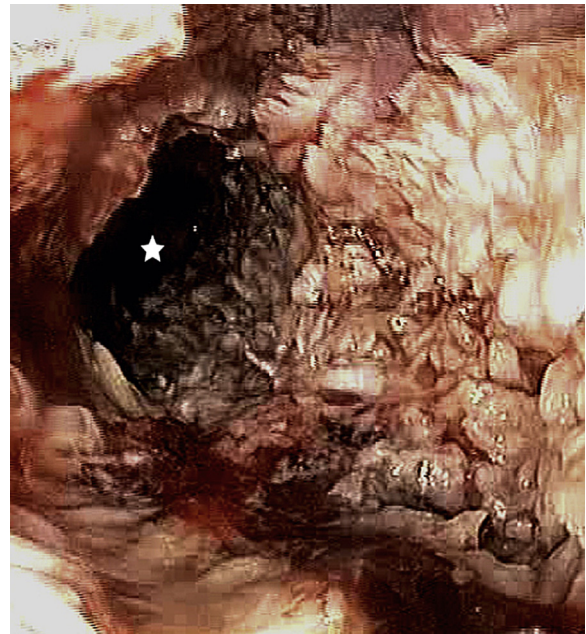

Richard F. Knoop, MD,<sup>1</sup> Hans-Juergen Richter-Schrag, MD,<sup>1</sup> Steffen Heeg, MD,<sup>1</sup> Jens Hoepfner, MD,<sup>2</sup> Andreas Fischer, MD<sup>1</sup>

A 47-year-old man with stenosing verrucous carcinoma of the mid and distal esophagus (Figs. 1 and 2) underwent an abdominothoracic esophagectomy.<sup>1</sup> The resection was complicated by severely hardened periesophageal inflammation tissue. Therefore, the initially intended total esophagectomy with a collar anastomosis was abandoned intraoperatively in favor of a subtotal resection with an intrathoracic anastomosis 27 cm from the incisors.

Staging and grading showed G1pT2pN0(0/15) LOVOPnOR0 status (Figs. 3 and 4). At day 15, the patient was discharged in good clinical condition after an uneventful postoperative course.<sup>1</sup> During the follow-up period, an endoscopy initially showed a regular postoperative result with normal esophageal mucosa and an unsuggestive anastomosis (Video 1, available online at [www.VideoGIE.org](http://www.VideoGIE.org)). However, 22 months after the operation, another endoscopy revealed suggestive, disseminated, white spot-like lesions affecting the entire remaining esophageal mucosa (Fig. 5 and Video 1, available online at [www.VideoGIE.org](http://www.VideoGIE.org)). As suspected, pathologic examination confirmed the recurrence of verrucous carcinoma in the entire remaining esophagus. A penetration depth of up to 500  $\mu\text{m}$  (pT1a) was determined on the basis of biopsy specimens (taken by Jumbo Biopsy Forceps, Endo-Flex, Voerde, Germany); the histologic evaluation was conducted by a calibrated eyepiece.

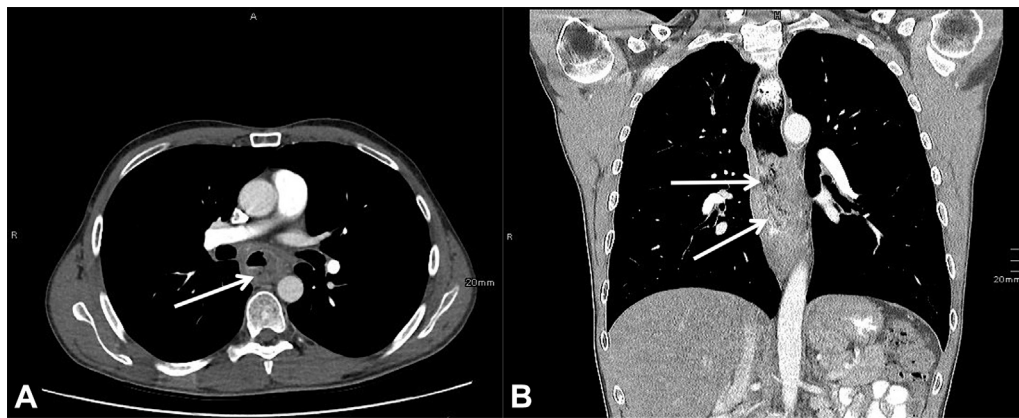
Subsequently, the interdisciplinary consensus with the attending surgeons was to attempt an interventional endoscopic approach to postpone or even avoid a second tumor resection. Given that the mucosa was affected only superficially (500  $\mu\text{m}$ ), radiofrequency ablation (RFA), with a known penetration depth of 800  $\mu\text{m}$  to 1000  $\mu\text{m}$ , seemed to be a promising option.<sup>2</sup> Within an interval of 3 months, 2 consecutive RFA sessions (Fig. 6 and Video 1, available online at [www.VideoGIE.org](http://www.VideoGIE.org)) were performed by use of the Barrx 90 and the Barrx 60 RFA Focal Catheter (Covidien, Mansfield, Mass). The standard ablation regimen was chosen, 2 applications of energy (15 J/cm<sup>2</sup>) were given, the ablation zone was cleaned, and 2 additional applications of energy were given according to the Van Vilsteren simplified ablation method.<sup>3,4</sup>



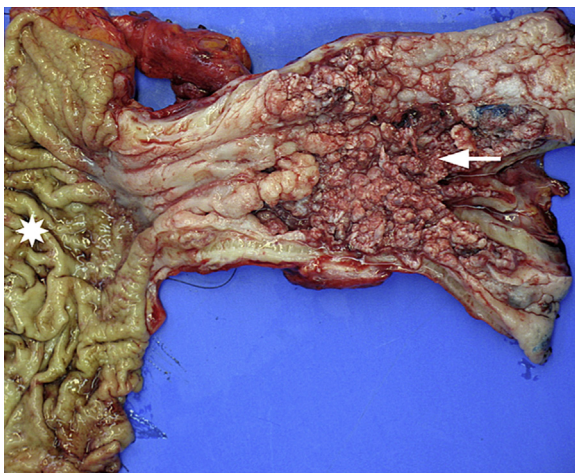
**Figure 1.** Upper endoscopic view before operation, showing a thickened, contact-vulnerable, exophytic, and lumen-constricting verrucous mass in the esophagus over a distance of 15 cm (*asterisk* = esophageal lumen). (From Kulemann B, Fischer A, Hoepfner J. Esophageal stenosis caused by a rare entity. *Gastroenterology* 2014;146:618-871. Used with permission.)

After that, stepwise biopsy specimens were taken from the remaining esophagus, the examination of which demonstrated unsuggestive mucosa but a persisting small recurrence of the verrucous carcinoma at the level of the esophagogastrostomy (Fig. 7). Because of the very localized extent of the latter, ablation with argon plasma coagulation (MABS-GIT 2.3 mm, KLS Martin, Tuttlingen, Germany), with maximum 30 W, flow 0.6 L/min, was conducted twice within an interval of 2 months. Further control determinations still remained suggestive of relapse of verrucous carcinoma limited to this site only (Fig. 8).

The case was again discussed with the interdisciplinary tumor board. Precise external radiation therapy was suggested, with the aim of exclusively irradiating the area of anastomosis to preserve an exit strategy for a second surgi-



**Figure 2.** CT scans with contrast enhancement showing long-segment thickening of the thoracic esophagus (*arrows*) without signs of lymphadenopathy or metastases.



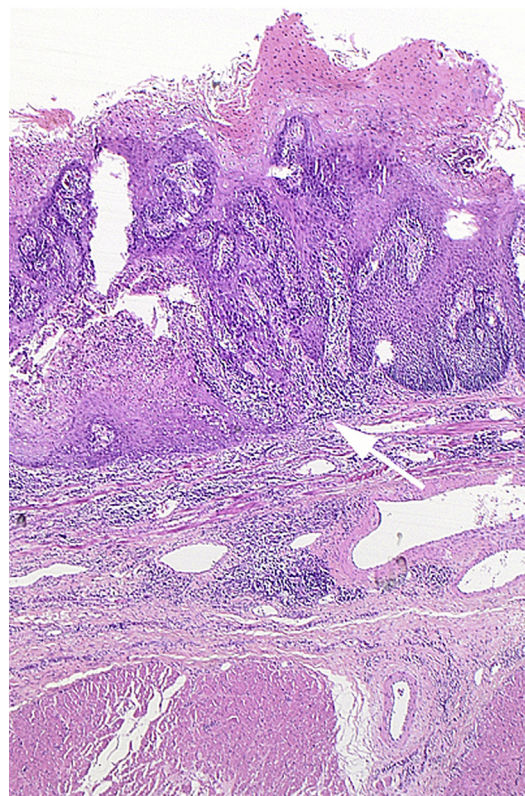
**Figure 3.** Surgical specimen with hyperkeratotic, exophytic growth of the tumor (*arrow*) and normal esophageal tissue (*asterisk*). (From Kulemann B, Fischer A, Hoepfner J. Esophageal stenosis caused by a rare entity. *Gastroenterology* 2014;146:618-871. Used with permission.)

cal resection in terms of a colonic interposition. In this case, an esophagocolostomy could be performed as a collar anastomosis in a nonirradiated proximal esophagus remnant. For this purpose, EGD was used to mark the area of anastomosis with a lipiodol injection for exact localization in the radiation treatment planning. High-precision radiation of this site was then performed over a period of 2 months with single doses of 1.8 Gy and a total dose of 55.8 Gy.

Since then, the remaining esophagus that was not irradiated, for the reasons mentioned, has remained free of tumors for 18 months (Fig. 9 and Video 1, available online at [www.VideoGIE.org](http://www.VideoGIE.org)).

## BACKGROUND AND DISCUSSION

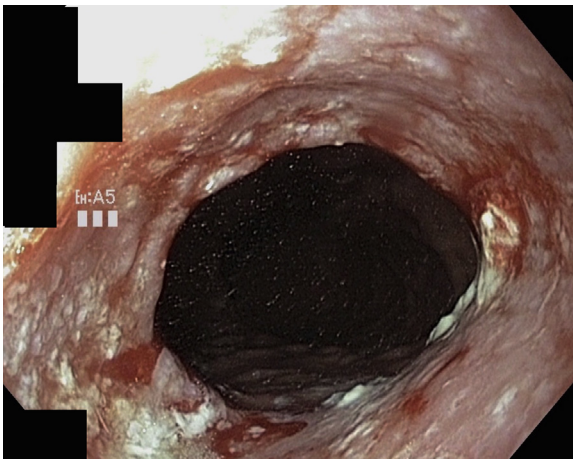
Verrucous carcinoma of the esophagus is very rare; only approximately 25 cases have been reported worldwide. Consequently, only limited data are available, and treat-



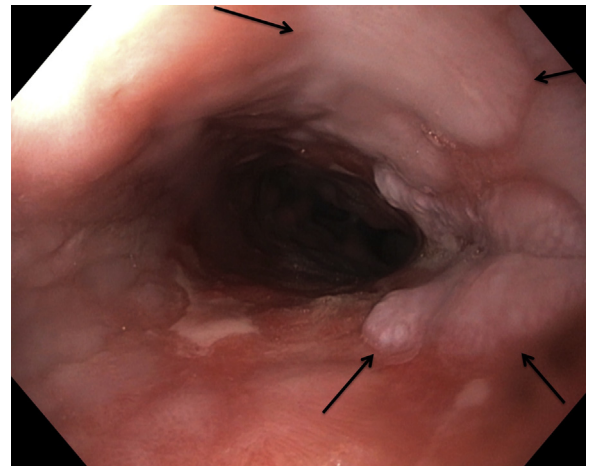
**Figure 4.** Microscopic view of verrucous esophageal carcinoma showing invasive characteristics (*arrow*). (From Kulemann B, Fischer A, Hoepfner J. Esophageal stenosis caused by a rare entity. *Gastroenterology* 2014;146:618-871. Used with permission.)

ment approaches should be individualized in agreement with the patient. The leading symptoms are odynophagia and dysphagia followed by weight loss. As a result of the histopathologic resemblance of this entity to that of esophageal squamous cell carcinoma, the diagnostic and therapeutic standards of the latter have been adopted.<sup>5</sup> This applies particularly to local endoscopic therapy.<sup>6</sup> Although classified as a variant of squamous cell

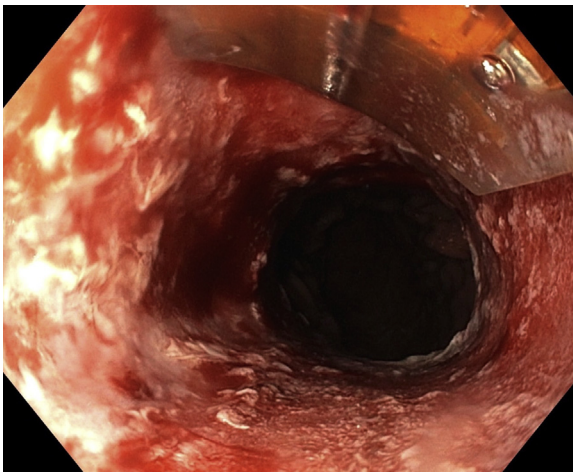




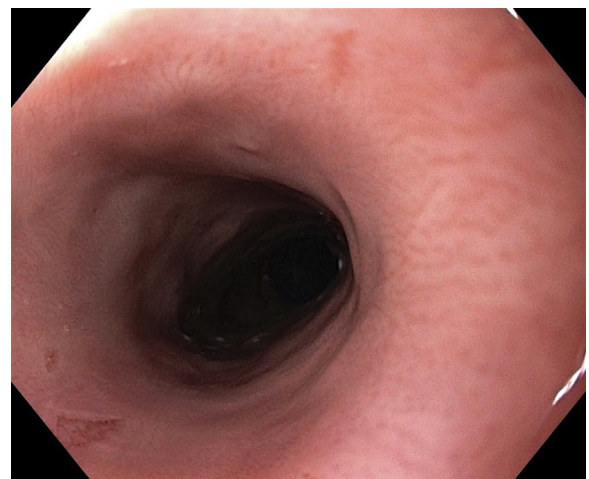
**Figure 5.** Early disseminated recurrence of verrucous carcinoma in the remaining esophagus 22 months after esophageal resection with intrathoracic esophagogastrostomy.



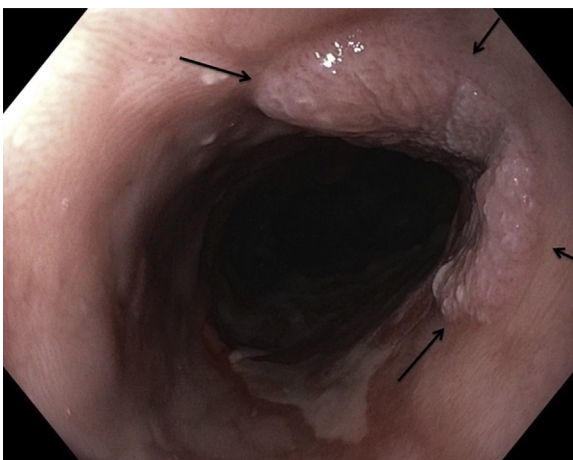
**Figure 8.** Persistent local recurrence limited strictly to the anastomotic site (*arrows*) after additional argon-plasma coagulation by use of a MABS-GIT probe.



**Figure 6.** Endoscopic radiofrequency ablation with use of a Barrx 90 RFA Focal Catheter.



**Figure 9.** The main part of the initially affected esophagus has remained free of tumor 18 months after radiofrequency ablation.



**Figure 7.** First local recurrence limited strictly to the anastomotic site 6 months after radiofrequency ablation (*arrows*).

carcinoma, esophageal verrucous carcinomas bear several specific characteristics. In particular, although locally spreading, they usually do not lead to lymph node involvement or distant metastasis and can therefore be characterized as semimalignant.<sup>5,6</sup> Furthermore, they show a much lower response to chemoradiotherapy.<sup>6</sup> Those are also the main reasons why initial neoadjuvant therapy was not provided to our patient.

Endoscopic radiofrequency ablation is a well-validated therapy for dysplastic Barrett's disease, and it also has become increasingly accepted for early squamous cell carcinoma of the esophagus.<sup>2,7,8</sup>

In our case, relapsing verrucous carcinoma involved the whole circumference of the remaining esophagus. On that account and because of an entire lack of lifting at the anastomotic site, neither EMR nor endoscopic submucosal dissection was considered feasible as a therapeutic option.

RFA led to complete tumor remission except in the area of anastomosis. The reasons for this might be that the penetration depth was too deep (>800 µm) at the anastomotic site or that the anastomotic tissue was too uneven for a tight connection between the RFA catheter and the esophageal wall.

However, RFA was very effective except from the anastomotic area because of the previously mentioned reasons. In case of an early verrucous esophageal carcinoma (<800-µm invasion depth) and good transmission of thermal energy, RFA seems to be an effective treatment option.

## CONCLUSIONS

To the best of our knowledge, this is the first report demonstrating the efficacy of RFA in early-stage verrucous esophageal carcinoma. Because of its slow and semimalignant growth, RFA treatment appears to be acceptable to prevent or at least postpone the need for surgery.

## DISCLOSURE

*All authors disclosed no financial relationships relevant to this publication.*

## REFERENCES

1. Kulemann B, Fischer A, Hoepfner J. Esophageal stenosis caused by a rare entity. *Gastroenterology* 2014;146:618-871.
2. Becq A, Camus M, Rahmi G, et al. Emerging indications of endoscopic radiofrequency ablation. *United European Gastroenterol J* 2015;3: 313-24.
3. van Vilsteren FG, Phoa KN, Alvarez Herrero L, et al. A simplified regimen for focal radiofrequency ablation of Barrett's mucosa: a randomized multicenter trial comparing two ablation regimens. *Gastrointest Endosc* 2013;78:30-8.
4. van Vilsteren FG, Bergman JJ. Endoscopic therapy using radiofrequency ablation for esophageal dysplasia and carcinoma in Barrett's esophagus. *Gastrointest Endosc Clin N Am* 2010;20:55-74, vi.
5. Sweetser S, Jacobs NL, Wong Kee Song LM. Endoscopic diagnosis and treatment of esophageal verrucous squamous cell cancer. *Dis Esophagus* 2014;27:452-6.
6. Behrens A, Stolte M, Pech O, et al. Verrucous oesophageal carcinoma: single case report and case series including 15 patients - issues for consideration of therapeutic strategies. *Viszeralmedizin* 2014;30:346-52.
7. Pouw RE, Gondrie JJ, Curvers WL, et al. Successful balloon-based radiofrequency ablation of a widespread early squamous cell carcinoma and high-grade dysplasia of the esophagus: a case report. *Gastrointest Endosc* 2008;68:537-41.
8. Coron E, Robaszekiewicz M, Chatelain D, et al. Advanced precancerous lesions in the lower oesophageal mucosa: high-grade dysplasia and intramucosal carcinoma in Barrett's oesophagus. *Best Pract Res Clin Gastroenterol* 2013;27:187-204.

Department of Medicine II, Interdisciplinary Gastrointestinal Endoscopy (1), Department of General and Visceral Surgery (2), Faculty of Medicine, University Hospital Freiburg, University of Freiburg, Freiburg, Germany.

Copyright © 2016 The Authors. Published by Elsevier, Inc. on behalf of the American Society for Gastrointestinal Endoscopy. This is an open access article under the CC BY-NC-ND license (<http://creativecommons.org/licenses/by-nc-nd/4.0/>).

<http://dx.doi.org/10.1016/j.vgje.2016.09.008>