



Effect of Drinking Warm Water on Esophageal Preparation Before Peroral Endoscopic Myotomy in Patients With Achalasia

Hong Jin Yoon,¹ Young Hoon Youn,^{2*} Sung Hwan Yoo,² Seyeon Jeon,² and Hyojin Park²

¹Department of Internal Medicine, Soonchunhyang University College of Medicine, Cheonan, Chungcheongnam-do, Korea; and ²Department of Internal Medicine, Gangnam Severance Hospital, Yonsei University College of Medicine, Seoul, Korea

Background/Aims

Food retention, which is a characteristic observed in patients with achalasia, can interfere with peroral endoscopic myotomy (POEM). However, there is no established guideline for esophageal preparation for POEM. A previous study has shown that drinking warm water may reduce the lower esophageal sphincter pressure in patients with achalasia. This study aims to evaluate the possibility of proper preparation of POEM by instructing the patient to drink warm water.

Methods

The warm water preparation was performed in 29 patients with achalasia who underwent POEM. The patients drank 1 L of warm water (60°C) the night before POEM. We evaluated the esophageal clearness and determined the preparation quality. Twenty-nine patients were prospectively recruited and compared to control group. The control cohort comprised achalasia patients whose endoscopic image was available from the achalasia database of our institution. A 1:2 propensity score-matched control cohort was established from the database of achalasia subjects (n = 155) to compare the outcome of the preparation.

Results

In the warm water preparation group, only 1 patient (3.4%) had some solid retention, but it did not interfere with the POEM procedure. The grade of clearness ($P = 0.016$) and quality of preparation ($P < 0.001$) were significantly better in the warm water preparation group than in the matched control group. There was no any adverse event at all related to warm water preparation protocol.

Conclusions

Drinking warm water dramatically reduces esophageal food retention and significantly improves the quality of esophageal preparation. This simple protocol is quite useful, safe, and cost-effective in the preparation of achalasia patients for POEM.

(*J Neurogastroenterol Motil* 2022;28:231-236)

Key Words

Esophageal achalasia; Esophageal sphincter, Lower; Peroral endoscopic myotomy; Water

Received: June 4, 2021 Revised: None Accepted: July 14, 2021

© This is an Open Access article distributed under the terms of the Creative Commons Attribution Non-Commercial License (<http://creativecommons.org/licenses/by-nc/4.0>) which permits unrestricted non-commercial use, distribution, and reproduction in any medium, provided the original work is properly cited.

*Correspondence: Young Hoon Youn, MD, PhD

Department of Internal Medicine, Gangnam Severance Hospital, Yonsei University College of Medicine, 211 Eonjuro, Gangnam-gu, Seoul 06273, Korea
Tel: +82-2-2019-3453, Fax: +82-2-3463-3882, E-mail: DRYOUN@yuhs.ac

Introduction

Recently, peroral endoscopic myotomy (POEM) has been widely used as an endoscopic treatment method for patients with achalasia.¹ The nature of achalasia can cause food or fluid retention in the esophagus.² Therefore, patients with achalasia are more likely to develop aspiration pneumonia than general patients during endoscopic procedures. Yang et al³ reported that in 52 patients who had undergone pre-POEM endoscopy, approximately half had residual esophageal contents.³ Some authors reported that aspiration pneumonia was observed in 0.04–1.16% of patients during POEM procedures,^{4,5} while the incidence of respiratory infections after endoscopy under sedation was 0.1% in the general population.⁶ Also, esophageal food retention significantly interferes with POEM procedures, in terms of poor mucosal visualization and possible mediastinal contamination. However, guidelines for proper esophageal preparation before POEM do not exist. Large quantities of food frequently remain in the esophagus after routine overnight fasting for upper endoscopy in patients with achalasia. Proper esophageal preparation is essential to ensure patient safety and adequate visualization of the esophageal mucosa and to optimize a successful POEM procedure.

Clinically, warm water intake relieves the symptoms of a patient with achalasia. Winship et al⁷ reported that warm water intake would facilitate the transit of propagated waves, shorten the duration of the distal esophageal contraction, and decrease the amplitude of the lower esophageal sphincter (LES) after contraction.⁷ Ren et al⁸ reported the changes in esophageal motility to warm temperature in untreated achalasia patients using high-resolution esophageal manometry. Warm water could reduce the LES resting pressure, assist LES relaxation, shorten the contraction duration of the esophageal body, and relieve achalasia symptoms.⁸ Drinking warm water may help in providing a cleaner esophagus in a patient with achalasia than simply fasting.

This study aims to evaluate the possibility of warm water drinking for proper esophageal preparation prior to POEM.

Materials and Methods

Study Cohort

For the initial pilot study, we prospectively recruited 12 patients with achalasia who underwent POEM at Gangnam Severance Hospital from June 2019 to June 2020. These patients drank warm

water the night before POEM. The degree of esophageal clearness was evaluated by endoscopy before performing the POEM procedure. The control cohort comprised achalasia patients whose endoscopic image was available from the achalasia database of our institution. Among the 155 patients, we excluded 12 patients whose endoscopic images or reports were not available. A propensity score-matched control group was established comprising of 24 patients whose age, sex, achalasia subtype, and history of previous treatment (balloon dilatation and botulinum toxin injection) were matched to those in the study group. In the control cohort, the grade of esophageal clearness was retrospectively reviewed using endoscopic images and reports.

With favorable preparation outcomes from the initial pilot study, we continued the warm water preparation in subsequent 17 patients. Finally, the warm water preparation was performed in 29 patients. In the same way as the pilot study, a 1:2 propensity score-matched cohort was established. This study was approved by the Institutional Review Board of Gangnam Severance Hospital (No. 3-2019-0104).

Esophageal Preparation

In the warm water preparation group, the patients drank 1 L of warm water at 60°C during 30 minutes at 8 PM the day before the POEM. Moreover, the patient had nothing to eat or drink after midnight the evening before the procedure in both the warm water preparation group and the control group.

The degree of clearness of the esophagus was compared with that of the control cohort, in which the patients underwent endoscopic procedures without warm water preparation. We defined the esophageal clearness scale for assessment of esophageal preparation quality (Table 1). Grades 0 to 3 were defined as follows: 0 = the entire mucosa of the esophagus can be clearly observed without residual staining; 1 = minor amount of residual staining with opaque liquid can be observed, but the entire esophageal mucosa can be easily observed just by endoscopic suction; 2 = a portion of the

Table 1. Esophageal Clearness Grade

Preparation quality	Grade	Characteristic	Mucosal visualization
Good	0	Clear	Entire mucosa
	1	Liquid retention	Most of the mucosa
Poor	2	Some solid retention	Part of the mucosa
	3	Large amount of solid retention	Not observed

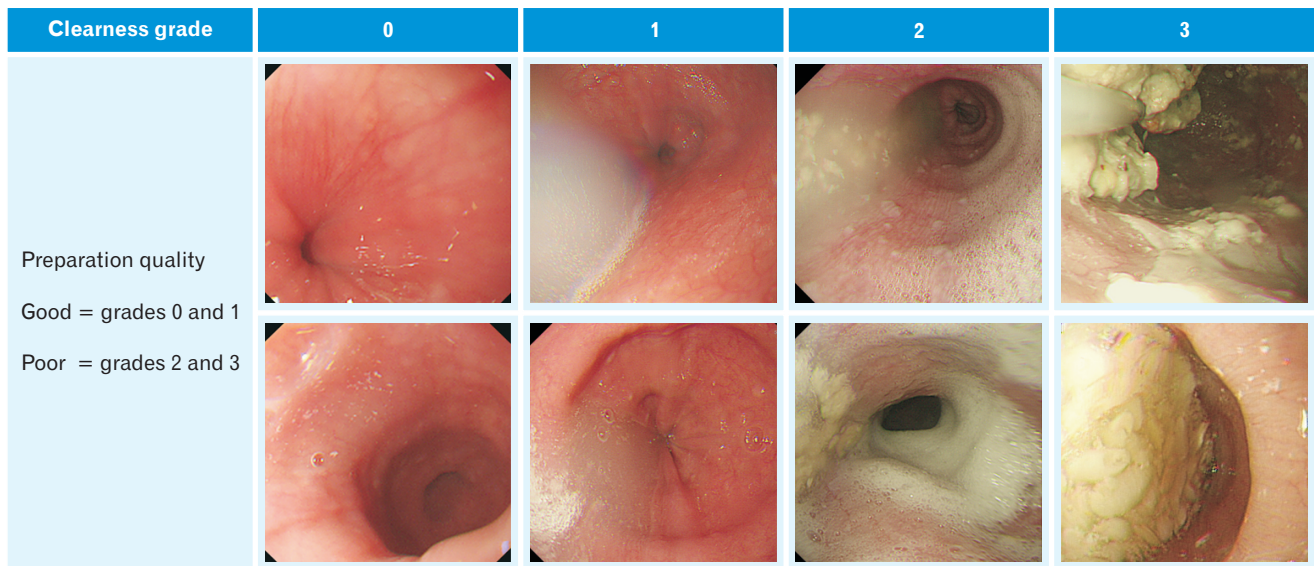


Figure. Representative case of different endoscopic preparation grades for patients with achalasia.

Table 2. Baseline Characteristics of and Preparation Outcomes in Initial Pilot Study

Variables	Warm water preparation (n = 12)	Control (n = 143)	P-value
Male	3 (25.0)	64 (44.8)	0.756
Age (yr)	42.3 ± 15.0	44.2 ± 17.1	0.793
Previous treatment	4 (33.3)	75 (52.4)	0.475
Achalasia type			0.599
Type I	3 (25.0)	40 (28.0)	
Type II	9 (75.0)	91 (63.6)	
Type III	0 (0.0)	12 (8.4)	
Clearness grade			0.274
Grade 0	2 (16.7)	54 (37.7)	
Grade 1	10 (83.3)	48 (33.6)	
Grade 2	0 (0.0)	21 (14.7)	
Grade 3	0 (0.0)	20 (14.0)	
Preparation quality			0.019
Good	12 (100.0)	102 (71.3)	
Poor	0 (0.0)	41 (28.7)	

Data are presented as n (%) or mean ± SD.

mucosa of the esophagus can be observed, but residual solid food retention hinders the observation of the entire esophageal mucosa; and 3 = an unprepared esophagus with the mucosa cannot be observed due to large quantity of solid retention that cannot be cleared by endoscopic suction.

Figure shows the representative endoscopic images of each esophageal clearness scale. Grades 0 and 1 indicate that the qual-

Table 3. Baseline Characteristics of and Preparation Outcomes in the 1:2 Propensity Score-matched Cohort of Initial Pilot Study

Variables	Warm water preparation (n = 12)	Control (n = 24)	P-value
Male	3 (25.0)	6 (25.0)	> 0.999
Age (yr)	42.3 ± 15.0	44.7 ± 17.5	0.685
Previous treatment	4 (33.3)	8 (33.3)	> 0.999
Achalasia type			> 0.999
Type I	3 (25.0)	6 (25.0)	
Type II	9 (75.0)	18 (75.0)	
Clearness grade			0.041
Grade 0	2 (16.7)	4 (16.7)	
Grade 1	10 (83.3)	9 (37.5)	
Grade 2	0 (0.0)	6 (25.0)	
Grade 3	0 (0.0)	5 (20.9)	
Preparation quality (n, %)			0.006
Good	12 (100.0)	13 (54.2)	
Poor	0 (0.0)	11 (45.8)	

Data are presented as n (%) or mean ± SD.

ity of preparation is good, which is a state adequate for endoscopic therapeutic procedures. Grades 2 and 3 indicate that the quality of preparation is poor, which is a state inadequate for endoscopic therapeutic procedures.

Statistical Methods

The Fisher’s exact test was used to examine the associations among categorical variables. The Mantel–Haenszel test was used

for ordinal variables, and the independent 2 sample *t* test was used for the non-categorical variables. A *P*-value < 0.05 was considered statistically significant. The Statistical Package for the Social Sciences version 12.0 (IBM Corp, Armonk, NY, USA) and Statistical Analysis System version 9.4 (SAS Institute, Cary, NC, USA) were used for all analyses.

Results

The baseline characteristics and preparation outcomes of the 2 groups for pilot study (initial 12 patients) are shown in Table 2. The warm water preparation group comprised of 3 male and 9 female patients with a mean age of 42.3 years. In the control group before propensity score matching (*n* = 143), a total of 64 (44.8%) males were included, with a mean age of 44.2 years. Moreover, 4 of the 12 patients (33.3%) in the warm water preparation group and 75 of the 143 patients (52.4%) in the control group previously underwent balloon dilatation. Most of the patients in the preparation group (83.3%) showed clearness grade 1. In the control group, clearness grade 1 was observed in 33.6% of patients. However, there was no statistical difference in clearness grade between the warm water preparation group and the control group (*P* = 0.274). The preparation quality was better in the warm preparation group than that in the control group (100.0% vs 71.3%, *P* = 0.019). We also compared the warm water preparation group with the 1:2 propensity score-matched cohort control group (*n* = 24). Patients from the control group were statistically matched to those of the warm water preparation group with regard to the following factors: age, sex distribution, previous balloon dilatation, and achalasia subtype. Table 3 shows the baseline characteristics and preparation outcomes of the 1:2 well-balanced, propensity score-matched cohort. The warm water preparation group showed better clearness grade than the control group (*P* = 0.041). Preparation quality was significantly better in the preparation group than that in the control group (100.0% vs 54.2%, *P* = 0.006).

Table 4 shows the baseline characteristics and preparation outcomes of the total study cohort including initial pilot and follow up study (*n* = 29). There was some solid retention in 1 of 29 patients, but it did not interfere with the POEM procedure. When compared to the 1:2 propensity score-matched cohort control group, the warm water preparation group showed better clearness grade than the control group (*P* = 0.016). Preparation quality was significantly better in the preparation group than that in the control group (96.6% vs 44.8%, *P* ≤ 0.001). For 2 years of the study period, none of the patients in the warm preparation group experienced any adverse

Table 4. Baseline Characteristics of and Preparation Outcomes in the 1:2 Propensity Score-matched Cohort of Follow-up Study

Variables	Warm water preparation (n = 29)	Control (n = 58)	<i>P</i> -value
Male	19 (65.5)	19 (65.5)	> 0.999
Age (yr)	44.7 ± 15.1	41.1 ± 16.5	0.327
Previous treatment	7 (24.1)	7 (24.1)	> 0.999
Achalasia type			> 0.999
Type I	10 (34.5)	6 (34.5)	
Type II	18 (62.1)	18 (62.1)	
Type III	1 (3.4)	1 (3.4)	
Clearness grade			0.016
Grade 0	2 (6.9)	5 (17.2)	
Grade 1	26 (89.7)	8 (27.6)	
Grade 2	1 (3.4)	9 (31.0)	
Grade 3	0 (0.0)	7 (24.2)	
Preparation quality			< 0.001
Good	28 (96.6)	13 (44.8)	
Poor	1 (3.4)	16 (55.2)	

Data are presented as *n* (%) or mean ± SD.

event from drinking warm water.

Discussion

Achalasia is characterized by abnormal relaxation of LES and absent or abnormal peristalsis of the esophageal body, and the impaired esophageal transit induces symptoms of achalasia, such as dysphagia, regurgitation, chest pain, and weight loss.⁹ Endoscopic examination in patients with achalasia often shows food retention in the esophagus, even after overnight fasting. Esophageal food retention is considered a significant problem because it hinders the precise observation of the esophageal mucosa, interferes with the endoscopic therapeutic procedure, and increases the risk of aspiration. Aspiration of fluid and food contents during endoscopic procedure may induce pneumonia, other pulmonary infections, or even death in patients with achalasia. In general preparations before endoscopic procedures, a patient is instructed not to eat or drink after midnight the evening before the procedure. However, in some patients with achalasia, fasting alone is insufficient to achieve optimal preparation. Additionally, POEM is performed under general anesthesia and is different from conventional endoscopy that is performed under conscious sedation.³ There is a risk of aspiration pneumonia due to esophageal and gastric content reflux during induction of general anesthesia when performing positive pressure ventilation with a face mask¹⁰ and during the process of intubation. Furthermore, POEM

procedures creates a submucosal tunnel and cuts the esophageal proper muscle; thus, even a small amount of esophageal food retention can contaminate the mediastinum and cause serious infection. Hence, clean esophageal preparation is especially important in POEM.

Fasting is essential before induction of general anesthesia or upper gastrointestinal endoscopy owing to the risk of aspiration pneumonia caused by reflux of the gastroesophageal contents. In general, 6-8 hours of fasting is required before general anesthesia induction.¹¹ Depending on the protocol of each institution, patients may fast either 24 hours before POEM or from midnight on the day of the procedure.^{4,12} In a study in which the patients continued on a clear liquid diet for 48 hours followed by a midnight fast before undergoing the POEM procedure, solid residues were observed in 37.0% of the patients.⁴

The need for pre-inspection by separate endoscopy to remove retained food in the esophagus is controversial.¹⁰ Inoue et al¹³ recommended that a few days of fasting and endoscopic cleaning should be performed prior to POEM, specifically for patients with sigmoid type achalasia. Endoscopic cleaning before POEM may be the most reliable method. However, several studies in which aspiration pneumonia associated with POEM has not occurred have questioned its necessity.⁴ Unnecessary costs and procedures can be avoided if reliable esophageal preparation can be achieved by means other than additional pre-inspection endoscopy.

The effects of temperature on esophageal motor function have been studied since about 50 years ago.¹⁴ Triadafilopoulos et al¹⁵ investigated the effects of warm water drinking in patients with esophageal motility disorders using esophageal scintigraphy and conventional esophageal manometry. Clinically, drinking cold water can cause dysphagia or chest pain in some patients with achalasia. In contrast, some patients with achalasia tend to improve their esophageal symptoms after drinking warm water. Esophageal clearance was accelerated in esophageal scintigraphy, and esophageal body contractions were decreased by drinking warm water in manometry.¹⁵ Catalano et al¹⁶ investigated manometric monitoring while administering wet swallows with warm and cold water boluses to patients with esophageal motility disorders. Warm bolus showed normal amplitude peristaltic contraction, while cold bolus showed low-amplitude aperistaltic contraction.¹⁶ The exact mechanism by which temperature alternates esophageal motor and sensory function in achalasia is not yet clearly known.

This study showed that simple warm water drinking protocol was significantly effective and useful for adequate preparation for POEM. Although the number of subjects was small, all achalasia

patients who complied with the warm water drinking protocol showed good clearness of the esophagus for POEM. This warm water preparation protocol was tolerable in all patients without any adverse events and would also be easily applied at any institution, with little costs.

This study has several limitations. First, the number of study subjects, 29 in the warm water preparation group was relatively small, and moreover, only 1 case of type III achalasia was included in the preparation group, which was collected prospectively. Hence, further experience and validation are required with a larger patient population. Second, although the warm water preparation group was prospectively recruited, the control group was retrospectively reviewed from the database of a single center. Hence, possible selection bias may have affected the clinical outcomes. We tried to overcome this bias by creating a propensity score-matched control cohort. Despite these limitations, we believe that this warm water preparation method will be of great practical help in the POEM procedure in hospitals worldwide. To the best of our knowledge, this study is the first to compare the clinical outcomes of warm water intake in esophageal preparation before POEM.

In conclusion, warm water is feasible and sufficient for achieving adequate esophageal preparation before POEM by temporarily improving esophageal motility in patients with achalasia. Warm water preparation is effective, easy, safe, and cost-effective. It also enables optimal preparation for POEM while reducing the cost and risk of additional endoscopy before POEM.

Financial support: None.

Conflicts of interest: None.

Author contributions: Hong Jin Yoon, Sung Hwan Yoo, and Seyeon Jeon acquired data; Hong Jin Yoon and Young Hoon Youn analyzed and interpreted data; Hong Jin Yoon, Sung Hwan Yoo, and Seyeon Jeon prepared figure, drafted, and revised the manuscript; Young Hoon Youn and Hyojin Park designed and supervised the study; and all authors read and approved the final manuscript.

References

1. Kroch DA, Grimm IS. POEM for achalasia. *Am Surg* 2018;84:489-495.
2. Youn YH, Minami H, Chiu PWY, Park H. Peroral endoscopic myotomy for treating achalasia and esophageal motility disorders. *J Neurogastroenterol Motil* 2016;22:14-24.
3. Yang D, Pannu D, Zhang Q, White JD, Draganov PV. Evaluation of anesthesia management, feasibility and efficacy of peroral endoscopic

- myotomy (POEM) for achalasia performed in the endoscopy unit. *Endoscopy international open* 2015;3:E289-E295.
4. Nishihara Y, Yoshida T, Ooi M, Obata N, Izuta S, Mizobuchi S. Anesthetic management and associated complications of peroral endoscopic myotomy: a case series. *World J Gastrointest Endosc* 2018;10:193-199.
 5. Goudra B, Singh PM, Gouda G, Sinha AC. Peroral endoscopic myotomy-initial experience with anesthetic management of 24 procedures and systematic review. *Anesth Essays Res* 2016;10:297-300.
 6. Friedrich K, Scholl SG, Beck S, et al. Respiratory complications in outpatient endoscopy with endoscopist-directed sedation. *J Gastrointest Liver Dis* 2014;23:255-259.
 7. Winship D, De Andrade SV, Zboralske F. Influence of bolus temperature on human esophageal motor function. *J Clin Invest* 1970;49:243-250.
 8. Ren Y, Ke M, Fang X, et al. Response of esophagus to high and low temperatures in patients with achalasia. *J Neurogastroenterol Motil* 2012;18:391-398.
 9. Ates F, Vaezi MF. The pathogenesis and management of achalasia: current status and future directions. *Gut and liver* 2015;9:449-463.
 10. Bang Y-S, Park C. Anesthetic consideration for peroral endoscopic myotomy. *Clin Endosc* 2019;52:549-555.
 11. Apfelbaum J, Caplan R, Connis R, Epstein B, Nickinovich D, Warner M; American Society of Anesthesiologists Committee. Practice guidelines for preoperative fasting and the use of pharmacologic agents to reduce the risk of pulmonary aspiration: application to healthy patients undergoing elective procedures: an updated report by the American Society of Anesthesiologists Committee on Standards and Practice Parameters. *Anesthesiology* 2011;114:495-511.
 12. Tanaka E, Murata H, Minami H, Sumikawa K. Anesthetic management of peroral endoscopic myotomy for esophageal achalasia: a retrospective case series. *J Anesth* 2014;28:456-459.
 13. Inoue H, Shiwaku H, Iwakiri K, et al. Clinical practice guidelines for peroral endoscopic myotomy. *Dig Endosc* 2018;30:563-579.
 14. Respass J, Ingelfinger F, Kramer P, Hendrix T. Effect of cold on esophageal motor function. *Am J Med* 1956;20:955.
 15. Triadafilopoulos G, Tsang HP, Segall GM. Hot water swallows improve symptoms and accelerate esophageal clearance in esophageal motility disorders. *J Clin Gastroenterol* 1998;26:239-244.
 16. Catalano CJ, Bozyski EM, Orlando RC. Temperature-dependent symptoms in a patient with esophageal motor disease. *Gastroenterology* 1983;85:1407-1410.