

Dyke–Davidoff–Masson Syndrome: A Rare Cause of Acquired Cerebral Hemiatrophy

Abstract

Dyke–Davidoff–Masson syndrome is a rare disease of childhood which is clinically characterized by hemiparesis, refractory seizures, facial asymmetry, and mental retardation. The classical radiological findings are cerebral hemiatrophy, calvarial thickening, and hyperpneumatization of the frontal sinuses. Seizure refractory to medical management warrants surgical intervention with excellent outcome. Here, we are reporting two such cases who presented late and diagnosis was made on the basis of magnetic resonance imaging brain features. Both of our children responded to oral anticonvulsant and are on regular follow-up.

Keywords: Calvarium thickening, cerebral hemiatrophy, Dyke–Davidoff–Masson syndrome, intellectual disability, seizures

**Deepak Bhol,
Shyam
Chandrasekar,
Joseph John,
Amit Kumar
Satapathy**

*Department of Pediatrics,
All India Institute of Medical
Sciences, Bhubaneswar, Odisha,
India*

Introduction

Dyke – Davidoff – Masson syndrome (DDMS) is characterized by hemiatrophy of cerebral hemisphere with ipsilateral hypertrophy of the skull and sinuses. It usually occurs due to an insult to the developing brain *in utero* or in postnatal period.^[1] Major causes are infection, trauma, birth asphyxia, intracranial hemorrhage, tumor, or prolonged febrile seizure. The clinical features vary depending on the extent of brain injury. They usually present with seizures, facial asymmetry, contralateral hemiplegia or hemiparesis, and intellectual disability. Seizures are mostly refractory and may appear months or years after the insult or onset of hemiparesis. Learning disabilities, impaired speech, and behavioral abnormalities are consistent findings in most of these children.^[2] Either side of the brain may be affected without any sex predilection. Major concern of the disease remains the intractable seizures, for which drug therapy is not sufficient in most cases, and a surgical approach may be required. Here, we are reporting two cases of DDMS who presented to us with refractory seizure.

Case Report

Case 1

A 10-year-old girl, born to nonconsanguineous parents, 2nd in birth order, presented with refractory seizures, intermittent drooling of saliva, and intellectual disability for 7 years of age. There was no history of significant antenatal or perinatal complications. She was developmentally normal till the onset of this illness and was not having any preceding head trauma, blood transfusion, or pain crisis. At 7 years of age, she had fever for 2 days followed by multiple episodes of generalized tonic-clonic seizures, each episode lasting up to for 3-4 min. Initially, the child was admitted and managed for seizure. Initially, it was 10-15 episodes every month, but gradually frequency decreased to 5-8 episodes per month. Seizures were both focal and generalized types and mostly precipitated by anxiety, sleep deprivation, fever, etc. Subsequently, she developed weakness of right upper and lower limb along with speech difficulty. Gradually, the child developed learning difficulty, slurred speech, facial deviation, and progressive left-sided weakness. She did not have hearing or vision problem. She was not on any regular medication.

On examination, she had spastic hemiplegic gait and right-sided facial palsy. Deep

Address for correspondence:

*Dr. Amit Kumar Satapathy,
Department of Pediatrics,
All India Institute of
Medical Sciences,
Bhubaneswar - 751 019,
Odisha, India.
E-mail: amitkumar.satapathy@
yahoo.co.in*

This is an open access journal, and articles are distributed under the terms of the Creative Commons Attribution-NonCommercial-ShareAlike 4.0 License, which allows others to remix, tweak, and build upon the work non-commercially, as long as appropriate credit is given and the new creations are licensed under the identical terms.

For reprints contact: WKHLRPMedknow_reprints@wolterskluwer.com

How to cite this article: Bhol D, Chandrasekar S, John J, Satapathy AK. Dyke–davidoff–masson syndrome: A rare cause of acquired cerebral hemiatrophy. *Asian J Neurosurg* 2021;16:579-81.

Submitted: 20-Nov-2020

Revised: 22-May-2021

Accepted: 13-Jun-2021

Published: 14-Sep-2021

Access this article online

Website: www.asianjns.org

DOI: 10.4103/ajns.AJNS_499_20

Quick Response Code:



tendon reflexes are exaggerated in right side with plantar extensor response. Other systemic examination was unremarkable. Her IQ score was 40 according to Stanford-Binet test.

On investigation, serum electrolytes, blood gas, lactate, blood sugar, calcium, liver, and kidney function tests were within normal limit. Magnetic resonance imaging (MRI) of brain suggested unilateral atrophy of the left cerebral hemisphere with ex vacuo dilatation of ipsilateral lateral ventricle and ipsilateral sulci prominence [Figure 1a and b]. There was subtle thickening of the left hemicranium, measuring 4.0 mm on the right side and 6–7 mm on left temporal lobe. There was midline shift of 4 mm toward same side. Mild atrophy of the left cerebral peduncle was also noticed. The above MRI findings along with the clinical presentation were fulfilling the criteria for DDMS.

She was started on sodium valproate, and dose was gradually increased to 30 mg/kg/day, but focal seizures were continued. After adding carbamazepine, seizure frequency decreased. On follow-up, seizure frequency decreased to 2–3 times per month. The child may need an increment of doses in future.

Case 2

A 10-year-old boy, born to nonconsanguineous parents, first in birth order, presented with one episode of left focal seizure with impaired awareness for 30 min. His birth and

family history was unremarkable. Parents noticed weakness of left side of bodies since early infancy which is static. He had intellectual disability with normal vision and hearing.

On examination, he had left-sided spastic hemiparesis without facial asymmetry. Deep tendon reflexes were brisk with extensor plantar response on left side. MRI brain revealed gliosis with cystic encephalomalacia in the right cerebral hemisphere causing ex-vacuo dilatation of right lateral ventricle, hemiatrophy of right cerebral hemisphere, cerebral peduncle and right side mid brain with mild calvarial hypertrophy suggestive of DDMS [Figure 2a, b and c]. The child was started on carbamazepine after which there were no further episodes of seizure. Physiotherapy and occupational therapy were initiated.

Discussion

Dyke, Davidoff, and Masson in 1933, first time described the plain skull radiographic and pneumatoencephalographic changes in a series of nine patients presented with hemiparesis, seizures, facial asymmetry, and mental retardation.^[1] It is characterized by asymmetry of cerebral hemisphere with atrophy or hypoplasia of one side along with midline shift, ipsilateral osseous hypertrophy and hyperpneumatization of sinuses mainly frontal and mastoid air cells. Cerebral hemiatrophy can be of two types. Primary (congenital) type, cerebral hemisphere is entirely hypoplastic, whereas secondary type results due to cerebrovascular lesion, inflammatory process, or head trauma.^[3] Clinical presentations include variable degree of facial asymmetry, seizures, contralateral hemiparesis, mental retardation, learning disabilities, and impaired speech. Seizures can be focal or generalized. Complex partial seizure with secondary generalization also had been reported. Age of presentation depends on time of insult and characteristic changes may be seen only in adolescence or adult. However, mental retardation was not always present, and seizures may appear months or years after the onset of hemiparesis like our second case.^[4] Although there is no predilection to any sex or hemisphere, male gender and left side involvement are more common.^[5]

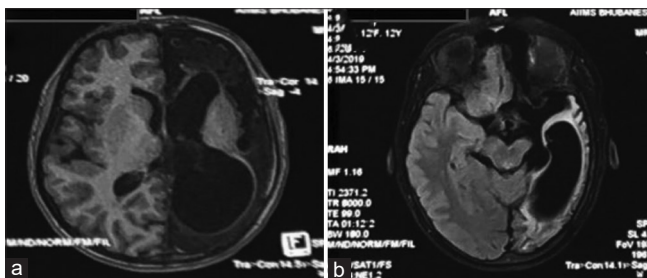


Figure 1: (a and b) Magnetic resonance imaging brain images in axial section showing hyperpneumatization of left frontal sinus with compensatory calvarial thickening of left side. Left cerebral hemiatrophy with dilated left lateral ventricle and midline shift to left side are also seen

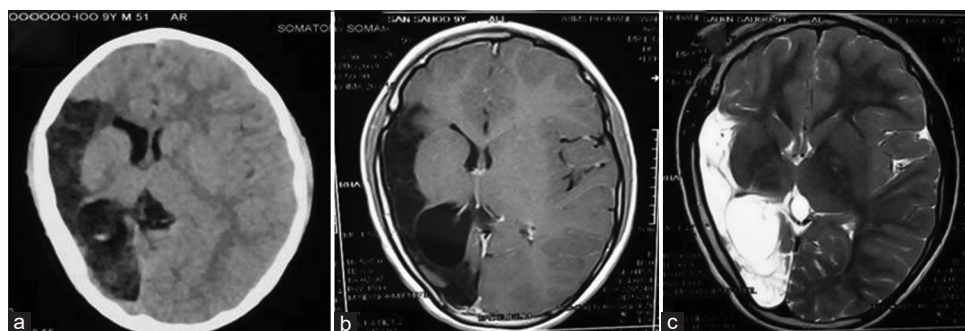


Figure 2: (a) Computed tomography of brain showing hemiatrophy of right cerebral hemisphere and midline shifting to right side. (b and c) Magnetic resonance imaging brain T2 flair images in axial section showing hemiatrophy of right cerebral hemisphere, cerebral peduncle, and mid brain with mild calvarial hypertrophy of right side and dilated right lateral ventricle. Focal encephalomalacia and gliotic changes are also noted

It was proposed that a vascular anomaly occurring in very early gestation (5 or 6 weeks) may result in a major defect in the brain development, whereas those occurring later may produce more localized lesions. It was reported that decrease in carotid artery flow due to coarctation of aorta can also cause cerebral hemiatrophy. The manifestations of DDMS may be so subtle as to be overlooked on plain radiographs; however, computed tomography/MRI is the diagnostic modality of choice.

A proper history, thorough clinical examination, and radiologic findings provide the correct diagnosis. This condition is to be differentiated from basal ganglia germinoma, Sturge–Weber syndrome, Silver-Russell syndrome, linear nevus syndrome, Fishman syndrome, and Rasmussen encephalitis.^[5]

The uniqueness of our cases lies in the fact that both the children were presented late with seizure though it is a disease of developing brain. Case 1 had seizure at 7 years of age with normal previous history, whereas case 2 presented at age of 10 with a history of delayed attainment of milestone.

Conclusion

Patients with DDMS usually present with refractory seizures and treatment should focus on control of the seizures with suitable anticonvulsants. Along with drugs, physiotherapy, occupational therapy, and speech therapy play a significant role in long-term management of the child. Prognosis is better if the onset of hemiparesis is after 2 years of age and in the absence of prolonged or recurrent seizure.^[6] Hemispherectomy is the treatment of choice for children with intractable disabling seizures and hemiplegia with a success rate of 85% in selected cases.^[7] As hemispherectomy is not available even in many tertiary care centers, it is very important to diagnose it early by means of suitable imaging and optimization of anticonvulsant to control of seizures, revision of drug doses from time to time, and domiciliary physiotherapy.

Informed consent

All appropriate patient consent forms signed from parents for child's images and other clinical information to be reported in the journal.

Declaration of patient consent

The authors certify that they have obtained all appropriate patient consent forms. In the form, the parents have given their consent for images and other clinical information to be reported in the journal. The parents understand that names and initials will not be published, and due efforts will be made to conceal identity, but anonymity cannot be guaranteed.

Financial support and sponsorship

Nil.

Conflicts of interest

There are no conflicts of interest.

References

1. Dyke CG, Davidoff LM, Masson CB. Cerebral hemiatrophy and homolateral hypertrophy of the skull and sinuses. *Surg Gynecol Obstet* 1933;57:588-600.
2. Ono K, Komai K, Ikeda T. Dyke-Davidoff-Masson syndrome manifested by seizure in late childhood: A case report. *J Clin Neurosci* 2003;10:367-71.
3. Alpers BJ, Dear RB. Hemiatrophy of the brain. *J Nerv Ment Dis* 1939;89:653-1.
4. Zilkha A. CT of cerebral hemiatrophy. *AJR Am J Roentgenol* 1980;135:259-62.
5. Unal O, Tombul T, Cirak B, Anlar O, Incesu L, Kayan M. Left hemisphere and male sex dominance of cerebral hemiatrophy (DDMS). *Clin Imaging* 2004;28:163-5.
6. Pendse NA, Bapna P, Menghani V, Diwan A. Dyke-Davidoff-Masson syndrome (DDMS). *Indian J Pediatr* 2004;71:943.
7. Narain NP, Kumar R, Narain B. Dyke-Davidoff-Masson syndrome. *Indian Pediatr* 2008;45:927-8.