



Lessons learned: Preventable misses and near-misses of endoscopic procedures

Alla Turshudzhyan, Houman Rezaizadeh, Micheal Tadros

Specialty type: Gastroenterology and hepatology

Provenance and peer review: Invited article; Externally peer reviewed.

Peer-review model: Single blind

Peer-review report's scientific quality classification

Grade A (Excellent): 0
Grade B (Very good): B
Grade C (Good): C
Grade D (Fair): 0
Grade E (Poor): 0

P-Reviewer: Hosoe N, Japan; Roma M, India

Received: November 4, 2021

Peer-review started: November 4, 2021

First decision: November 29, 2021

Revised: December 30, 2021

Accepted: April 21, 2022

Article in press: April 21, 2022

Published online: May 16, 2022



Alla Turshudzhyan, Department of Medicine, University of Connecticut, Farmington, CT 06030, United States

Houman Rezaizadeh, Department of Gastroenterology and Hepatology, University of Connecticut, Farmington, CT 06030, United States

Micheal Tadros, Department of Gastroenterology and Hepatology, Albany Medical College, Albany, NY 12208, United States

Corresponding author: Micheal Tadros, FACP, MD, Associate Professor, Department of Gastroenterology and Hepatology, Albany Medical College, 43 New Scotland Avenue, Albany, NY 12208, United States. tadrosml@amc.edu

Abstract

Endoscopy is a complex procedure that requires advanced training and a highly skilled practitioner. The advances in the field of endoscopy have made it an invaluable diagnostic tool, but the procedure remains provider dependent. The quality of endoscopy may vary from provider to provider and, as a result, is not perfect. Consequently, 11.3% of upper gastrointestinal neoplasms are missed on the initial upper endoscopy and 2.1%-5.9% of colorectal polyps or cancers are missed on colonoscopy. Pathology is overlooked if endoscopic exam is not done carefully, bypassing proper visualization of the scope's entry and exit points or, if exam is not taken to completion, not visualizing the most distal bowel segments. We hope to shed light on this issue, establish areas of weakness, and propose possible solutions and preventative measures.

Key Words: High-quality colonoscopy; Esophagogastroduodenoscopy; EGD; Cancer screening; endoscopy; Missed lesions

©The Author(s) 2022. Published by Baishideng Publishing Group Inc. All rights reserved.

Core Tip: Endoscopy has become a widely used diagnostic tool and plays an instrumental role in screening and surveillance of gastrointestinal pathology. Despite its wide acceptance, it remains provider dependent and, as a result, is not perfect. Both upper and lower endoscopy have weaknesses and shortcomings unless executed flawlessly. A high-quality endoscopy includes a complete examination of the bowel, including distal segments that are difficult to visualize, as well as scope's entry and exit points. Better understanding of the shortcomings of endoscopy may help change training and improve physician awareness.

Citation: Turshudzhyan A, Rezaizadeh H, Tadros M. Lessons learned: Preventable misses and near-misses of endoscopic procedures. *World J Gastrointest Endosc* 2022; 14(5): 302-310

URL: <https://www.wjgnet.com/1948-5190/full/v14/i5/302.htm>

DOI: <https://dx.doi.org/10.4253/wjge.v14.i5.302>

INTRODUCTION

Today, endoscopy is considered one of the best diagnostic tools for screening and surveillance of gastrointestinal pathology. Since the beginning of the 21st century, endoscopy use has risen by more than 50%[1]. With wider utilization of endoscopy, it has become more and more evident that the procedure quality is multifactorial and operator dependent[2]. Consequently, lesions may be missed depending on the level of provider training, procedural skills, and attentiveness to subtle pathology. This prompted development of several quality metrics to provide guidance for operators[3-7]. Despite proposed quality metrics, there is still a significant number of missed gastrointestinal cancers. A meta-analysis by Menon *et al*[8] suggested that 11.3% of upper gastrointestinal (UGI) neoplasms are overlooked on the initial upper endoscopy (EGD). Around 2.1%-5.9% of colorectal polyps or cancers are missed on colonoscopy[9]. The difference likely stems from the fact that endoscopic training has historically put emphasis on colorectal cancer prevention and screening, while there is usually less awareness around UGI neoplasms.

It should be noted that aside from neoplastic lesions, bleeding sources can be missed on endoscopy and only seen on repeat examination in patients with unexplained occult GI bleed or iron deficiency anemia with negative diagnostic work up[10]. Missed lesions on endoscopy are a common reason for malpractice lawsuits[11], which further emphasizes the importance of quality improvement. Some of the common reasons for why pathology is overlooked are a hastily performed endoscopy that bypasses proper visualization of the scope's entry and exit points, not taking endoscopic exam to completion, and not visualizing more distal bowel segments.

REVIEW

Using our personal experience with 4 patients who had lesions missed or near missed on endoscopy, we hope to expose some of the weaknesses and shortcomings of endoscopy. Our goal is to bring the attention of other gastroenterologists to these commonly missed areas that may go undetected.

Case 1

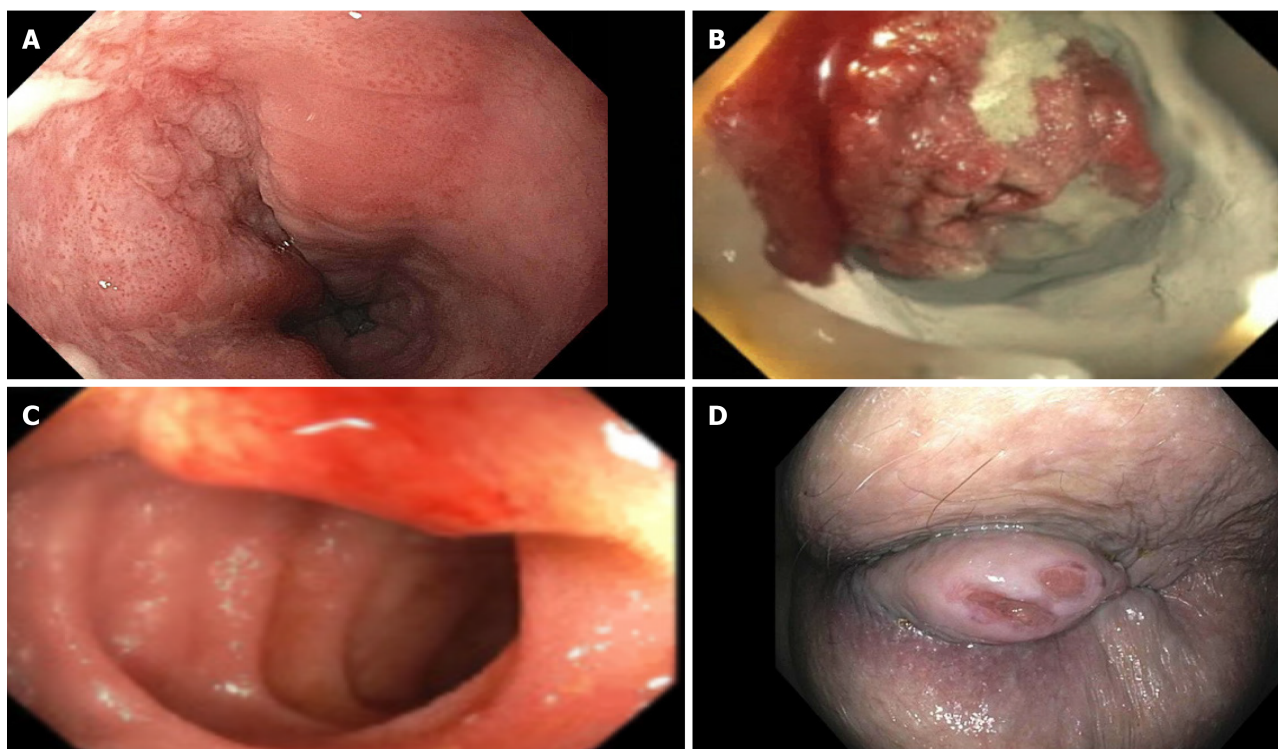
The first patient was a 72-year-old male who presented with symptoms of dysphagia. The initial EGD was unrevealing. It was only after the second EGD that a flat squamous cell carcinoma was appreciated 2 cm below the upper esophageal sphincter (UES) (Figure 1A, Figure 2A). The lesion was missed on the initial scope insertion and was likely missed because of a rapid scope withdrawal.

Case 2

The second patient was a 40-year-old female with iron deficiency anemia requiring multiple blood transfusions. The patient had undergone multiple upper and lower endoscopies and a capsule study, all of which were unrevealing. It was only after the 4th portion of the duodenum was examined that a malignant gastrointestinal stromal tumor was identified, diagnosed, and resected (Figures 1B and 2B).

Case 3

The third patient was a 50-year-old female who presented with ongoing diarrhea. Stool studies revealed cryptosporidium. Fortunately, the patient's colonoscopy included examination of the terminal ileum and was able to detect a small submucosal carcinoid tumor (Figures 1C and 2C). It was successfully resected with metastatic disease noted in only one lymph node.



DOI: 10.4253/wjge.v14.i5.302 Copyright ©The Author(s) 2022.

Figure 1 Endoscopic visualization of the lesions near missed. A: Subtle flat squamous cell carcinoma was appreciated 2 cm below the upper esophageal sphincter; B: Malignant gastrointestinal stromal tumor treated with hemospray in proximal jejunum; C: Small submucosal carcinoid tumor in terminal ileum; D: 2 cm anal squamous cell cancer noted on rectal exam.

Case 4

Our last patient was a 68-year-old with a history of cirrhosis and recurrent bright red blood per rectum. She had 2 colonoscopies done to find the bleeding source, both were unrevealing. It was months later that the patient had a 2 cm anal growth examined and diagnosed on careful retroflexion. The anal lesion was then seen on a reinspection of the anal area. (Figures 1D and 2D).

DISCUSSION

Increasing awareness of the bowel segments at risk for being missed on endoscopy is important. Similarly, it is important to incorporate technical maneuvers that could help identify these challenging lesions into fellowship training and post-graduate courses to help practicing endoscopists (Tables 1 and 2)[10]. Lastly, following the most recent endoscopy quality metrics will help improve the detection of challenging lesions.

Colonoscopy

A complete colonoscopy should include a thorough exam of the endoscope's entry point (anal canal), all segments of the colon, and, if possible, the distal ileum. We are going to discuss distal to proximal bowel segments as visualized on colonoscopy and use it as a framework to go over commonly missed lesions for each segment along with maneuvers and techniques that can help detect them.

Anorectum: Some of the commonly missed lesions in anorectum are anal and rectal cancer, anal fissures, recto cutaneous fistulas, anal warts (Table 1)[10]. This is likely because of the scopes entry point being overlooked or not properly visualized at the beginning of the procedure. The importance of anal examination by a skilled endoscopist is further emphasized by the fact that anorectal lesions can have a non-specific presentation and may go undiagnosed by patient's primary care physician. Chiu *et al*[12] found that only 54% of patients have a rectal examination by their primary care provider when they present with a non-specific anal complaint. Another study indicated that only 23% of patients presenting with anal complaint were diagnosed correctly by their primary care provider; the remaining patients were erroneously diagnosed with hemorrhoids[13]. As a result, this leads to delay in diagnosis and management of anal and rectal cancers. As proposed by quality metrics, digital rectal exam needs to be performed and thoroughly documented prior to colonoscopy (Table 2)[11]. Another maneuver that

Table 1 Commonly missed lesions requiring second-look colonoscopy[10,14-16] or upper endoscopy[10,20,24]

Bowel segment	Lesions missed	Intervention to improve lesion detection
Anorectum	Anal/rectal cancers Anal fissures Recto-cutaneous fistulas Anal warts	Careful anorectal exam before and on scope insertion with retroflexion
Colon	Lesions in colonic folds (particularly sigmoid) Right colon Cecum (especially behind IC valve)	Careful exam between the folds of the colon, especially in sigmoid segment, consider using a cap Excellent, good, or adequate bowel preparation, supported by photography Second look Retroflex in right colon Document examination Examine behind the ileocecal valve Cecal intubation rate
Terminal ileum	Lesions in ileum	Intubate in the terminal ileum
Esophagus	Below UES lesions, <i>i.e.</i> , squamous cell carcinoma Distal esophagus, collapsed varices in volume depleted patient Subtle lesions of Barrett segment	Careful examination of upper esophagus, slow scope withdrawal Careful examination of distal esophagus and awareness of patient's volume status Adequate time for examination of the segment
Stomach	Cameron lesions, gastro-esophageal junction (especially challenging to detect/examine with large hiatal hernias) Arteriovenous malformation, Dieulafoy's lesions	Careful examination of gastro-esophageal junction and diaphragmatic hiatus with retroflexion of the scope Careful inspection between the gastric folds using a cap
Small bowel	Duodenal bulb Duodenal sweep 3 rd and 4 th part of the duodenum	Examine all 4 walls of the duodenal bulb and May need to use of a side view scope Advance scope by reducing the loop into 3 rd and 4 th parts of duodenum

UES: Upper esophageal sphincter.

could be used to enhance detection of challenging lesions in anorectum is retroflexion. It allows for a better visualization of distal rectum and distal anus (Table 1)[14]. Retroflexion needs to be photographed and documented[11].

Colon: Some of the commonly missed lesion of colonic segment include lesions found inside the colonic folds (especially in sigmoid colon), right-sided colon, cecum [especially behind the ileocecal (IC) valve], and distal ileum (Table 1). There are a few techniques that can be implemented to facilitate detection of these challenging lesions (Table 1). Endoscopists should do a thorough examination between the haustral folds to avoid missing even large polyps that can hide inside the folds. Cap-assisted colonoscopy is another acceptable option as it involves a transparent attachment at the end of the scope that can improve adenoma detection rate (ADR) by flattening of the haustral folds and improving visualization of mucosa, especially on scope withdrawal[15].

Second look examination of the right side of the colon can help reduce the rate of cecal lesions missed [16]. Retroflexion in the right colon is another maneuver that can enhance visualization of right-sided lesions and improve ADR[14,16]. It entails bending of the scope in a U-turn such that viewing lens is facing backwards[14].

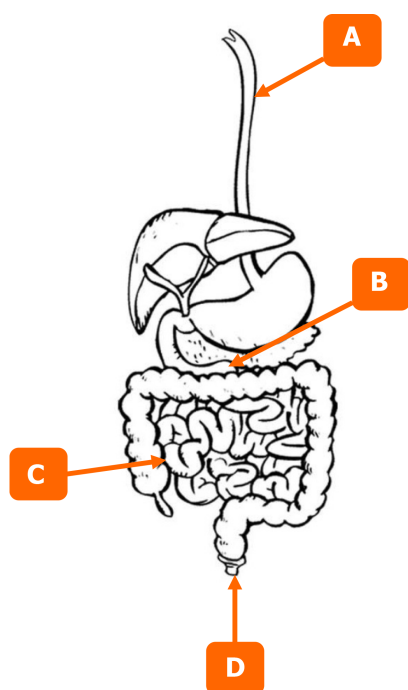
Cecum intubation is a very important skill and a quality measure that can enhance visualization of the cecum and identify lesions that are oftentimes missed. Additionally, endoscopists should pay particular attention to the mucosa behind the IC valve. Documentation of cecal landmarks is crucial.

All maneuvers discussed need to be thoroughly photographed and documented in the procedure description per the colonoscopy quality metrics (Table 2). Quality metrics further require bowel preparation to be excellent, good, or adequate and supported by photography and withdrawal time

Table 2 Quality metrics for endoscopic procedures[11,20,21,23,24]

Colonoscopy	EGD
High quality bowel preparation (excellent, good, or adequate), documented with photos	At least 1 min of inspection per centimeter of circumferential segment of Barrett's esophagus
Digital rectal examination prior to colonoscopy with results documented	NDR record should be considered
Cecal intubation performed, landmarks noted in documentation and photos recorded	When evaluating for gastric intestinal metaplasia, 5 or more biopsies need to be taken
Withdrawal time is 6 min or more	Overall, EGD evaluation for gastric intestinal metaplasia has to last 7 min or more
Retroflexion, if performed, is thoroughly documented (with photographs)	
Endoscopists ADR exceeds recommended thresholds. Physician participates in quality-improvement and continues to measure individual ADR	

EGD: Endoscopy; NDR: Neoplasia detection rate; ADR: Adenoma detection rate.



DOI: 10.4253/wjge.v14.i5.302 Copyright ©The Author(s) 2022.

Figure 2 Gastrointestinal tract segments at risk for having lesions missed. A: Upper esophageal sphincter; B: Proximal jejunum; C: Terminal ileum; D: Anus.

should be noted in documentation and exceed 6 minutes[11]. It is also encouraged that practicing endoscopist's adenoma detection rate (ADR) exceeds recommended thresholds. Physicians should routinely measure their ADR and participate in quality improvement programs[11].

The optimal withdrawal time for colonoscopy remains an important topic. A 6-minute withdrawal time was accepted, but a recent meta-analysis by Bhurwal *et al*[17] of 69551 patients compared withdrawal time of 6 vs 9 min in its ability to detect adenomas. They found that odds ratio for ADR was significantly higher at 1.54 for colonoscopies with withdrawal time of 9 min or more[17].

Terminal ileum: Lesions can be missed in terminal ileum as many colonoscopies do not investigate this bowel segment. It is important to note that the ileum is the most common site for development of carcinoid tumors (57%) and that even primary ileal tumors are missed on computer tomography (CT) scans in 64% of cases[18-20]. This emphasizes the importance of a thorough and complete endoscopic exam that may detect primary ileal tumors early and allow for timely intervention[20]. Endoscopists should try to intubate the terminal ileum whenever feasible.

Upper endoscopy

A complete EGD should entail a thorough exam of the esophagus, including the UES, point of entry into the stomach, other poorly visualized areas of the stomach, along with all segments of the duodenum. We are going to discuss distal to proximal bowel segments as visualized on EGD and use it as a framework to go over commonly missed lesions for each segment along with maneuvers and techniques to help detect them.

Esophagus: Some of the most commonly missed esophageal lesions are immediately below the UES and lesions in the distal esophagus (such as collapsed varices in a volume depleted patient or subtle changes of Barrett's segment) (Table 1)[10]. Some possible interventions to facilitate detection of challenging lesions are careful examination of the full length esophagus paying particular attention to upper and lower most segments, being aware of patient's volume status, and allotting adequate time for examination of the segment (Table 1). Quality metrics for Barrett's segment inspection time call for 1 minute inspection time per cm of circumferential length[21]. Longer inspection time results in a more careful visualization of the mucosa and subsequently increase chances of detecting pathology[21]. Another quality metric that is being proposed when examining esophagus is neoplasia detection rate (NDR)[22]. Like ADR for colonoscopy, it is important to keep track of NDR for EGD when examining for Barrett's segment, because it reflects the quality of inspection[22].

Stomach: Some of the common gastric lesions missed on EGD are Cameron lesions, lesions around gastro-esophageal (GE) junction (especially with large hiatal hernias), arteriovenous malformations, Dieulafoy lesions (Table 1). Some interventions that can be done are careful inspection of GE and diaphragmatic hiatus with retroflexion of the scope, inspection between gastric folds using the previously discussed cap-assisted endoscopy (Table 1)[23]. One of the EGD quality metrics that is important to remember is adequate number of gastric biopsies, which should be greater or equal to 5 [24]. Timing is another important quality metric. Examination time during EGD when looking for intestinal metaplasia should be longer than 7 min, because longer inspection implies a more careful exam and results in a higher rate of neoplasia detection[25]. Park *et al*[25] observed that slow endoscopists (defined as withdrawal time of more than 3 min) were better at detecting neoplastic lesions (0.28%) compared to fast endoscopists (0.20%). As a result, they proposed that examination time could be a surrogate measure for the procedure quality[25]. Another study identified that endoscopist who takes more than 7 min to complete exams is more likely to detect a high-risk gastric lesion when compared to a fast endoscopist[26]. Given heterogeneity of data between the two studies, it is difficult to draw conclusions regarding the optimal examination time. This is further complicated by the fact that longer endoscopic times are associated with cardiac arrhythmias, esophageal tears, aspiration, and bacterial translocation[27].

Incidence of gastric pathology varies in different countries. There is higher prevalence of gastric cancer in Eastern countries. Consequently, this led to increased awareness of gastric lesions and a more robust screening protocols in countries like Japan[28]. In Japan, it is recommended to undergo annual upper endoscopy for anybody over the age 40. As a result, there are more early-stage gastric lesions (53%) identified when compared to United States (27%)[29,30]. This shows that increased awareness and adequate training can improve subtle lesion detection.

Duodenum

Some of the commonly missed segments of the small bowel are duodenal bulb, duodenal sweep, and 3rd and 4th parts of the duodenum (Table 1). Some of the maneuvers that can help detect these challenging lesions are careful examination of all 4 walls of the duodenal bulb, use of a side view scope for the duodenal sweep, advancement of the scope by reducing the loop into the 3rd and 4th parts of duodenum (Table 1). Many upper endoscopies do not go past the 2nd part of the duodenum. Lesions in more distal segments of the duodenum (3rd and 4th) are usually more challenging to visualize and require an extra-log fiber optic scope and a trained endoscopist[31]. Interestingly, 60% of benign duodenal lesions and 50% of malignant duodenal lesions are only diagnosed on autopsy and missed on the endoscopic exam [32].

TRAINING

As we learn more about common pitfalls and shortcomings of endoscopy, training fellows to recognize them becomes the next key step. It is important to standardize best practices and shed light on the areas commonly missed in colonoscopy training[33]. One of the studies even suggested that pre-fellowship exposure to best practices of endoscopy, can improve the learning period and procedural skill of fellows [34].

ARTIFICIAL INTELLIGENT in ENDOSCOPY

Endoscopy continues to be an operator dependent procedure. As such, it presents a growing opportunity for development of machine learning technology and computer algorithms to assist endoscopists with lesion detection. Artificial intelligent (AI) has a promise to improve accuracy of endoscopic procedures, reduce inter-operator variability, and compensate for human error and factors contributing to it such as fatigue or limited experience[35]. Thus far, computer-aided detection algorithms of AI have been trained to detect lesions both macroscopically and by optical biopsy/microscopically[36]. Recent studies demonstrated that AI performed better than endoscopists in esophageal cancer and neoplasm detection in pooled sensitivity 94% *vs* 82%, respectively[37]. The specificity of AI-based endoscopy had specificity of 85% for esophageal cancer and neoplasms[37]. AI-based endoscopy provided a 26.5% increase in sensitivity for detection of early gastric cancer when compared to endoscopists (sensitivity of 95%)[38]. The specificity of AI-based endoscopy had specificity of 87.3% for early gastric cancer[38]. AI algorithms have also been targeted towards colorectal cancer detection. Recent reports suggest that AI-assisted colonoscopy has sensitivity of 94% [39,40]. While some reports suggest that AI may not show significant improvement in larger polyp detection rate (38.8% *vs* 26.2%), AI-based colonoscopy showed significant improvement in detection of small and flat polyps that are easily missed (76.0% *vs* 68.8% and 5.9% *vs* 3.3%, respectively)[41].

CONCLUSION

Endoscopy has developed into a sophisticated diagnostic tool that provides great accuracy in lesion detection, but it is not perfect and remains operator dependent. The cases we presented expose weaknesses and shortcomings of endoscopic examination for both the upper and lower gastrointestinal tract, providing an opportunity for improvement. Commonly missed areas and the reason for why they were missed need to be communicated to currently practicing gastroenterologists. Additionally, educating fellows during their training on the possible shortcomings and weaknesses of endoscopy may help improve the quality of procedures in the future.

FOOTNOTES

Author contributions: Turshudzhyan A wrote the letter, Rezaizadeh H and Tadros M critically revised the manuscript.

Conflict-of-interest statement: Rezaizadeh H has financial interest associated with AstraZeneca and research funding/interest associated with Celgene/Bristol Meyers Squibb.

Open-Access: This article is an open-access article that was selected by an in-house editor and fully peer-reviewed by external reviewers. It is distributed in accordance with the Creative Commons Attribution NonCommercial (CC BY-NC 4.0) license, which permits others to distribute, remix, adapt, build upon this work non-commercially, and license their derivative works on different terms, provided the original work is properly cited and the use is non-commercial. See: <https://creativecommons.org/licenses/by-nc/4.0/>

Country/Territory of origin: United States

ORCID number: Alla Turshudzhyan 0000-0001-6867-7569; Houman Rezaizadeh 0000-0002-1066-5394; Micheal Tadros 0000-0003-3118-3893.

S-Editor: Xing YX

L-Editor: A

P-Editor: Xing YX

REFERENCES

- 1 Peery AF, Dellon ES, Lund J, Crockett SD, McGowan CE, Bulsiewicz WJ, Gangarosa LM, Thiny MT, Stizenberg K, Morgan DR, Ringel Y, Kim HP, DiBonaventura MD, Carroll CF, Allen JK, Cook SF, Sandler RS, Kappelman MD, Shaheen NJ. Burden of gastrointestinal disease in the United States: 2012 update. *Gastroenterology* 2012; **143**: 1179-1187.e3 [PMID: 22885331 DOI: 10.1053/j.gastro.2012.08.002]
- 2 Januszewicz W, Kaminski MF. Quality indicators in diagnostic upper gastrointestinal endoscopy. *Therap Adv Gastroenterol* 2020; **13**: 1756284820916693 [PMID: 32477426 DOI: 10.1177/1756284820916693]
- 3 Beg S, Ragunath K, Wyman A, Banks M, Trudgill N, Pritchard DM, Riley S, Anderson J, Griffiths H, Bhandari P, Kaye P, Veitch A. Quality standards in upper gastrointestinal endoscopy: a position statement of the British Society of

- Gastroenterology (BSG) and Association of Upper Gastrointestinal Surgeons of Great Britain and Ireland (AUGIS). *Gut* 2017; **66**: 1886-1899 [PMID: [28821598](#) DOI: [10.1136/gutjnl-2017-314109](#)]
- 4 **Bisschops R**, Areia M, Coron E, Dobru D, Kaskas B, Kuvaev R, Pech O, Ragunath K, Weusten B, Familiari P, Domagk D, Valori R, Kaminski MF, Spada C, Bretthauer M, Bennett C, Senore C, Dinis-Ribeiro M, Rutter MD. Performance measures for upper gastrointestinal endoscopy: a European Society of Gastrointestinal Endoscopy (ESGE) Quality Improvement Initiative. *Endoscopy* 2016; **48**: 843-864 [PMID: [27548885](#) DOI: [10.1055/s-0042-113128](#)]
 - 5 **Park WG**, Shaheen NJ, Cohen J, Pike IM, Adler DG, Inadomi JM, Laine LA, Lieb JG 2nd, Rizk MK, Sawhney MS, Wani S. Quality indicators for EGD. *Am J Gastroenterol* 2015; **110**: 60-71 [PMID: [25448872](#) DOI: [10.1038/ajg.2014.384](#)]
 - 6 **ASGE Endoscopy Unit Quality Indicator Taskforce**, Day LW, Cohen J, Greenwald D, Petersen BT, Schlossberg NS, Vicari JJ, Calderwood AH, Chapman FJ, Cohen LB, Eisen G, Gerstenberger PD, Hambrick RD 3rd, Inadomi JM, MacIntosh D, Sewell JL, Valori R. Quality indicators for gastrointestinal endoscopy units. *VideoGIE* 2017; **2**: 119-140 [PMID: [29905282](#) DOI: [10.1016/j.vgie.2017.02.007](#)]
 - 7 **Rex DK**, Schoenfeld PS, Cohen J, Pike IM, Adler DG, Fennerty MB, Lieb JG 2nd, Park WG, Rizk MK, Sawhney MS, Shaheen NJ, Wani S, Weinberg DS. Quality indicators for colonoscopy. *Gastrointest Endosc* 2015; **81**: 31-53 [PMID: [25480100](#) DOI: [10.1016/j.gie.2014.07.058](#)]
 - 8 **Menon S**, Trudgill N. How commonly is upper gastrointestinal cancer missed at endoscopy? *Endosc Int Open* 2014; **2**: E46-E50 [PMID: [26135259](#) DOI: [10.1055/s-0034-1365524](#)]
 - 9 **Bressler B**, Paszat LF, Chen Z, Rothwell DM, Vinden C, Rabeneck L. Rates of new or missed colorectal cancers after colonoscopy and their risk factors: a population-based analysis. *Gastroenterology* 2007; **132**: 96-102 [PMID: [17241863](#) DOI: [10.1053/j.gastro.2006.10.027](#)]
 - 10 **Tadros M**, Wu GY. Management of occult gi bleeding a clinical guide. Cham: Springer International Publishing; 2021
 - 11 **Rex DK**. Avoiding and defending malpractice suits for postcolonoscopy cancer: advice from an expert witness. *Clin Gastroenterol Hepatol* 2013; **11**: 768-773 [PMID: [23376796](#) DOI: [10.1016/j.cgh.2013.01.027](#)]
 - 12 **Chiu S**, Joseph K, Ghosh S, Cornand RM, Schiller D. Reasons for delays in diagnosis of anal cancer and the effect on patient satisfaction. *Can Fam Physician* 2015; **61**: e509-e516 [PMID: [26889506](#)]
 - 13 **Edwards AT**, Morus LC, Foster ME, Griffith GH. Anal cancer: the case for earlier diagnosis. *J R Soc Med* 1991; **84**: 395-397 [PMID: [1865443](#)]
 - 14 **Rex DK**, Vemulapalli KC. Retroflexion in colonoscopy: why? *Gastroenterology* 2013; **144**: 882-883 [PMID: [23499952](#) DOI: [10.1053/j.gastro.2013.01.077](#)]
 - 15 **Pohl H**, Bensen SP, Toor A, Gordon SR, Levy LC, Berk B, Anderson PB, Anderson JC, Rothstein RI, MacKenzie TA, Robertson DJ. Cap-assisted colonoscopy and detection of Adenomatous Polyps (CAP) study: a randomized trial. *Endoscopy* 2015; **47**: 891-897 [PMID: [26126162](#) DOI: [10.1055/s-0034-1392261](#)]
 - 16 **Ai X**, Qiao W, Han Z, Tan W, Bai Y, Liu S, Zhi F. Results of a second examination of the right side of the colon in screening and surveillance colonoscopy: a systematic review and meta-analysis. *Eur J Gastroenterol Hepatol* 2018; **30**: 181-186 [PMID: [29232250](#) DOI: [10.1097/MEG.0000000000001009](#)]
 - 17 **Bhurwal A**, Rattan P, Sarkar A, Patel A, Haroon S, Gjeorgijevski M, Bansal V, Mutneja H. A comparison of 9-min colonoscopy withdrawal time and 6-min colonoscopy withdrawal time: A systematic review and meta-analysis. *J Gastroenterol Hepatol* 2021; **36**: 3260-3267 [PMID: [34617312](#) DOI: [10.1111/jgh.15701](#)]
 - 18 **Baxi AJ**, Chintapalli K, Katkar A, Restrepo CS, Betancourt SL, Sunnapwar A. Multimodality Imaging Findings in Carcinoid Tumors: A Head-to-Toe Spectrum. *Radiographics* 2017; **37**: 516-536 [PMID: [28287937](#) DOI: [10.1148/rg.2017160113](#)]
 - 19 **Modlin IM**, Lye KD, Kidd M. A 5-decade analysis of 13,715 carcinoid tumors. *Cancer* 2003; **97**: 934-959 [PMID: [12569593](#) DOI: [10.1002/cncr.11105](#)]
 - 20 **Gupta A**, Lubner MG, Wertz RM, Foley E, Loeffler A, Pickhardt PJ. CT detection of primary and metastatic ileal carcinoid tumor: rates of missed findings and associated delay in clinical diagnosis. *Abdom Radiol (NY)* 2019; **44**: 2721-2728 [PMID: [31016344](#) DOI: [10.1007/s00261-019-01945-0](#)]
 - 21 **Gupta N**, Gaddam S, Wani SB, Bansal A, Rastogi A, Sharma P. Longer inspection time is associated with increased detection of high-grade dysplasia and esophageal adenocarcinoma in Barrett's esophagus. *Gastrointest Endosc* 2012; **76**: 531-538 [PMID: [22732877](#) DOI: [10.1016/j.gie.2012.04.470](#)]
 - 22 **Parasa S**, Desai M, Vittal A, Chandrasekar VT, Pervaz A, Kennedy KF, Gupta N, Shaheen NJ, Sharma P. Estimating neoplasia detection rate (NDR) in patients with Barrett's oesophagus based on index endoscopy: a systematic review and meta-analysis. *Gut* 2019; **68**: 2122-2128 [PMID: [30872393](#) DOI: [10.1136/gutjnl-2018-317800](#)]
 - 23 **Karaca C**, Daglilar ES, Soyer OM, Gulluoglu M, Brugge WR. Endoscopic submucosal resection of gastric subepithelial lesions smaller than 20 mm: a comparison of saline solution-assisted snare and cap band mucosectomy techniques. *Gastrointest Endosc* 2017; **85**: 956-962 [PMID: [27663715](#) DOI: [10.1016/j.gie.2016.09.016](#)]
 - 24 **Dinis-Ribeiro M**, Areia M, de Vries AC, Marcos-Pinto R, Monteiro-Soares M, O'Connor A, Pereira C, Pimentel-Nunes P, Correia R, Ensari A, Dumonceau JM, Machado JC, Macedo G, Malfertheiner P, Matysiak-Budnik T, Megraud F, Miki K, O'Morain C, Peek RM, Ponchon T, Ristimaki A, Rembacken B, Carneiro F, Kuipers EJ; European Society of Gastrointestinal Endoscopy; European Helicobacter Study Group; European Society of Pathology; Sociedade Portuguesa de Endoscopia Digestiva. Management of precancerous conditions and lesions in the stomach (MAPS): guideline from the European Society of Gastrointestinal Endoscopy (ESGE), European Helicobacter Study Group (EHS), European Society of Pathology (ESP), and the Sociedade Portuguesa de Endoscopia Digestiva (SPED). *Endoscopy* 2012; **44**: 74-94 [PMID: [22198778](#) DOI: [10.1055/s-0031-1291491](#)]
 - 25 **Park JM**, Huo SM, Lee HH, Lee BI, Song HJ, Choi MG. Longer Observation Time Increases Proportion of Neoplasms Detected by Esophagogastroduodenoscopy. *Gastroenterology* 2017; **153**: 460-469.e1 [PMID: [28501581](#) DOI: [10.1053/j.gastro.2017.05.009](#)]
 - 26 **Teh JL**, Tan JR, Lau LJ, Saxena N, Salim A, Tay A, Shabbir A, Chung S, Hartman M, So JB. Longer examination time improves detection of gastric cancer during diagnostic upper gastrointestinal endoscopy. *Clin Gastroenterol Hepatol* 2015;

- 13: 480-487.e2 [PMID: [25117772](#) DOI: [10.1016/j.cgh.2014.07.059](#)]
- 27 **Kavic SM**, Basson MD. Complications of endoscopy. *Am J Surg* 2001; **181**: 319-332 [PMID: [11438266](#) DOI: [10.1016/s0002-9610\(01\)00589-x](#)]
- 28 **Hanazaki K**, Sodeyama H, Wakabayashi M, Miyazawa M, Yokoyama S, Sode Y, Kawamura N, Miyazaki T, Ohtsuka M. Surgical treatment of gastric cancer detected by mass screening. *Hepatogastroenterology* 1997; **44**: 1126-1132 [PMID: [9261611](#)]
- 29 **Theuer CP**. Asian gastric cancer patients at a southern California comprehensive cancer center are diagnosed with less advanced disease and have superior stage-stratified survival. *Am Surg* 2000; **66**: 821-826 [PMID: [10993608](#)]
- 30 **Theuer CP**, Kurosaki T, Ziogas A, Butler J, Anton-Culver H. Asian patients with gastric carcinoma in the United States exhibit unique clinical features and superior overall and cancer specific survival rates. *Cancer* 2000; **89**: 1883-1892 [PMID: [11064344](#) DOI: [10.1002/1097-0142\(20001101\)89:9<1883::aid-cnrc3>3.3.co;2-8](#)]
- 31 **Markogiannakis H**, Theodorou D, Toutouzas KG, Gloustanou G, Katsaragakis S, Bramis I. Adenocarcinoma of the third and fourth portion of the duodenum: a case report and review of the literature. *Cases J* 2008; **1**: 98 [PMID: [18706123](#) DOI: [10.1186/1757-1626-1-98](#)]
- 32 **Kaminski N**, Shaham D, Eliakim R. Primary tumours of the duodenum. *Postgrad Med J* 1993; **69**: 136-138 [PMID: [8506195](#) DOI: [10.1136/pgmj.69.808.136](#)]
- 33 **Kumar NL**, Smith BN, Lee LS, Sewell JL. Best Practices in Teaching Endoscopy Based on a Delphi Survey of Gastroenterology Program Directors and Experts in Endoscopy Education. *Clin Gastroenterol Hepatol* 2020; **18**: 574-579.e1 [PMID: [31125782](#) DOI: [10.1016/j.cgh.2019.05.023](#)]
- 34 **Kim DH**, Park SJ, Cheon JH, Kim TI, Kim WH, Hong SP. Does a Pre-Training Program Influence Colonoscopy Proficiency during Fellowship? *PLoS One* 2016; **11**: e0164360 [PMID: [27764144](#) DOI: [10.1371/journal.pone.0164360](#)]
- 35 **El Hajjar A**, Rey JF. Artificial intelligence in gastrointestinal endoscopy: general overview. *Chin Med J (Engl)* 2020; **133**: 326-334 [PMID: [31929362](#) DOI: [10.1097/CM9.0000000000000623](#)]
- 36 **Li H**, Hou X, Lin R, Fan M, Pang S, Jiang L, Liu Q, Fu L. Advanced endoscopic methods in gastrointestinal diseases: a systematic review. *Quant Imaging Med Surg* 2019; **9**: 905-920 [PMID: [31281783](#) DOI: [10.21037/qims.2019.05.16](#)]
- 37 **Zhang SM**, Wang YJ, Zhang ST. Accuracy of artificial intelligence-assisted detection of esophageal cancer and neoplasms on endoscopic images: A systematic review and meta-analysis. *J Dig Dis* 2021; **22**: 318-328 [PMID: [33871932](#) DOI: [10.1111/1751-2980.12992](#)]
- 38 **Ikenoyama Y**, Hirasawa T, Ishioka M, Namikawa K, Yoshimizu S, Horiuchi Y, Ishiyama A, Yoshio T, Tsuchida T, Takeuchi Y, Shichijo S, Katayama N, Fujisaki J, Tada T. Detecting early gastric cancer: Comparison between the diagnostic ability of convolutional neural networks and endoscopists. *Dig Endosc* 2021; **33**: 141-150 [PMID: [32282110](#) DOI: [10.1111/den.13688](#)]
- 39 **Kominami Y**, Yoshida S, Tanaka S, Sanomura Y, Hirakawa T, Raytchev B, Tamaki T, Koide T, Kaneda K, Chayama K. Computer-aided diagnosis of colorectal polyp histology by using a real-time image recognition system and narrow-band imaging magnifying colonoscopy. *Gastrointest Endosc* 2016; **83**: 643-649 [PMID: [26264431](#) DOI: [10.1016/j.gie.2015.08.004](#)]
- 40 **Byrne MF**, Chapados N, Soudan F, Oertel C, Linares Pérez M, Kelly R, Iqbal N, Chandelier F, Rex DK. Real-time differentiation of adenomatous and hyperplastic diminutive colorectal polyps during analysis of unaltered videos of standard colonoscopy using a deep learning model. *Gut* 2019; **68**: 94-100 [PMID: [29066576](#) DOI: [10.1136/gutjnl-2017-314547](#)]
- 41 **Xu L**, He X, Zhou J, Zhang J, Mao X, Ye G, Chen Q, Xu F, Sang J, Wang J, Ding Y, Li Y, Yu C. Artificial intelligence-assisted colonoscopy: A prospective, multicenter, randomized controlled trial of polyp detection. *Cancer Med* 2021; **10**: 7184-7193 [PMID: [34477306](#) DOI: [10.1002/cam4.4261](#)]



Published by **Baishideng Publishing Group Inc**
7041 Koll Center Parkway, Suite 160, Pleasanton, CA 94566, USA

Telephone: +1-925-3991568

E-mail: bpgoffice@wjgnet.com

Help Desk: <https://www.f6publishing.com/helpdesk>

<https://www.wjgnet.com>

