

Duodenal Perforation Precipitated by Scrub Typhus

Raghunath Rajat, David Deepu, Arul Jeevan Jonathan, Abhilash Kundavaram Paul Prabhakar

Department of General Surgery, Christian Medical College, Vellore, Tamil Nadu, India

ABSTRACT

Scrub typhus is an acute febrile illness usually presenting with fever, myalgia, headache, and a pathognomonic eschar. Severe infection may lead to multiple organ failure and death. Gastrointestinal tract involvement in the form of gastric mucosal erosions and ulcerations owing to vasculitis resulting in gastrointestinal bleeding is common. This process may worsen a pre-existent asymptomatic peptic ulcer, causing duodenal perforation, and present as an acute abdomen requiring surgical exploration. We report the case of a patient with no previous symptoms or risk factors for a duodenal ulcer, who presented with an acute duodenal perforation, probably precipitated by scrub typhus infection.

Key words: Scrub typhus, duodenal perforation, acute abdomen

INTRODUCTION

Scrub typhus is caused by *Orientia tsutsugamushi*, a Gram-negative obligate intracellular bacterium, which is transmitted to humans by the bite of the larval stage (chigger) of the trombiculid mites, most commonly *Leptotrombidium deliense*. *O. tsutsugamushi* infects various cells, including endothelial cells and phagocytes, causing acute focal or disseminated vasculitis. Gastrointestinal vasculitis can cause multiple erosions and ulcers in the mucosa, which may cause gastrointestinal bleeding.^[1,2] However, severe ulceration leading to perforation is a very rare occurrence. We report the case of a patient with no previous symptoms or risk factors for a duodenal ulcer, who presented with an acute duodenal perforation, probably precipitated by scrub typhus infection.

CASE REPORT

A 55-year-old woman with no premorbid illnesses presented to the Emergency Department with a history of high-grade intermittent fever with chills, myalgia, and headache for seven days and severe abdominal pain for one day. She was not on any regular medications prior to this illness

and did not have any surgery in the past. On examination her pulse rate was 120/minute, blood pressure was 100/70 mm Hg, and respiratory rate was 28/minute. Her abdomen was distended with guarding and rebound tenderness and bowel sounds were absent. The cardiovascular, respiratory, and central nervous system examinations were normal. A complete blood picture profile showed a hemoglobin of 11.9 gm/dl, total WBC count of 16,400/cu mm (84% neutrophils, 13% lymphocytes, 3% monocytes, and 4% eosinophils) and a platelet count of 6,000/cu mm. Liver function tests showed a total bilirubin of 2.2 mg% and a serum albumin of 2.6 gm%, with normal liver enzymes and alkaline phosphatase. Serum creatinine, serum amylase, and lipase levels were normal. An erect x-ray of the abdomen showed air under the diaphragm confirming a hollow viscus perforation [Figure 1]. She was immediately taken for surgical closure of a perforated hollow viscus, with the support of platelet concentrates and packed red cells. Intraoperatively a 1 × 1 cm perforation was found on the anterior aspect of the first part of duodenum and multiple patchy erosions were noted over the mesentery. After successful closure of the duodenal ulcer she was shifted to the ward for further management. An initial examination showed an eschar over the right inframammary region. The diagnosis of scrub typhus was confirmed by a positive IgM enzyme-linked immunosorbent assay (ELISA) test (InBios International, Seattle, USA). Tests for malarial parasites, IgM ELISA for dengue fever, and three blood

Access this article online

Quick Response Code:



Website:
www.jgid.org

DOI:
10.4103/0974-777X.154450

Address for correspondence:

Dr. Abhilash Kundavaram Paul Prabhakar,
E-mail: kppabhilash@gmail.com

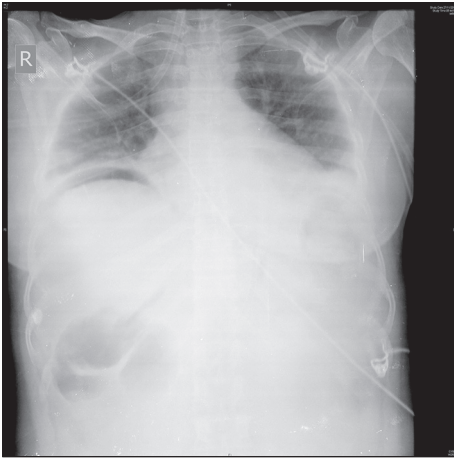


Figure 1: X-ray abdomen, erect, showing air under the diaphragm

cultures were negative. She showed a dramatic response to intravenous azithromycin and had complete resolution of her symptoms, with normal platelet counts, within 48 hours.

DISCUSSION

Scrub typhus is a vector-borne bacterial infection, commonly seen in an area known as the ‘tsutsugamushi triangle,’ which extends from northern Japan and Far East Russia in the north, to northern Australia in the south, and to Pakistan and Afghanistan in the west. The infection can range from a self-limiting disease to, if not promptly diagnosed and appropriately treated, a fatal illness in 12-35% of the cases, with multiple organ dysfunction.^[3] Complications include acute respiratory distress syndrome (ARDS), hepatitis, renal failure, meningoencephalitis and myocarditis with shock in a varying proportion of patients.

Involvement of the GI tract is well-documented, with nausea, vomiting, jaundice, and abdominal pain being the common symptoms. Erosion and ulceration of the gastric mucosa causing GI bleeding are also frequently reported. This is further compounded by thrombocytopenia, which is usually associated with severe infection. A study in Thailand has reported hematemesis or melena in 25% of the patients.^[4] Endoscopic findings in patients with scrub typhus include superficial hemorrhage, multiple erosions and ulcers without any predilection sites. Kim *et al.*, graded the endoscopic findings as Grade I, normal, nonspecific hyperemia; Grade II, distinct hyperemia, petechiae, purpura;

Grade III, superficial hemorrhage, erosion; and Grade IV, ulcer, active bleeding.^[2] There is a direct correlation between the clinical severity and endoscopic findings.

Although scrub typhus cannot be directly implicated in causing the perforation without histopathological evidence, the vasculitis may have worsened a pre-existing ulcer. Chang *et al.*, reported two cases of peritonitis on account of gastric perforation in patients with scrub typhus, with the histopathology of the ulcer showing infiltration of the lymphocytes and plasma cells within the vessel walls, consistent with vasculitis on account of scrub typhus.^[5] Kang *et al.*, also reported a similar presentation of scrub typhus with duodenal perforation.^[6] Some other unusual presentations of scrub typhus with an acute abdomen, as reported in literature, include acute acalculous cholecystitis, acute pancreatitis, and pancreatic abscess.^[7]

In conclusion, scrub typhus may cause serious GI complications as a result of focal or disseminated vasculitis. Pre-existent GI mucosal ulcers may worsen and rupture and present as an acute abdomen. Prompt recognition of this unusual complication precipitated by scrub typhus may be life saving.

REFERENCES

1. Jeong YJ, Kim S, Wook YD, Lee JW, Kim KI, Lee SH. Scrub Typhus: Clinical, Pathologic, and Imaging Findings. *Radiographics* 2007;27:161-72.
2. Kim SJ, Chung IK, Chung IS, Song DH, Park SH, Kim HS, *et al.* The clinical significance of upper gastrointestinal endoscopy in gastrointestinal vasculitis related to scrub typhus. *Endoscopy* 2000;32:950-5.
3. Chrispal A, Boorugu H, Gopinath KG, Prakash JA, Chandy S, Abraham OC, *et al.* Scrub typhus: An unrecognized threat in South India — clinical profile and predictors of mortality. *Trop Doct* 2010;40:129-33.
4. Aung-Thu, Supanaranond W, Phumiratanaprapin W, Phonrat B, Chinprasatsak S, Ratanajaratroj N. Gastrointestinal manifestations of septic patients with scrub typhus in Maharat Nakhon Ratchasima Hospital. *Southeast Asian J Trop Med Public Health* 2004;35:845-51.
5. Lee CH, Lee JH, Yoon KJ, Hwang JH, Lee CS. Peritonitis in Patients with Scrub Typhus. *Am J Trop Med Hyg* 2012;86:1046-8.
6. Kang JW, Jeong WJ, Lee KW, Lee SJ, Lee JH, Kim YD, *et al.* A case of duodenal ulcer perforation combined with scrub typhus. *Korean J Med* 2012;82:449-52.
7. Yang CH, Young TG, Peng MY, Hsu GJ. Unusual presentation of acute abdomen in scrub typhus: A report of two cases. *Chung Hua I Hsueh Tsa Chih (Taipei)* 1995;55:401-4.

How to cite this article: Rajat R, Deepu D, Jonathan AJ, Prabhakar AP. Duodenal perforation precipitated by scrub typhus. *J Global Infect Dis* 2015;7:87-8.

Source of Support: Nil. **Conflict of Interest:** None declared.